

## Tunneled lumbar drain

### Technical note

MICHAEL HAHN, M.D., RAJ MURALI, M.D., AND WILLIAM T. COULDWELL, M.D., PH.D.

*Department of Neurosurgery, New York Medical College, Valhalla and New York, New York; and Department of Neurosurgery, University of Utah School of Medicine, Salt Lake City, Utah*

✓ The authors report a simple and rapid procedure for tunneling a lumbar drain subcutaneously to facilitate chronic cerebrospinal fluid (CSF) drainage. A standard lumbar puncture (LP) is performed with a large-bore Tuohy needle (14- to 16-gauge), the drainage catheter is advanced into the subarachnoid space, and the needle is removed. The free Tuohy needle is then passed from a lateral position and brought out through the initial LP site. The free catheter is fed through the needle, and the needle is removed. The drain is attached to an external drainage bag in the usual manner. The authors have found this method particularly useful in some skull base and spinal surgical applications in which longer term continuous CSF drainage is desired.

**KEY WORDS** • lumbar drain • cerebrospinal fluid shunt

TREATMENT to prevent a CSF fistula commonly involves the use of continuous lumbar drainage.<sup>1–3,6</sup> For longer term drainage, it may be desirable to tunnel the catheter laterally to avoid kinking of or leakage around the tube at the skin exit site. We report a simple and rapid procedure for tunneling a lumbar drain subcutaneously to facilitate chronic closed CSF drainage. We have found this method to be particularly useful in some skull base and spinal surgical applications in which continuous drainage is desired.

### Surgical Procedure

The patient is placed in either the lateral decubitus or the vertical anterior flexed position, and the skin is prepared in the usual fashion. Surgical drapes extend more laterally to one side or the other to allow tunneling. A standard LP is performed, usually in the L4–5 interspace, with a large-bore Tuohy needle (14- to 16-gauge). When CSF is encountered, the curve of the needle is directed superiorly, the stylet is removed, and the catheter is advanced into the subarachnoid space at least 20 cm (Fig. 1A). The catheter (17- or 18-gauge) is then slowly advanced with one hand, and the needle is simultaneously removed. A local anesthetic agent is injected subcutaneously along the desired path of tunneling for the length of the needle. The free Tuohy needle is passed from this direct lateral position and brought out through the initial LP site, with care being taken not to cut the catheter with the tip of the needle (more room may be obtained be-

Abbreviations used in this paper: CSF = cerebrospinal fluid; LP = lumbar puncture.

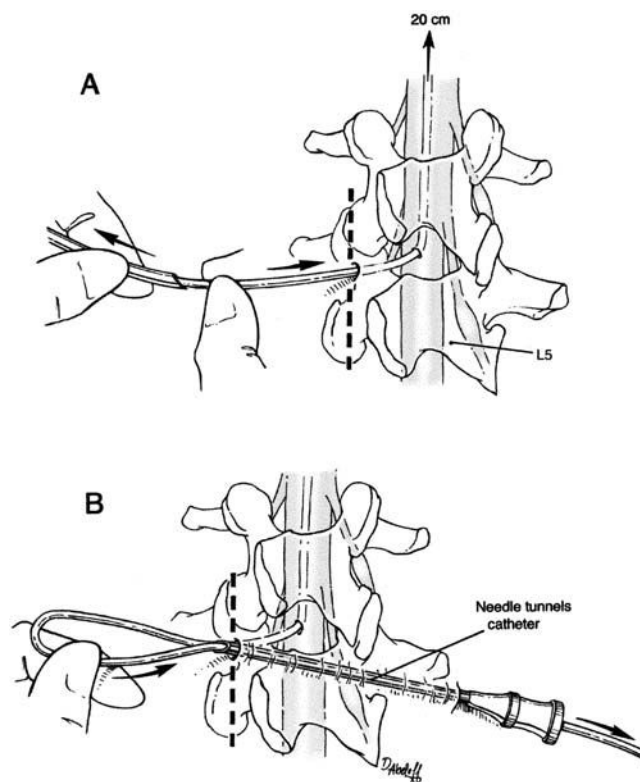


FIG. 1. Drawings depicting the procedure. The Tuohy needle is used to place the catheter in the subarachnoid space as usual (A); then after its removal, the Tuohy needle itself is used to tunnel the catheter from the initial midline LP site laterally (B).

## Simple lumbar drain tunneling method

side the catheter by making a skin incision approximately 5 mm in length and adjacent to the tube). The catheter is fed through the needle (Fig. 1B), and the needle is removed, being careful to prevent any subcutaneous coiling of the catheter. The drain is attached to an external drainage bag in the usual manner. If the midline LP site had to be enlarged with a scalpel, a single simple skin suture is placed, and sterile dressings are applied to the midline LP and lateral exit sites. A loop is made in the catheter to relieve tension, and the catheter is taped over onto the patient's flank.

### Results

This method provides a simple and rapid procedure for lumbar drain tunneling. The authors have used this method for several years, in more than 200 cases, and routinely leave the catheter in place for up to 7 days of continuous CSF drainage. Although this tunneling procedure has not prevented infectious complications completely, it reduces CSF leakage around the tube at the exit site and increases patient tolerance of the indwelling catheter.

### Discussion

A CSF fistula is a well-recognized complication of basilar skull fracture, or skull base and spinal surgery. It has long been recognized that treatment or prevention of this complication may be facilitated by the use of continuous indwelling intrathecal lumbar spinal drainage.<sup>1,3,5,6</sup> Various methods of continuous drainage have been used, with major associated complications consisting of infection, deficient or excessive CSF flow, and pneumocephalus.<sup>1,2,4</sup> Some local complications related to catheter kinking and leakage of CSF around the tube may be obviated by tunneling a segment of the catheter to exit laterally. In addition, patient comfort is enhanced by the avoidance of a bulky dressing over the midline exit site. We have described a simple and

rapid tunneling method in which the same Tuohy needle is used to place the intrathecal catheter.

### Conclusions

We have found this simple procedure to be particularly useful in some skull base and spinal surgical applications in which longer term continuous CSF drainage is desired.

### References

1. Basauri LT, Concha-Julio E, Selman JM, et al: Cerebrospinal fluid spinal lumbar drainage: indications, technical tips, and pitfalls. **Crit Rev Neurosurg** 26:21–27, 1999
2. Coplin WM, Avellino AM, Kim DK, et al: Bacterial meningitis associated with lumbar drains: a retrospective cohort study. **J Neurol Neurosurg Psychiatry** 67:468–473, 1999
3. Findler G, Sahar A, Beller AJ: Continuous lumbar drainage of cerebrospinal fluid in neurosurgical patients. **Surg Neurol** 8:455–457, 1977
4. Grady RE, Horlocker TT, Brown RD, et al: Neurologic complications after placement of cerebrospinal fluid drainage catheters and needles in anesthetized patients: implications for regional anesthesia. Mayo Perioperative Outcomes Group. **Anesth Analg** 88:388–392, 1999
5. Roland PS, Marple BF, Meyerhoff WL, et al: Complications of lumbar spinal fluid drainage. **Otolaryngol Head Neck Surg** 107:564–569, 1992
6. Shapiro SA, Scully T: Closed continuous drainage of cerebrospinal fluid via a lumbar subarachnoid catheter for treatment or prevention of cranial/spinal cerebrospinal fluid fistula. **Neurosurgery** 30:241–245, 1992

---

Manuscript received November 26, 2001.

Address reprint requests to: William T. Couldwell, M.D., Ph.D., Department of Neurosurgery, University of Utah, Suite 3B409, 30 North 1900 East, Salt Lake City, Utah 84132-2303. email: william.couldwell@hsc.utah.edu.