

Complications of intracranial pressure monitoring in children with head trauma

RICHARD C. E. ANDERSON, M.D., PETER KAN, M.D., PAUL KLIMO, M.D., M.P.H., DOUGLAS L. BROCKMEYER, M.D., MARION L. WALKER, M.D., AND JOHN R. W. KESTLE, M.D., M.Sc.

Primary Children's Medical Center, University of Utah, Department of Neurosurgery, Salt Lake City, Utah

Object. Intracranial pressure (ICP) monitoring has become routine in the management of patients with traumatic brain injury (TBI). Many surgeons prefer to use external ventricular drains (EVDs) over fiberoptic monitors to measure ICP because of the added benefit of cerebrospinal fluid drainage. The purpose of this study was to examine a consecutive series of children with TBI and compare the incidence of complications after placement of an EVD, a fiberoptic intraparenchymal monitor, or both.

Methods. A retrospective chart review was conducted to identify children with TBI who met the criteria for insertion of an ICP monitor. All patients underwent head CT scanning on admission and after placement of an ICP monitor.

During a 5-year period 80 children met the criteria for inclusion in the study. Eighteen children (22.5%) underwent EVD placement only, 18 (22.5%) underwent placement of a fiberoptic device only, and 44 (55%) received both. A total of 62 fiberoptic devices (48%) were inserted, and 68 EVDs (52%) were placed. Overall, there was a fourfold increased risk of complications in children who received an EVD compared with those in whom a fiberoptic monitor was placed ($p = 0.004$). Hemorrhagic complications were detected in 12 (17.6%) of 62 patients who received an EVD compared with four (6.5%) of 62 patients who received a fiberoptic monitor ($p = 0.025$). Six (8.8%) of 68 EVDs were malpositioned and required replacement; in three (50%) of these cases a hemorrhagic complication occurred. Only one infection was noted in a patient with an EVD (1.5%).

Conclusions. In this retrospective cohort of pediatric patients with TBI, complication rates were significantly higher in those receiving EVDs than in those in whom fiberoptic monitors were placed. Although the majority of these complications did not entail clinical sequelae, surgeons should be aware of the different complication rates when choosing the most appropriate device for each patient.

KEY WORDS • ventriculostomy • external ventricular drain • head trauma • intracranial pressure monitoring • fiberoptic monitor • children

ELEVATED ICP has been recognized as one of the most important factors affecting morbidity and mortality rates in patients who have suffered TBI;^{23,24,34} therefore, ICP monitoring has become routine in the management of severe head injuries in both adults and children. A variety of monitoring techniques and devices are available, each with advantages and disadvantages. An EVD is considered the gold standard for accurate ICP monitoring, and it allows for drainage of CSF, a potentially important means to lower elevated pressures.^{15,25} Alternatively, several different types of fiberoptic monitoring systems are currently available that can be placed in the epidural space, subdural space, brain parenchyma, or ventricle.^{4,5,13,16,17,30–34,39,41}

Overall, insertion of an ICP monitor is thought to be a

safe and effective adjunct in the management of raised ICP, producing a low incidence of hemorrhagic or infectious complications.^{1,2,4,5,13,16,17,20,22,26,30–34,39,41} Authors of the majority of studies have focused on adult patients in whom ICP monitors have been placed for a variety of reasons, including head trauma, metabolic coma, hydrocephalus, and postoperative craniotomy. There are few studies in the literature in which these issues are addressed in the pediatric population.^{5,16,33}

Authors of a recently published report described the hemorrhagic complications of fiberoptic intraparenchymal monitors in children.⁵ When monitoring ICP, however, many surgeons prefer to use EVDs alone or concomitant with fiberoptic devices when possible because of the added benefit of drainage of CSF to reduce elevated ICP. Although the complication rates associated with EVDs have been examined in detail in previous reports,^{11,18,20,27,28,41} none has addressed exclusively the complication rates in children who have suffered head trauma. Because of the generally smaller ventricle size and thin scalps in

Abbreviations used in this paper: CT = computerized tomography; CSF = cerebrospinal fluid; EVD = external ventricular drain; ICP = intracranial pressure.

children, it is certainly possible that both the hemorrhagic and infection complication rates in this group of patients may differ substantially from those reported previously. The purpose of this study was to examine a consecutive series of children with TBI in whom an ICP monitor had been placed and to compare the incidence of complications (hemorrhagic, infectious, and malpositioning) after insertion of an EVD, a fiberoptic intraparenchymal ICP monitor, or both.

Clinical Material and Methods

Patient Population

Between 1998 and 2003, a total of 80 children admitted to Primary Children's Medical Center after sustaining head trauma were evaluated and met criteria for insertion of an ICP monitoring device (EVD, intraparenchymal fiberoptic monitor, or both). The mean age of this group was 8.5 years (range 0.5–18 years). There were 51 boys (64%) and 29 girls (36%). Criteria for ICP monitoring were standardized and included children with an initial Glasgow Coma Scale score of less than 8, with evidence of intracranial injury or elevated ICP (such as, effacement of cisterns) on head CT scans.^{15,19} Prior to placement of either an EVD or fiberoptic ICP monitor, the results of normal coagulation studies and platelet levels were confirmed. Children who had undergone placement of an ICP monitoring device after elective intracranial procedures or for the treatment of hydrocephalus were excluded from this study.

Study Methodology

A retrospective review of patients' hospital charts, laboratory studies, and radiographic studies was conducted. Head CT scans obtained at admission and after placement of an ICP monitoring device were available in all patients included in the study. Unless unusual circumstances arose, postprocedure CT scans were obtained within 24 hours (maximum 5 days after insertion). All CT scans were reviewed and graded by the authors based on a previously published scale.⁵

ICP Monitoring Devices

Patients who underwent placement of a fiberoptic intraparenchymal monitor (Camino; Integra LifeSciences, Plainsboro, NJ), an EVD, or both were included in this study. Monitoring devices in all patients were placed at the bedside in the pediatric intensive care unit after normal results of coagulation and platelet studies were confirmed. The decision to use the right or left side was based primarily on the location of intracranial injury, skull fracture, and skin covering; in ambivalent situations, the right side was preferred. The insertion point for all monitoring devices was approximately 1 cm anterior to the coronal suture in the midpupillary line. The area of interest was shaved and aseptically draped, and local anesthetic was infiltrated. A stab incision was made through the skin down to the bone. A twist-drill hole was then made through the skull, and the dura was pierced with an 18-gauge spinal needle. If a fiberoptic device was placed, the Camino bolt was screwed manually into the bone and the catheter was connected to a

monitor, calibrated to zero, and then placed through the bolt approximately 2 cm into the brain parenchyma. If an EVD was placed, the catheter was directed using anatomical landmarks into the frontal horn of the lateral ventricle, tunneled subcutaneously to a distant site, and secured to the skin by using 2-0 silk ties. No more than three attempts were made to cannulate the ventricle. The catheter was connected to an external drainage bag and left open at 10 to 15 cm H₂O above the ear. If a second monitor was used concomitantly, it was placed through a separate incision just anterior to the first monitor. Personal preferences of the senior authors (J.R.W.K., D.L.B., M.L.W.) determined which monitor type was used or whether dual monitoring was used. Monitoring was discontinued when ICP and waveforms returned to normal after the patient was successfully weaned from ICP lowering maneuvers.

Outcome Criteria

Intracranial hemorrhage attributable to the placement of the monitoring device was defined as a new area of hemorrhage adjacent to the probe, which could be demonstrated on a postprocedure head CT scan. In all cases of dual monitoring, the location of the hemorrhage made it possible to determine which monitoring device was responsible for the hemorrhage. Malpositioned EVDs were defined as those catheters shown on a CT scan to be outside the ventricular system and which required a second procedure for replacement of the device. External ventricular drains that were found in locations other than the frontal horn on postprocedure CT scanning (third ventricle, contralateral lateral ventricle) but that continued to drain CSF were not considered complications. Meningitis and ventriculitis were diagnosed from positive CSF cultures. No prophylactic antibiotic agents were administered during the ICP monitoring. Cerebrospinal fluid was cultured only when a fever was present, because routine analysis of CSF in children with EVDs is not supported by the literature.¹⁴

Results

Among children consecutively evaluated over a 5-year period at a Level 1 trauma and regional medical center, ICP monitoring was performed in 80 patients. More than one procedure was performed in 50 children for a total of 130 procedures. Eighteen children (22.5%) underwent placement of an EVD only, 18 (22.5%) received a fiberoptic intraparenchymal device only, and 44 (55%) underwent placement of both. In six patients, it was necessary to place a second EVD; therefore, a total of 62 fiberoptic devices (48%) were implanted and 68 EVDs (52%) were placed.

Hemorrhagic Complications

A total of 114 procedures (87.7%) were performed without any hemorrhagic complications. To facilitate comparisons, we classified hemorrhages according to the grading system recently proposed by Blaha and colleagues.⁵ Grade I hemorrhages are small punctate hemorrhages or localized subarachnoid hemorrhages; Grade II hemorrhages are larger bleeds that do not cause a new neurological deficit or require surgical evacuation, but may alter readings of ICP; and Grade III hemorrhages cause a new deficit or necessitate surgical removal (Fig. 1).

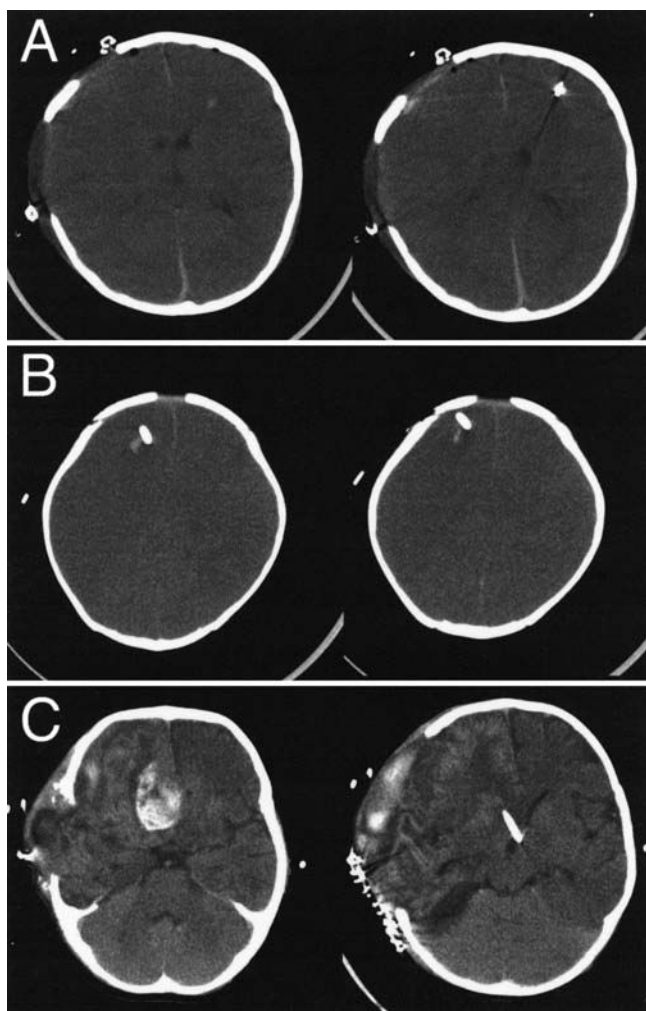


FIG. 1. Axial unenhanced head CT scans demonstrating Grades I (A), II (B), and III (C) hemorrhages.

Twelve (17.6%) of 68 EVD insertions led to hemorrhagic complications detected on postprocedure CT scans: three (25%) of these were Grade I, eight (67%) were Grade II, and one (8%) was Grade III. In comparison, four (6.5%) of 62 patients who received fiberoptic intraparenchymal monitors had hemorrhagic complications: three (75%) of these were Grade I; one (25%) was Grade II; and none was Grade III (Table 1). The difference in the incidence of hemorrhagic complications resulting from placement of EVDs and intraparenchymal fiberoptic monitors reached statistical significance ($p = 0.025$). There was no difference in the incidence of hemorrhage in patients receiving EVDs only and those receiving both a fiberoptic intraparenchymal monitor and an EVD ($p = 0.79$).

Infection Complications

There were no complications due to infection in the 62 patients receiving fiberoptic intraparenchymal monitors. One (1.6%) of 62 patients in whom an EVD was placed suffered an infection complication. An EVD was removed from this patient after 9 days, and cultures grew *Staphylococcus aureus*.

TABLE 1

*Comparison of hemorrhagic complication rates in patients with EVDs and intraparenchymal fiberoptic monitor**

Type of Monitor	No. of Patients	Hemorrhage Grade (%)			Total
		I	II	III	
EVD	68	3 (4.4)	8 (11.7)	1 (1.5)	12 (17.6)
fiberoptic	62	3 (4.8)	1 (1.6)	0	4 (6.4)

Malpositioned Catheters and Mechanical Failure

Six (8.8%) of 68 EVD insertions resulted in malpositions and replacement was required (Fig. 2). Of note, three (50%) of these reinsertions resulted in hemorrhagic complications. None of the fiberoptic monitors had to be replaced because of mechanical failure.

Discussion

Given all of the clinical indications for its use, ICP monitoring has had the most positive impact on the management of severe TBI.¹⁹ Abnormal elevations of ICP commonly occur in patients with TBI, and numerous studies show that control of ICP improves outcome.^{3,10,21,27,35} Although ICP monitoring has become routine, there are no guidelines regarding whether to use an intraparenchymal fiberoptic monitor or an EVD when monitoring is desired after TBI. The device selected is at present dictated primarily by the surgeon's personal preference.

Both types of monitors have advantages and disadvantages. Many surgeons prefer the EVD because it is considered the gold standard, and problems with its operation are easy to troubleshoot. Use of the ventricular catheter has the added advantage of allowing the therapeutic drainage of CSF to lower ICP.^{16,27} This device also requires that the brain be fully penetrated; requires some skill in placement, especially in the case of small or shifted ventricles; can malfunction or dampen secondary to air locks and debris; and its placement produces a small but definite risk of infection. The advantage of the fiberoptic monitoring device system is ease of placement; that is, it allows direct measurement of brain tissue pressure in patients with compressed or dislocated ventricles in which placement of EVDs would be difficult,^{12,16} which is especially important in children, because ventricle size is small unless the child has hydrocephalus.⁹ Disadvantages of the device include fragility, mechanical failure, higher complexity and expense, and incompatibility with magnetic resonance units. In addition it is not possible to recalibrate this device in situ if the monitor becomes subject to drift or dampening of waveforms.^{7,12,29,40} Accidental displacement, fracture, or monitor malfunction requiring replacement has been reported in up to 13% of patients.^{16,32,33}

Several studies in adults have demonstrated that the complications of ICP monitoring are at least in part dependent on the type of monitor used.^{13,17,34} Because EVDs are larger than the fiberoptic intraparenchymal monitors, require the brain to be completely penetrated, and may require multiple passes through the brain, it is not surprising that the highest reported hemorrhagic complication rates occur when placing EVDs. The reported risk of hem-

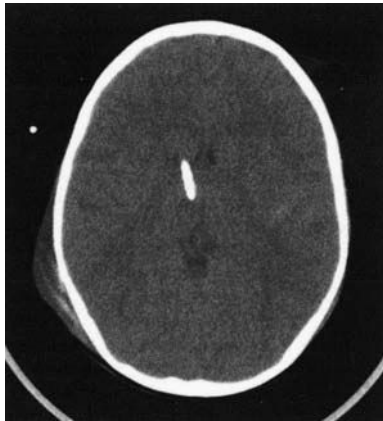


FIG. 2. Axial unenhanced head CT scan demonstrating a malpositioned EVD in the right thalamus that required reinsertion.

orrhage produced by EVDs is between 2 and 10%.^{11,27,28,41} Our hemorrhagic complication rate of 17.6% is substantially higher than those previously reported. There are at least two possible explanations for this difference. First, standardized evaluation of CT scans obtained after EVD insertion was not performed in most earlier studies,⁴¹ so small hemorrhages likely went undetected. Second, previous studies have included primarily adult patients or children with hydrocephalus, both of whom are likely to have substantially larger ventricles than children after TBI. We do not think that unusual technical issues are responsible for the increased hemorrhagic rate seen after EVD insertion. No more than three passes were performed to attempt ventricular cannulation. Furthermore, if any of our techniques in drilling or dural penetration were responsible for an increased hemorrhage rate after EVD insertion, we would also expect a higher rate of hemorrhage after fiberoptic monitor insertion, which we did not find (6.4%). Because normal coagulation studies and platelet levels were required before EVD placement, we do not think that unusual coagulopathies are responsible for the increased hemorrhagic rate seen after EVD insertion.

We and other authors recognize that the high hemorrhagic complication rates associated with these intraventricular monitors are in most cases radiographic findings without clinical significance.^{17,22} Although this is certainly true, it can often be difficult to evaluate the clinical importance of hemorrhages in children after TBI because they are often paralyzed and sedated as an early measure to reduce elevated ICP. These children may require additional diagnostic studies to monitor their evolution and therapeutic intervention to replace the monitoring device. Paralysis and sedation may cause a false reading of ICP.

The reported incidences of hemorrhagic complications from intraparenchymal monitors ranges from 0 to 10%.^{4,6,8,13,16,22,26,33,37,42,43} The three previously published studies in which only children were included reported hemorrhagic complications of 0, 0.3, and 9.7%.^{5,16,33} Our hemorrhage rate of 6.4% is similar to prior reports.

In our series, there was only one infection (1.6%) in a 12-year-old child in whom an EVD had been placed for 9 days. The low infection rate was rather surprising because we hypothesized that children with thinner scalps in the

setting of high ICP would have an increased risk for CSF leak and infection. The reported range of infection rate for EVDs varies from 0 to 45%, with authors of most large series and reviews indicating that the risk of infection is approximately 10%.^{18,20} We did not prophylactically change EVDs or administer antibiotic agents because the risk of infection does not appear to be reduced by these measures.¹⁸ We did not detect any infections in children in whom fiberoptic ICP monitors had been placed. These results are in agreement with prior reports that fiberoptic intraparenchymal monitoring is associated with a very low infection rate.^{33,38,43}

There was an 8.8% rate (six of 68) of malpositioned EVDs in our series. Although we expected this complication rate to be higher in this population because of the smaller ventricles in children, our results are within the 1.5 to 20% rates of catheter malpositioning that have been reported previously.^{13,17,30} The wide range of complication rates is likely due to varying criteria for a “malpositioned catheter,” which have been described as anything from a functioning catheter with its tip in the third ventricle to a nonfunctional catheter requiring replacement.

The largest group of patients in our study underwent dual monitoring. We did not find any difference in the risk of complications when comparing children who received both an EVD and a fiberoptic monitor with those receiving only an EVD ($p = 0.79$). Some authors have advocated the use of two monitors at the same time because dual monitoring allows simultaneous therapeutic drainage of CSF through the ventricular catheter and moment-to-moment readings of ICP from the parenchymal monitor.^{19,36} This dual method may become especially valuable when ICP is elevated enough to cause collapse of the ventricular system around a ventricular catheter, making drainage of CSF at best intermittent and readings of ICP from the catheter less reliable. Another clinical situation in which dual monitoring may be helpful is when small ventricle size precludes placement of a ventricular catheter at the time therapy is initiated. Instead, a parenchymal monitor can be inserted to begin aggressive medical management. The parenchymal monitor may allow some expansion of the ventricular system such that a safer or successful cannulation of the ventricles can occur. In this situation, the parenchymal monitor remains to guide therapy, while the ventricular catheter becomes an avenue of that therapy.¹⁹ Furthermore, the presence of two monitors allows a crosscheck of the accuracy of either monitor because differences in simultaneous recordings from intraventricular pressures and intraparenchymal monitors have been reported in some situations.³⁶

In our retrospective cohort of pediatric patients who sustained TBI, we found complication rates that were significantly different depending on the type of monitor used. Placement of an EVD was associated with a threefold increased risk of hemorrhage when compared with placement of a fiberoptic intraparenchymal monitor ($p = 0.025$). The nearly 10% rate of malpositioned catheters is a complication unique to EVDs, with half of the malpositioned catheters (three of six) leading to insertion of replacements that caused hemorrhages. Because of the small number of infections in our group of patients (one or 1.6%), no conclusions can be drawn regarding the difference in risk of infection between an EVD or fiberoptic

Complications of ICP monitoring in children

monitor. These rates must be interpreted with caution, however, because they are raw, unadjusted measurements of risk. Furthermore, it is important to note that the majority of these complications did not cause clinical sequelae. The retrospective nature of this study and the relatively small number of patients are additional limitations of this report.

Conclusions

Although ICP monitoring has played an important role in improving outcomes in patients with TBI, the procedure is not without risk. We found an overall complication rate of 28% for patients in whom EVDs had been placed and 6.5% for those in whom a fiberoptic intraparenchymal monitor was placed. There is no clear standard of care regarding whether to use an intraparenchymal fiberoptic monitor or an EVD when ICP monitoring is desired in children with TBI. Because the complication rate associated with the use of an EVD is significantly higher than that with the use of a fiberoptic intraparenchymal device in children with TBI, it seems reasonable to consider a fiberoptic device first unless there are compelling reasons for immediate ventricular drainage. Although the majority of these complications were clinically insignificant, surgeons should be aware of these different complication rates when choosing the most appropriate device for each patient.

References

1. Aucoin PJ, Kotilainen HR, Gantz NM, et al: Intracranial pressure monitors. Epidemiologic study of risk factors and infections. **Am J Med** 80:369–376, 1986
2. Bader MK, Littlejohns L, Palmer S: Ventriculostomy and intracranial pressure monitoring: in search of a 0% infection rate. **Heart Lung** 24:166–172, 1995
3. Becker DP, Miller JD, Ward JD, et al: The outcome from severe head injury with early diagnosis and intensive management. **J Neurosurg** 47:491–502, 1977
4. Bekar A, Goren S, Korfali E, et al: Complications of brain tissue pressure monitoring with a fiberoptic device. **Neurosurg Rev** 21:254–259, 1998
5. Blaha M, Lazar D, Winn RH, et al: Hemorrhagic complications of intracranial pressure monitors in children. **Pediatr Neurosurg** 39:27–31, 2003
6. Bochicchio M, Latronico N, Zappa S, et al: Bedside burr hole for intracranial pressure monitoring performed by intensive care physicians. A 5-year experience. **Intens Care Med** 22:1070–1074, 1996
7. Crutchfield JS, Narayan RK, Robertson CS, et al: Evaluation of a fiberoptic intracranial pressure monitor. **J Neurosurg** 72:482–487, 1990
8. Dacey RG Jr, Alves WM, Rimel RW, et al: Neurosurgical complications after apparently minor head injury. Assessment of risk in a series of 610 patients. **J Neurosurg** 65:203–210, 1986
9. Dean JM, McComb JG: Intracranial pressure monitoring in severe pediatric near-drowning. **Neurosurgery** 9:627–630, 1981
10. Eisenberg HM, Frankowski RF, Contant CF, et al: High-dose barbiturate control of elevated intracranial pressure in patients with severe head injury. **J Neurosurg** 69:15–23, 1988
11. Feldman Z, Narayan RK: Intracranial pressure monitoring: techniques and pitfalls, in Cooper PR (ed): **Head Injury**, ed 3. Baltimore: Williams & Wilkins, 1993, pp 247–274
12. Gambardella G, d'Avella D, Tomasello F: Monitoring of brain tissue pressure with a fiberoptic device. **Neurosurgery** 31:918–922, 1992
13. Guyot LL, Dowling C, Diaz FG, et al: Cerebral monitoring devices: analysis of complications. **Acta Neurochir Suppl** 71:47–49, 1998
14. Hader WJ, Steinbok P: The value of routine cultures of the cerebrospinal fluid in patients with external ventricular drains. **Neurosurgery** 46:1149–1155, 2000
15. Hammer GB, Andrews BT: Physiological monitoring in the pediatric intensive care unit, in Andrews BT, Hammer GB (eds): **Pediatric Neurosurgical Intensive Care**. Park Ridge, IL: American Association of Neurological Surgeons, 1997, pp 13–24
16. Jensen RL, Hahn YS, Ciro E: Risk factors of intracranial pressure monitoring in children with fiberoptic devices: a critical review. **Surg Neurol** 47:16–22, 1997
17. Khan SH, Kureshi IU, Mulgrew T, et al: Comparison of percutaneous ventriculostomies and intraparenchymal monitor: a retrospective evaluation of 156 patients. **Acta Neurochir Suppl** 71:50–52, 1998
18. Lozier AP, Sciacca RR, Romagnoli MF, et al: Ventriculostomy-related infections: a critical review of the literature. **Neurosurgery** 51:170–182, 2002
19. Luerssen TG, Wolfla CE: Pathophysiology and management of increased intracranial pressure in children, in Andrews BT, Hammer GB (eds): **Pediatric Neurosurgical Intensive Care**. Park Ridge, IL: American Association of Neurological Surgeons, 1997, pp 37–58
20. Lyke KE, Obasanjo OO, Williams MA, et al: Ventriculitis complicating use of intraventricular catheters in adult neurosurgical patients. **Clin Infect Dis** 33:2028–2033, 2001
21. Marshall LF, Smith RW, Shapiro HM: The outcome with aggressive treatment in severe head injuries. Part I: the significance of intracranial pressure monitoring. **J Neurosurg** 50:20–25, 1979
22. Martinez-Manas RM, Santamarta D, de Campos JM, et al: Camino intracranial pressure monitor: prospective study of accuracy and complications. **J Neurol Neurosurg Psychiatry** 69:82–86, 2000
23. Miller JD, Becker DP, Ward JD, et al: Significance of intracranial hypertension in severe head injury. **J Neurosurg** 47:503–516, 1977
24. Miller JD, Butterworth JF, Gudeman SK, et al: Further experience in the management of severe head injury. **J Neurosurg** 54:289–299, 1981
25. Miller JD, Sweet RC, Narayan R, et al: Early insults to the injured brain. **JAMA** 240:439–442, 1978
26. Munch E, Weigel R, Schmiedek P, et al: The Camino intracranial pressure device in clinical practice: reliability, handling characteristics and complications. **Acta Neurochir** 140:1113–1120, 1998
27. Narayan RK, Kishore PR, Becker DP, et al: Intracranial pressure: to monitor or not to monitor? A review of our experience with severe head injury. **J Neurosurg** 56:650–659, 1982
28. North B, Reilly P: Comparison among three methods of intracranial pressure recording. **Neurosurgery** 18:730–732, 1986
29. Ostrup RC, Luerssen TG, Marshall LF, et al: Continuous monitoring of intracranial pressure with a miniaturized fiberoptic device. **J Neurosurg** 67:206–209, 1987
30. Paramore CG, Turner DA: Relative risks of ventriculostomy infection and morbidity. **Acta Neurochir** 127:79–84, 1994
31. Piek J: [Complications in measuring ventricular pressure in patients with craniocerebral trauma and spontaneous intracranial hemorrhage—a prospective study.] **Zentralbl Neurochir** 55:48–53, 1994 (Ger)
32. Poca MA, Sahuquillo J, Arribas M, et al: Fiberoptic intraparenchymal brain pressure monitoring with the Camino V420 monitor: reflections on our experience in 163 severely head-injured patients. **J Neurotrauma** 19:439–448, 2002
33. Pople IK, Muhlbauer MS, Sanford RA, et al: Results and complications of intracranial pressure monitoring in 303 children. **Pediatr Neurosurg** 23:64–67, 1995

34. Rossi S, Buzzi F, Paparella A, et al: Complications and safety associated with ICP monitoring: a study of 542 patients. **Acta Neurochir Suppl** **71**:91–93, 1998
35. Saul TG, Ducker TB: Effect of intracranial pressure monitoring and aggressive treatment on mortality in severe head injury. **J Neurosurg** **56**:498–503, 1982
36. Schickner DJ, Young RF: Intracranial pressure monitoring: fiberoptic monitor compared with the ventricular catheter. **Surg Neurol** **37**:251–254, 1992
37. Schurer L, Munch E, Piepgras A, et al: Assessment of the CAMINO intracranial pressure device in clinical practice. **Acta Neurochir Suppl** **70**:296–298, 1997
38. Shapiro S, Bowman R, Callahan J, et al: The fiberoptic intraparenchymal cerebral pressure monitor in 244 patients. **Surg Neurol** **45**:278–282, 1996
39. Stenager E, Gerner-Smidt P, Kock-Jensen C: Ventriculostomy-related infections—an epidemiological study. **Acta Neurochir** **83**:20–23, 1986
40. Sundbarg G, Nordstrom CH, Messeter K, et al: A comparison of intraparenchymatous and intraventricular pressure recording in clinical practice. **J Neurosurg** **67**:841–845, 1987
41. Wiesmann M, Mayer TE: Intracranial bleeding rates associated with two methods of external ventricular drainage. **J Clin Neurosci** **8**:126–128, 2001
42. Winn HR, Dacey RG, Jane JA: Intracranial subarachnoid pressure recording: experience with 650 patients. **Surg Neurol** **8**:41–47, 1977
43. Yablon JS, Lantner HJ, McCormack TM, et al: Clinical experience with a fiberoptic intracranial pressure monitor. **J Clin Monit** **9**:171–175, 1993

Manuscript received December 19, 2003.

Accepted in final form February 24, 2004.

Address reprint requests to: Richard C. E. Anderson, M.D., The Neurological Institute and Children's Hospital of New York, 4th Floor, 710 West 168th Street, New York, New York, 10032. email: rceanderson@yahoo.com.