

International Journal of Neuropsychopharmacology (2006), 9, 221–228. Copyright © 2005 CINP
doi:10.1017/S1461145705005699 First published online 28 June 2005

Prefrontal grey-matter changes in short-term and long-term abstinent methamphetamine abusers

BRIEF REPORT

Seog Ju Kim¹, In Kyoon Lyoo^{2,4}, Jaek Hwang², Ain Chung^{2,4}, Young Hoon Sung², Jihyun Kim², Do-Hoon Kwon⁵, Kee Hyun Chang³ and Perry F. Renshaw⁶

¹ Gil Medical Center, Gachon Medical School, Department of Psychiatry, Incheon, South Korea

Seoul National University College of Medicine, Department of ² Psychiatry and ³ Radiology, Seoul, South Korea

⁴ Interdisciplinary Program for Neuroscience, Seoul National University College of Natural Science, Seoul, South Korea

⁵ Bugok National Hospital, Department of Psychiatry, Gyeongsangnam-do, South Korea

⁶ Harvard Medical School and McLean Hospital Brain Imaging Center, Belmont, MA, USA

Abstract

Authors explored grey-matter density in 29 methamphetamine abusers and 20 healthy comparison subjects using voxel-based morphometry. Grey-matter density changes and performances on the Wisconsin Card Sorting test (WCST) were also compared between 11 short-term (<6 months) and 18 long-term (≥6 months) abstinent methamphetamine abusers. Methamphetamine abusers had lower grey-matter density in the right middle frontal cortex (corrected $p < 0.05$) and more total errors in the WCST ($p < 0.01$) relative to healthy comparison subjects. Grey-matter density decrease in the right middle frontal cortex correlated with total errors in the WCST in methamphetamine abusers ($r = -0.45$). Long-term abstinent abusers had significantly less right middle frontal grey-matter density decrease ($p < 0.01$) and total errors in the WCST ($p < 0.01$) than short-term abstinent abusers, but more than the healthy comparison subjects. We report that methamphetamine abusers have prefrontal grey-matter deficit, which may, in part, recover with long-term abstinence.

Received 4 January 2005; Reviewed 23 February 2005; Revised 16 March 2005; Accepted 21 April 2005

Key words: Abstinence, executive function; frontal lobe, methamphetamine, voxel-based morphometry.

Introduction

Methamphetamine (MA) has been reported to cause long-term neuronal damage (Wilson et al., 1996). Prior studies of functional magnetic resonance imaging (fMRI) (Paulus et al., 2002), positron emission tomography (London et al., 2004; Sekine et al., 2003) and proton magnetic resonance spectroscopy (Ernst et al., 2000) have reported frontal abnormalities in recently detoxified and relatively short-term abstinent MA abusers. Cerebral perfusion defects and ischaemic lesions have also been observed in MA abusers (Chang et al., 2002; Rothrock et al., 1988; Yen et al., 1994). After long-term (>1 yr) abstinence periods, recoveries of

striatal dopamine transporter levels and thalamic glucose metabolism have been reported (Volkow et al., 2001; Wang et al., 2004).

In contrast, there have been few structural brain-imaging studies in MA abusers. A recent study using a cortical pattern-matching approach has reported grey-matter deficits in various brain regions including frontal lobes in recently detoxified MA abusers (abstinence period ≤7 d) (Thompson et al., 2004). To the best of our knowledge, there have been no prior studies investigating structural brain deficits in short-term, beyond an acute detoxification period, and long-term abstinent MA abusers.

There have been reports of grey-matter density decrease in subjects with cocaine abuse (Franklin et al., 2002; Matochik et al., 2003) and 3,4-methylenedioxy-methamphetamine (MDMA) abuse (Cowan et al., 2003). Grey-matter density changes have also been reported in subjects with various psychiatric disorders (Bell-McGinty et al., 2002; Lyoo et al., 2004). Since MA abusers commonly have comorbid psychiatric disorder and other drug abuses, we conducted a

Address for correspondence: I. K. Lyoo, M.D., Ph.D., Department of Psychiatry, Seoul National University Hospital, 28 Yongon-dong, Chongno-gu, Seoul, 110-744, South Korea.

Tel.: (82-2)-2072-3173 Fax: (82-2)-3672-0677

E-mail: inkylyoo@yahoo.com

This study was presented at the 2004 Annual Meeting of the College on Problems of Drug Dependence held at San Juan, Puerto Rico on 12–17 June 2004.

brain-imaging study in subjects with a 'sole' diagnosis of MA dependence without comorbid psychiatric disorders or lifetime exposure to most abuse-related illicit drugs.

Compared with conventional region-of-interest methods, voxel-based morphometry (VBM) can systematically assess tissue density changes of a whole brain across anatomically ill-defined areas. VBM is suitable for analyses of some psychiatric disorders, especially when only subtle structural brain changes are suspected.

The impairment of neuropsychological function has been reported in MA abusers (Kalechstein et al., 2003; Vorhees et al., 1994). The cognitive impairment in MA abusers may be related with abnormalities of frontal regions of the brain, as shown in prior functional magnetic resonance (MR) studies reporting the failure of normal prefrontal activation during a decision-making task in MA abusers (Paulus et al., 2002).

Based on prior imaging reports, we hypothesized that abstinent MA abusers would have a decreased grey-matter density in prefrontal cortices and that this decrease would correlate with a decrease in frontal executive function. We also hypothesized that, in accord with previous reports of functional recovery with long-term abstinence (Volkow et al., 2001; Wang et al., 2004), long-term abstinent MA abusers would have a lesser decrease in grey-matter density than short-term abstinent MA abusers.

Method

Subjects

Study subjects were recruited through advertisements in local newspapers in Seoul, South Korea. Inclusion criteria were (1) age 19–49 yr, (2) lifetime diagnosis of DSM-IV MA dependence, as determined by the Structured Clinical Interview for DSM-IV (SCID-IV), (3) an abstinence period longer than 4 wk, and (4) cumulative intravenous MA use over 50.0 g. Exclusion criteria were (1) current or past significant medical or neurological illness such as hypertension, hepatitis, and diabetes mellitus, (2) current or lifetime Axis I psychiatric disorders, as identified by SCID-IV, (3) antisocial or borderline personality disorders, as identified by the Personality Disorder Questionnaire – 4, (4) lifetime exposure to any other DSM-IV dependence-related or abuse-related drugs, except nicotine, caffeine, social drinking of alcohol and prescribed medications, and (5) contraindications to MR scanning.

To detect the current use of MA, cocaine, opiate, phencyclidine and marijuana, urine screening was conducted twice with the Redwood Biotech[®] (Santa

Rosa, CA, USA) urine strip at the baseline interview and ~2 h before the MR scan. A subject who drank more than 8 g of ethanol per week but not having a lifetime diagnosis of alcohol-related disorder, was defined as a social drinker. Information regarding lifetime exposure to dependence- or abuse-related drugs was obtained from the Addiction Severity Index (ASI) and interview. MA abuse characteristics including abstinence periods were assessed by structured interviews with MA abusers. The Wechsler Adult Intelligence Scale (WAIS) was performed for all study subjects. HCV Ab and HBs Ag tests were performed to exclude the presence of hepatitis C and hepatitis B. The screen for HIV-positive subjects was not conducted for ethical and legal issues. However, the prevalence of HIV infection in Korea is lower than in other countries (Kim et al., 2003). Furthermore, only 1.1% of HIV transmissions were due to intravenous drug injection in Korea, probably because disposable syringes can be easily purchased in pharmacies (Kim et al., 2003).

Screening procedures were as follows. A total of 165 subjects who potentially met inclusion criteria were referred. Of these, subjects with prior exposure history (not mutually exclusive) of inhalant ($n=54$), marijuana ($n=38$), MDMA ($n=5$), and cocaine ($n=1$), subjects with current or past history of alcohol abuse or dependence ($n=46$), subjects with current or lifetime psychiatric disorders [major depressive disorder ($n=32$), schizophrenia and delusional disorder ($n=6$), bipolar I and II ($n=7$), panic disorder ($n=4$), generalized anxiety disorder ($n=4$), and antisocial personality disorders ($n=7$)], and subjects with hypertension ($n=25$), hepatitis ($n=4$), and diabetes mellitus ($n=34$), were excluded from the brain-imaging portion of the study. No study subjects had current or past history of attention deficit hyperactivity disorder (ADHD), as assessed by interviews and school reports. Finally, 29 of the 31 remaining MA abusers completed an MR imaging study. Twenty healthy comparison subjects also participated in the current study. Healthy comparison subjects were subjected to the same study protocol as MA abusers. The study protocol was approved by the Institutional Review Boards at Seoul National University Hospital and McLean Hospital, Massachusetts, USA. After a complete description of the study to the subjects, written informed consent was obtained. All study procedures including MR scan and VBM analysis were conducted in South Korea from 2002 to 2004.

There were no significant differences in age, gender composition, prevalence of social alcohol drinking, handedness, parents' socioeconomic status or IQ

Table 1. Demographic characteristics of MA abusers and healthy comparison subjects

	Long-term abstinent MA abusers (<i>n</i> = 18) Mean ± s.d. <i>n</i> (%)	Short-term abstinent MA abusers (<i>n</i> = 11) Mean ± s.d. <i>n</i> (%)	All MA abusers (long-term + short-term) (<i>n</i> = 29) Mean ± s.d. <i>n</i> (%)	Healthy comparison subjects (<i>n</i> = 20) Mean ± s.d. <i>n</i> (%)
Demographic variables				
Age (yr)	35.6 ± 5.2	37.9 ± 6.0	36.5 ± 5.5	33.2 ± 6.5
Gender (male)	16 (88.9%)	11 (100.0%)	27 (93.1%)	15 (75.0%)
Handedness (right)	15 (83.3%)	11 (100.0%)	26 (90.0%)	17 (85.0%)
Parents' SES				
High	5 (27.8%)	1 (9.1%)	6 (20.7%)	6 (30.0%)
Middle	6 (33.3%)	6 (54.5%)	12 (41.4%)	10 (50.0%)
Low	7 (38.9%)	4 (36.4%)	11 (37.9%)	4 (20.0%)
Educational level (yr) ^a	11.1 ± 1.4	10.1 ± 1.9	10.7 ± 1.6 ^a	15.1 ± 1.7 ^a
Social alcohol drinking	13 (72.2%)	8 (72.7%)	21 (72.4%)	14 (70.0%)
Current smoking ^b	14 (77.8%)	8 (72.7%)	22 (75.9%) ^b	7 (35.0%) ^b
MA use characteristics				
Intravenous use	18 (100.0%)	11 (100.0%)	29 (100.0%)	–
Total cumulative dose (g)	290.7 ± 277.8	252.7 ± 153.4	276.3 ± 235.8	–
Average daily dose (g)	0.56 ± 0.47	0.71 ± 0.41	0.62 ± 0.44	–
Age of initial use (yr)	24.0 ± 5.8	21.3 ± 4.2	23.1 ± 5.4	–
Duration of use (months)	67.6 ± 53.1	58.4 ± 22.6	64.2 ± 44.0	–
Abstinence periods (months) ^c	30.6 ± 39.2 ^c	2.6 ± 1.6 ^c	20.0 ± 33.5	–

MA, methamphetamine; SES, socioeconomic status.

^aSignificant difference between MA abusers and healthy comparison subjects (independent *t* test, *t* = 10.1, d.f. = 47, *p* < 0.001).

^bSignificant difference between MA abusers and healthy comparison subjects (Fisher's exact test, *p* < 0.01).

^cSignificant difference between long-term abstinent and short-term abstinent MA abusers (independent *t* test, *t* = 2.4, d.f. = 27, *p* < 0.05).

between 29 abstinent MA abusers (27 men, 2 women; 36.5 ± 5.5 yr) and 20 healthy comparison subjects (15 men, 5 women; 33.2 ± 6.5 yr). Prevalence of the current cigarette smoking was significantly higher in MA abusers relative to healthy comparison subjects (Fisher's exact test, *p* < 0.01). MA abusers had a lower educational level than healthy comparison subjects (*t* = 10.1, d.f. = 47, *p* < 0.01). Detailed clinical and demographic information of subjects are presented in Table 1.

Depending on the abstinence period, MA abusers were categorized into short-term (<6 months) abstinent abusers (11 men, 37.9 ± 6.0 yr) and long-term (≥6 months) abstinent abusers (16 men, 2 women; 35.6 ± 5.2 yr). All MA abusers administered MA intravenously. There were no significant differences in age, gender composition, handedness, parents' socioeconomic status, prevalence of social alcohol drinking or smoking, educational levels, age of initial MA use, duration of MA use, total cumulative and average daily dose between two MA abusers groups (Table 1).

MR image acquisition

Brain MR imaging was performed using a 3.0 T GE whole-body imaging system (GE VH/i, Milwaukee, WI, USA). A three-dimensional spoiled gradient echo-pulse sequence was used to produce 248 0.7-mm-thick contiguous sagittal images [TE = 1.4 ms, TR = 5.7 ms, TI = 400 ms, 256 × 256 matrix; FOV = 22 cm, flip angle = 20°, 1 NEX (number of excitations)]. In IR-prepared 3D spoiled gradient (SPGR) sequence, in- and through-plane spatial resolution matrix zero-fill interpolation processing (ZIP) was used to reconstruct images in 512 × 512 format and with a slice thickness decreased by half. Axial T2 weighted images (TE = 118 ms, TR = 3500 ms, 256 × 192 matrix; FOV = 22 cm, flip angle = 90°, 3 NEX, 5-mm-thick slices, 1.5 mm skip) as well as fluid-attenuated inversion recovery (FLAIR) axial images (TE = 145 ms, TR = 9900 ms, TI = 2250 ms, 256 × 192 matrix; FOV = 22 cm, flip angle = 90°, 1 NEX, 5-mm-thick slices, 1.5 mm skip) were obtained to screen for brain structural

abnormalities by an experienced neuroradiologist (K.H.C.). Subjects were asked to refrain from over-the-counter (OTC) medications including those for the common cold and dyspepsia for 2 d before scanning and any herbal medications for 7 d before scanning. No study subjects were medicated at the time of MR scan. No brain structural abnormalities were noted for either group of subjects.

Voxel-based morphometry

The 248 contiguous sagittal images were transferred to a Dell 530 PC workstation and interpolated to 0.104 mm^3 ($0.47 \times 0.47 \times 0.47$) voxels, using Analyze 5.0 software (Rochester, MN, USA). After inspecting individual MR volume, image non-uniformity was corrected using a spatial filter, as described in our previous study of VBM (Lyo et al., 2004).

Each MR volume was transformed and co-registered into a standardized proportional stereotaxic space using the Montreal Neurological Institute 152 brain-averaged space (Ashburner and Friston, 1999) [Statistical Parametric Mapping 99 (SPM99), London, UK]. Spatial normalization consists of 12 parameter-affined transformations and nonlinear warping using basis functions ($7 \times 8 \times 7$). Resulting images had isotropic voxels of 1.0 mm. Grey matter, white matter and CSF components were segmented from spatially normalized images using a modified mixture model cluster analysis technique. Segmented images were smoothed by convolving with a 12-mm full width at half-maximum isotropic Gaussian kernel.

Neurocognitive tests

The Wisconsin Card Sorting test (WCST) assesses executive function, the ability to form abstract concepts, to shift and maintain set, and to utilize feedback (Heaton et al., 1993). The WCST was conducted to examine the frontal executive function. The numbers of perseveration errors, non-perseveration errors, and total errors (perseveration errors + non-perseveration errors) were used for the statistical analysis. The Trail-making test (TMT) and Stroop tests were also conducted for all study subjects.

Statistical analysis

Smoothed images were compared between diagnostic groups using an ANCOVA model controlling for possible effects of age and sex. Significant difference was estimated using the theory of random Gaussian fields (Friston et al., 1996). Parameters to define regions of significant differences included a p value of

0.05 (corrected for multiple comparisons), height threshold $t=5.27$, and an extent threshold of 400 voxels (equivalent to 50 voxels when using voxels of 2.0 mm). For the voxel cluster with significant between-group difference (corrected $p < 0.05$), normalized values for grey-matter density were calculated using a volume of interest (VOI) module of SPM. These values were used in further analysis in comparing grey-matter density between groups and correlating with WCST scores.

In addition, differences at the uncorrected p level of 0.001 were also presented, as this level has also been considered as a significant threshold for statistical difference maps when there are a-priori hypotheses regarding the location of findings (Ashburner et al., 2003).

Group differences in variables involving continuous data were computed using independent t tests and ANOVAs with post-hoc tests. Between-group comparisons involving categorical data were assessed using Fisher's exact test for $2 \times k$ table. Associations between continuous variables were calculated using Pearson's correlation analysis. Statistical significance was defined at α level of 0.05 using two-tailed tests. STATA 7.0 for Windows (Stata Corp., College Station, TX, USA) was used for computations.

Results

After correction for multiple comparison (corrected $p < 0.05$, $t > 5.27$), there was a grey-matter density decrease in the right middle frontal gyrus in MA abusers [Talairach coordinates (x, y, z): 29, 52, 18; Brodmann area (BA) 10, 10.3% decrease] (Figure 1). When uncorrected p values were used ($p < 0.001$), grey-matter density decreases in MA abusers were observed in three other brain areas; left medial frontal gyrus (BA 10), right middle frontal gyrus (BA 6), and right post-central gyrus (BA 43) (Figure 1).

For the grey-matter density value in the area of significant difference at corrected $p < 0.05$ (i.e. right middle frontal gyrus, BA 10), there were significant group differences between three groups (ANOVA: $F = 27.0$, d.f. = 2, 46, $p < 0.01$; short-term abstinent MA abusers < long-term abstinent MA abusers < healthy comparison subjects, by post-hoc tests) (Figure 2).

There were no significant differences in white-matter densities between MA abusers and healthy comparison subjects at corrected $p < 0.05$ or uncorrected $p < 0.001$.

This right middle frontal grey-matter density negatively correlated with the number of total and perseveration errors in the WCST in MA abusers ($r = -0.45$,

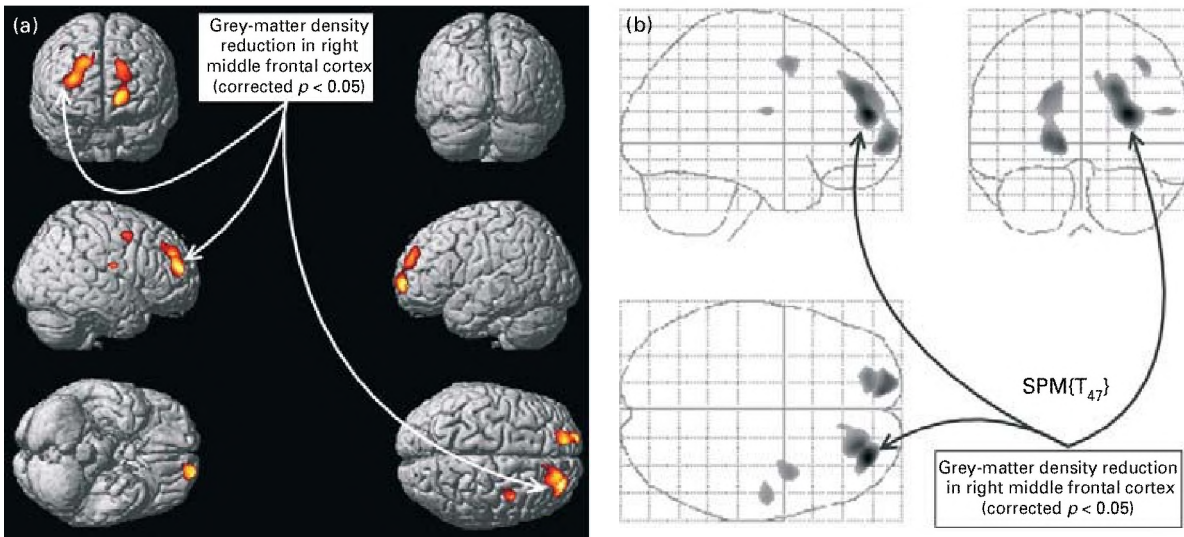


Figure 1. Location of grey-matter density decrease in abstinent methamphetamine (MA) abusers. Locations of grey-matter density decrease in MA abusers is depicted in whole brain rendering (a) and glass brain projection (b). Locations of grey-matter density decrease in MA abusers ($p < 0.05$ corrected for multiple comparisons) are marked by arrows. Grey-matter density in the right middle frontal gyrus [Brodmann area (BA 10)] was decreased in MA abusers relative to healthy comparison subjects. Grey-matter density decrease in MA abusers, to a lesser degree (uncorrected $p < 0.001$), were observed in three other areas; left medial frontal gyrus (BA 10), right middle frontal gyrus (BA 6), and right postcentral gyrus (BA 43) in MA abusers relative to healthy comparison subjects. Locations are according to nearest grey-matter location of Talairach coordinates.

$n = 29, p = 0.01; r = -0.47, n = 29, p < 0.01$ respectively). There was no significant correlation between the right middle frontal grey-matter density and the number of non-persistence errors in the WCST in MA abusers ($r = -0.31, n = 29, p = 0.10$).

MA abusers had significantly more total, perseveration and non-persistence errors in the WCST relative to healthy comparison subjects (independent t test: $t = 3.22, d.f. = 47, p < 0.01; t = 2.87, d.f. = 47, p < 0.01; t = 2.48, d.f. = 47, p = 0.02$ respectively). There were also significant group differences between the three groups in the number of total errors (ANOVA: $F = 9.50, d.f. = 2, 46, p < 0.01$; short-term abstinent MA abusers > long-term MA abstinent abusers > healthy comparison subjects, by post-hoc tests), perseveration errors ($F = 4.91, d.f. = 2, 46, p = 0.01$; short-term abstinent MA abusers > long-term abstinent MA abusers > healthy comparison subjects), and non-persistence errors ($F = 8.47, d.f. = 2, 46, p < 0.01$; short-term MA abstinent abusers > healthy comparison subjects) in the WCST. There were no significant differences between MA abusers and healthy comparison subjects in the TMT or Stroop test.

The influences by potential confounders including age, gender, educational level, IQ, and smoking were tested in additional analyses. When analyses were confined to men (11 short-term abstinent abusers, 16

long-term abstinent abusers, 15 healthy comparison subjects), similar results were produced. Due to a small sample size (2 MA abusers vs. 5 healthy comparison subjects), the analysis was not repeated for women. There were no significant differences in the right middle frontal grey-matter density or WCST errors between MA abusers who were smokers ($n = 22$) and those who were not ($n = 7$), or between smokers ($n = 7$) and non-smokers ($n = 13$) in the healthy comparison group. After controlling for educational levels, age, or IQ using the ANCOVA model, between-group differences remained similar in the right middle frontal grey-matter density and WCST errors.

Discussion

We report a prefrontal grey-matter density decrease and impairment in frontal executive function in MA abusers, with different levels of deficits by the abstinence period. To the best of our knowledge, the current report is the first VBM study in MA abusers and the first structural brain-imaging study comparing short-term and long-term abstinent MA abusers, albeit a limited power due to a small sample size.

We also made efforts to recruit MA abusers without comorbid drug exposures or psychiatric disorders by strict screening procedures, as our main aim was to

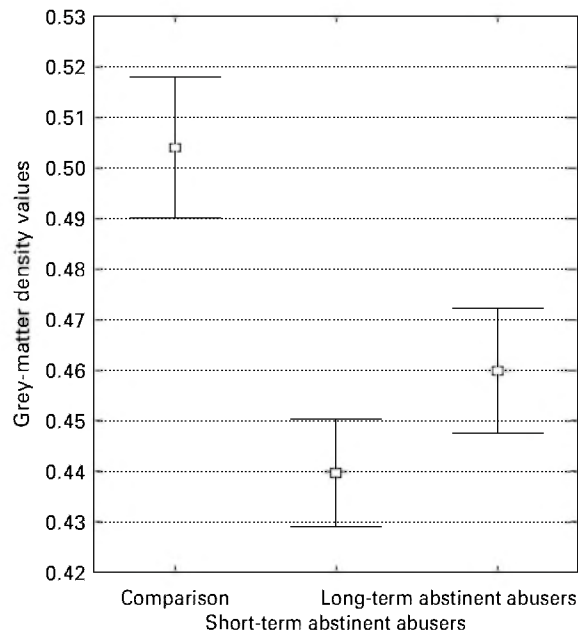


Figure 2. Differences of grey-matter density between healthy comparison subjects, short-term abstinent methamphetamine (MA) abusers, and long-term abstinent MA abusers. Significant group differences in grey-matter density in right middle frontal gyrus [Talairach coordinates (x, y, z): 29, 52, 18; Brodmann area (BA) 10] between long-term abstinent MA abusers ($n=18$), short-term abstinent MA abusers ($n=11$), and healthy comparison subjects ($n=20$) (ANOVA: $F=27.0$, d.f. = 2, 46, $p < 0.01$; short-term abstinent MA abusers < long-term abstinent MA abusers < healthy comparison subjects, by post-hoc tests). □, Mean; ▭, 95% confidence interval.

investigate the effects of MA on the brain structures. All MA subjects in our study were (1) without comorbid Axis I or II disorders for which structural brain deficits have been reported and (2) without lifetime exposure to any other DSM-IV dependence- or abuse-related drugs, except nicotine, caffeine, alcohol drinking and prescribed medications. As MA is much more easily available than other illicit drugs in Korea, MA abuse or dependence comprises 74.2% of all illicit drug-related prosecutions (Department of Justice, South Korea). Consequently, subjects with a 'sole' diagnosis of MA dependence were successfully recruited in the present study.

Grey-matter density decrease in MA abusers might be related to microscopic neuronal injury by MA-induced ischaemic changes or dopaminergic neurotoxicity. Lesser degree of grey-matter density decrease in long-term abstinent MA abusers, compared to short-term abstinent MA abusers, might suggest the

recovery of MA-induced ischaemic or neurotoxic injury after long-term abstinence periods.

The dorsolateral prefrontal cortex, the area of focal grey-matter deficit in our study, is associated with the frontal executive function. Consequently, the current finding of decreased prefrontal grey-matter density may underlie the impairment in frontal executive function in MA abusers. Our findings are also in line with a prior fMRI report that MA abusers had lower activation of dorsolateral prefrontal cortex during decision-making tasks (Paulus et al., 2002). Decreased prefrontal grey-matter density in our MA abusers also accords with prior reports of lower dopamine transporter levels (Sekine et al., 2003), altered glucose metabolism (London et al., 2004), and decreased *N*-acetyl aspartate levels (Ernst et al., 2000) in frontal brain regions.

There has been a prior report that MA subjects had impairment in non-verbal and abstract thinking ability rather than verbal function (Simon et al., 2000). Since the right frontal cortex governs non-verbal/visuospatial memory and abstraction abilities (Roland, 1993), the current finding of right-side predominance in grey-matter density decrease in MA abusers is in line with this finding.

In the present study, long-term abstinent MA abusers had a lesser prefrontal grey-matter density decrease and lesser impairment in the frontal executive function compared to short-term abstinent MA abusers. Considering that there were no significant differences in clinical and demographic variables between the two MA abuser groups, our findings suggest that the recovery in grey-matter density decrease may occur with a long-term abstinence. This finding echoes recent reports that lower striatal dopamine transporter level and thalamic glucose metabolism recover after abstinence periods of 12–17 months (Volkow et al., 2001; Wang et al., 2004). Future prospective studies with repeated measurements in the same cohort will help assess the degree of recovery in grey-matter density deficits with long-term abstinence.

Another possible explanation can be suggested for differences of frontal grey-matter density between short-term and long-term MA abuser groups. MA abusers with higher frontal grey-matter density may have the preceding (i.e. before MA exposure) constitution more capable of maintaining abstinence than MA abusers with the lower frontal grey-matter density. However, there were no significant differences between two MA groups in cumulative doses, average daily doses, and durations of MA abuse, which may be closely related with abstinence and relapse of MA use. Therefore, the recovery of grey-matter density with

long-term abstinence is a more plausible explanation for differences between the two MA groups than differences in the preceding constitution to maintain abstinence.

Both frontal grey-matter density and frontal executive function in long-term abstinent MA abusers were lower than those of healthy comparison subjects. These findings suggest that MA abusers may continue to have remnant structural deficits (i.e. decreased prefrontal grey-matter density) and impaired frontal executive function (i.e. more WCST errors) relative to healthy comparison subjects, even after a potential recovery with long-term abstinence.

A limitation of the current study is the small sample size, especially when long-term and short-term abstinent MA abusers were compared. However, differences between long-term and short-term abstinent MA abusers were found in analyses of VBM as well as the WCST. In addition, similar findings existed even after controlling potential confounding factors and at the conservative SPM threshold. Therefore, despite the small sample size, our findings may support the existence of abstinence effects on the frontal grey-matter density and the frontal executive function in MA abusers. However, future studies with a larger sample size would be necessary to confirm our findings. Although potential gender difference in neurotoxicity of MA have been suggested (Chang et al., 2002; Kim et al., 2005), this difference could not be tested due to the small number of female subjects. Findings from male MA abusers ($n=27$) and male comparison subjects ($n=15$) were similar to those when all genders were included. A future study is recommended to evaluate the grey-matter density changes in female MA abusers.

Reliability of the information regarding the past history of abstinence can be an issue as abstinence periods were defined by interviews with MA abusers. However, MA abusers in the current study did not receive any legal or financial benefits by not giving accurate information. To overcome this potential reliability issue, future prospective studies with repeated urine screening tests may be necessary.

A higher prevalence of smoking in MA abusers may have influenced current findings, as prefrontal grey-matter density decrease has been reported in smokers (Brody et al., 2004). Although the prevalence of smoking was higher in MA abusers than in healthy comparison subjects, there was no significant difference in the prevalence of smoking between long-term and short-term abstinent MA abusers. In the additional exploratory analysis, there were no significant differences of grey-matter density between smokers and

non-smokers within the MA abuser group or within the healthy comparison group.

In conclusion, our findings suggest that abstinent MA abusers would have prefrontal grey-matter deficits and impaired frontal executive function. Findings of the current study also suggest that these frontal abnormalities of MA abusers may recover with long-term abstinence, although not to the level of healthy comparison subjects.

Acknowledgements

This work was supported, in part, by grants from the National Institute on Drug Abuse (DA09448-09S1), Stanley Medical Research Institute, NARSAD and the Harvard-MIT CIIP, National Institute on Drug Abuse (DA09448) (I.K.L and P.F.R.), the National Institute of Mental Health (MH58681) (P.F.R.), and Seoul National University Hospital (21-2004-008) (I.K.L.).

Statement of Interest

None.

References

- Ashburner J, Csernansky JG, Davatzikos C, Fox NC, Frisoni GB, Thompson PM (2003). Computer-assisted imaging to assess brain structure in healthy and diseased brains. *Lancet Neurology* 2, 79–88.
- Ashburner J, Friston KJ (1999). Nonlinear spatial normalization using basis functions. *Human Brain Mapping* 7, 254–266.
- Bell-McGinty S, Butters MA, Meltzer CC, Greer PJ, Reynolds 3rd, CF, Becker JT (2002). Brain morphometric abnormalities in geriatric depression: long-term neurobiological effects of illness duration. *American Journal of Psychiatry* 159, 1424–1427.
- Brody AL, Mandelkern MA, Jarvik ME, Lee GS, Smith EC, Huang JC, Bota RG, Bartzokis G, London ED (2004). Differences between smokers and nonsmokers in regional gray matter volumes and densities. *Biological Psychiatry* 55, 77–84.
- Chang L, Ernst T, Speck O, Patel H, DeSilva M, Leonido-Yee M, Miller EN (2002). Perfusion MRI and computerized cognitive test abnormalities in abstinent methamphetamine users. *Psychiatry Research* 114, 65–79.
- Cowan RL, Lyoo IK, Sung SM, Ahn KH, Kim MJ, Hwang J, Haga E, Vimal RL, Lukas SE, Renshaw PF (2003). Reduced cortical gray matter density in human MDMA (Ecstasy) users: a voxel-based morphometry study. *Drug and Alcohol Dependence* 72, 225–235.
- Ernst T, Chang L, Leonido-Yee M, Speck O (2000). Evidence for long-term neurotoxicity associated with methamphetamine abuse: a ¹H MRS study. *Neurology* 54, 1344–1349.

- Franklin TR, Acton PD, Maldjian JA, Gray JD, Croft JR, Dackis CA, O'Brien CP, Childress AR (2002). Decreased gray matter concentration in the insular, orbitofrontal, cingulate, and temporal cortices of cocaine patients. *Biological Psychiatry* 51, 134–142.
- Friston KJ, Holmes A, Poline JB, Price CJ, Frith CD (1996). Detecting activations in PET and fMRI: levels of inference and power. *Neuroimage* 4, 223–235.
- Heaton RK, Chelune GJ, Kay KK, Curtiss G (1993). *Wisconsin Card Sorting Test Manual: revised and expanded*. Los Angeles, CA: Western Psychological Services.
- Kalechstein AD, Newton TF, Green M (2003). Methamphetamine dependence is associated with neurocognitive impairment in the initial phases of abstinence. *Journal of Neuropsychiatry and Clinical Neuroscience* 15, 215–220.
- Kim JM, Cho GJ, Hong SK, Chang KH, Chung JS, Choi YH, Song YG, Huh A, Yeom JS, Lee KS, Choi JY (2003). Epidemiology and clinical features of HIV infection/AIDS in Korea. *Yonsei Medical Journal* 44, 363–370.
- Kim SJ, Lyoo IK, Hwang J, Sung YH, Lee HY, Lee DS, Jeong DU, Renshaw PF (2005). Frontal glucose hypometabolism in abstinent methamphetamine users. *Neuropsychopharmacology*. Published online: 23 February 2005. doi:10.1038/sj.npp.1300699.
- London ED, Simon SL, Berman SM, Mandelkern MA, Lichtman AM, Bramen J, Shinn AK, Miotto K, Learn J, Dong Y, Matochik JA, Kurian V, Newton T, Woods R, Rawson R, Ling W (2004). Mood disturbances and regional cerebral metabolic abnormalities in recently abstinent methamphetamine abusers. *Archives of General Psychiatry* 61, 73–84.
- Lyoo IK, Kim MJ, Stoll AL, Demopulos CM, Parow AM, Dager SR, Friedman SD, Dunner DL, Renshaw PF (2004). Frontal lobe gray matter density decreases in bipolar I disorder. *Biological Psychiatry* 55, 648–651.
- Matochik JA, London ED, Eldreth DA, Cadet JL, Bolla KI (2003). Frontal cortical tissue composition in abstinent cocaine abusers: a magnetic resonance imaging study. *Neuroimage* 19, 1095–1102.
- Paulus MP, Hozack NE, Zauscher BE, Frank L, Brown GG, Braff DL, Schuckit MA (2002). Behavioral and functional neuroimaging evidence for prefrontal dysfunction in methamphetamine-dependent subjects. *Neuropsychopharmacology* 26, 53–63.
- Roland PE (1993). *Brain Activation*. New York: Wiley-Liss.
- Rothrock JF, Rubenstein R, Lyden PD (1988). Ischemic stroke associated with methamphetamine inhalation. *Neurology* 38, 589–592.
- Sekine Y, Minabe Y, Ouchi Y, Takei N, Iyo M, Nakamura K, Suzuki K, Tsukada H, Okada H, Yoshikawa E, Futatsubashi M, Mori N (2003). Association of dopamine transporter loss in the orbitofrontal and dorsolateral prefrontal cortices with methamphetamine-related psychiatric symptoms. *American Journal of Psychiatry* 160, 1699–1701.
- Simon SL, Domier C, Carnell J, Brethen P, Rawson R, Ling W (2000). Cognitive impairment in individuals currently using methamphetamine. *American Journal of Addiction* 9, 222–231.
- Thompson PM, Hayashi KM, Simon SL, Geaga JA, Hong MS, Sui Y, Lee JY, Toga AW, Ling W, London ED (2004). Structural abnormalities in the brains of human subjects who use methamphetamine. *Journal of Neuroscience* 24, 6028–6036.
- Volkow ND, Chang L, Wang GJ, Fowler JS, Franceschi D, Sedler M, Gatley SJ, Miller E, Hitzemann R, Ding YS, Logan J (2001). Loss of dopamine transporters in methamphetamine abusers recovers with protracted abstinence. *Journal of Neuroscience* 21, 9414–9418.
- Vorhees CV, Ahrens KG, Acuff-Smith KD, Schilling MA, Fisher JE (1994). Methamphetamine exposure during early postnatal development in rats: I. Acoustic startle augmentation and spatial learning deficits. *Psychopharmacology (Berlin)* 114, 392–401.
- Wang GJ, Volkow ND, Chang L, Miller E, Sedler M, Hitzemann R, Zhu W, Logan J, Ma Y, Fowler JS (2004). Partial recovery of brain metabolism in methamphetamine abusers after protracted abstinence. *American Journal of Psychiatry* 161, 242–248.
- Wilson JM, Kalasinsky KS, Levey AI, Bergeron C, Reiber G, Anthony RM, Schmunk GA, Shannak K, Haycock JW, Kish SJ (1996). Striatal dopamine nerve terminal markers in human, chronic methamphetamine users. *Nature Medicine* 2, 699–703.
- Yen DJ, Wang SJ, Ju TH, Chen CC, Liao KK, Fuh JL, Hu HH (1994). Stroke associated with methamphetamine inhalation. *European Neurology* 34, 16–22.