

J Neurosurg 95:704–709, 2001

Compressive optic neuropathy caused by renal osteodystrophy

Case report

**RICHARD H. SCHMIDT, M.D., PH.D., LISA A. RIETZ, M.D.,
BHUPENDRA C. K. PATEL, M.D., F.R.C.S., F.R.C.OPHTH., ANNE G. OSBORNE, M.D.,
DAVID PRATT, M.D., AND KATHLEEN B. DIGRE, M.D.**

Departments of Neurology, Ophthalmic Plastic and Reconstructive Surgery, Neuroradiology, and Neurosurgery, University of Utah Health Sciences Center, Salt Lake City, Utah

✓ Compressive optic neuropathy with acute or chronic vision loss has been associated with various skull base tumors, aneurysms, Graves disease, trauma, and, less commonly, fibrous dysplasia and osteopetrosis. The authors present a case of acute visual deterioration in a 25-year-old woman who had massive calvarial hypertrophy with optic canal stenosis secondary to renal osteodystrophy (uremic leontiasis ossea [ULO]: bighead disease). Significant visual field restoration was achieved with high-dose corticosteroids followed by optic nerve decompression. This is the first case report of cranial neuropathy associated with ULO.

KEY WORDS • optic neuropathy • optic nerve decompression • renal osteodystrophy

OPTIC nerve compression is a well-known cause of both acute and chronic visual loss. Common causes include tumors such as pituitary macroadenomas, meningiomas, ON gliomas, and metastases, and trauma to the frontal skull base involving the optic canal. Other causes include aneurysms and hemorrhage, like that seen in sickle cell disease.^{6,16,17,20} Graves disease may compromise the ON at the orbital apex, secondary to hypertrophy of the orbital muscles.³ Less commonly, ON compression may be caused by osseous tumors of the sphenoid bone or orbit.^{16,17} Osteopetrosis and fibrous dysplasia of the central cranial base are well-known but uncommon causes of chronic, and more rarely, acute vision loss.^{1,4,11} Compressive optic neuropathy may respond to ON decompression, especially if the vision loss is incomplete.

We present an unusual case of acute optic neuropathy in which the patient had massive calvarial hypertrophy caused by renal hyperparathyroidism. This hypertrophic condition of the facial bones has recently been described in the radiological literature as ULO, or “bighead” disease.¹⁵ It has not been associated previously with the development of cranial neuropathy.

Case Report

History. This 25-year-old woman with dialysis-dependent renal failure was referred to the neuro-ophthalmology clinic for evaluation of acute, painless vision loss in the right eye. Vision loss began 6 days before presentation, but she did not seek immediate clinical attention.

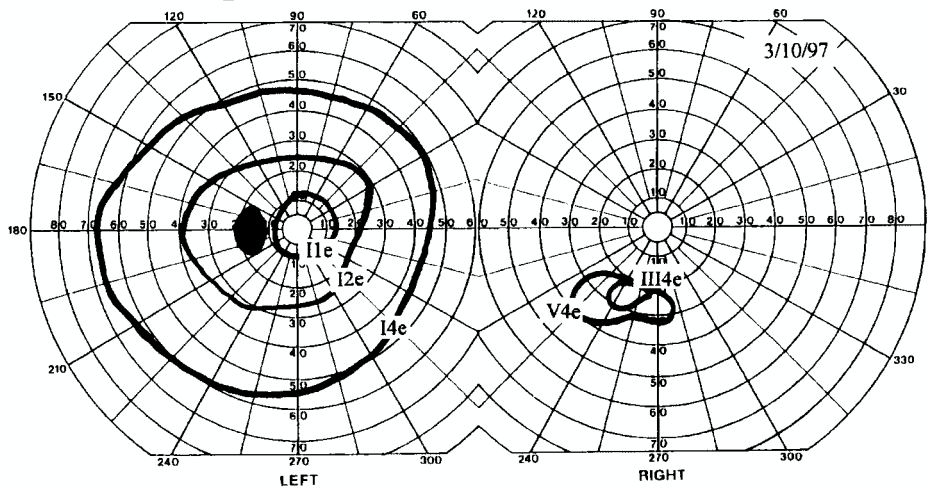
Abbreviations used in this paper: MR = magnetic resonance; OD = right eye; ON = optic nerve; OphA = ophthalmic artery; OS = left eye; RAPD = relative afferent pupillary defect; ULO = uremic leontiasis ossea.

Her medical history was significant for congenital bilateral renal dysplasia and failed kidney transplants at 11 and 16 years of age. She started hemodialysis 6 months before presentation after suffering multiple complications from peritoneal dialysis. She had required a parathyroidectomy at the age of 10 years for secondary hyperparathyroidism. During this procedure, she had suffered a right frontal watershed infarction, with subsequent, well-controlled seizures. She has chronic anemia, hypertension, and surgically corrected bone/joint growth abnormalities as a result of her renal disease. She also suffers from asymptomatic aortic insufficiency, chronic daily headache, and frequent bouts of sinusitis.

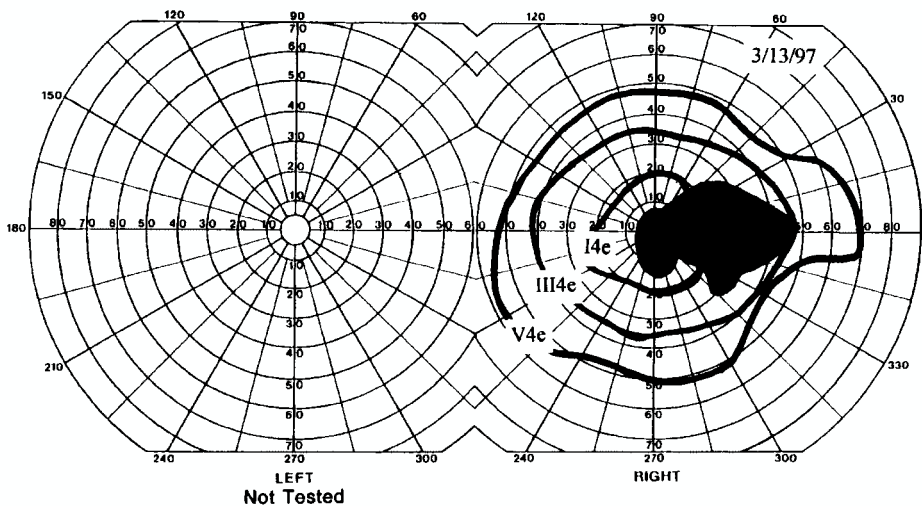
Examination. On general examination, the patient was found to be of small stature (5 ft 1 in, 45 kg), with a broad, rounded head and small facial features. Neuroophthalmological examination at presentation revealed visual acuity of 20/400 with no color vision OD, and 20/15 with normal color vision OS. Pupils were reactive, with a profound right RAPD of greater than 2.4 log U. Her right optic disc was severely swollen, with retinal hemorrhages and venous congestion; her left was elevated, with no venous pulsations. Visual fields on the right revealed a large central scotoma to confrontation, with only a small area in the inferonasal quadrant in which she could count fingers. Extraocular movements and all other cranial nerve functions were normal. Results on the remainder of her ophthalmological examination were normal. The neurological examination was notable only for trace left proximal lower-extremity weakness and hyperreflexia.

The small area of limited acuity in the inferonasal quadrant OD was confirmed on Goldmann visual fields (Fig. 1 upper). Ophthalmological color Doppler ultrasonography examination revealed significantly diminished blood flow in the right OphA. Retinal fluorescein angiography

Hospital Day #1, Initial Presentation



Hospital Day #4, After Steroids



Follow Up at One Year

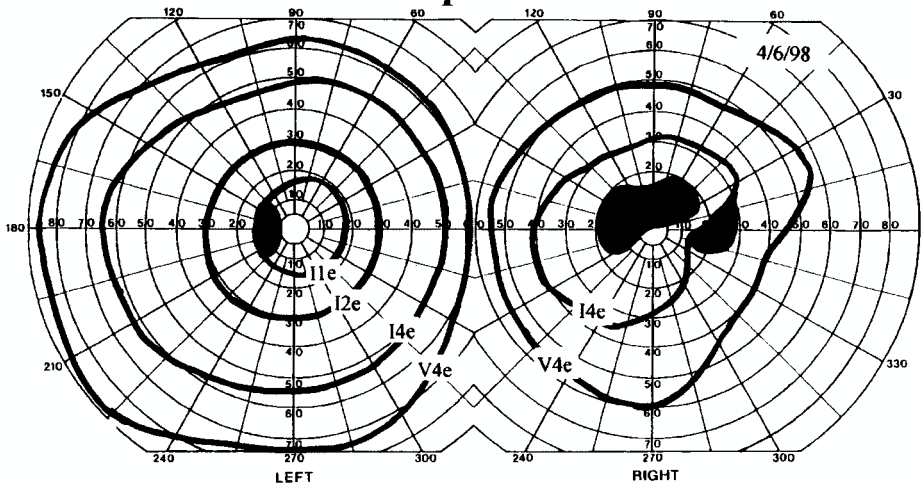


FIG. 1. Goldmann visual fields at presentation (*upper*), after 3 days of treatment with high-dose methylprednisolone (*center*), and 1 year (*lower*) after ON decompression. The initially small area of preserved vision enlarged significantly after treatment with steroid drugs and remained improved after surgical treatment 1 year later.

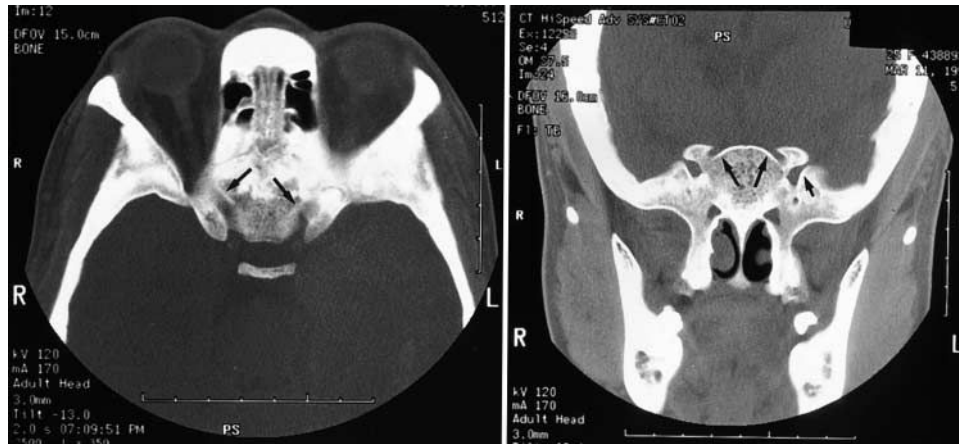

FIG. 2. Axial (left) and coronal (right) computerized tomography scans of the orbits revealing bone thickening and overgrowth that was narrowing the optic canals (large arrows) and superior orbital fissures (small arrows) bilaterally. The sinus mucosa is thickened.

revealed normal flow times but significant capillary leakage in the right optic disc.

Neuroradiological Studies. Computerized tomography scanning (Fig. 2) revealed diffuse hyperostosis resulting in a thickened calvaria that measured up to 3 cm thick in some areas; only the bisquamous occipital bone was spared. All foramina were significantly narrowed, and the right optic canal in particular was narrowed to less than 2 mm. Sinus spaces were nearly obliterated, and sinus mucous membranes and meninges were diffusely thickened. Sagittal MR imaging (Fig. 3) revealed multiple small, circumscribed lesions within the calvaria that were consistent with brown tumors, characteristic of the hypererythropoiesis of chronic anemia. Also observed on MR imaging were abnormal vascular flow voids in the anterior intracranial region, and MR angiography revealed a moyamoya pattern of collateral vascularization. Conventional angiography demonstrated occlusion of the supraclinoid segment

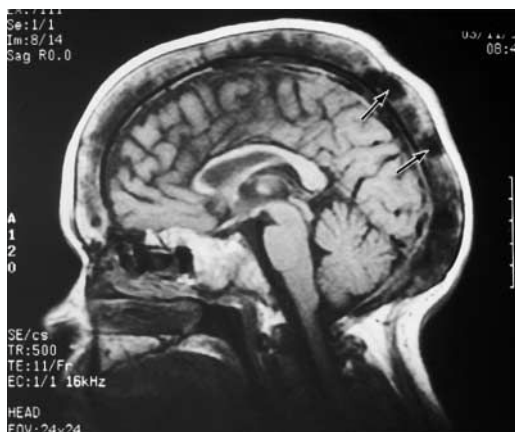

FIG. 3. Sagittal T₁-weighted MR image revealing diffuse calvarial thickening. The hypointense areas in the marrow spaces represent areas of hypererythropoiesis or so-called brown tumors (arrows).

of the internal carotid arteries bilaterally, distal to the origin of the anterior choroidal artery, with collateral reconstitution of the distal anterior and middle cerebral arteries. The proximal and cavernous segments of the internal carotid arteries, and the OphAs, were normal on angiographic studies.

Opening pressure on lumbar puncture was normal at 180 mm H₂O. Cerebrospinal fluid chemistry and cell counts were normal, and oligoclonal bands were negative. Serum levels of sodium, potassium, bicarbonate, chloride, and glucose were normal. Elevation of the following constituents were noted on serum studies: blood urea nitrogen 50 mg/dl (normal 7–20 mg/dl), creatinine 7 mg/dl (normal 0.7–1.1 mg/dl), calcium 9.5 mg/dl (normal 8.4–10.2 mg/dl), phosphorus 5.5 mg/dl (normal 2.1–4.3 mg/dl), and parathyroid hormone 701 pg/ml (normal 11–54 pg/ml).

Treatment and Clinical Course. The patient was admitted and treated with intravenously administered high-dose methylprednisolone (250 mg every 6 hours). Within 18 hours of starting treatment, her visual acuity had improved subjectively, and within 3 days it had improved to 20/200. The right central scotoma was reduced in size and she was able to count fingers in all but the superonasal field (Fig. 1 center).

Because we were concerned that compression of the ON within the optic canal was contributing at least in part to her vision loss,²³ we decided to proceed with surgical decompression of the canal via a right pterional craniotomy. Care was taken throughout the surgery to avoid any hypotension. The bone thickness at the pterion was 2.5 cm, which was well beyond the capability of conventional drills and craniotomes, making entry somewhat challenging. This difficulty was surmounted using handheld burrs and an oscillating saw to complete the cranial opening. The ON and orbital roof were exposed by gentle elevation of the frontal lobe intradurally, and the dorsal aspect of the optic canal was completely opened using a burr (model M8; Midas Rex Inc., Fort Worth, TX) with copious irrigation, microcurette, and a 1-mm Kerrison rongeur. The bone in this location was noted to be 10 mm thick, in contrast with the usual thickness of 1 to 2 mm. The ON sheath was

Compressive optic neuropathy secondary to renal osteodystrophy

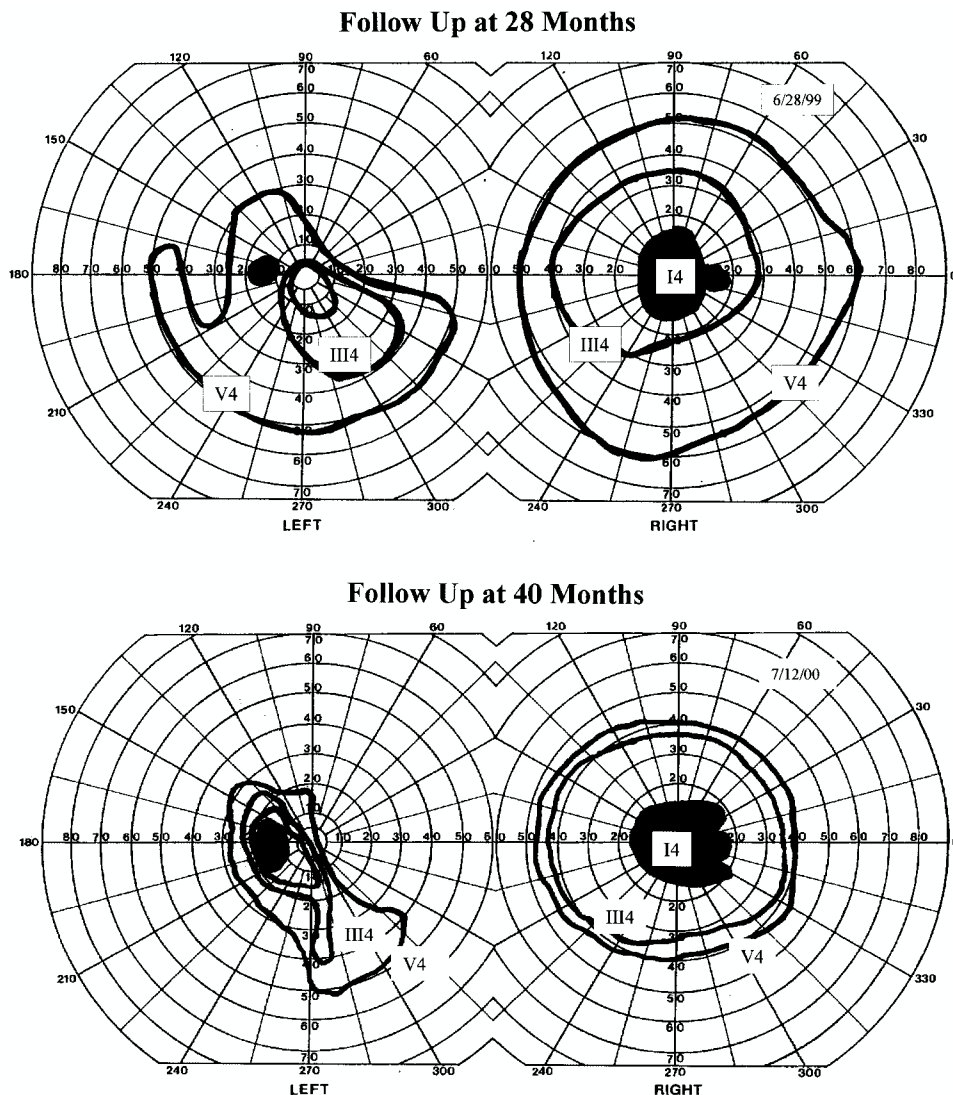


FIG. 4. Goldmann visual fields 28 months (*upper*) and 40 months (*lower*) after initial presentation, and after a similar episode of acute left eye vision loss treated only with steroid drugs. The left eye shows persistent severe vision field loss, which progressively worsens between studies obtained at 28 months and 40 months, whereas the visual field in the right eye remains stable.

fenestrated with a scalpel and microscissors, and a distinct pallor of the ON was noted.

Postoperative Course. The patient had an uneventful postoperative course with further objective improvement in her right visual field and color vision. Steroid medications were tapered after the 3rd postoperative day. Over the next 12 months, the visual field of her right eye had improved, with only a small central scotoma remaining (Fig. 1 *lower*). Her acuity remained stable at 20/200 OD, with a 1.5 log U RAPD. She underwent evaluation for residual parathyroid tissue, but none was found.

Sixteen months after her initial presentation she suffered acute painless vision loss of the left eye. Visual acuity was 20/400 OS, there was a 0.9 to 1.2 log U RAPD, and the visual field was severely constricted. She sought clinical treatment immediately after the onset of symptoms, and treatment was begun with intravenously administered ste-

roids at the same dose as before for 5 days. This was then followed by orally administered prednisone (60 mg/day). With this treatment there was also significant improvement in visual acuity, and ON decompression was not attempted. On subsequent visual examinations her acuity was 20/200 OD and 20/30 OS, with a RAPD of 0.6 log U in the left eye. A visual field examination conducted 28 months after her initial presentation, however, showed a significantly more constricted visual field in the left eye than in the right (Fig. 4A), and at 40 months the visual field loss in her left eye had increased further (Fig. 4B).

Discussion

The massive calvarial hypertrophy encountered in this patient fits best with a diagnosis of ULO or bighead disease, which has been known to affect animals with hyper-

parathyroidism induced by diets chronically deficient in calcium and rich in phosphate.¹⁴ It has also been seen in animals with hyperparathyroidism secondary to chronic renal insufficiency.¹⁹ Uremic leontiasis ossea represents an extreme manifestation of renal osteodystrophy in the calvaria and facial bones. Lee, et al.,¹⁵ recently described the clinical and radiographic features of ULO in five patients and found only four previous descriptions of this entity in humans.^{5,7,12,13,22} In these cases, maxillary and mandibular hypertrophy dominated the clinical presentation and led to respiratory insufficiency, parotitis, dysphagia, or speech impairment. In all the patients presented by Lee, et al., there was calvarial hypertrophy with marked expansion of the diploic space and numerous diploic nodules typical of brown tumors. The incidence of ULO is unknown, as is the incidence of subclinical craniofacial hypertrophy in cases of chronic uremia and secondary hyperparathyroidism.

The calvarial hypertrophy and neuroforaminal stenosis in our patient resembles the conditions of fibrous dysplasia and osteopetrosis. These two entities commonly present with compressive cranial neuropathies, especially of the second, seventh, and eighth cranial nerves.^{1,4,10} Vision loss with these two diseases is most commonly progressive, but can be precipitous. The compressive optic neuropathy seen in these two conditions is best treated with ON decompression.^{1,2,4,6,8-11,18,19,24} Improvement or stabilization of vision has been achieved in 83 to 94% of patients with these disorders who undergo ON decompression for subtotal vision loss.^{1,4,20} Transient visual worsening after surgery was reported in only one of 16 eyes. It is less clear whether decompressive surgery should be performed prophylactically in patients with these two entities, although it is advocated by some authors because of the low morbidity rate associated with this procedure.^{1,21} In cases of neoplasm, trauma and fibrous dysplasia, visual outcome is better the less impaired vision is at the time of decompression.^{3,4,6,16,17,20} The use of corticosteroid drugs as an adjunct to treatment of vision loss in compressive optic neuropathy has not been studied in a randomized controlled fashion, although they tend to be widely used. In a recent metaanalysis of steroid treatment compared with decompressive surgery for acute traumatic optic neuropathy, similar outcomes were found with either treatment or both together, and worse outcomes were seen if neither treatment was used.⁶

A variety of surgical approaches are available for ON decompression, including the transcranial approach used here, and the transthemoidal approach. In this case the transcranial approach was used because of the marked distortion of the skull base anatomy secondary to bone hypertrophy and the perceived advantage of being able to visualize the ON directly in the suprasellar subarachnoid space as it enters the optic canal. It is our opinion that with this degree of bone thickening, the transthemoidal approach would be extremely challenging. Regardless of the approach, it is essential to decompress the nerve along the entire length of the optic canal and over an adequate width. Most authors also advocate opening the dural sheath and the annulus of Zinn to complete the decompression.^{4,16}

This patient also had coincidental moyamoya disease with bilateral occlusion of the supraclinoid segment of her carotid arteries just distal to the origin of the anterior choroïdal arteries. Although this underlying disease also could have contributed to the patient's vision loss, the angiogram

revealed no abnormalities of the orbital vasculature including the OphA. We believe that a combination of ischemia and ON compression best account for this patient's vision loss.²³ The abrupt onset of vision loss was fundamentally ischemic in nature; however, the ON compression from the bone overgrowth likely contributed to the nerve's vascular compromise. Thus, we believe that ON decompression is justified for this condition.

Interestingly, with the subsequent episode of vision loss involving the contralateral eye, the patient served as her own control. The medically treated eye sustained progressive visual field loss from 28 months to 40 months, and the final examination 40 months after her initial presentation showed a substantially worse visual field outcome in this eye. The eye that did not undergo operation also ended up with a larger RAPD than the one that did. The eye that was not surgically treated, however, did recover better visual acuity with less impairment of the central fibers. This difference may be due to the fact that the patient sought ophthalmological treatment much sooner after the second episode of vision loss than after the first.

Parathyroidectomy is recommended for treatment of patients with ULO, and it may stabilize the disease, although the long-term outcome of these patients has not been determined.¹⁵ Patients with this disease should be considered to be at risk of compressive cranial neuropathy, and appropriate clinical monitoring should be performed on a regular basis. Until a way is found to reverse the foraminal stenosis medically, we suggest considering treating any compressive cranial neuropathy in these patients with prompt surgical decompression.

Conclusions

Calvarial hypertrophy in renal osteodystrophy, or ULO, has not previously been described as a cause of ON compression. When treated early and aggressively with high-dose steroid medications and ON decompression, vision loss can be significantly reversed. Without ON decompression, progressive loss of vision may occur.

References

1. Al-Mefty O, Fox JL, Al-Rodhan N, et al: Optic nerve decompression in osteopetrosis. **J Neurosurg** 68:80-84, 1988
2. Bland LI, Marchese MJ, McDonald JV: Acute monocular blindness secondary to fibrous dysplasia of the skull: a case report. **Ann Ophthalmol** 24:263-266, 1992
3. Carter KD, Freuh BR, Hessburg TP, et al: Long-term efficacy of orbital decompression for compressive optic neuropathy of Grave's eye disease. **Ophthalmology** 98:1435-1442, 1991
4. Chen YR, Breidahl A, Chang CN: Optic nerve decompression in fibrous dysplasia: indications, efficacy, and safety. **Plast Reconstr Surg** 99:22-33, 1997
5. Cohen J, Diamond I: Leontiasis ossea, slipped epiphysis, and granulosa cell tumor of testis with renal disease: report of a case with autopsy findings. **Arch Pathol** 56:488-500, 1953
6. Cook MW, Levin LA, Joseph MP, et al: Traumatic optic neuropathy. A meta-analysis. **Arch Otolaryngol Head Neck Surg** 122:389-392, 1996
7. Dantas M, Costa RS, Jorgetti V, et al: Facial leontiasis ossea: a rare presentation of hyperparathyroidism secondary to chronic renal insufficiency. **Nephron** 58:475-478, 1991

Compressive optic neuropathy secondary to renal osteodystrophy

8. Donoso LA, Magargal LE, Eiferman RA: Fibrous dysplasia of the orbit with optic nerve decompression. **Ann Ophthalmol** **14**:80–83, 1982
9. Finney HL, Roberts TS: Fibrous dysplasia of the skull with progressive cranial nerve involvement. **Surg Neurol** **6**:341–343, 1976
10. Guyer DR, Miller NR, Long DM, et al: Visual function following optic canal decompression via craniotomy. **J Neurosurg** **62**:631–638, 1985
11. Haines SJ, Erickson DL, Wirtschafter JD: Optic nerve decompression for osteopetrosis in early childhood. **Neurosurgery** **23**:470–475, 1988
12. Hogan DB, Couture RA, Levine DZ: Leontiasis ossea, flail chest and pancytopenia in a patient with renal osteodystrophy. **Can Med Assoc J** **127**:1012–1013, 1982
13. Kienbock R: Leontiasis ossea facie: Virchow. **Beitr Klin Chir** **171**:25–52, 1940
14. Krook L, Lowe JE: Nutritional secondary hyperparathyroidism in the horse. **Pathol Vet** **1 (Suppl)**:1–98, 1964
15. Lee VS, Webb MS Jr, Martinez S, et al: Uremic leontiasis ossea: “bighead” disease in humans? Radiologic, clinical, and pathologic features. **Radiology** **199**:233–240, 1996
16. Li KK, Lucarelli MJ, Bilyk JR, et al: Optic nerve decompression for compressive neuropathy secondary to neoplasia. **Arch Otolaryngol Head Neck Surg** **123**:425–429, 1997
17. Long DM: Neurosurgical involvement in tumors of the orbit. **Clin Neurosurg** **32**:514–523, 1985
18. Nanami T, Hidaka T, Kidoguchi J, et al: [Orbito-cranial reconstruction and unilateral optic canal release in a patient with left fronto-orbital fibrous dysplasia: a case report.] **No Shinkei Geka** **10**:967–971, 1994 (Jpn)
19. Norrdin RW: Fibrous osteodystrophy with facial hyperostosis in a dog with renal cortical hypoplasia. **Cornell Vet** **65**:178–186, 1975
20. Orzincolo C, Bedani PL, Tamarozzi R, et al: Il cranio nell’osteodistrofia renale. **Radiol Med** **73**:518–522, 1987
21. Papay FA, Morales L Jr, Flaharty P, et al: Optic nerve decompression in cranial base fibrous dysplasia. **J Craniofac Surg** **6**:5–14, 1995
22. Pfeifle K, Koch H, Grabensee B, et al: Monströsse tumorartige Veränderungen des Gesichtsschädels bei sekundärem hyperparathyreoidismus. **Dtsch Med Wochenschr** **99**:389–391, 1974
23. Trobe JD, Glaser JS: Quantitative perimetry in compressive optic neuropathy and optic neuritis. **Arch Ophthalmol** **96**:1210–1216, 1978
24. Weisman JS, Hepler RS, Vinters HV: Reversible visual loss caused by fibrous dysplasia. **Am J Ophthalmol** **110**:244–249, 1990

Manuscript received December 14, 1998.

Accepted in final form June 26, 2001.

Address reprint requests to: Richard H. Schmidt, M.D., Ph.D., Department of Neurosurgery, University of Utah Health Sciences Center, 50 North Medical Drive, Salt Lake City, Utah 84132. email: rhs@suzy.med.utah.edu.