

## Cosmetic mastoidectomy for the combined supra/infratentorial transtemporal approach

### Technical note

WILLIAM T. COULDWELL, M.D., PH.D., AND TAKANORI FUKUSHIMA, M.D., D.M.Sc.

*Department of Neurological Surgery, University of Southern California School of Medicine, Los Angeles, California*

✓ The authors describe a cosmetic mastoidectomy technique for use when performing a combined supra/infratentorial craniotomy and transtemporal exposure. The technique involves a single temporal suboccipital bone flap and cosmetic mastoidectomy, removing the outer table of bone for later replacement. Replacement of the outer table of mastoid bone enables tamponade of a fat graft against the dura to reduce the risk of postoperative cerebrospinal fluid leaks. The technique has been performed in eight patients treated for petroclival meningiomas with excellent cosmetic results.

**KEY WORDS** • mastoidectomy • surgical approach • supratentorial approach • infratentorial approach

UTILIZATION of the combined supra/infratentorial approach with mastoidectomy for retrolabyrinthine, translabyrinthine, or transcochlear exposure results in an undesirable cosmetic deformity in the retroauricular area, and also carries the risk of cerebrospinal fluid (CSF) leakage if the dura is not closed optimally. To avoid cosmetic deformity and facilitate watertight closure, we have developed an alternative to the standard technique of complete drilling of the mastoid region.

### Operative Technique

In this approach, a one-piece temporal and suboccipital bone flap is first raised with careful placement of burr holes straddling the transverse sinus, the most lateral extension being the asterion. Following removal of the bone flap by means of a craniotome,\* taking care to avoid violation of the transverse sinus, the outer table of bone overlying the mastoid is removed with either an oscillating saw or a fine high-speed cutting drill. The margins of the outer table resection are the root of the zygoma, the external auditory canal, and the outer contour of the mastoid to the tip of the mastoid process, carefully leaving the insertion of the sternocleidomastoid muscle intact (Fig. 1). The remain-

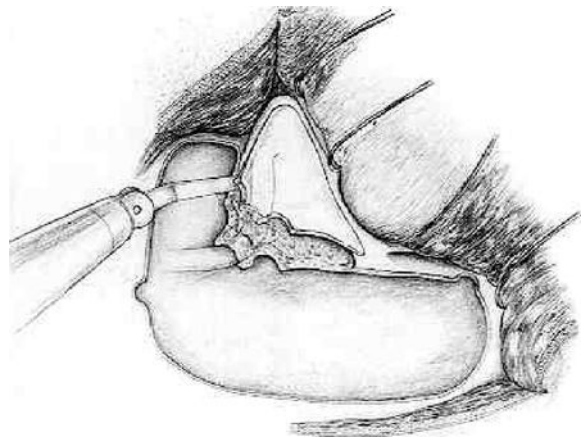


FIG. 1. The initial bone flap is planned to include the temporal and suboccipital exposure to the margin of the mastoid laterally. Burr holes are placed straddling the transverse sinus to visualize and protect this area during craniotome cutting. The mastoidectomy is performed by cutting through the outer table of the bone, with the zygomatic root, external auditory canal, and lower mastoid margin as the limits of resection. The outer table is then undercut with an oscillating saw and removed as a split-thickness bone flap for later cosmetic reapproximation. The remainder of the mastoid is drilled in the standard fashion, with labyrinth or cochlear removal as necessary.

\* Craniotome manufactured by Midas Rex Institute, Fort Worth, Texas.

## Mastoidectomy for supra/infratentorial approach

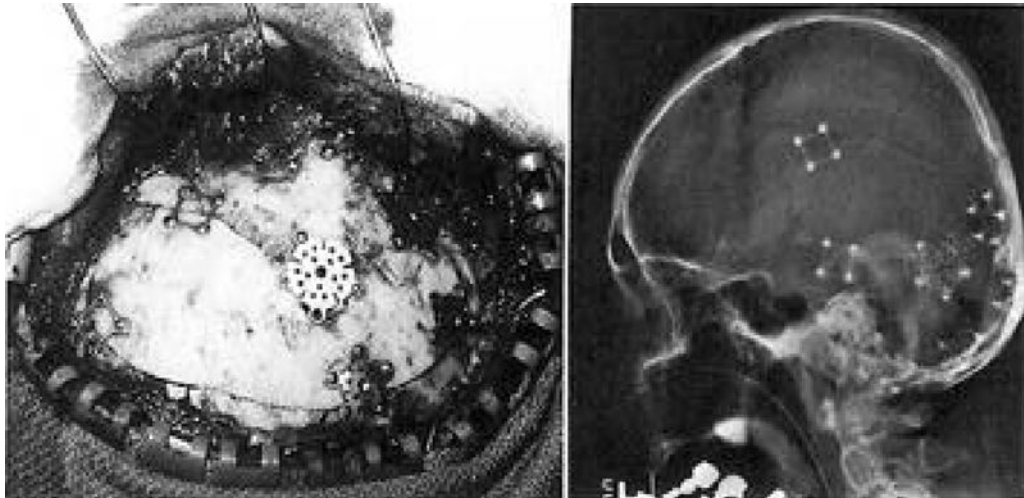

FIG. 2. *Left:* Intraoperative photograph demonstrating the use of the miniplate system for fixation of the bone flaps. Note that replacing the outer table of mastoid bone buttresses the fat graft placed in the drilled mastoid cavity below. Burr holes are covered with titanium burr-hole covers. *Right:* Postoperative skull radiograph showing the bone flaps and various miniplates used for fixation.

der of the mastoidectomy is then performed with a high-speed burr. Upon closure, the outer table of mastoid bone is replaced over a fat graft to the mastoid defect and dura, with tamponade of the fat graft to minimize CSF leaks. This outer-table bone flap is fastened in place with miniplate fixation (Fig. 2).†

### Comment

The cosmetic mastoidectomy technique has been used in eight patients undergoing a combined supra/infratentorial transpetrosal approach with excellent results. All patients had petroclival meningiomas requiring a large basal exposure (combined supra/infratentorial). No postoperative CSF leaks were encountered and there were no complications related to the cosmetic mastoidectomy.

Originally popularized by Malis,<sup>2</sup> the combined supra/infratentorial approach is ideal for large tumors centered on the petrous apex and having a large basal attachment necessitating extensive basal exposure.<sup>3,4</sup> Inherent in this exposure is the risk of CSF leakage if the dura is not closed or grafted properly. The method described here enables tamponade of the fat graft over the dura closure, in addition to obviating the cosmetically undesirable defect in the retroauricular region.<sup>1</sup>

† Miniplate fixation system manufactured by Leibinger, Irving, Texas.

The introduction of microplating systems to fasten bone flaps and cover burr hole defects enables the replacement of small bone fragments in difficult locations with greater ease than the standard wiring technique. The modified mastoidectomy has been successfully performed in eight patients with a combined approach; we conclude that it is a safe and cosmetically superior alternative to radical mastoid drilling in these cases.

### References

1. Fukushima T: Combined supra- and infra-parapetrosal approach for petroclival lesions. in Sekhar LN, Janecka IP (eds): *Surgery of Cranial Base Tumors*. New York: Raven Press, 1993, pp 661-670
2. Malis LI: Surgical resection of tumors of the skull base, in Wilkins RH, Rengachary SS (eds): *Neurosurgery*. New York: McGraw-Hill, 1985, Vol 1, pp 1011-1021
3. Samii M, Ammirati M, Mahran A, et al: Surgery of petroclival meningiomas: report of 24 cases. *Neurosurgery* 24:12-17, 1989
4. Spetzler RF, Dasgupta CP, Pappas CTE: The combined supra- and infratentorial approach for lesions of the petrous and clival regions: experience with 46 cases. *J Neurosurg* 76:588-599, 1992

Manuscript received November 19, 1992.

Address reprint requests to: William T. Couldwell, M.D., Ph.D., University of Southern California University Hospital, 1510 San Pablo Street, Los Angeles, California 90033.