

# Vitamin A in the Cerebrospinal Fluid of Patients with and without Idiopathic Intracranial Hypertension

Judith E. A. Warner, MD,<sup>1,2</sup>  
Paul S. Bernstein, MD, PhD,<sup>1</sup>  
Alexander Yemelyanov, MD, PhD,<sup>1</sup>  
Stephen C. Alder, PhD,<sup>3</sup> Steven T. Farnsworth, MD,<sup>4</sup>  
and Kathleen B. Digre, MD<sup>1,2</sup>

**We quantified vitamin A in the cerebrospinal fluid of patients with idiopathic intracranial hypertension, elevated intracranial pressure of other causes and normal intracranial pressure. Vitamin A could be detected by high-pressure liquid chromatography in most of the specimens. There was a significantly higher level of vitamin A in the cerebrospinal fluid of some patients with idiopathic intracranial hypertension. Vitamin A toxicity may play a role in the pathogenesis of idiopathic intracranial hypertension.**

Ann Neurol 2002;52:647–650

Idiopathic intracranial hypertension (IIH) is a condition of elevated intracranial pressure (ICP) that tends to occur in otherwise healthy overweight young women. The underlying cause of IIH is unknown. Vitamin A has been proposed as a candidate mediator of IIH because of reports of vitamin A intoxication associated with elevated ICP. Recently, elevated serum retinol<sup>1</sup> and serum retinol-binding protein<sup>2</sup> (RBP) levels were found in some patients with IIH, suggesting that IIH is associated with an abnormality in the vitamin A transport system. Vitamin A has not been measured previously in cerebrospinal fluid (CSF). We explored the role of vitamin A in the pathophysiology of IIH by attempting to detect and quantify retinol, the major

circulating form of vitamin A, in the CSF of patients with and without IIH.

## Patients and Methods

We obtained 1ml of CSF from patients undergoing lumbar puncture (LP) for various reasons from January 1999 through August 2001. We recorded the reason for the LP, opening pressure, CSF indices, MRI results, presence of papilledema, medications, gender, and age of the patient. In most patients, height and weight data were available in the chart.

In addition, a group of patients undergoing spinal anesthesia for routine surgical procedures consented to have their CSF pressure measured and to donate an aliquot of CSF, but indices were not analyzed. All CSF was shielded from light during collection. The institutional review board of the University of Utah approved this study.

Patients were grouped based on medical history into three categories: (1) IIH, those meeting the modified Dandy criteria of increased ICP, papilledema, normal neuroimaging, and no other causes discovered, (2) elevated ICP, those with elevated ICP attributable to medical conditions, medication use, or venous sinus thrombosis, and (3) normal ICP, those having LP for other neurological conditions or spinal anesthesia. ICP was considered elevated if the pressure was greater than 250mm CSF. Patients with clinically suspected breakdown of the blood–brain barrier (BBB) were identified based on history of brain tumor or recent neurosurgical procedure.

## High-Pressure Liquid Chromatography Analysis of Vitamin A in Cerebrospinal Fluid Samples

CSF samples were stored in aliquots of 0.5ml at  $-70^{\circ}\text{C}$  until analyzed. Under red light and on ice, 0.5ml of CSF and 0.5ml of methanol were blended thoroughly. Hexane 0.5ml containing 0.1% butylated hydroxytoluene as an antioxidant was added to the CSF-methanol mixture, which again was mixed thoroughly. After centrifugation at 5,000 rpm for 5 minutes, the upper phase contained hexane with extracted retinol. Single-step extraction was sufficient to extract greater than 90% of endogenous detectable retinol. Immediately after extraction, 200 $\mu\text{l}$  of extracted material was analyzed by normal phase HPLC using a DYNAMAX-60A silica column (Ranin Instrument, Emeryville, CA). Samples were eluted isocratically at a flow rate of 1.0ml per minute with a mixture of 90% hexane and 10% 1,4-dioxane on a Waters (Milford, MA) HPLC system with single wavelength detection at 325nm or on a Thermo Separations (San Jose, CA) HPLC system with photodiode array detection. The vitamin A peak on the chromatograms was quantified by external standardization against synthetic vitamin A (all-*trans*-retinol) from Sigma Chemicals (St. Louis, MO). Storage of CSF samples at  $-70^{\circ}\text{C}$  in the dark for up to 12 months did not affect retinol content.

## Statistical Methods

Data were entered into Microsoft Excel 97 and imported into SPSS 10.0 for Windows for analysis. Summary statistics were used to characterize patients participating in this study. CSF vitamin A levels were grouped into three ordinal cate-

<sup>1</sup>Department of Ophthalmology and Visual Sciences, John A. Moran Eye Center; and <sup>2</sup>Department of Neurology, <sup>3</sup>Graduate Programs in Public Health, Department of Family and Preventive Medicine, and <sup>4</sup>Department of Anesthesiology, University of Utah Health Sciences Center, Salt Lake City, UT.

Received Apr 22, 2002, and in revised form Jul 30. Accepted for publication Jul 30, 2002.

Address correspondence to Dr Warner, Department of Ophthalmology and Visual Sciences, John A. Moran Eye Center, 50 North Medical Drive, Salt Lake City, UT 84132. E-mail: judith.warner@hsc.utah.edu

gories for analysis: undetectable (<1nM), moderate (1–25nM), and high (>25nM). Associations between patients with IIH and vitamin A levels were tested using the Fisher's exact test, with post hoc paired tests conducted using a Bonferroni adjusted  $\alpha$ .<sup>5</sup>

## Results

A peak whose elution time was the same as the synthetic vitamin A standard was present on many of the CSF chromatograms (Fig, *inset*). The identity of this peak was confirmed on pooled CSF samples by photodiode array detection, which showed an absorption spectrum identical to the vitamin A standard with a peak absorbance at 326nm. No retinyl esters or carotenoids were detectable under these conditions. Furthermore, coinjection of a vitamin A-positive CSF sample with the vitamin A standard yielded a single peak on the chromatogram. The CSF vitamin A levels ranged from 0 to 304nM, with a mean of 14.2nM and a median of 7.13nM. Ten specimens had no detectable vitamin A.

Samples from a total of 80 patients were included in the analyses. See Table 1 for demographic information. Expected differences were observed for mean age, body mass index, the percentage of patients who were female, and mean ICP. Four patients were identified as having BBB. Of the 21 patients with IIH, 2 did not have elevated ICP at the time of the LP but were included in the group because of previously having met the Dandy criteria. Eighteen of those in the elevated ICP group had elevated ICP because of use of a medication or from a medical condition. Six had venous

outflow obstruction, four were on tetracycline antibiotics, two had pulmonary disease, and two had cancer involving the central nervous system. Nine patients gave specimens while undergoing spinal anesthesia (11%). One of these patients was included in the elevated ICP group because of asymptomatic ICP of 336mm CSF. The others were included in the normal ICP group. Most in the normal ICP group were undergoing LP for conditions such as optic neuropathy, multiple sclerosis, or headache.

There was a statistically significant association between higher vitamin A levels and IIH ( $p = 0.036$ ; Table 2 and Fig). Vitamin A levels were not significantly associated with increased pressure ( $p = 0.31$ ), body mass index ( $p = 0.120$ ), or with the presence of abnormal CSF parameters of elevated protein ( $p = 0.382$ ), erythrocytes ( $p = 0.153$ ), or leukocytes ( $p = 0.936$ ). Higher vitamin A levels were marginally significantly associated with female gender ( $p = 0.094$ ) and younger age ( $p = 0.069$ ). The average vitamin A level in the four patients with BBB was 23.0nM. The small size of the group did not permit statistical analysis. The average vitamin A level in the nine patients undergoing spinal anesthesia was 5.9nM. There was no association between multivitamin use and level of vitamin A.

## Discussion

Serum RBP and retinol have been found to be elevated in some patients with IIH.<sup>1,2</sup> Retinol is actively transported across the BBB by transthyretin, in a complex with RBP.<sup>4</sup> RBP has been found to localize to the hu-

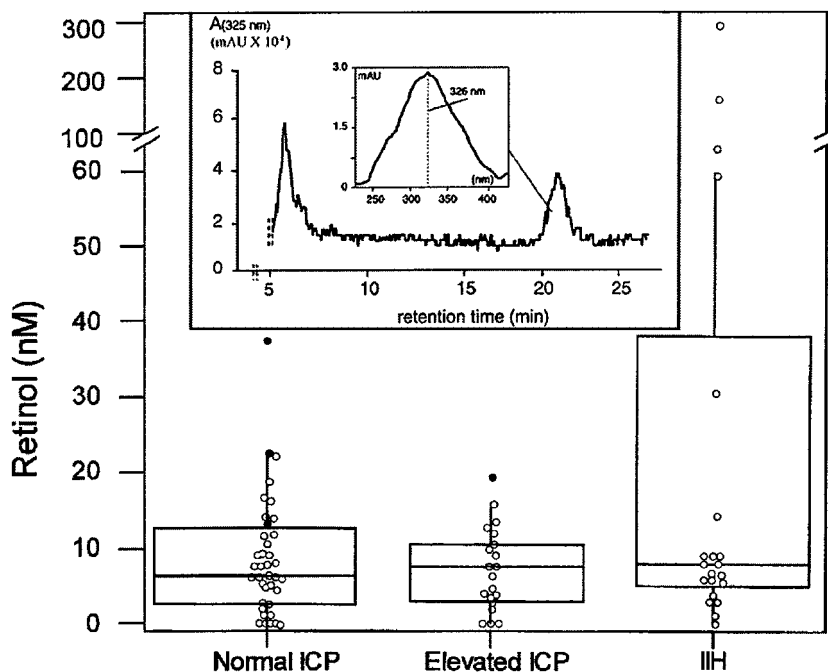


Fig. Scattergram of serum retinol levels showing normal intracranial pressure (ICP), elevated ICP, and idiopathic intracranial hypertension (IIH). The horizontal bar represents the median value. The boxes represent the 75th and 25th percentiles, and the whiskers represent the 95th and 5th percentiles. The filled dots denote the patients with blood-brain barrier. The inset box is an high-performance liquid chromatogram of extracted vitamin A from pooled cerebrospinal fluid samples from three subjects, and its inset box displays the photodiode array spectrum of the peak eluting at 21 minutes that coelutes with vitamin A standard and whose absorbance maximum at 326nm matches that of synthetic vitamin A.

Table 1. Characteristics of Study Patients

Characteristic	IIH (n = 20)	E-ICP (n = 19)	N-ICP (n = 39)	Totals (n = 78)	p
Age <sup>a</sup> (yr)	26.0 (21.5–38.0)	34.0 (22.0–52.0)	48.5 (39.3–63.3)	40.0 (24.3–52.8)	<0.001
BMI <sup>a,b</sup> (kg/m <sup>2</sup> )	33.5 (31.1–41.4)	32.8 (28.0–36.1)	26.3 (23.4–31.2)	29.4 (24.4–36.1)	<0.003
Female <sup>c</sup> (%)	100.0	84.2	55	73.8	<0.001
Opening pressure <sup>a,d</sup> (mm CSF)	318 (281–458)	350 (310–390)	183 (152–205)	240 (177–338)	<0.001
Multivitamin use <sup>c,d</sup> (%)	0	10.5	30	17.5	0.005
CSF retinol levels <sup>a</sup> (nM)	8.0 (4.7–22.4)	7.5 (2.8–9.3)	6.2 (2.6–12.7)	7.13 (3.1–11.9)	0.470

<sup>a</sup>Median (interquartile range), group comparison using Kruskal–Wallis test.

<sup>b</sup>n = 56 (IIH, n = 15; E-ICP, n = 12; N-ICP, n = 29).

<sup>c</sup>Group comparison using Fisher's exact test.

<sup>d</sup>n = 78 (IIH, n = 20; E-ICP, n = 19; N-ICP, n = 39).

IIH = idiopathic intracranial hypertension; E-ICP = elevated intracranial pressure; N-ICP = normal ICP; BMI = body mass index; CSF = cerebrospinal fluid.

Table 2. Association between IIH and Vitamin A Levels<sup>a</sup>

Vitamin A Level (nM)	IIH, f (%)	E-ICP, f (%)	N-ICP, f (%)	Total, f (%)
<1	1 (10.0)	3 (30.0)	6 (60.0)	10 (100.0)
1–25	15 (23.4)	16 (25.0)	33 (51.6)	64 (100.0)
>25	5 (83.3)	0 (0.0)	1 (16.7)	6 (100.0)
Total	21 (26.3)	19 (23.8)	40 (50.0)	80 (100.0)

<sup>a</sup>Using Fisher's exact test, *p* = 0.036. Paired comparisons using a Bonferroni adjustment ( $\alpha$  = 0.0167) were not significant (IIH vs E-ICP, *p* = 0.048; IIH vs N-ICP, *p* = 0.021; E-ICP vs N-ICP, *p* = 1.000).

IIH = idiopathic intracranial hypertension; E-ICP = elevated intracranial pressure; N-ICP = normal ICP.

man choroid plexus epithelium and to endothelial cells of brain microvasculature.<sup>5</sup> Vitamin A therefore is thought to have a specific transport mechanism into the CSF. Retinol and its metabolite retinoic acid play an important role not only in developing brain, but also in transneuronal signaling in the basal ganglia and associated structures in the mature brain.<sup>6</sup> However, retinol is thought to be toxic to membranes when its level exceeds the binding capacity of RBP.<sup>7</sup>

Excess RBP and retinol in the serum may be transported into the CSF where retinol acts as a toxin to the arachnoid granulation resorption mechanism. The finding of high vitamin A in the CSF of some patients with IIH would support this theory, as would the high average vitamin A level in patients with BBB. High CSF vitamin A found in IIH may represent an epiphenomenon or marker of excess CSF production by the choroid plexus.

Of interest are several observations. One patient with chronic daily headaches and borderline elevated ICP without papilledema had three samples analyzed. Her CSF vitamin A was consistent over time (4.59, 4.86, and 5.97nM). Another patient had two LP, one while symptomatic with IIH (65.1nM), and another when symptoms and signs of IIH had resolved

(5.07nM). One patient with headaches attributed to isotretinoin had normal ICP (210mm CSF), and a CSF vitamin A of 5.8nM.

In this study, we demonstrate detection of retinol in spinal fluid. Some patients with IIH had statistically significantly higher levels of vitamin A than patients with normal ICP or patients with other causes of elevated ICP. Vitamin A levels were not fully explained by the age, gender, multivitamin use, body mass index, or ICP of the patients.

Further research is needed to study the association between CSF vitamin A levels and IIH. Studies should include patients with both low (<1nM) and high (>25nM) vitamin A levels to determine whether the observed relationship with IIH remains consistent. Many more subjects undergoing spinal anesthesia should be studied, to ascertain a normal range of vitamin A. Measurement of other metabolites such as retinoic acid in the serum (or CSF) might be revealing.<sup>8</sup> Detection and quantification of RBP in the CSF also may prove fruitful in elucidating in the pathophysiology of IIH. Matched specimens of serum and CSF vitamin A and RBP should be analyzed. Further study of patients with BBB could shed light on the regulation of vitamin A transport and metabolism in the central nervous system. There is no question, however, that vitamin A can be detected in CSF in many individuals, and our results indicate a higher level in some patients with IIH.

This work was supported in part by an unrestricted grant from Research to Prevent Blindness, Inc., New York, NY, to the Department of Ophthalmology and Visual Sciences, University of Utah. P.S.B. is a Sybil B. Harrington RPB Research Scholar.

We acknowledge J. C. Moore and Dr P. Bhosale for their work in analyzing CSF specimens.

## References

- Jacobson DM, Berg R, Wall M, et al. Serum vitamin A concentration is elevated in idiopathic intracranial hypertension. *Neurology* 1999;53:1114–1118.

2. Selhorst JB, Kulkantrakorn K, Corbett JJ, et al. Retinol-binding protein in idiopathic intracranial hypertension (IIH). *J Neuro-Ophthalmol* 2000;20:250–252.
3. Zar JH. *Biostatistical analysis*. 4th ed. Upper Saddle River, NJ: Prentice-Hall, 1999.
4. Herbert J, Wilcox JN, Pham K-TC, et al. Transthyretin: a choroid plexus-specific transport protein in human brain. *Neurology* 1986;36:900–911.
5. McDonald PN, Bok D, Ong DE. Localization of cellular retinol-binding protein and retinol-binding protein in cells comprising the blood-brain barrier of rat and human. *Proc Natl Acad Sci USA* 1990;87:4265–4269.
6. Zetterstrom RH, Lindqvist E, Mata de Urquiza A, et al. Role of retinoids in the CNS: differential expression of retinoid binding proteins and receptors and evidence for presence of retinoic acid. *Eur J Neurosci* 1999;11:407–416.
7. Smith FR, Goodman DS. Vitamin A transport in human vitamin A toxicity. *N Engl J Med* 1976;294:805–808.
8. Sass JO, Arnhold T, Tzimas G. Serum vitamin A is elevated in idiopathic intracranial hypertension. *Neurology* 2000;54:2192–2193.

## Thalamic Neurodegeneration in Multiple Sclerosis

Alberto Cifelli, MD,<sup>1,2</sup> Marzena Arridge, PhD,<sup>1</sup> Peter Jezzard, PhD,<sup>1</sup> Margaret M. Esiri, FRCPATH,<sup>2</sup> Jacqueline Palace, MD,<sup>2</sup> and Paul M. Matthews, FRCP<sup>1,2</sup>

---

**Multiple sclerosis is still regarded primarily as a disease of the white matter. However, recent evidence suggests that there may be significant involvement of gray matter. Here, we have used magnetic resonance imaging and magnetic resonance spectroscopy in vivo and histopathology postmortem to estimate thalamic neuronal loss in patients with multiple sclerosis. Our results show that neuronal loss in multiple sclerosis can be substantial (30–35% reduction). We conclude that a neurodegenerative pathology may make a major contribution to the genesis of symptoms in multiple sclerosis.**

*Ann Neurol* 2002;52:650–653

---

With an increasing focus on axonal injury and transection as the main cause of chronic disability with multiple sclerosis (MS),<sup>1,2</sup> attention also has turned to un-

---

From the <sup>1</sup>Centre for Functional Magnetic Resonance Imaging of the Brain, and <sup>2</sup>Department of Clinical Neurology, University of Oxford, Oxford, United Kingdom.

Received Mar 18, 2002, and in revised form May 28. Accepted for publication May 28, 2002.

Published online Aug 25, 2002, in Wiley InterScience (www.interscience.wiley.com). DOI: 10.1002/ana.10326

Address correspondence to Dr Matthews, Centre for Functional Magnetic Resonance Imaging of the Brain, John Radcliffe Hospital, Headley Way, Headington, Oxford OX3 9DU, United Kingdom. E-mail: paul@fmrib.ox.ac.uk

derstanding neuronal pathology in gray matter (GM) of patients with MS, particularly to explain cognitive symptoms.<sup>3</sup> Axotomy is associated with retrograde neuronal degeneration and apoptosis.<sup>4</sup> Apoptosis of retinal ganglion cells is associated with optic neuritis in a rodent experimental allergic encephalitis model.<sup>5</sup> GM also may be a common focus for inflammatory damage.<sup>6</sup>

The aim of our study was to assess the extent of neuronal loss in thalamic GM of patients with MS using imaging methods and then to validate the measurements with parallel histopathological studies performed on (different) postmortem material. The thalamic medial dorsal (MD) nucleus specifically was chosen for the histopathological study because of its relatively large size, clearly defined boundaries, and potential importance for understanding cognitive manifestations of MS.<sup>7</sup>

### Subjects and Methods

#### *Magnetic Resonance Spectroscopy and Imaging*

Magnetic resonance studies were conducted for 14 secondary progressive MS patients randomly selected from our clinic database (Table 1). Healthy controls were age- and gender-matched. Subjects had a structural magnetic resonance imaging for thalamic volume measurements with a pulse sequence optimized for contrast between the thalamus and surrounding white matter and magnetic resonance spectroscopy of the thalamus. Informed consent was obtained.

All studies were performed using a 3T Varian-Inova scanner (Varian NMR Instruments, Inc., Palo Alto, CA). For volume measurements, a three-dimensional magnetization-prepared fast gradient echo sequence (inversion recovery time TI, 500 milliseconds; TE, 5 milliseconds; TR, 30 milliseconds; 64 × 3 mm) was used. Thalamic and intracranial volumes were outlined manually in the coronal plane (Fig. A and B). Ratios of thalamic volume to intracranial volume were calculated in every patient (multiplied by 10<sup>6</sup> for a normalized thalamic volume [NTV]). Third ventricle width was measured from the coronal slice showing maximum width.

Proton magnetic resonance spectra were acquired using a localized PRESS sequence<sup>8</sup> (echo time TE, 26 milliseconds; repetition time TR, 5 seconds) and a WET<sup>9</sup> water suppression scheme. The use of a short echo time and a TR long enough to allow full relaxation minimized the effects of modest changes in relaxation times (eg, from factors such as increased iron content) on measurements of metabolite concentrations. Application of a specially designed 90 degree RF pulse in PRESS allowed simultaneous acquisition of the signal from two cubical approximately 1 cm<sup>3</sup> volumes of interest placed in the thalami. Metabolite concentrations were estimated (VARPRO method and MRUI software) using brain tissue water as a concentration reference.<sup>10,11</sup> We confirmed that similar results were obtained using LCModel.<sup>12</sup> The relative volumes of water in cerebrospinal fluid and tissue compartments within the voxel were estimated with biexponential fitting of the water signal T2 decay (TR, 15 seconds; TE,