

Neurosurgical complications of direct thrombin inhibitors—catastrophic hemorrhage after mild traumatic brain injury in a patient receiving dabigatran

Case report

SARAH T. GARBER, M.D., WALAVAN SIVAKUMAR, M.D., AND RICHARD H. SCHMIDT, M.D., PH.D.

Department of Neurosurgery, University of Utah, Salt Lake City, Utah

Dabigatran etexilate is an oral anticoagulant that acts as a direct, competitive thrombin inhibitor. Large randomized clinical trials have shown higher doses of dabigatran (150 mg taken twice daily) to be superior to warfarin in terms of stroke and systemic embolism rates in patients with nonvalvular atrial fibrillation. As a result, in 2010 the US FDA approved the use of dabigatran for the prevention of stroke and systemic embolism in patients with atrial fibrillation. Dabigatran is especially attractive in the outpatient setting because patients do not require routine monitoring with prothrombin times or international normalized ratios. To date, no effective reversal agent for dabigatran in the event of catastrophic hemorrhage has been identified. The authors report a case of an elderly patient, being treated with dabigatran for atrial fibrillation, who presented with a rapidly expanding intracranial hemorrhage after a ground-level fall. This case highlights an impending neurosurgical quandary of complications secondary to this new anticoagulation agent and suggests potential options for management.

(<http://thejns.org/doi/abs/10.3171/2012.2.JNS112132>)

KEY WORDS • dabigatran • intracerebral hemorrhage •
anticoagulation • thrombin • traumatic brain injury •
neurosurgical complication

ATRIAL fibrillation has long been shown to increase the risk of stroke and death.^{5,6} Pharmacological stroke prevention agents for nonvalvular atrial fibrillation have evolved in an effort to address various aspects of the coagulation cascade. Specific efforts aimed at altering thrombus formation have included platelet function inhibitors, such as aspirin and clopidogrel, and vitamin K blockade, with warfarin. Treatment with warfarin results in a relative stroke risk reduction of 60%;⁶ however, this drug's efficacy has been hindered by the need for frequent monitoring, multiple interactions with food and other medications, and its increased risk of hemorrhage.¹ Newer agents have aimed at more direct coagulation factor inhibition. Large, randomized, multicenter noninferiority trials have shown that direct thrombin inhibitors, such as dabigatran, have lower rates of stroke and systemic embolism than warfarin with decreased rates of major hemorrhage.^{1,3} In the event of traumatic hemorrhage in patients receiving dabigatran, however, there are currently no effective reversal agents. Familiar-

ity with this new anticoagulation agent is critical in the neurosurgical community so that management options, while currently limited, can be implemented in a timely fashion.

Case Report

This 83-year-old man was evaluated in the emergency department after a ground-level fall at home. One month earlier, he had been diagnosed with new-onset atrial fibrillation and started on dabigatran 150 mg twice a day by his primary care physician. On initial neurosurgical evaluation, the patient was found to have a GCS of 15.⁹ Noncontrast CT revealed a right temporal intraparenchymal hemorrhage with surrounding cerebral edema, as well as a small right subdural hematoma and a small area of SAH (Fig. 1 left). There was also a small amount of left frontal lobe and left parietal lobe SAH (Fig. 1 right). Initial laboratory values revealed an international normalized ratio of 1.4, a prothrombin time of 17.2 seconds (normal range 12–15.5 seconds), and a partial thromboplastin time of 43 seconds (normal range 24–35 seconds). Platelet counts were normal at 271. The thrombin time was also measured and found to exceed 150 seconds (normal range

Abbreviations used in this paper: GCS = Glasgow Coma Scale; SAH = subarachnoid hemorrhage.

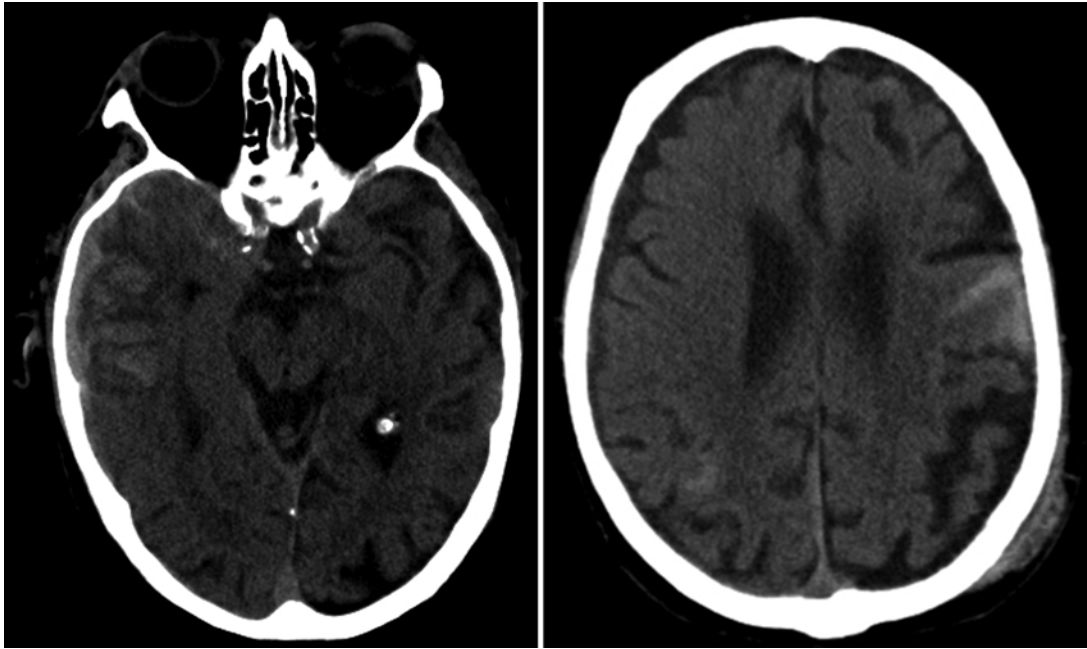


Fig. 1. Noncontrast head CT scans obtained in the emergency department showing right temporal intraparenchymal hemorrhage with associated subdural hemorrhage and SAH (left) and left frontal subarachnoid blood (right).

14.7–19.5 seconds). The patient was admitted to the neurocritical care unit for serial neurological examinations.

Approximately 2 hours after admission to the intensive care unit, the patient developed dysarthric speech, although he was still able to briskly follow commands. Repeat CT demonstrated significant interval progression of both the right parenchymal and left frontal hemorrhages (Fig. 2A). Although the neurosurgical team was aware of the limited options available for reversal of dabigatran, a weight-based dose of recombinant factor VII was administered because it has a rapid onset of action. The patient's mental status continued to decline, however, and he required emergency endotracheal intubation for a GCS score of 6 (E1, V1, M4).⁹ A final CT scan, obtained only 6 hours after his initial presentation, showed extensive progression of the patient's bilateral intraparenchymal hemorrhages, now encompassing most of the left hemisphere with 7 mm of left-to-right midline shift and effacement of the left lateral ventricle (Fig. 2B). After extensive discussion with the patient's family regarding his poor neurological prognosis, the decision was made to transition the patient to comfort care. The patient died shortly thereafter.

Discussion

The recent approval of dabigatran by the US FDA for stroke and systemic embolism prevention in patients with atrial fibrillation presents a new dilemma for neurosurgeons. Patients treated with dabigatran are often elderly individuals with multiple comorbidities. Imbalance and falls are common in this population, and intracranial hemorrhage resulting even from minor trauma may occur with increasing frequency as use of this drug becomes more widespread.

Atrial fibrillation is characterized by a loss of organized atrial contraction, which can lead to stasis and thrombus formation. In patients with nonvalvular atrial fibrillation, the annual risk of stroke can be calculated according to the CHADS₂ criteria.⁷ Because thrombin plays a key role in fibrin clot formation and is essential to blood coagulation, it is an attractive target for pharmaceutical agents. Current anticoagulants such as unfractionated low-molecular-weight heparin and the vitamin K antagonist warfarin require frequent blood draws and dosing adjustments to ensure patients remain in a therapeutic range.

Dabigatran is a synthetic thrombin inhibitor that binds directly to clot-bound and free thrombin with high specificity.⁸ Pharmacokinetic highlights include 80% renal excretion and a serum half-life of 12–17 hours. Because of its half-life, which is shorter than that of warfarin, dabigatran is typically administered twice daily. It is not metabolized by cytochrome p450 isoenzymes and therefore is less likely to potentiate drug-drug interactions.⁸ In addition, because dabigatran has been shown to have little interaction with food or drugs, it can be prescribed in a fixed dose without the constraints of frequent monitoring.⁸ The most common side effect of dabigatran is dyspepsia, although clinical trial results indicate a possible increased risk of myocardial infarction in patients taking this drug.¹ The mechanism behind this cardiac dysfunction is currently unknown.

Analysis by the RE-LY (Randomized Evaluation of Long Term Anticoagulant Therapy) trial investigators³ showed that lower doses of dabigatran (110 mg twice daily) had a lower rate of intracranial hemorrhage when compared with warfarin, while a higher dose (150 mg twice daily) had a similar rate. Additionally, the higher-dose dabigatran was superior to warfarin in the annual rate of stroke and systemic embolism. Postulated to by-

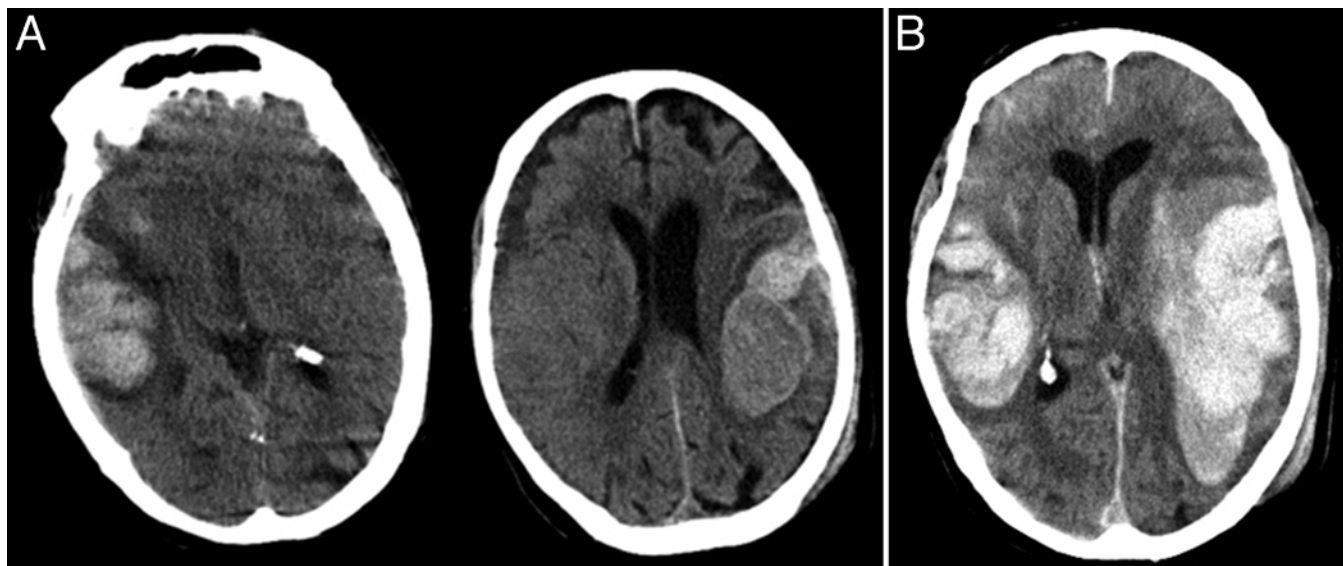


Fig. 2. Noncontrast head CT scans. **A:** Study obtained approximately 2.5 hours postadmission showing significant interval evolution of the patient's intracranial hemorrhage bilaterally. **B:** Study obtained 6 hours postadmission revealing significant further progression of the patient's intracranial hemorrhage.

pass the activated factor VII–tissue factor binding that is integral to initiating coagulation, dabigatran preserves hemostatic protection mechanisms that the brain employs to limit spontaneous intracranial hemorrhage.³ In addition to its use in stroke and systemic embolism prevention in patients with atrial fibrillation, dabigatran is also currently approved in both Europe and Canada for the prevention and treatment of venous thromboembolism.⁸

There is currently no effective antidote to reverse the anticoagulant effect of dabigatran in the event of an emergency. As a direct thrombin (factor II) inhibitor, dabigatran exerts its mechanism of action at the very end of the coagulation cascade, and therefore both factor VIIa and fresh-frozen plasma are ineffective as treatment options. One recent randomized clinical trial showed no effect of prothrombin complex concentrate on the anticoagulant effect of dabigatran.² Although recent preclinical trials using murine models have shown that high-dose prothrombin complex concentrate slows the expansion of intracerebral hematoma, direct clinical applicability is limited by a lack of neurological outcome monitoring and appropriate safety and efficacy studies.¹⁰ Additionally, prothrombin complex concentrate is not currently available at our institution and so was not used in this case. Because dabigatran is primarily renally excreted, dialysis is an alternative for drug clearance and can remove approximately 35%–60% of the drug in 2–3 hours.⁴ Dialysis was not considered at the time of initial presentation of our patient, and by the time of his deterioration it was too late to implement effectively.

While dabigatran can alter the activated prothrombin time, this has not been shown to be an effective measure of systemic anticoagulation. The thrombin time is the most sensitive laboratory test to assess the effects of dabigatran in urgent clinical situations. In addition, the thrombin time is a rapidly obtained laboratory value that should be readily available in the inpatient and emergency de-

partment setting. Our patient presented with a markedly elevated thrombin time, which could have been serially monitored to assess his response to dabigatran had his clinical course been prolonged.

As stated, recombinant factor VII administration failed to slow the progression of our patient's intracranial hemorrhage. Dabigatran is different from warfarin, whose inhibitory effect on clotting factors II, VII, IX, and X can be reversed by fresh-frozen plasma, vitamin K, and factor VII. In the absence of an effective antidote, treating physicians should consider obtaining a thrombin time and instituting early use of dialysis in conjunction with judicious use of intravenous fluid administration to maintain renal perfusion. Caution is necessary, however, because patients with atrial fibrillation have tenuous intravascular volume status, and fluid overload can lead to worsening heart function. Dabigatran is only the first of several direct thrombin inhibitors that may enter clinical use (Table 1), and these agents will likely have similar risks for catastrophic progression of traumatic injuries.

Conclusions

New direct coagulation factor inhibitors, such as dabigatran, have demonstrated superior stroke and systemic embolism prevention without the burdensome monitoring and drug-drug interactions seen with agents such as warfarin. Although dabigatran has been shown to have a lower incidence of major bleeding than warfarin, in the event of catastrophic hemorrhage no effective reversal agent exists. Neurosurgeons are likely to encounter this clinical scenario more frequently with the increased use of dabigatran and other similar drugs. Preclinical and early clinical trials have thus far failed to yield an effective reversal agent for these medications, and new treatments are certainly needed. The authors stress that a high index of suspicion for catastrophic hemorrhage is

TABLE 1: List of direct thrombin inhibitors*

Drug Name	Brand Name	FDA Regulatory Status
dabigatran etexilate	Pradaxa	approved for prevention of stroke & blood clots in patients w/ nonvalvular atrial fibrillation (2010)
Argatroban	Argatroban	approved for prophylaxis or treatment of thrombosis in patients w/ HIT (2000) & for use during PCI in patients w/ or at risk for HIT (2002)
lepirudin	Refludan	approved for the treatment of HIT Type II (1998)
bivalirudin	Angiomax	approved for use w/ aspirin & provisional glycoprotein inhibitors as anticoagulation therapy for patients undergoing a PCI (2005)
desirudin	Iprivask	approved for the prevention of DVT in patients undergoing elective hip replacement (2003); tested in randomized trial in patients w/ HIT
AZD0837		tested in a randomized Phase II study for patients w/ atrial fibrillation; compared w/ vitamin K antagonists in nonrandomized Phase II study in patients w/ nonvalvular atrial fibrillation
M118		tested in Phase II study for use as anticoagulant in patients w/ stable coronary artery disease undergoing a PCI

* DVT = deep venous thrombosis; HIT = heparin-induced thrombocytopenia; PCI = percutaneous coronary intervention.

required in patients taking dabigatran so that the limited management options can be evaluated and implemented without potentially life-threatening delay.

Disclosure

The authors report no conflict of interest concerning the materials or methods used in this study or the findings specified in this paper.

Author contributions to the study and manuscript preparation include the following. Conception and design: all authors. Acquisition of data: Garber, Sivakumar. Analysis and interpretation of data: Garber, Sivakumar. Drafting the article: Garber, Sivakumar. Critically revising the article: all authors. Reviewed submitted version of manuscript: all authors. Approved the final version of the manuscript on behalf of all authors: Schmidt.

Acknowledgment

The authors thank Kristin Kraus, M.Sc., for her masterful help in preparing this paper.

References

1. Connolly SJ, Ezekowitz MD, Yusuf S, Eikelboom J, Oldgren J, Parekh A, et al: Dabigatran versus warfarin in patients with atrial fibrillation. **N Engl J Med** **361**:1139–1151, 2009
2. Eerenberg ES, Kamphuisen PW, Sijpkens MK, Meijers JC, Buller HR, Levi M: Reversal of rivaroxaban and dabigatran by prothrombin complex concentrate: a randomized, placebo-controlled, crossover study in healthy subjects. **Circulation** **124**:1573–1579, 2011
3. Eikelboom JW, Wallentin L, Connolly SJ, Ezekowitz M, Healey JS, Oldgren J, et al: Risk of bleeding with 2 doses of dabigatran compared with warfarin in older and younger patients with atrial fibrillation: an analysis of the randomized evaluation of long-term anticoagulant therapy (RE-LY) trial. **Circulation** **123**:2363–2372, 2011
4. Ganetsky M, Babu KM, Salhanick SD, Brown RS, Boyer EW: Dabigatran: review of pharmacology and management of bleeding complications of this novel oral anticoagulant. **J Med Toxicol** **7**:281–287, 2011
5. Hart RG, Benavente O, McBride R, Pearce LA: Antithrombotic therapy to prevent stroke in patients with atrial fibrillation: a meta-analysis. **Ann Intern Med** **131**:492–501, 1999
6. Hart RG, Pearce LA, Aguilar MI: Meta-analysis: antithrombotic therapy to prevent stroke in patients who have nonvalvular atrial fibrillation. **Ann Intern Med** **146**:857–867, 2007
7. Medi C, Hankey GJ, Freedman SB: Stroke risk and antithrombotic strategies in atrial fibrillation. **Stroke** **41**:2705–2713, 2010
8. Stangier J, Stähle H, Rathgen K, Fuhr R: Pharmacokinetics and pharmacodynamics of the direct oral thrombin inhibitor dabigatran in healthy elderly subjects. **Clin Pharmacokinet** **47**:47–59, 2008
9. Teasdale G, Jennett B: Assessment of coma and impaired consciousness: a practical scale. **Lancet** **2**:81–84, 1974
10. Zhou W, Schwarting S, Illanes S, Liesz A, Middelhoff M, Zorn M, et al: Hemostatic therapy in experimental intracerebral hemorrhage associated with the direct thrombin inhibitor dabigatran. **Stroke** **42**:3594–3599, 2011

Manuscript submitted November 23, 2011.

Accepted February 6, 2012.

Please include this information when citing this paper: published online March 6, 2012; DOI: 10.3171/2012.2.JNS112132.

Address correspondence to: Richard H. Schmidt, M.D., Ph.D., Department of Neurosurgery, University of Utah, 175 North Medical Drive East, Salt Lake City, Utah 84132. email: neuropub@hsc.utah.edu.