

## **Delayed Vasospasm after Removal of a Skull Base Meningioma**

### **Protrahierte Vasospasmen nach Entfernung eines Schädelbasismeningeoms**

**P. Tausky, R. Kalra, W. T. Couldwell**

**University of Utah, Department of Neurosurgery**

**Salt Lake City, United States**

#### **Correspondence**

**Prof. W. T. Couldwell**

**University of Utah Medical Center**

**Department of Neurological Surgery**

**175 N. Medical Drive East**

**84132-2303 Salt Lake City**

**United States**

**Tel.: + 1 / 801 / 581 6908**

**Fax: + 1 / 801 / 581 4385**

**neuropub@hsc.utah.edu**

## Introduction

Cerebral vasospasm is a well-known clinical entity associated with subarachnoid hemorrhage and traumatic brain injury [1,2]. In rare instances, vasospasm has been reported to occur after tumor resections, more specifically, after skull base tumor removal [3-5]. We report a rare case of a patient presenting with delayed clinical and angiographic vasospasm, 14 days after removal of a hyperostotic meningioma of the right sphenoid wing.

## Case Report

A 41-year-old right-handed woman presented with a four-month history of progressive proptosis of her right eye and headaches. On neurological examination, she had a right eye proptosis of 3 mm and diplopia on right gaze. All other cranial nerve, motor, sensory, and cerebellar examinations were unremarkable. Computed tomography (CT) and magnetic resonance (MR) imaging demonstrated a right sphenoid wing meningioma with severe hyperostosis that involved the lateral orbital wall, the superior roof of the orbit, and the middle cranial fossa floor (Figure 1).

The tumor was approached via a right pterional craniotomy. Upon visual inspection, it was extensively hyperostotic and invasive. Thus, the orbital roof, the lateral orbital wall, most of the anterior clinoid, and the sphenoid wing had to be removed using the combination of a high-speed drill and ultrasonic aspirator (Sonopet) in an extradural fashion. Intradurally, residual meningioma was removed from the lateral wall of the cavernous sinus. The optic canal was unroofed using a high-speed drill to further decompress the optic nerve. A temporoparietal fascial flap was mobilized to

supplement the duraplasty. The pathological analysis of the tumor confirmed it was a WHO grade I meningioma.

Postoperatively, the patient's proptosis and diplopia resolved completely. Because an early postoperative CT scan showed subarachnoid hemorrhage within the Sylvian fissure (Figure 2), the patient was monitored for the development of vasospasm by means of transcranial Doppler sonography. The patient was hydrated for several days postoperatively. There was no indication of the development of cerebral vasospasm, and the patient was discharged on the eighth postoperative day.

Fourteen days after the patient's surgery, she developed acute left-sided arm weakness and complete left leg paralysis. CT imaging showed interval development of patchy areas of low density involving the right temporal lobe tip and right frontal lobe. MR imaging showed a wedge-shaped area of diffusion deficit involving the right frontal, parietal, and temporal lobes with large surrounding ischemic penumbra (Figure 3). MR angiography imaging revealed near-total occlusion of the right M1 segment of the middle cerebral artery (MCA). Minimal flow was maintained to the inferior branches of the right MCA. Severe right MCA (M2>M1) and left A1-A2 vasospasm as well as mild right A1-A2 and right distal internal carotid artery (ICA) vasospasm were noted on angiography on postoperative day 15 (Figure 4). The vasospasm was successfully treated with intra-arterial infusion of verapamil into the right anterior cerebral artery (ACA) and right MCA segments, with mild improvement of the right distal ICA and left ACA segments (Figure 5). This was repeated after the initial treatment on postoperative day 15, with daily intra-arterial spasmolytic treatment until postoperative day 19 with the last intervention on postoperative day 22, after which vasospasm subsided. In addition

to intra-arterial verapamil, the patient was started on hypervolemic-hypertensive-hemodilution therapy. Treatment with intra-arterial verapamil was repeated twice in the following days for sustained severe cerebral vasospasm. The patient remained hospitalized for 13 days, and upon discharge to the rehabilitation center, she continued to have a left central facial nerve paralysis, but had regained 4/5 strength in her left upper extremity and 3/5 strength in her left lower extremity. At 6-month follow-up, she had regained 5/5 strength in both upper and lower extremities.

## Discussion

Cerebral vasospasm after tumor resection (a pituitary adenoma and an acoustic adenoma) was first described in 1960 by Krayenbuhl [6]. Although cerebral vasospasm after tumor resection is exceedingly rare, with fewer than 50 instances reported in the literature, it can cause neurological disability, which is just as disastrous as subarachnoid vasospasm [3,5,7-12].

The exact pathophysiology underlying the occurrence of cerebral vasospasm, particularly after aneurysmal rupture, remain unclear, but the time frame in which vasospasm develops is well established and seems to follow a consistent pattern [13]. Characteristically, aneurysmal vasospasm develops on the third post-hemorrhagic day, with a peak of vasospasm around the seventh day and slow reduction of vasospasm after day 14 [14]. In our patient, however, vasospasm was not identified until the patient acute left-sided arm weakness and complete left leg paralysis 14 days after tumor removal.

Several risk factors have been associated with vasospasm after skull base surgery [9]. Most commonly, postoperative blood in the basal cisterns and direct vessel manipulation are identified as possible causative mechanisms of cerebral vasospasm. In fact, the subarachnoid hemorrhage in the Sylvian cistern postoperatively raised our suspicion about the possible development of vasospasm, and hence the patient was monitored postoperatively on days 6 and 7 by transcranial Doppler sonography. The development of delayed cerebral vasospasm on the 14th postoperative day after tumor resection, however, is highly unusual, especially with normal blood flow velocities recorded at days 6 and 7.

Since vasospasm can be associated with cocaine use [15], a drug screening test was undertaken, but the results were negative. Dehydration is another well-known risk factor for the development of vasospasm, yet we had no indication that this was the case in our patient [16]. Vasospasm may also develop in the context of an acute infection, particularly meningitis. Because our patient exhibited no signs or symptoms of meningitis, no lumbar puncture was undertaken. Finally, products of blood breakdown are the most frequent cause of vasospasm, and this may well be the case in our patient, too, as evidenced by the clot in the Sylvian cistern [17].

This case poses questions regarding the correct treatment and monitoring of affected patients, in particular whether all patients with postoperative blood in the basal cisterns should be monitored and for how long. In their large series of 470 patients who underwent skull base tumor resection, Bejjani et al. [3] reported that only nine patients, or 1.9%, developed symptomatic vasospasm. Although this is an exceedingly rare occurrence, monitoring can be done noninvasively by transcranial Doppler sonography.

Doppler sonography may not always correlate with the presence of clinical vasospasm, however, as in our case where a reduction in flow velocity was in fact followed by clinical worsening. Also, the best timing for Doppler monitoring remains unclear, particularly whether this should extend beyond the seventh postoperative day, when vasospasm is expected to be at its peak [18]. In fact, transcranial Doppler was performed on days 6 and 7 in our patient, without suspicion of vasospasm or increased flow velocities, after which the patient was discharged home.

The delayed manner in which vasospasm manifested itself in our patient without prior indications is highly unusual, and questions regarding optimal management of these patients cannot be answered based on this single experience. We believe, however, that our case raises important questions regarding the pathophysiology and causes of vasospasm and recognizing the possibility of such an occurrence is of importance for the treating physician.

## References

1. Kassell NF, Torner JC, Jane JA, Haley EC, Jr., Adams HP. The International Cooperative Study on the Timing of Aneurysm Surgery. Part 2: Surgical results. *J Neurosurg* 1990;73:37-47
2. Martin NA, Patwardhan RV, Alexander MJ, Africk CZ, Lee JH, Shalmon E, Hovda DA, Becker DP. Characterization of cerebral hemodynamic phases following severe head trauma: hypoperfusion, hyperemia, and vasospasm. *J Neurosurg* 1997;87:9-19
3. Bejjani GK, Sekhar LN, Yost AM, Bank WO, Wright DC. Vasospasm after cranial base tumor resection: pathogenesis, diagnosis, and therapy. *Surg Neurol* 1999;52:577-583; discussion 583-584
4. Aoki N, Origitano TC, al-Mefty O. Vasospasm after resection of skull base tumors. *Acta Neurochir (Wien)* 1995;132:53-58
5. Alzubair M, Africk C. Cerebral vasospasm after resection of an esthesioneuroblastoma: case report and literature review. *Surg Neurol* 2007;68:322-328; discussion 328
6. Krayenbuhl H. Beitrag zur Frage des cerebralen angiospastischen Insultes. *Schweiz med Wochenschr* 1960;90:961-965
7. Chang SD, Yap OW, Adler JR, Jr. Symptomatic vasospasm after resection of a suprasellar pilocytic astrocytoma: case report and possible pathogenesis. *Surg Neurol* 1999;51:521-526; discussion 526-527

8. Lee TT, Ragheb J, Bruce JC, Altman N, Morrison G. Diffuse cerebral vasospasm with ischemia after resection of a cerebellopontine angle primitive neuroectodermal tumor in a child. *Pediatr Neurosurg* 1998;29:300-303
9. Bejjani GK, Duong DH, Kalamarides M, Ziyal I, Sullivan BJ. Cerebral vasospasm after tumor resection. A case report. *Neurochirurgie* 1997;43:164-168
10. Kusunose M, Fukuda O, Saito T, Takaku A, Endo S. [Diffuse cerebral artery vasospasm following total resection of posterior fossa meningioma: a case report]. *No Shinkei Geka* 1997;25:953-957
11. Itoyama Y, Goto S, Miura M, Kuratsu J, Ushio Y, Matsumoto T. Intracranial arterial vasospasm associated with pituitary apoplexy after head trauma--case report. *Neurol Med Chir (Tokyo)* 1990;30:350-353
12. Hyde-Rowan MD, Roessmann U, Brodkey JS. Vasospasm following transsphenoidal tumor removal associated with the arterial changes of oral contraception. *Surg Neurol* 1983;20:120-124
13. Dorsch NW, King MT. A review of cerebral vasospasm in aneurysmal subarachnoid haemorrhage Part I: Incidence and effects. *J Clin Neurosci* 1994;1:19-26
14. Wu CT, Wong CS, Yeh CC, Borel CO. Treatment of cerebral vasospasm after subarachnoid hemorrhage--a review. *Acta Anaesthesiol Taiwan* 2004;42:215-222
15. Conway JE, Tamargo RJ. Cocaine use is an independent risk factor for cerebral vasospasm after aneurysmal subarachnoid hemorrhage. *Stroke* 2001;32:2338-2343



16. Harrod CG, Bendok BR, Batjer HH. Prediction of cerebral vasospasm in patients presenting with aneurysmal subarachnoid hemorrhage: a review. *Neurosurgery* 2005;56:633-654; discussion 633-654
17. Zabramski JM, Spetzler RF, Bonstelle C. Chronic cerebral vasospasm: effect of volume and timing of hemorrhage in a canine model. *Neurosurgery* 1986;18:1-6
18. Seiler R, Grolimund P, Huber P. Transcranial Doppler sonography. An alternative to angiography in the evaluation of vasospasm after subarachnoid hemorrhage. *Acta Radiol Suppl* 1986;369:99-102

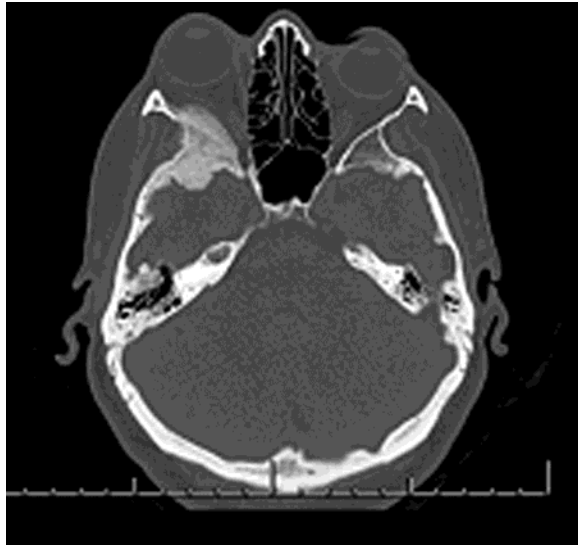


Figure 1: Axial computed tomography scan (bone window) showing the extent of the largely intraosseous meningioma involving the right sphenoid wing and causing proptosis of the right eye

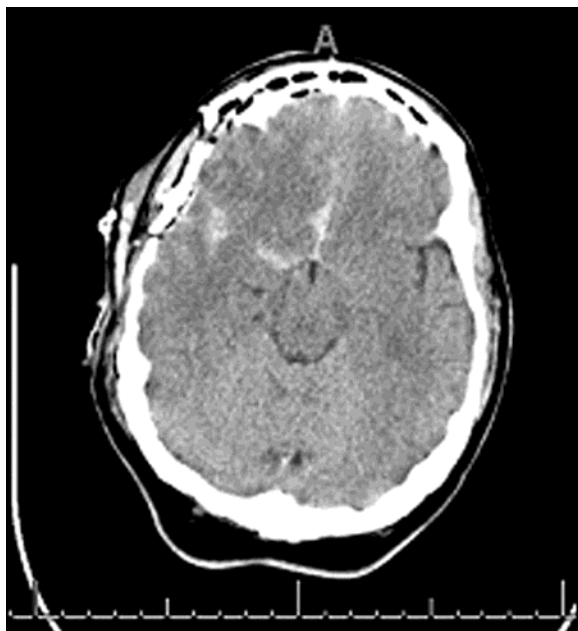

Figure 2: Postoperative axial computed tomography scan showing subarachnoid blood in the basal cisterns and particularly in the right sylvian fissure.

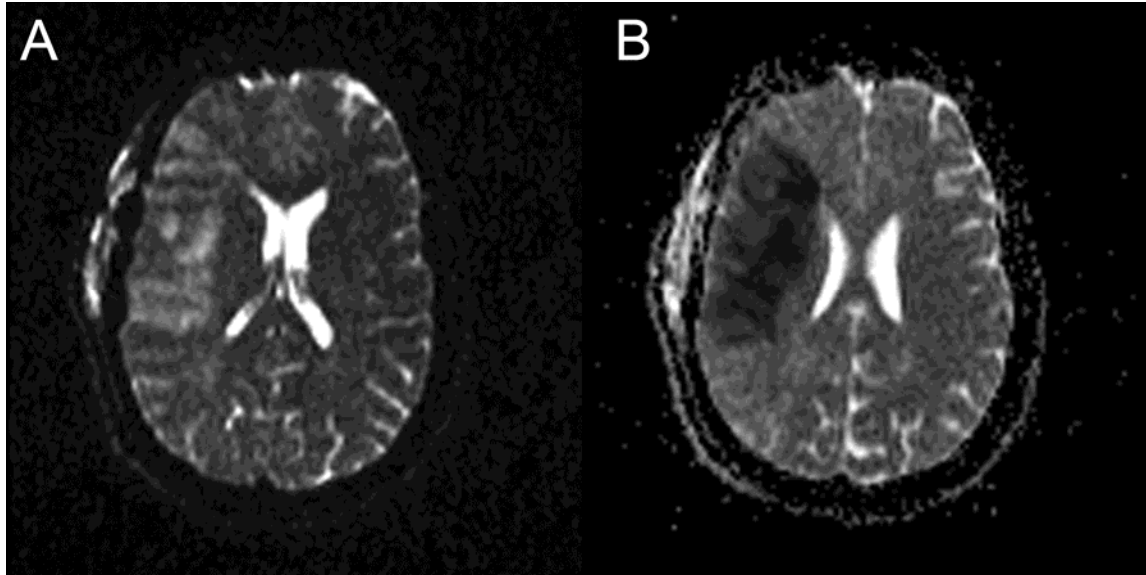


Figure 3: (A) Axial diffusion-weighted imaging showing increased diffusion signal involving the right frontal, parietal, temporal lobes, consistent with ischemia. (B) Corresponding apparent diffusion coefficient map showing low signal consistent with ischemia.

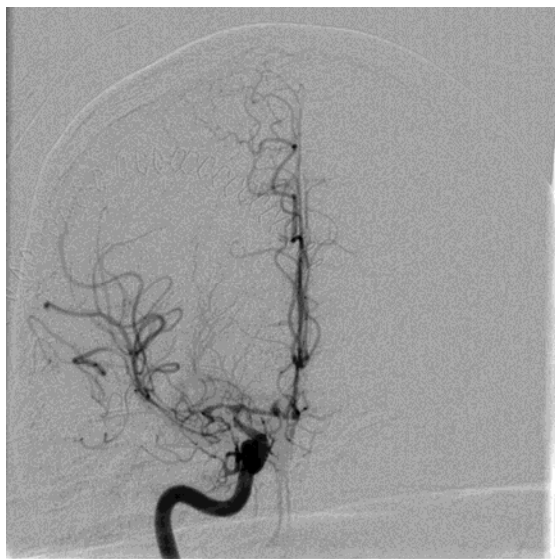

Figure 4: Cerebral angiography showing severe vasospasm of the right middle cerebral artery (M2 and M1 segments) and the distal internal carotid artery.

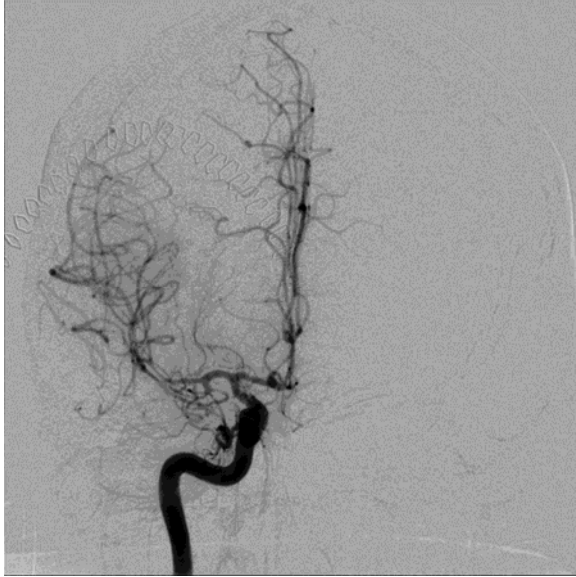

Figure 5: Cerebral angiography after intra-arterial infusion of 25 mg of verapamil into the right internal carotid artery showing improvement of cerebral vasospasm in the affected segments.