

Data Set for the Reporting of Carcinomas of the Hypopharynx, Larynx, and Trachea

Explanations and Recommendations of the Guidelines From the International Collaboration on Cancer Reporting

Tim Helliwell, MD, MB, BChir; Rebecca Chernock, MD; Jane E. Dahlstrom, MBBS, FPAC, PhD, FRCPA; Nina Gale, MD; Jonathan McHugh, MD; Bayardo Perez-Ordoñez, MD, FRCPC; Nick Roland, MBChB, MD, FRCS; Nina Zidar, MD; Lester D. R. Thompson, MD

• **The International Collaboration on Cancer Reporting is a nonprofit organization whose mission is to develop evidence-based, universally available surgical pathology reporting data sets. Standardized pathologic reporting for cancers facilitates improved communication for patient care and prognosis and the comparison of data between countries to progressively improve clinical outcomes. Laryngeal cancers are often accompanied by significant morbidity, although surgical advances (such as transoral endoscopic laser microresection and transoral robotic surgery) provide new alternatives. The anatomy of the larynx is complex, with an understanding of the exact anatomic sites and subsites, along with recognizing anatomic landmarks, being crucial to classification and prognostication. This review outlines the data set developed for the histopathology reporting in *Carcinomas of the Hypopharynx, Larynx and Trachea* and discusses the main elements required and recommended for reporting.**

(*Arch Pathol Lab Med.* 2019;143:432–438; doi: 10.5858/arpa.2018-0419-SA)

This consensus guidance has been developed by the International Collaboration on Cancer Reporting (ICCR) to assist pathologists in consistently describing the features of primary carcinomas of the hypopharynx, larynx, and trachea that are important for patient management. The guidance is based on published evidence of those pathologic features that influence prognosis and the prediction of response to treatment. For guidance on the reporting of neck dissections, mucosal melanoma, and tumors at other sites in the head and neck region, pathologists should refer to other data sets in the ICCR head and neck suite (www.iccr-cancer.org/datasets/published-datasets/head-neck).

The ICCR is a not-for-profit organization founded in 2011 by a collaboration between the College of American Pathologists, the Canadian Association of Pathologists—Association Canadienne des Pathologistes in association with the Canadian Partnership Against Cancer, the Royal Colleges of Pathologists of Australasia and the United Kingdom, joined in 2013 by the European Society of Pathologists, and followed by the American Society of Clinical Pathology and the Royal College of Physicians of Ireland, Faculty of Pathology as sustaining members. The mission of the ICCR is to create a globally applicable series of data sets for the histopathologic reporting of cancers in order to support a common standard of reporting and to promote synoptic reporting practices as an aid to effective communication within clinical teams. Toward this end, additional sponsoring organizations for the head and neck series included the North American Society of Head and Neck Pathology; American Academy of Oral and Maxillofacial Pathology; the British Society for Oral and Maxillofacial Pathology; and the International Association of Oral and Maxillofacial Pathologists.

CLINICAL BACKGROUND

Squamous cell carcinomas (SCCs) of the hypopharynx and larynx are uncommon malignancies, usually arising from dysplastic surface epithelium in patients older than 60 years, with the risk factors of smoking and alcohol.¹ A small proportion of carcinomas appears to be related to transcriptionally active human papillomavirus infection; the

Accepted for publication October 1, 2018.

Published online November 30, 2018.

From the Department of Cellular Pathology, University of Liverpool, Liverpool, United Kingdom (Dr Helliwell); the Department of Pathology and Immunology, Washington University School of Medicine, Saint Louis, Missouri (Dr Chernock); ANU College of Health and Medicine, Anatomical Pathology, ACT Pathology, Canberra Hospital, Woden, Australia (Dr Dahlstrom); Institute of Pathology, Faculty of Medicine, University of Ljubljana, Ljubljana, Slovenia (Drs Gale and Zidar); the Department of Pathology, Michigan Medicine – University of Michigan, Ann Arbor (Dr McHugh); the Department of Anatomic Pathology, Laboratory Medicine Program, University Health Network, Toronto, Ontario, Canada (Dr Perez-Ordoñez); the Department of ENT-Head and Neck Surgery, University Hospital Aintree, Liverpool, United Kingdom (Dr Roland); and the Department of Pathology, Southern California Permanente Medical Group, Woodland Hills Medical Center, Woodland Hills (Dr Thompson).

The authors have no relevant financial interest in the products or companies described in this article.

Corresponding author: Lester D. R. Thompson, MD, Department of Pathology, Southern California Permanente Medical Group, Woodland Hills Medical Center, 5601 De Soto Avenue, Woodland Hills, CA 91365 (email: Lester.D.Thompson@kp.org).

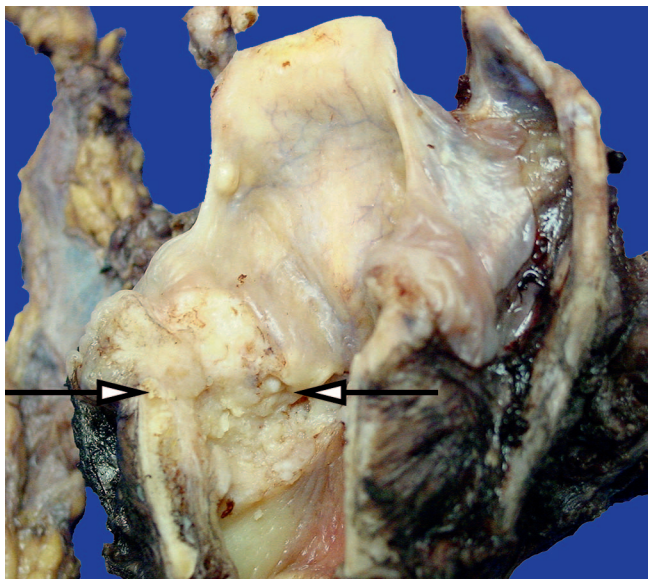


Figure 1. A total laryngectomy has been performed for a transglottic (arrows) squamous cell carcinoma (Courtesy of Jason C. Fowler, PA-C).

prognostic significance of this is not known at these sites.² The treatment of patients is modified according to patient factors (age, comorbidity) and tumor stage, and includes options for radiation therapy and chemotherapy.^{3,4} Preservation laryngeal surgery is an option with early disease (stage I/II) and can be used in highly selected advanced tumors. Transoral endoscopic laser microresection (TLM) and transoral robotic surgery are further treatment options.⁵ Open partial laryngeal surgery (laryngofissure cordectomy, vertical partial laryngectomy, supracricoid laryngectomy) is less frequently used owing to the availability of TLM. More advanced tumors (stage III/IV disease) treated by surgery are likely to need a total laryngectomy (Figure 1), usually with postoperative radiotherapy.

Initial biopsy will confirm the diagnosis and may determine the type of treatment. Resection reports inform the assessment of the accuracy of preoperative imaging and clinical examination. Pathologic staging provides the most accurate evaluation of prognosis and will influence the need for adjuvant treatment.

This article highlights selected data elements and provides additional explanation and discussion on their inclusion in the surgical pathology ICCR *Carcinomas of the Hypopharynx, Larynx and Trachea: Histopathology Reporting Guide*.⁴⁵

METHODS

The Dataset Steering Committee of the ICCR invites each of the founding/sustaining organizations to nominate pathologists with a special interest in the specific topic area to serve on the Dataset Authoring Committee (DAC), chaired by a series champion. Nominees are usually pathologists who have contributed to national data sets and who ardently support synoptic cancer reporting. The DAC is facilitated by the ICCR staff and most work is done by teleconference. Initial review of the nationally commissioned data sets (Australasian, United Kingdom, and North America) seeks alignment of the data. The DAC considers the published evidence and determines whether the criteria are reporting core data (normally required for prognosis and prediction) or noncore data (recommended to be included in a comprehensive report but where impact on patient management is uncertain or lacks evidence). Evidentiary support for core

Table 1. Summary of Core and Noncore Data Elements for Carcinomas of the Hypopharynx, Larynx, and Trachea

Core Elements (Required)	Noncore Elements (Recommended)
Operative procedure	Neoadjuvant therapy
Specimens submitted	
Specimen dimensions	
Tumor site	
Tumor focality	
Tumor dimensions	Tumor thickness
Histologic tumor type	
Tumor grade	
Extent of invasion	Pattern of invasive front
Perineural invasion	
Lymphovascular invasion	
Margin status	Coexistent pathology
Pathologic staging	Ancillary studies

elements was at level III-2 or above, but when such data were lacking, expert opinion was accepted and reasons were stated.

Each of the data elements is accompanied by an explanatory note, linked by hypertext to the published data sets. The data sets have had wide consultation, initially among the authors of all head and neck tumor data sets, and subsequently via open consultation through the ICCR Web site. Comments received through the consultation are reviewed by the DAC and each comment is accepted or rejected in a transparent, open process. The Dataset Steering Committee provides oversight of the responses to consultation and hosts publication on the ICCR Web site as an interactive form with linked notes.

Presentation of data items on the proforma as constrained lists provides the potential for structured data capture and coding. Where appropriate, options are provided for free-text comments and additional detail. A balance is reached between overspecifying the number of data elements in order to be comprehensive and providing a number of data points that is achievable and serves the needs of all users and cancer registries.

DATA SET ELEMENTS AND EXPLANATORY NOTES

The core and noncore data elements are summarized in Table 1.

Information on Previous Treatment

Information on the clinical background leading to receipt of a specimen will assist the pathologist in correctly interpreting the pathologic findings. This information, specifically the details of any neoadjuvant therapy, is regarded as noncore data, as they are not generated by the pathologist. The histologic extent of response to previous treatment (fibrosis and necrosis) is not currently an important guide to future management but may be recorded in a free-text report as an estimate of the percentage of tumor volume showing a particular feature.

Operative Procedure and Specimen(s) Submitted

The nature of the operative procedure affects the level of detail that can be provided in the histopathology report (Table 2). Diagnostic biopsies rarely allow consideration of more than the type of invasive carcinoma and the presence or absence of dysplasia.

The nature of the specimens submitted (site and type) assists the pathologist in the description of the specimen

Table 2. Data Elements for Operative Procedure and Type of Specimen

Operative procedure
Biopsy (excisional, incisional)
Resection
Other
Type of specimen
Trachea
Hypopharynx
Laryngopharyngectomy
Other
Larynx
Endolaryngeal excision
Transoral laser resection
Supraglottic laryngectomy
Supracricoid laryngectomy
Total laryngectomy
Vertical hemilaryngectomy
Partial laryngectomy
Other

and the selection of appropriate blocks of tissue to obtain information relevant to cancer staging.^{6,7} The complexity of the anatomy of the larynx may be better understood by references to figures produced for the ICCR data set (Figures 2 and 3). For classification purposes, the larynx is divided into 3 regions, each of which has several subsites.

The supraglottis (Figure 4) includes the epiglottis, aryepiglottic folds, arytenoids, ventricular bands (false cords), and laryngeal ventricles. The glottis extends from the ventricle to approximately 1 cm below the free level of the true vocal cord and includes the vocal cords and anterior and posterior commissures. The subglottis (Figure 5) extends from approximately 1 cm below the level of the true vocal cord to the inferior rim of the cricoid cartilage.

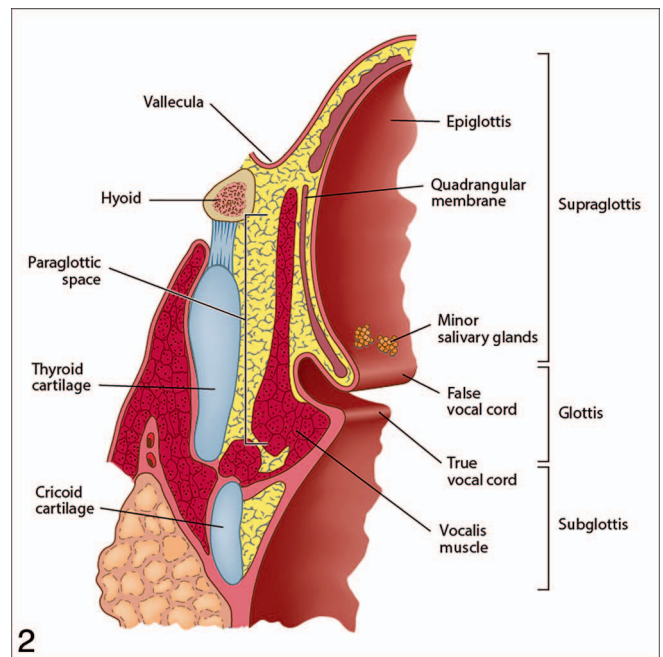
The hypopharynx includes the left and right piriform sinuses, which expand around the sides of the larynx and lie between the larynx and the thyroid cartilage; the lateral and posterior hypopharyngeal walls; and the postcricoid region extending from the level of the arytenoid cartilages to the inferior border of the cricoid cartilage.

The paraglottic and pre-epiglottic spaces are potential spaces filled with adipose and connective tissues. The paraglottic space lies anterolateral and deep to the ventricles and saccules, and the pre-epiglottic space is anterior to the base of the epiglottis.

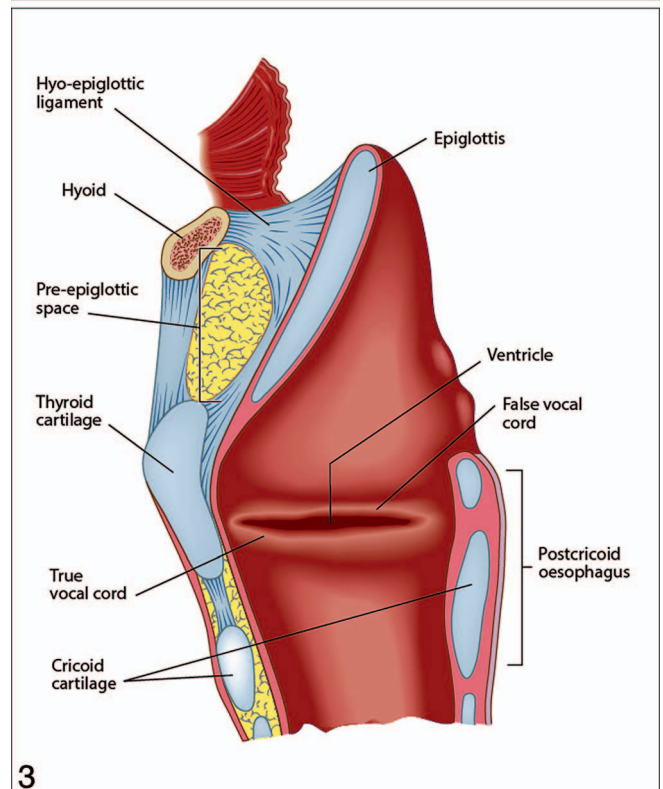
Tumor Site and Focality

The site (and/or subsite) of the primary tumor is the main determinant for the use of clinicopathologic staging systems and is recorded according to the nomenclature used by the Union for International Cancer Control (UICC) and American Joint Committee on Cancer (AJCC).^{8,9} For tumors that involve more than 1 site, the principal site of involvement is recorded, acknowledging that this may not be the site of origin (Table 3).

Tumor focality is described as unifocal or multifocal to allow the pathologist to describe the complexity of the disease in some patients.



2



3

Figure 2. Coronal section through the larynx to show the main anatomic structures, the subsites, and the paraglottic space. Reproduced with permission from International Collaboration on Cancer Reporting (ICCR).

Figure 3. Sagittal section through the larynx to show the main anatomic structures and the pre-epiglottic space. Reproduced with permission from International Collaboration on Cancer Reporting (ICCR).

Specimen and Tumor Dimensions

The macroscopic dimension (in millimeters) should be recorded unless the histologic extent of tumor is greater. As is common practice, this measurement pragmatically

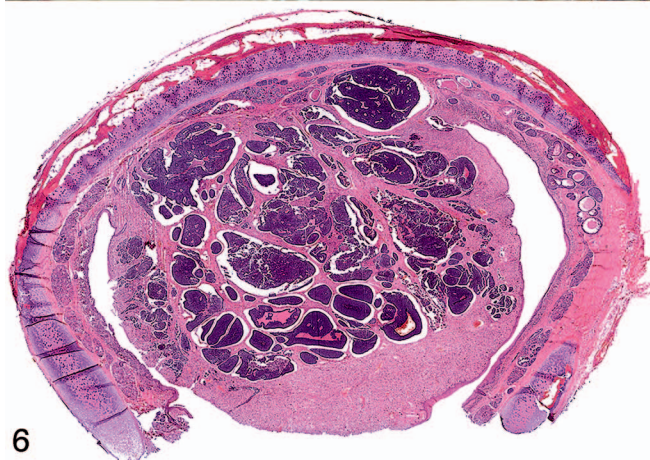
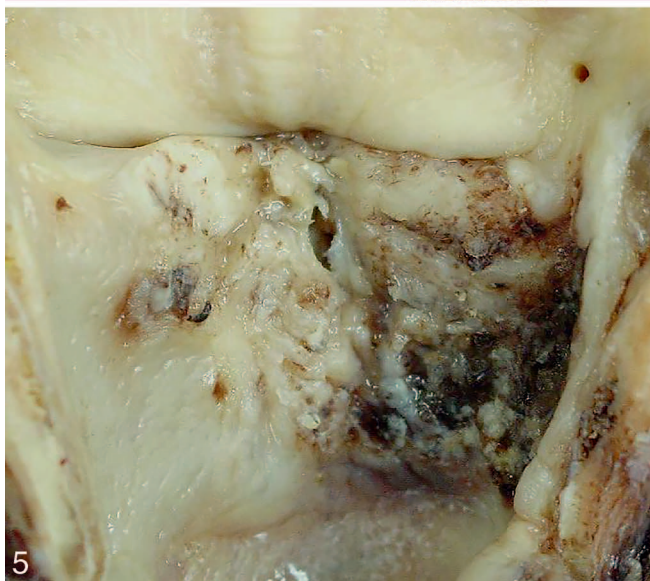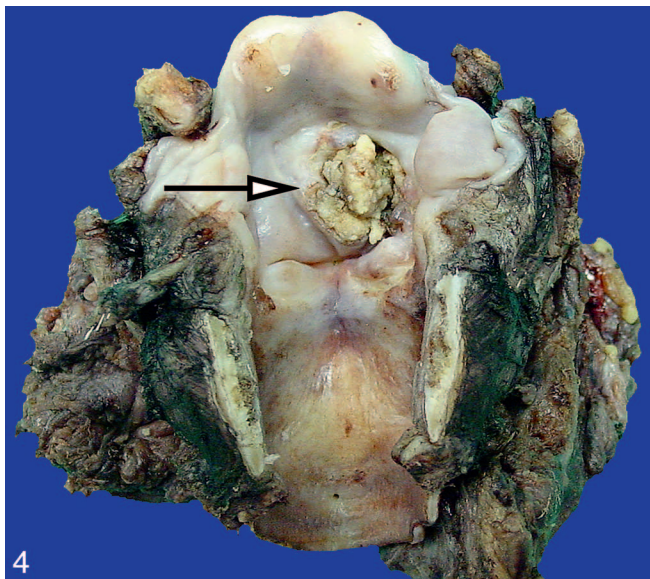


Figure 4. A total laryngectomy has been performed for a supraglottic (arrow) squamous cell carcinoma (Courtesy of Jason C. Fowler, PA-C).

Figure 5. A gross view of a tumor, which is confined to the subglottic region (Courtesy of Jason C. Fowler, PA-C).

Trachea	Left, right, midline
Hypopharynx	Left, right, midline
	Piriform sinus
	Postcricoid
	Pharyngeal wall (lateral and/or posterior)
	Other
Supraglottis	Left, right, midline
	Epiglottis
	Aryepiglottic fold(s)
	Arytenoid(s)
	False vocal cord(s)/fold(s)
Glottis	Ventricle(s)
	Left, right, midline
	True vocal cord/fold
	Anterior commissure
Subglottis	Posterior commissure
	Left, right, midline

acknowledges that the dimensions of tissues are affected by fixation and processing. The absolute tumor thickness is noncore for both larynx and hypopharynx, although considered differently in other head and neck subsites (ie, oral cavity).

The maximum dimension of a tumor is a key determinant for staging carcinomas of the hypopharynx,^{8,9} and tumor size is part of a good description for carcinomas of the larynx, allowing comparison with imaging studies, but is not a staging criterion.

Histologic Tumor Type

The histologic type of cancer (Table 4) is recorded by using the value list of the World Health Organization's (WHO) *Classification of Head and Neck Tumours*.¹ Histologic type is important for cancer registration and prognosis and may influence the need for adjuvant treatment. A good prognosis is associated with verrucous and papillary SCCs, while adenosquamous carcinomas tend to have a worse prognosis than conventional and spindle cell SCCs.¹⁰⁻¹² For large cell neuroendocrine carcinomas, irradiation and chemotherapy may be considered in preference to surgery.

Salivary-type carcinomas are described in detail in the ICCR *Carcinomas of the Major Salivary Glands: Histopathology Reporting Guide*,⁴⁶ but minor salivary gland carcinomas, as would arise in the hypopharynx, larynx, and trachea, are reported in this anatomic site data set.

Histologic Tumor Grade

Some of the variants of SCC (basaloid, adenosquamous, and spindle cell) are considered to have intrinsic biological potential and are not graded. Unlike oropharyngeal carcinomas, human papillomavirus status is not a determinant of tumor type or grade, and all conventional SCCs are graded according to the WHO classification as well,

Figure 6. A basaloid squamous cell carcinoma of the larynx is shown to have extension to the adjacent cartilage rings (hematoxylin-eosin, original magnification $\times 10$).

Table 4. World Health Organization Classification of the Histologic Types of the Tumors of the Hypopharynx, Larynx, and Trachea^a

Descriptor	Tumor Type
Malignant surface epithelial tumors	Conventional squamous cell carcinoma
	Verrucous squamous cell carcinoma
	Basaloid squamous cell carcinoma
	Papillary squamous cell carcinoma
	Spindle cell squamous cell carcinoma
	Adenosquamous carcinoma
Neuroendocrine tumors	Lymphoepithelial carcinoma
	Well-differentiated neuroendocrine carcinoma
	Moderately differentiated neuroendocrine carcinoma
Salivary carcinomas	Poorly differentiated neuroendocrine carcinoma (small cell, large cell types)
	Adenoid cystic carcinoma
	Mucoepidermoid carcinoma
	Other

^a Reproduced with permission from World Health Organization (WHO)/International Agency for Research on Cancer (IARC).¹

moderately, or poorly differentiated.^{1,13–18} Although there is interobserver variation, this system is prognostically useful. Pathologists should record the highest grade (poorest differentiation) as a core element.

Extent of Invasion and Pattern of Invasive Front

Pathologists should note that neither the absolute depth of invasion nor the pattern of the invasive front are core data items for carcinomas of the hypopharynx or larynx (Table 5), as there is insufficient evidence of prognostic value. The extent of invasion into the tissue compartments of the larynx (Figure 6) or wall of the hypopharynx is an important criterion for staging.^{8,9,19}

Perineural and Lymphovascular Invasion

Perineural invasion is defined as extension of tumor into the perineural plane between nerve bundles and the perineurium. For this data set, either *intratumoral* or *extratumoral* perineural invasion is regarded as a positive finding. The presence of perineural invasion is a predictor of local recurrence and nodal metastasis and may prompt consideration of adjuvant therapy.^{18,20–25}

The presence of carcinoma within an endothelial-lined space is required to identify lymphovascular invasion. For carcinomas of the larynx and hypopharynx, vascular invasion is a weak predictor of nodal metastasis.^{26,27}

Margin Status

For surgically treated carcinomas, the status of the margins is a predictor of local recurrence and may require

Table 5. Data Elements for Descriptors of Extent of Invasion of Carcinomas of the Larynx

Involves mucosa
Involves paraglottic space
Involves pre-epiglottic space
Partial-thickness invasion of cartilage
Full-thickness invasion of cartilage

consideration of adjuvant therapy.^{28–39} For completeness of description, the margin status should include the distance in millimeters from both invasive and in situ carcinoma (if present) to the closest margin. Pathologists should note that comment on the deep resection margin of a laryngectomy specimen may be nonapplicable unless the tumor extends close to the base of tongue or into the soft tissues of the neck.

A positive margin is one where carcinoma is present at the margin. The definition of a “close margin” varies between published series, typically being regarded as between 3 and 5 mm. The clinical implications of a positive or close margin should be discussed with the surgical team, preferably in a multidisciplinary meeting. For laser resections of glottic carcinomas, even 1 mm may be adequate owing to the thermal damage to tissue at the in situ margin.

Coexistent Pathology and Ancillary Studies

These are noncore data, included to allow pathologists the flexibility to include additional findings, including the results of molecular testing, where the prognostic or predictive significance is presently uncertain.

Pathologic Staging

Pathologic staging is usually performed after surgical resection of the primary tumor and depends on the pathologic documentation of the anatomic extent of disease, whether or not the primary tumor has been completely removed. If a biopsied tumor is not resected for any reason (eg, when technically unfeasible) and if the highest T and N categories or the M category of the tumor can be confirmed microscopically, the criteria for pathologic classification and staging have been satisfied without total removal of the primary cancer.

Staging criteria are provided in Table 6. By preference for ICCR data sets, cancer staging uses the most recent UICC TNM staging (currently 8th version), which reflects the AJCC cancer staging for all criteria except for T3/T4a subglottic carcinomas.^{8,9} In the AJCC system, T3 carcinomas include those limited to larynx with vocal cord fixation and/or invasion of paraglottic space and/or inner cortex of the thyroid cartilage. Normal (T1) or impaired (T2) vocal cord mobility and vocal cord fixation (T3) may only be determined clinically.

Carcinomas of the Trachea

Carcinomas of the trachea are uncommon and are mostly SCCs or carcinomas of salivary type arising from mucosal glands. The literature on these malignancies is confined to case reports and small series of cases.^{40–44} There is insufficient evidence from which to derive robust guidance on the management of these malignancies and neither UICC nor AJCC provide a separate TNM classification. The authors suggest, pragmatically, that pathologists encountering primary tracheal malignancies should report them by using the data set for hypopharyngeal carcinomas. In particular, greatest tumor dimension and depth of invasion should be reported.

CONCLUSIONS

The publication of this data set and explanatory notes should aid pathologists in providing consistent histopathology reports on cancers of the hypopharynx, larynx, and trachea. A synoptic approach will facilitate communication

Table 6. Union for International Cancer Control TNM 8th Edition Staging of Carcinomas of the Hypopharynx and Larynx^{a,b}

pTx	Primary tumor cannot be assessed
pT0	No evidence of primary tumor
pTis	Carcinoma in situ
Hypopharynx	
pT1	Tumor limited to 1 subsite of hypopharynx and/or 2 cm or less in greatest dimension
pT2	Tumor invades more than 1 subsite of hypopharynx or an adjacent site, or measures more than 2 cm but not more than 4 cm in greatest dimension without fixation of hemilarynx
pT3	Tumor measures more than 4 cm in greatest dimension or with fixation of hemilarynx or extension to esophagus mucosa
pT4	Moderately advanced or very advanced local disease
pT4a	Tumor invades thyroid/cricoid cartilage, hyoid bone, thyroid gland, esophagus, or central compartment soft tissue (strap muscles, subcutis)
pT4b	Tumor invades prevertebral fascia, encases carotid artery, or invades mediastinal structures
Supraglottis	
pT1	Tumor limited to 1 subsite of supraglottis with normal vocal cord mobility
pT2	Tumor invades mucosa of more than 1 adjacent subsite of supraglottis or glottis or region outside the supraglottis (eg, mucosa of base of tongue, vallecula, medial wall of piriform sinus) without fixation of the larynx
pT3	Tumor limited to larynx with vocal cord fixation and/or invades any of the following: postcricoid area, pre-epiglottic space, paraglottic space, and/or inner cortex of thyroid cartilage
pT4	Moderately advanced or very advanced local disease
pT4a	Tumor invades through the thyroid cartilage and/or invades tissues beyond the larynx (eg, trachea, soft tissues of neck including deep extrinsic muscle of tongue, strap muscles, thyroid, or esophagus)
pT4b	Tumor invades prevertebral space, encases carotid artery, or invades mediastinal structures
Glottis	
pT1	Tumor limited to the vocal cord(s) (may involve anterior or posterior commissure) with normal mobility
pT1a	Tumor limited to 1 vocal cord
pT1b	Tumor involves both vocal cords
pT2	Tumor extends to supraglottis and/or subglottis and/or with impaired vocal cord mobility
pT3	Tumor limited to the larynx with vocal cord fixation and/or invasion of paraglottic space, and/or inner cortex of thyroid cartilage
pT4	Moderately advanced or very advanced local disease
pT4a	Tumor invades through the outer cortex of the thyroid cartilage and/or invades tissues beyond the larynx (eg, trachea, soft tissues of neck including deep extrinsic muscle of the tongue, strap muscles, thyroid, or esophagus)
pT4b	Tumor invades prevertebral space, encases carotid artery, or invades mediastinal structures
Subglottis	
pT1	Tumor limited to subglottis
pT2	Tumor extends to vocal cord(s) with normal or impaired mobility
pT3	Tumor limited to larynx with vocal cord fixation
pT4	Moderately advanced or very advanced local disease
pT4a	Tumor invades cricoid or thyroid cartilage and/or invades tissues beyond the larynx (eg, trachea, soft tissues of neck including deep extrinsic muscles of the tongue, strap muscles, thyroid, or esophagus)
pT4b	Tumor invades prevertebral space, encases carotid artery, or invades mediastinal structures

Note: For carcinoma of the larynx, normal (T1) or impaired (T2) vocal cord mobility and vocal cord fixation (T3) may only be determined clinically. Pathologic staging is therefore provisional unless the clinical information is available at the time of staging.

^a Reproduced with permission from Union for International Cancer Control (UICC).⁸ In: James D. Brierley, Mary K. Gospodarowicz, Christian Wittekind, eds. *UICC TNM Classification of Malignant Tumours*. 8th ed. New York: Wiley-Blackwell; 2017.

^b The results of lymph node/neck dissection are derived from a separate data set.

with clinicians for patient management and with cancer registries so that outcomes of treatment can be compared equitably within and between countries. The ICCR is supporting initiatives to translate the data sets into languages other than English and for data elements to be included in SNOMED-CT (see www.iccr-cancer.org), enhancing their global application.

There is a commitment to regularly review the ICCR data sets in line with revisions of the *WHO Classification of Tumours* and updates to staging manuals.

The authors would like to express their appreciation to the sponsoring societies and organizations and give special thanks to Fleur Webster and Hannah B. Canlas for their exceptional organizational and editing contributions. The views expressed are those of the authors solely.

References

1. El-Naggar AK, Chan JKC, Grandis JR, Takata T, Slootweg PJ, eds. *WHO Classification of Head and Neck Tumours*. 4th ed. Lyon, France: IARC; 2017. *World Health Organization Classification of Tumours*; vol 9.
2. Torrente MC, Rodrigo JP, Haigentz M Jr, et al. Human papillomavirus infections in laryngeal cancer. *Head Neck*. 2011;33(4):581–586.

3. Jones TM, De M, Foran B, Harrington K, Mortimore S. Laryngeal cancer: United Kingdom National multidisciplinary guidelines. *J Laryngol Otol*. 2016;130(S2):S75–S82.
4. Hall SF, Groome PA, Irish J, O'Sullivan B. Radiotherapy or surgery for head and neck squamous cell cancer: establishing the baseline for hypopharyngeal carcinoma? *Cancer*. 2009;115(24):5711–5722.
5. Ambrosch P. The role of laser microsurgery in the treatment of laryngeal cancer. *Curr Opin Otolaryngol Head Neck Surg*. 2007;15(2):82–88.
6. Helliwell TR. ACP Best Practice No 157: guidelines for the laboratory handling of laryngectomy specimens. *J Clin Pathol*. 2000;53(3):171–176.
7. Lam A. RCPA (The Royal College of Pathologists of Australasia) Web site. Macroscopic Cut-up Manual. 2015. <https://www.rcpa.edu.au/Library/Practising-Pathology/Macroscopic-Cut-Up/Specimen/Head-and-neck/Larynx>. Accessed July 13, 2018.
8. Union for International Cancer Control (UICC). In: Brierley JD, Gospodarowicz MK, Wittekind C, eds. *TNM Classification of Malignant Tumours*. 8th ed. New York: Wiley-Blackwell; 2017.
9. Amin MB, Edge S, Grenne FL, Byrd DR, Brookland RK. *AJCC Cancer Staging Manual*. 8th ed. New York: Springer; 2017.
10. Wenig BM. Squamous cell carcinoma of the upper aerodigestive tract: precursors and problematic variants. *Mod Pathol*. 2002;15(3):229–254.
11. Chute DJ, Stelow EB. Cytology of head and neck squamous cell carcinoma variants. *Diagn Cytopathol*. 2010;38(1):65–80.
12. Lopez F, Williams MD, Cardesa A, et al. How phenotype guides management of non-conventional squamous cell carcinomas of the larynx? *Eur Arch Otorhinolaryngol*. 2017;274(7):2709–2726.
13. Jakobsson PA, Eneroth CM, Killander D, Moberger G, Martensson B. Histologic classification and grading of malignancy in carcinoma of the larynx. *Acta Radiol Ther Phys Biol*. 1973;12(1):1–8.
14. Roland NJ, Caslin AW, Nash J, Stell PM. Value of grading squamous cell carcinoma of the head and neck. *Head Neck*. 1992;14(3):224–229.
15. Kearsley JH, Thomas S. Prognostic markers in cancers of the head and neck region. *Anticancer Drugs*. 1993;4(4):419–429.
16. Snow GB, Annayas A, Vanslooten EA, Bartelink H, Hart AM. Prognostic factors of neck node metastasis. *Clin Otolaryngol Allied Sci*. 1982;7(3):185–192.
17. Henson DE. The histological grading of neoplasms. *Arch Pathol Lab Med*. 1988;112(11):1091–1096.
18. Sethi S, Lu M, Kapke A, Benninger MS, Worsham MJ. Patient and tumor factors at diagnosis in a multi-ethnic primary head and neck squamous cell carcinoma cohort. *J Surg Oncol*. 2009;99(2):104–108.
19. Alkureishi LW, Ross GL, Shoaib T, et al. Does tumor depth affect nodal upstaging in squamous cell carcinoma of the head and neck? *Laryngoscope*. 2008;118(4):629–634.
20. Brandwein-Gensler M, Smith RV, Wang B, et al. Validation of the histologic risk model in a new cohort of patients with head and neck squamous cell carcinoma. *Am J Surg Pathol*. 2010;34(5):676–688.
21. Fagan JJ, Collins B, Barnes L, D'Amico F, Myers EN, Johnson JT. Perineural invasion in squamous cell carcinoma of the head and neck. *Arch Otolaryngol Head Neck Surg*. 1998;124(6):637–640.
22. Miller ME, Palla B, Chen Q, et al. A novel classification system for perineural invasion in noncutaneous head and neck squamous cell carcinoma: histologic subcategories and patient outcomes. *Am J Otolaryngol*. 2012;33(2):212–215.
23. Cooper JS, Pajak TF, Forastiere AA, et al. Postoperative concurrent radiotherapy and chemotherapy for high-risk squamous-cell carcinoma of the head and neck. *N Engl J Med*. 2004;350(19):1937–1944.
24. Bernier J, Dommenege C, Ozsahin M, et al. Postoperative irradiation with or without concomitant chemotherapy for locally advanced head and neck cancer. *N Engl J Med*. 2004;350(19):1945–1952.
25. Stojan P, Ferlito A, Langendijk JA, Silver CE. Indications for radiotherapy after neck dissection. *Head Neck*. 2012;34(1):113–119.
26. Suzuki M, Suzuki T, Asai M, et al. Clinicopathological factors related to cervical lymph node metastasis in a patient with carcinoma of the oral floor. *Acta Otolaryngol Suppl*. 2007;(559):129–135.
27. Poleksic S, Kalwaic HJ. Prognostic value of vascular invasion in squamous cell carcinoma of the head and neck. *Plast Reconstr Surg*. 1978;61(2):234–240.
28. Jacobs JR, Ahmad K, Casiano R, et al. Implications of positive surgical margins. *Laryngoscope*. 1993;103(1, pt 1):64–68.
29. Laramore GE, Scott CB, Schuller DE, et al. Is a surgical resection leaving positive margins of benefit to the patient with locally advanced squamous cell carcinoma of the head and neck: a comparative study using the intergroup study 0034 and the Radiation Therapy Oncology Group head and neck database. *Int J Radiat Oncol Biol Phys*. 1993;27(5):1011–1016.
30. Zelefsky MJ, Harrison LB, Fass DE, Armstrong JG, Shah JP, Strong EW. Postoperative radiation therapy for squamous cell carcinomas of the oral cavity and oropharynx: impact of therapy on patients with positive surgical margins. *Int J Radiat Oncol Biol Phys*. 1993;25(1):17–21.
31. Slootweg PJ, Hordijk GJ, Schade Y, van Es RJJ, Koole R. Treatment failure and margin status in head and neck cancer: a critical view on the potential value of molecular pathology. *Oral Oncology*. 2002;38(5):500–503.
32. Bradley PJ, MacLennan K, Brakenhoff RH, Leemans CR. Status of primary tumour surgical margins in squamous head and neck cancer: prognostic implications. *Curr Opin Otolaryngol Head Neck Surg*. 2007;15(2):74–81.
33. Laskar SG, Agarwal JP, Srinivas C, Dinshaw KA. Radiotherapeutic management of locally advanced head and neck cancer. *Expert Rev Anticancer Ther*. 2006;6(3):405–417.
34. Langendijk JA, Ferlito A, Takes RP, et al. Postoperative strategies after primary surgery for squamous cell carcinoma of the head and neck. *Oral Oncol*. 2010;46(8):577–585.
35. Hinni ML, Ferlito A, Brandwein-Gensler MS, et al. Surgical margins in head and neck cancer: a contemporary review. *Head Neck*. 2013;35(9):1362–1370.
36. Brandwein-Gensler M, Teixeira MS, Lewis CM, et al. Oral squamous cell carcinoma: histologic risk assessment, but not margin status, is strongly predictive of local disease-free and overall survival. *Am J Surg Pathol*. 2005;29(2):167–178.
37. Alicandri-Ciufelli M, Bonali M, Piccinini A, et al. Surgical margins in head and neck squamous cell carcinoma: what is 'close'? *Eur Arch Otorhinolaryngol*. 2013;270(10):2603–2609.
38. Ansarin M, Santoro L, Cattaneo A, et al. Laser surgery for early glottic cancer: impact of margin status on local control and organ preservation. *Arch Otolaryngol Head Neck Surg*. 2009;135(4):385–390.
39. Liao CT, Chang JT, Wang HM, et al. Analysis of risk factors of predictive local tumor control in oral cavity cancer. *Ann Surg Oncol*. 2008;15(3):915–922.
40. Gaissert HA, Grillo HC, Shadmeh MB, et al. Long-term survival after resection of primary adenoid cystic and squamous cell carcinoma of the trachea and carina [discussion in *Ann Thorac Surg*. 2004;78(6):96–97]. *Ann Thorac Surg*. 2004;78(6):1889–1896.
41. Junker K. Pathology of tracheal tumors. *Thorac Surg Clin*. 2014;24(1):7–11.
42. Qi D, Feng L, Li J, Liu B, Zhang Q. Primary adenoid cystic carcinoma of the trachea with thyroid invasion: a case report and literature review. *Onco Targets Ther*. 2016;9:6291–6296.
43. Qiu J, Lin W, Zhou ML, Zhou SH, Wang QY, Bao YY. Primary small cell cancer of cervical trachea: a case report and literature review. *Int J Clin Exp Pathol*. 2015;8(6):7488–7493.
44. Huo Z, Meng Y, Wu H, et al. Adenoid cystic carcinoma of the tracheobronchial tree: clinicopathologic and immunohistochemical studies of 21 cases. *Int J Clin Exp Pathol*. 2014;7(11):7527–7535.
45. Helliwell T, Chernock R, Dahlstrom JE, et al. *Carcinomas of the Hypopharynx, Larynx and Trachea: Histopathology Reporting Guide*. 1st ed. Sydney, Australia: International Collaboration on Cancer Reporting; 2018.
46. Seethala RR, Altmani A, Ferris RL, et al. *Carcinomas of the Major Salivary Glands: Histopathology Reporting Guide*. 1st ed. Sydney, Australia: International Collaboration on Cancer Reporting; 2018.