

## Development of surgical site infections despite perioperative antimicrobial therapy in two dogs

*De ontwikkeling van postoperatieve wondinfecties bij twee honden ondanks perioperatieve toediening van antimicrobiële middelen*

<sup>1</sup>A. Lyssens, <sup>1</sup>N. Devriendt, <sup>2</sup>E. Stock, <sup>1</sup>T. Roggeman, <sup>1</sup>H. de Rooster

<sup>1</sup>Small Animal Department

<sup>2</sup>Department of Medical Imaging of Domestic Animals and Orthopedics of Small Animals  
Faculty of Veterinary Medicine, Ghent University  
Salisburylaan 133, B-9820 Merelbeke, Belgium

aurelie.lyssens@ugent.be

### ABSTRACT

Surgical site infections (SSI) are common complications with a prevalence of 0.8 to 18%. Many risk factors, such as patient, environmental and treatment factors can contribute to the development of SSI. Two dogs that developed a SSI after forelimb amputation are discussed. The first dog was presented with an open comminuted intra-articular fracture of the right elbow. The second dog was diagnosed with a soft-tissue sarcoma at the right elbow. Perioperative cefazolin was administered in both patients. Only in the first patient, antimicrobial therapy was continued in the postoperative period. Both dogs developed an SSI within four to five days postoperatively. Yet, prophylactic antimicrobials can help to prevent SSI, provided that the correct antimicrobial is used at the correct dose, at the right time and given IV. Factors, such as hypothermia, violating the Halsted's principles and the number of people present in the theater may increase the risk of SSI. Besides the meticulous use of antimicrobials, perioperative management is thus also important in SSI prevention.

### SAMENVATTING

Postoperatieve wondinfecties zijn een veel voorkomend probleem. Een prevalentie van 0,8 tot 18% wordt beschreven in de diergeneeskunde. Factoren met betrekking tot de patiënt, omgeving en chirurgie hebben een invloed op het ontstaan van postoperatieve wondinfecties.

Twee honden die na voorpootamputatie een postoperatieve wondinfectie ontwikkelden, worden besproken. De eerste hond werd aangeboden met een complexe open intra-articulaire fractuur van de rechterelleboog. De andere hond onderging een amputatie omwille van een wekedelensarcoma ter hoogte van de rechterelleboog. In beide gevallen werd er perioperatief cefazoline toegediend. Bij de eerste patiënt werd het antibioticum postoperatief verdergezet. De andere hond kreeg geen postoperatief antibioticum. Beide honden ontwikkelden na vier tot vijf dagen een postoperatieve wondinfectie. De aanwezigheid van verschillende risicofactoren kan de kans op postoperatieve wondinfecties doen toenemen. Naast het correct gebruik van antimicrobiële middelen speelt ook het vermijden van deze risicofactoren een belangrijke rol in de preventie van postoperatieve wondinfecties.

### INTRODUCTION

Surgical site infections (SSI) are infections that occur at the level of a surgical wound. They usually occur within fourteen to thirty days of the procedure (or within one year if an implant is left in place) (Sal-

kind and Rao, 2008; Yap et al., 2015). The reported incidence of SSI in veterinary medicine ranges from 0.8 to 18% (Boothe and Boothe, 2015; Walker et al., 2016; Hayes et al., 2017). The source of bacterial contamination can be endogenous and/or exogenous. A reduced quality of life, increased morbidity and in-

**Table 1. Surgical wound classification system (adapted from Vasseur et al., 1988).**

Classification of surgery	Description	Infection rate	Use of prophylactic antimicrobials?
<b>Clean</b>	A surgery in which no inflammation is encountered and in which the respiratory, alimentary, genital or infected urinary tract are not entered	1.6- 6%	Controversial, depends on the individual situation. When the consequences of a surgical wound infection would be severe or when surgical implants are inserted, prophylactic antimicrobials should be given as well when surgery is expected to take longer than 90 minutes
<b>Clean-contaminated</b>	Surgeries, in which the respiratory, alimentary, genital, or infected urinary tract are entered under controlled conditions without major contamination. Clean surgeries with a minor break in sterile surgery technique are also included	4.5- 10%	Controversial, depends on the individual situation. The duration of anesthesia and surgery, and the immune status of the patient are factors that may help to determine whether or not antimicrobials should be given prior to surgery
<b>Contaminated</b>	Surgeries with major breaks in sterile technique or gross spillage from the alimentary tract and incisions, in which acute non-purulent inflammation is encountered	6-29%	Indicated. The antimicrobial should be selected based on the expected type of bacteria in the surgical field or based on the results of the culture and the susceptibility tests
<b>Dirty</b>	Surgeries, in which viscera are perforated or surgeries with fecal contamination	10-20%	Therapeutic use of antimicrobials is indicated. The selected drugs should have a broad-spectrum and should be changed once bacterial culture and susceptibility test results are known to narrow the spectrum

creased mortality are some of the consequences for patients with an SSI (Kurz et al., 1996; Hayes et al., 2017; Gonzalez et al., 2017). Surgical site infections also result in significantly higher costs for the owner caused by prolonged hospitalization, more intensive postoperative care and frequent control visits (Nicoll et al., 2014).

The risk of SSI correlates directly with preoperative, perioperative and postoperative factors (Barie, 2002; Nelson, 2011). Some reported risk factors in veterinary medicine are signalment, presence of endocrinopathies, perioperative hypoxia and hypothermia, skin antisepsis, number of persons in the operation room, duration of anesthesia and surgery, presence of drains and inappropriate use of antimicrobials (Howe and Boothe, 2006; Nelson, 2011). Wrong type, dose or timing of the antimicrobial therapy, administration of prophylactic antimicrobials in clean or clean-contaminated procedures, or postoperative prophylaxis longer than twenty-four hours may facilitate SSI development and it may result in antimicrobial resistance and alterations in bacterial flora, leading to changes in colonization (Prospero et al., 2011; Aiken et al., 2015; Boothe and Boothe, 2015; Pratesi et al., 2015).

Prophylactic antimicrobials are administered prior to surgery to prevent a non-established infection (Howe and Boothe, 2006; Boothe and Boothe, 2015).

Recommendations are based on a surgical classification system (Vasseur et al., 1988; Mishriki et al., 1990; Nelson, 2011) (Table 1). Besides their prophylactic use, antimicrobials can also be used therapeutically. Therapeutic use of antimicrobials is indicated in patients undergoing contaminated or dirty surgical procedures and in case an infection is present at the surgical site or in a body cavity (Howe and Boothe 2006; Nelson, 2011; Bratzler et al., 2013).

In this paper, two dogs are described that underwent forelimb amputation and subsequently developed an SSI.

## CASE HISTORIES

### Case 1

A fourteen-year-old, male, intact Fox terrier was hit by a car. At initial presentation to the referring veterinarian, the dog was very painful and it was sedated intramuscularly (IM) with a combination of medetomidine and ketamine. In the right axillary region, a wound was observed. Radiographs disclosed a comminuted open intra-articular fracture of the right elbow. The wound was flushed with saline and a protective bandage was applied. Prior to referral, fluid

therapy was installed and amoxicillin, meloxicam and methadone were intravenously (IV) administered.

Within six hours after the original trauma, the dog was presented to the Small Animal Department of the Faculty of Veterinary Medicine (Ghent University). On physical examination, the dog was mildly sedated, hypothermic (35.8°C), and mildly increased lung sounds were present on auscultation. Oral mucosae were sticky, capillary refill time was two seconds and heart rate was one hundred beats per minute. Hair was entangled in the wound in the right axilla and damaged muscles were visualized in the depth; no active bleeding was present.

Fluid therapy was increased to correct for 5% dehydration (Ringer lactate, Hartmann®, Baxter 5 mL/kg/h IV). Methadone (Comfortan, Eurovet Animal Health B.V., Bladel, the Netherlands, 0.1 mg/kg IV) and cefazolin (Cefazoline Sandoz, Sandoz S.A., Vilvoorde, Belgium, 20 mg/kg IV) were installed. General blood examination revealed a significant increase of alanine aminotransferase and hyperglycemia. Radiographs of the thorax and additional views of the right elbow were obtained. The thoracic radiographs were within normal limits. An open comminuted intra-articular fracture of the right elbow with multiple, severely displaced ulnar and radial fragments was visualized (Figure 1). Because of the complexity of the fracture, fracture reduction and osteosynthesis were likely to result in a poor outcome concerning elbow joint function. Therefore, right front limb amputation was advised.

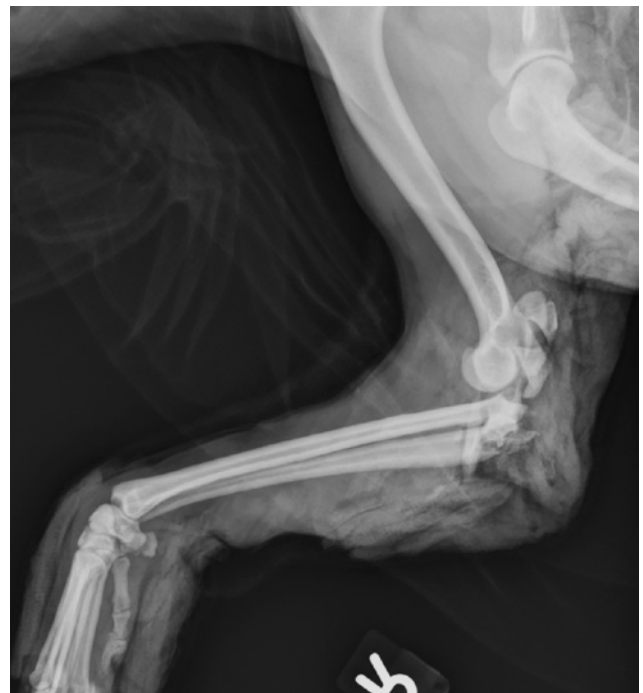
Ten hours after the insult, the dog was premedicated with a combination of dexmedetomidine (Dexdomitor, Orion Corporation, Espoo, Finland 5 µg/kg IV) and methadone (0.2 mg/kg IV), induced with propofol (Propovent Multidose, Abbott Laboratories, Berkshire, United Kingdom, 4-6 mg/kg IV to effect), and anesthesia was maintained with isoflurane vaporized in oxygen. Since the last cefazolin (20 mg/kg IV) administration was two hours prior to surgery, it was not repeated at the time of induction. During anesthesia, Ringer lactate (5 mL/kg/h IV) was administered as well as a constant rate infusion (CRI) of fentanyl (Fentanyl, Eurovet Animal Health B.V., Bladel, the Netherlands, 5 µg/kg/h IV with a loading dose of 2 µg/kg) for intraoperative analgesia. The plexus brachial nerves were infiltrated with bupivacaine (Marcaine 0.5%, AstraZeneca, Brussels, Belgium, 2 mL) before surgical dissection.

A standard forelimb amputation with removal of the scapula was performed. Prior to closure of the skin, an active drain (Multipurpose drain 10 French, Mila) was placed. A bandage made with a synthetic padding and cohesive bandage material was applied. The total duration of anesthesia and surgery was two hours and twenty-five minutes and one hour and forty-five minutes, respectively.

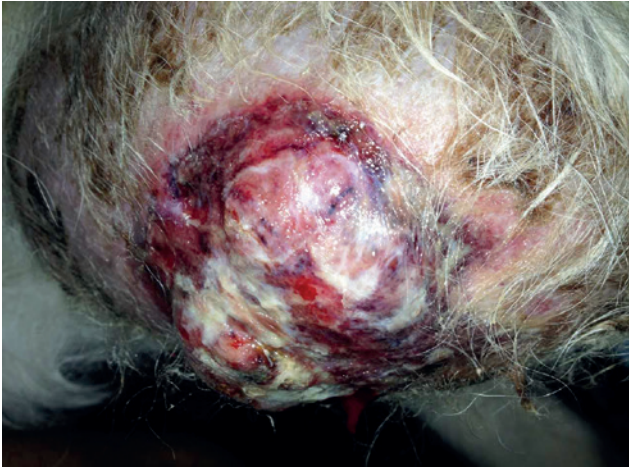Postoperatively, the dog was hospitalized. Anal-

gesia consisted initially of IV methadone (0.2 mg/kg every four hours) and was changed the next day to tramadol hydrochloride (Tramadol EG, Eurogenerics S.A., Brussels, Belgium, 3 mg/kg orally every eight hours) combined with meloxicam (Metacam, Boehringer Ingelheim Vetmedica, Ingelheim/Rhein, Germany, 0.1 mg/kg orally once daily). Intravenous cefazolin (20 mg/kg every eight hours) was continued until the day after surgery when it was changed to the oral administration of cephalexin (Rilexine 300mg, Virbac, Carros, France, 15 mg/kg twice daily). One day after surgery, the dog was able to walk with limited support. The drain was minimally productive and was removed two days after surgery. The incision remained dry and clean. The dog was discharged. Antimicrobial therapy was prescribed for another seven days and analgesia for another five days.

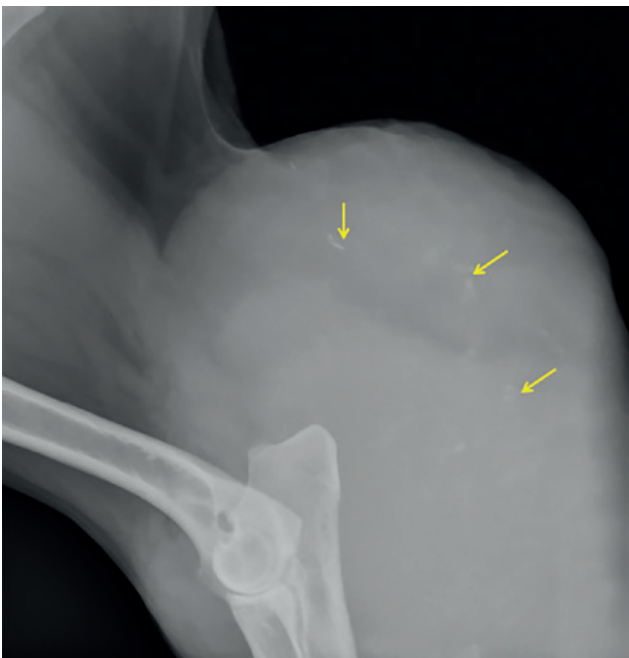Five days after surgery, the dog developed total anorexia and the owners noticed discharge from the wound. On physical examination, wound dehiscence and necrotic skin edges were noticed. The wound was debrided and flushed with saline (Vetivex, Dechra Regulatory B.V., Bladel, the Netherlands). A sample was taken for culture and sensitivity testing, and a silicone sheet impregnated with honey (Tulle, L-Mesitran, Theo Manufacturing B.V., Maastricht, the Netherlands), covered by non-adhesive compresses (Melolin, Smith & Nephew, Hull, United Kingdom) was applied. Bacteriological examination showed the presence of multiple colonies of *Escherichia coli* (*E.*



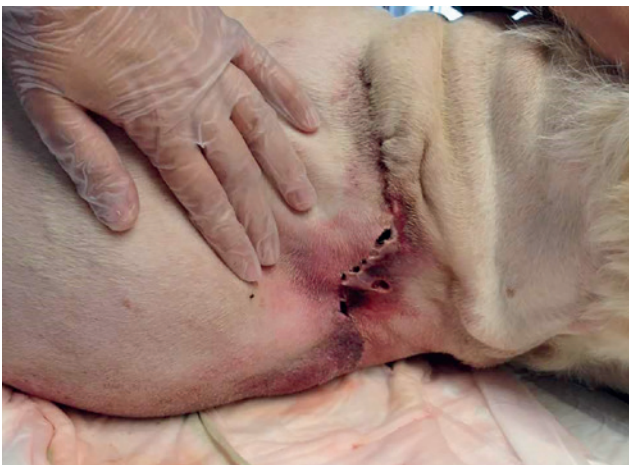**Figure 1. Mediolateral radiograph of the right front leg. There is a large, heterogeneous soft tissue swelling, containing multiple gas opacities surrounding the right front leg. An open comminuted intra-articular fracture of the proximal radius and ulna is present.**



**Figure 2.** Mass at the right elbow of a thirteen-year-old, male, castrated crossbreed dog.



**Figure 3.** Right-left lateral projection of the right elbow. A large soft tissue swelling containing mineralized opacities (arrows), centered on the caudal aspect of the elbow is present.



**Figure 4.** Wound dehiscence in case 2, four days post-operatively.

*coli*). Antimicrobial therapy was changed to amoxicillin clavulanic acid, based on the antibiogram (Kesium, Ceva Santé Animale B.V., Brussels, Belgium, 12.5 mg/kg orally twice daily). Delayed primary wound closure was performed after resection of the wound edges and curettage of the wound bed six days after wound dehiscence. Antimicrobial therapy was continued for another ten days; the wound healed without further complications.

## Case 2

A thirteen-year-old, male, castrated crossbreed dog was presented with an eroded mass at the level of the right elbow. The mass had been present for three to four years. The dog was not lame, but its endurance was decreased. The dog had received tramadol hydrochloride and carprofen for four weeks prior to presentation on the Faculty. The referring veterinarian performed fine-needle aspirates nine days prior to referral and made a tentative diagnosis of a synovial cell sarcoma. Because of continued sero-hemorrhagic oozing from the puncture sites, a protective bandage was placed. A week later, the mass eroded at a different site and a large amount of bloody discharge was evacuated. On physical examination, the dog was alert but calm. An enlarged prescapular lymph node was noticed at the right side. A large soft tissue mass with extensive central necrosis was present caudal to the right elbow (Figure 2).

General blood examination revealed mild leukocytosis, mild monocytosis and mild neutrophilia, as well as very mild hypoalbuminemia. Fine-needle aspirates of the mass were repeated but they were not diagnostic.

A mediolateral radiograph of the right elbow revealed a large soft tissue swelling caudal to the elbow. The mass had a heterogeneous appearance with the presence of multiple small mineralized opacities. There were no signs of bony involvement (Figure 3). Thoracic radiographs were free of metastasis, and front limb amputation was advised.

Premedication consisted of methadone (0.2 mg/kg IV). Midazolam (0.2mg/kg IV) was administered just prior to induction with propofol (1.5 mg/kg IV to effect). Isoflurane vaporized in oxygen was used to maintain anesthesia. Thirty minutes prior to surgery, cefazolin (20 mg/kg IV) was administered, and it was repeated once, two hours after its first administration. During surgery, Ringer lactate was administered at 5 mL/kg/h as well as a CRI of fentanyl (5 µg/kg/h with a loading dose of 2 µg/kg) to obtain intraoperative analgesia. Additionally, the brachial plexus was infiltrated with lidocaine (Xylocaine 2%®, Astra Zeneca, Brussels, Belgium, 2 mL).

Amputation of the right front leg and type of postoperative bandage were performed as described before, but no drain was placed. The total duration of the anesthesia was three hours and twenty-five

minutes; the total duration of surgery was two hours and forty minutes. The entire right forelimb, including the axillary and prescapular lymph nodes, was sent for histology. The mass was diagnosed as a soft tissue sarcoma grade two, with no evidence of metastasis in the lymph nodes.

Postoperatively, analgesia was provided with methadone (0.2 mg/kg IV every four hours) and carprofen (Rimadyl, Zoetis S.A., Louvain-la-Neuve, 2 mg/kg orally, every twelve hours).

Although the dog was reluctant to walk, he was discharged two days after surgery. A small zone of dehiscence, as well as inflammation of the skin around the surgical incision were present. A new bandage was placed using a synthetic padding and cohesive bandage material. Carprofen (2 mg/kg orally, twice daily) was prescribed for another seven days and tramadol hydrochloride (3 mg/kg orally, every eight hours) for five days.

Four days postoperatively, the bandage was soaked by fluid discharge; the wound had dehisced at the distal half of the suture line (Figure 4). The owners went to the referring veterinarian and a swab for culture and sensitivity testing was taken. A honey dressing was placed and systemic antimicrobial therapy with amoxicillin-clavulanic acid and enrofloxacin was installed. One day later, the dog was presented at the Small Animal Department of Ghent University. Wound debridement was performed and samples for cytology were taken. On cytology, several intracellular bacteria were detected. An antimicrobial compress based on nanocrystalline silver (Acticoat, Smith & Nephew, Hull, United Kingdom) was placed within the wound and the skin was loosely apposed. Bacteriological examination showed the presence of numerous colonies of *Enterococcus faecalis* and *Enterobacter cloacae* complex. Antimicrobial therapy was continued and consisted of only amoxicillin clavulanic acid since both types of bacteria showed resistance to enrofloxacin.

Three days later, the antimicrobial compress was removed. Cytology of the wound bed was repeated after rinsing the wound with saline. Neutrophils and a small number of macrophages were seen; intracellular bacteria were no longer detected. Secondary wound closure was performed after debridement of the wound edges and curettage of the wound bed. Amoxicillin clavulanic acid was given once more after the revision surgery and then stopped. Three days after wound closure, the dog was discharged. Recovery was uneventful and seven months after the revision surgery, the owner reported the dog to be in perfect health.

## DISCUSSION

Both dogs described underwent forelimb amputation for pathology at the level of the elbow. Amputa-

tion in a dog with an open elbow fracture is considered a contaminated surgery, whereas surgery in a dog with an eroded skin tumor is categorized as clean-contaminated. In case of contaminated or dirty surgeries or when preoperative infection is present, perioperative antimicrobial treatment is therapeutic rather than prophylactic (Zanetti et al., 2001; Howe and Booth, 2006; Nelson, 2011). In clean-contaminated cases, antimicrobial prophylaxis might be considered in an attempt to reduce the risk of SSI (Nicholson et al., 2002; Turk et al., 2015). Administration of prophylactic antimicrobials is not always indicated, as several prospective studies have reported no significant decrease in SSI when prophylactic antimicrobials were administered in clean or clean-contaminated surgeries (Vasseur et al., 1985; Brown et al., 1997; Daude-Lagrave et al., 2001).

The ideal antimicrobial prophylaxis should fulfil some conditions. First, the antimicrobial agent must be safe. The product associated with the lowest grade of toxicity and side effects must be chosen if more than one can be administered for prophylactic use (Polk and Christmas, 2000). Secondly, the antimicrobial should be based on the location and type of surgery and the expected pathogens (Weber et al., 2008; Willard and Schulz, 2012). However, antimicrobials do not need to be active against every type of bacteria that is present in the surgical wound, since not every organism results in SSI (Waddell and Rotstein, 1994; Weed et al., 2003). In companion animals, many bacteria found in SSI are opportunistic bacteria that are part of the normal flora of the patient. They only harm the patient if the host defense is impaired (Stull and Weese, 2015). Mainly *Staphylococcus aureus*, *Staphylococcus pseudintermedius*, *E. coli* and other *Staphylococcus* spp. are cultured from surgical sites (Howe and Boothe, 2006; Turk et al., 2015; Verwilghen and Singh, 2015). In the first dog, *E. coli* was isolated; in the second, *Enterococcus faecalis* and *Enterobacter cloacae* complex. All three bacterial species are part of the gastrointestinal flora in mammals (Hooper, 2004). It is unlikely that the dogs licked the wound since prevention of automutilation was explicitly discussed with the owners at the time of discharge. In both dogs, an Elizabethan collar was placed for fourteen days postoperatively.

It is recommended to choose antimicrobials with a relatively broad spectrum for prophylaxis to avoid the emergence of antimicrobial resistance. Ideally, antimicrobial selection should also be based on published data on the microbiology of common infections in the treated species (Dellinger et al., 1994; Willard and Schulz, 2012). For these reasons, cephalosporins are often used as a prophylactic antimicrobial in dogs and cats (Salkind and Rao, 2011). First-generation cephalosporins, such as cefazolin, are preferred because they are highly effective against pathogens that mostly cause SSI (Ohge, 1999; Weed, 2003; Gonzalez

et al., 2017). Cefazolin is also as effective as second-, third- or fourth-generation cephalosporins if no anaerobic bacteria are expected to be present in the wound. Lastly, first-generation cephalosporins are cheaper than cephalosporins of the other generations (Boothe and Boothe, 2015).

The timing of administration of antimicrobials is important for prophylaxis to be effective (Burke, 1961; Bratzler and Houck, 2005). Intravenous administration of cefazolin thirty to sixty minutes prior to the surgical incision would be ideal (Gonzalez et al., 2017). The IV route guarantees quick and high concentrations of the antimicrobial at the surgical wound (Waddell and Rotstein, 1994; Rosenberg et al., 2008; Boothe and Boothe, 2015). Furthermore, adequate antimicrobial levels in tissue and serum need to be maintained throughout surgery (Polk and Christmas, 2000; Gonzalez et al., 2017). To be efficacious in prophylaxis, the antimicrobial concentrations should exceed the minimal inhibitory concentration (MIC) for the expected pathogens in the surgical field (Tourmousoglou et al., 2008; Yap et al., 2015). In a recent pharmacokinetic study in dogs, an IV dose of cefazolin of 22 mg/kg has been reported to result in effective tissue concentrations for at least three hours of surgery (Gonzalez et al., 2017). In both dogs described, a traditional dose of 20 mg/kg of cefazolin IV was administered prior to surgery. The historical advice of re-dosing the prophylactic antimicrobial in companion-animal surgery every one hour and a half to two hours has been deduced from human pharmacokinetic studies (Verwilghen and Singh, 2015; Yap et al., 2015); in a recent canine study, it has been shown that intraoperative re-dosing of cefazolin is only necessary three hours post incision (Gonzalez et al., 2017).

Prophylactic antimicrobial use should be limited in time. A short duration, less than twenty-four hours after the end of surgery, is recommended (Waddell and Rotstein, 1994; Barie, 2002). In different studies in veterinary medicine, no benefits have been reported of administering postoperative antimicrobials for longer than twenty-four hours (Aiken et al., 2015; Yap et al., 2015). On the contrary, an increased risk of nosocomial infections, increased costs and the development of antimicrobial resistance have been reported (Bratzler and Houck, 2005; Aiken et al., 2015; Pratesi et al., 2015).

Besides the use of prophylactic antimicrobials, the presence of risk factors may influence the development of SSI. The risk to develop SSI was moderately high in both cases since various risk factors described in the literature were present in both cases. Forelimb amputation in dogs is a rather lengthy procedure, and the risk of SSI is positively correlated with the length of anesthesia (Beal et al., 2000; Eugster et al., 2004). Therefore, it is a concern to minimize the non-surgical duration of anesthesia (Eugster et al., 2004). The bandage applied to the unshaved distal leg should ideally

contain a sterile impermeable barrier to prevent bacteria entering the surgical field (Vince et al., 2008). None of the presented dogs had an impermeable layer incorporated in their bandage, but at the time of writing, the application of this barrier was added to the used protocol. During surgery, it is a focus of attention to comply with the principles of Halsted by gentle tissue handling and ensuring proper hemostasis (Barbieri, 2018). Placement of a drain should be considered to prevent seroma formation (Remedies, 1999). However, drains are ideal routes for bacteria to migrate into the surgical wound (Magee et al., 1976). In the first case, an active closed suction drain, instead of a passive drain, was placed to decrease this risk of bacterial migration. Alternatively, an absorbing dressing should cover the distal end of the drain. In both cases, a supportive circumferential bandage was placed around the thorax to prevent seroma formation by applying mild pressure. In the prevention of SSI, it is also important to maintain a normal intraoperative body temperature by using heat pads, forced air devices or hot water gloves (Kurz et al., 1996). Both patients became hypothermic during surgery. Furthermore, the amount of people attending the surgery increases the risk of postoperative problems (Eugster et al., 2004). The more persons present in the operating room, the more bacteria present in the air. It is important to communicate to students and surgical crew to enter (and leave) the operation room only if necessary and as little as possible.

## CONCLUSION

Plenty of perioperative parameters, such as hypothermia, the number of people attending a surgery and violating the principles of Halsted, might facilitate microbial proliferation in surgical wounds. It is important to try to avoid those potential risk factors. In selected cases, the correct use of antimicrobials (correct type, dose, dose interval and IV route) can decrease the risk of SSI but they can never replace aseptic techniques, meticulous tissue handling and/or appropriate wound care.

## REFERENCES

- Aiken, M.J., Hughes, T.K., Abercromby, R.H., Holmes, M.A., Anderson, A.A. (2015). Prospective, randomized comparison of the effect of two antimicrobial regimes on surgical site infection rate in dogs undergoing orthopedic implant surgery. *Veterinary Surgery* 44, 661-667.
- Barbieri, R.L. (2018). Tactics for reducing the rate of surgical site infection following cesarean delivery. *OBG Management* 30 (4), 7-10.
- Barie, P.S. (2002). Surgical site infections: epidemiology and prevention. *Surgical Infections* 3, S9-S21.

- Boothe, D.M., Boothe, H.W. (2015). Antimicrobial considerations in the perioperative patient. *Veterinary Clinics of North America: Small Animal Practice* 45, 585-608.
- Bratzler, D.W., Houck, P.M. (2005). Antimicrobial prophylaxis for surgery: an advisory statement from the National Surgical Infection Prevention Project. *The American Journal of Surgery* 189, 395-404.
- Bratzler, D.W., Dellinger, E.P., Olsen, K.M., Perl, T.M., Auwaerter, P.G., Bolon, M.K., Fish, D.M., Napolitano, L.M., Sawyer, R.G., Slain, D., Steinberg, J.P., Weinstein, R.A. (2013). Clinical practice guidelines for antimicrobial prophylaxis in surgery. *Surgical Infections* 14 (1), 73-156.
- Burke, J.P. (2001). Maximizing appropriate antibiotic prophylaxis for surgical patients: an update from LDS Hospital, Salt Lake City. *Clinical Infectious Diseases* 33 (2), S78-S83.
- Dellinger, E.P., Gross, P.A., Barrett, T.L., Krause, P.J., Martone, W.J., McGowan, J.E., Sweet, R.L., Wenzel, R.P. (1994). Quality standard for antimicrobial prophylaxis in surgical procedures. *Clinical Infectious Diseases* 18, 422-427.
- Eugster, S., Schawalder, P., Gaschen, F., Boerlin, P. (2004). A prospective study of postoperative surgical site infections in dogs and cats. *Veterinary Surgery* 33, 542-550.
- Gonzalez, O.J., Renberg, W.C., Roush, J.K., KuKanich, B., Warner, M. (2017). Pharmacokinetics of cefazolin for prophylactic administration to dogs. *American Journal of Veterinary Research* 78, 695-701.
- Hayes, G., Singh, A., Gibson, T., Moens, N., Oblak, M., Ogilvie, A., Reynolds, D. (2017). Influence of orthopedic reinforced gloves versus double standard gloves on contamination events during small animal orthopedic surgery. *Veterinary Surgery* 46, 981-985.
- Hooper, L.V. (2004). Bacterial contributions to mammalian gut development. *Trends in microbiology* 12, 129-134.
- Howe, L.M., Boothe, H.W. (2006). Antimicrobial use in the surgical patient. *Veterinary Clinics of North America: Small Animal Practice* 36, 1049-1060.
- Kurz, A., Sessler, D., Lenhardt, R. (1996). Perioperative normothermia to reduce the incidence of surgical wound infection and shorten hospitalization. *The New England Journal of Medicine* 334, 1209-1215.
- Magee, C., Rodeheaver, G.T., Golden, G.T., Fox, J., Edgerton, M.T., Edlich, R.F. (1976). Potentiation of wound infection by surgical drains. *The American Journal of Surgery* 131, 547-549.
- Mishriki, S.F., Law, D.J.W., Jeffery, P.J. (1990). Factors affecting the incidence of postoperative wound infection. *Journal of Hospital Infection* 16, 223-230.
- Nelson, L.L. (2011). Surgical site infections in small animal surgery. *Veterinary Clinics of North America: Small Animal Practice* 41, 1041-1056.
- Nicoll, C., Singh, A., Weese, J.S. (2014). Economic impact of tibial plateau leveling osteotomy surgical site infections in dogs. *Veterinary Surgery* 43, 899-902.
- Ohge, H., Takesue, Y., Yokoyama, T., Murakami, Y., Hiyama, E., Yokoyama, Y., Kanehiro, T., Itaha, H., Matsuura, Y. (1999). An additional dose of cefazolin for intraoperative prophylaxis. *The Japanese Journal of Surgery* 29, 1233-1236.
- Polk, H.C., Christmas, A.B. (2000). Prophylactic antibiotics in surgery and surgical wound infections. *The American Surgeon* 66, 105-111.
- Pratesi, A., Moores, A.P., Downes, C., Grierson, J., Maddox, T.W. (2015). Efficacy of postoperative antimicrobial use for clean orthopedic implant surgery in dogs: a prospective randomized study in 100 consecutive cases. *Veterinary Surgery* 44, 653-660.
- Prospero, E., Barbadoro, P., Marigliano, A., Martini, E., D'errico, M.M. (2011). Perioperative antibiotic prophylaxis: improved compliance and impact on infection rates. *Epidemiology and Infection* 139, 1326-1331.
- Remedies, A., (1999). Complications of wound healing. In: Fowler, D., Williams, J.M. (editors). *Manual of Canine and Feline Wound Management and Reconstruction*. First edition, BSAVA, Cheltenham, United Kingdom, pp. 137.
- Rosenberg, A.D., Wambold, D., Kraemer, L., Begley-Keys, M., Zuckerman, S.L., Singh, N., Cohen, M.M., Bennett, M.V. (2008). Ensuring appropriate timing of antimicrobial prophylaxis. *The Journal of Bone and Joint Surgery* 90, 226-232.
- Salkind, A.R., Rao, K.C. (2011). Antibiotic prophylaxis to prevent surgical site infections. *American Family Physician* 83, 587-590.
- Sessler, D.I. (2006). Non-pharmacologic prevention of surgical wound infection. *Anesthesiology Clinics* 24, 279-297.
- Stull, J.W., Weese, J.S. (2015). Hospital-associated infections in small animal practice. *Veterinary Clinics of North America: Small Animal Practice* 45, 217-233.
- Tourmousoglou, C.E., Yiannakopoulou, E.C., Kalapothaki, V., Bramis, J., Papadopoulos, J.S. (2008). Adherence to guidelines for antibiotic prophylaxis in general surgery: a critical appraisal. *Journal of Antimicrobial Chemotherapy* 61, 214-218.
- Turk, R., Singh, A., Weese, J.S. (2015). Prospective surgical site infection surveillance. *Veterinary Surgery* 44, 2-8.
- Vasseur, P.B., Levy, J., Dowd, E., Eliot, J. (1988). Surgical wound infection rates in dogs and cats. *Veterinary Surgery* 17, 60-64.
- Verwilghen, D., Singh, A. (2015). Fighting surgical site infections in small animals: are we getting anywhere? *Veterinary Clinics of North America: Small Animal Practice* 45, 243-276.
- Vince, K.J., Lascelles, B.D.X., Mathews, K.G., Altier, C., Roe, S.C. (2008). Evaluation of wraps covering the distal aspect of pelvic limbs for prevention of bacterial strike-through in an *ex vivo* canine model. *Veterinary Surgery* 37, 406-411.
- Waddell, T.K., Rotstein, O.D. (1994). Antimicrobial prophylaxis in surgery. *Canadian Medical Association Journal* 151, 925-931.
- Walker, M., Singh, A., Nazarali, A., Gibson, T.W.G., Rousseau, J., Weese, J.S. (2016). Evaluation of the impact of methicillin-resistant *Staphylococcus pseudintermedius* biofilm formation on antimicrobial susceptibility. *Veterinary Surgery* 45, 968-971.
- Weber, W.P., Marti, W.R., Zwahlen, M., Misteli, H., Rosenthal, R., Reck, S., Fueglistaler, P., Bolli, M., Trampuz, A., Oertli, D., Widmer, A.F. (2008). The timing of surgical antimicrobial prophylaxis. *Annals of Surgery* 247, 918-926.
- Weed, H.G. (2003). Antimicrobial prophylaxis in the surgical patient. *The Medical Clinics of North America* 87, 59-75.

- Willard, M.D., Schulz, K.S. (2012). Surgical infections and antibiotic selection. In: Fossum, T.W. (editor). *Small Animal Surgery*. Fourth edition, Elsevier, St. Louis, MO, USA, pp. 84-94.
- Wong-Beringer, A., Corelli, R.L., Schrock, T.R., Guglielmo, J. (1995). Influence of timing of antibiotic administration on tissue concentrations during surgery. *The American Journal of Surgery* 169, 379-381.
- Yap, F.W., Calvo, I., Smith, K.D., Parkin, T. (2015). Perioperative risk factors for surgical site infection in tibial tuberosity advancement: 224 stifles. *Veterinary and Comparative Orthopaedics and Traumatology* 3, 199-206.
- Zanetti, G., Giardina, R., Platt, R. (2001). Intraoperative re-dosing of cefazolin and risk for surgical site infection in cardiac surgery. *Emerging Infectious Diseases* 7, 828-831.
- Zelenitsky, S.A., Ariano, R.E., Harding, G.K.M., Silvermann, R.E. (2002). Antibiotic pharmacodynamics in surgical prophylaxis: an association between intraoperative antibiotic concentrations and efficacy. *Antimicrobial Agents and Chemotherapy* 46, 3026-3030.

### EXIT TESTUDO GRAECA

Eind mei werd besloten dat Basjes  
Winterslaap lang genoeg geduurd had.  
We groeven hem uit, veegden de aarde  
Van zijn grijze schild, schudden hem wat,  
Maar kregen hem niet wakker. Waarna  
We hem van aldoor groter hoogte plat  
Op het zeil lieten vallen, telkens  
Iets luider, waarna in het vuilnisvat.

Hendrik van Teylingen  
Amsterdam 1973