

PROF. CHRISTOPHER HAYWARD (Orcid ID : 0000-0003-4036-1890)

DR. BRUNO SCHNEGG (Orcid ID : 0000-0002-7660-6258)

Article type : Review Article

Is It Safe to Irradiate the Newest Generation of Ventricular Assist Devices? A Case Report and Systematic Literature Review.

Giancarlo Spano*1 Emanuel Stutz†1, Olgun Elicin†, Beate Hugi*, Dominik Henzen†, Monika Fürholz*, Monika Wieser*, Daniel Rhyner*, Stephan Dobner*, Maryam Pavlicek-Bahlo*, Desiree Robson‡, James Nadel‡, Christopher Hayward‡, Lukas Hunziker*, Michele Martinelli*, Bruno Schnegg*

* Center for advance heart failure, Department of Cardiology, Inselspital, Bern University Hospital, University of Bern, Switzerland

† Department of Radiation Oncology, Inselspital, Bern University Hospital, University of Bern, Switzerland

‡ Heart Failure and Transplant Unit, Vincent's Hospital, Sydney, New South Wales, Australia.

1 Equal contribution

Corresponding Author : Bruno Schnegg MD, Department of Cardiology, Inselspital Bern, University Hospital, Freiburgstrasse 8, 3010 Bern, bruno.schnegg@insel.ch, TEL :+41 (0)31 632 96 54, FAX : +41 (0)31 632 42 99

Summary of Author contributions:

Giancarlo Spano: Drafting article, Emanuel Stutz: Drafting article, Olgun Elicin: Drafting article, Beate Hugi: Critical revision of article, Dominik Henzen: Critical revision of article, Monika

This article has been accepted for publication and undergone full peer review but has not been through the copyediting, typesetting, pagination and proofreading process, which may lead to differences between this version and the [Version of Record](#). Please cite this article as [doi: 10.1111/AOR.13612](https://doi.org/10.1111/AOR.13612)

This article is protected by copyright. All rights reserved

Fürholz: Critical revision of article, Monika Wieser: Critical revision of article, Daniel Rhyner: Critical revision of article, Stephan Dobner: Critical revision of article, Maryam Pavlicek-Bahlo: Critical revision of article, Desiree Robson: Critical revision of article, James Nadel: Critical revision of article, Christopher Hayward: Critical revision of article, Lukas Hunziker: Critical revision of article, Michele Martinelli: Critical revision of article, Bruno Schnegg, Concept/design and Drafting article

Received: July 1, 2019

Revised: October 4, 2019

ABSTRACT:

An increasing number of mechanical assist devices, especially Left Ventricular Assist Devices (VAD), are being implanted for prolonged periods and as destination therapy. Some VAD patients require radiotherapy due to concomitant oncologic morbidities, including thoracic malignancies. This raises the potential of VAD malfunction via radiation-induced damage. So far, only case reports and small case series on radiotherapy have been published; most of them on HeartMate II™ (HMII, Abbott, North Chicago, IL, USA). Significantly, the effects of irradiation on the HeartMate 3™ (HM3, Abbott, North Chicago, IL, USA) remain undefined, despite the presence of controller components engineered within the pump itself.

We report the first case of a patient with a HM3 who successfully underwent stereotactic hypofractionated radiotherapy due to an early stage non-small-cell lung cancer. The patient did not suffer from any complications; including toxicity or VAD malfunction.

Based on this case report and on published literature, we think that performing radiotherapy after VAD implantation with the aid of a multidisciplinary team could be performed, but more in-vitro and cases series are needed to reinforce this statement.

Keywords: Ventricular assist device, Radiotherapy, **HeartMate 3™**, Non-small-cell lung cancer

INTRODUCTION

The proportion of patients with VAD as destination therapy, bridge to decision as well as the number of older people with VAD is increasing(1). Seventy-two% of VAD implantation between 2013 and 2016 were undertaken in patients older than 50 years and only 25% of this population were ultimately listed for heart transplantation(2). As the population of patients with VAD is getting older and their “lifetime on pump” is increasing, the number of patients developing malignancies is expected to rise(3). In addition, advanced heart failure itself is associated with a higher incidence of cancer(4). In one series, 7% (8 of 118) of patients implanted with a VAD were subsequently diagnosed with neoplasia within the next few years(5). In addition, cancer treatments themselves can lead to advanced heart failure,(6) and patients who suffer or have suffered from cancer cannot be listed for heart transplantation until confirmation of remission and stratification of risk of recurrence has been established,(7) which demands oncologic treatment with curative intent. These patients with severe heart failure and potentially curable or slowly developing neoplasia (with a life expectancy of more than two years) may be considered for VAD implantation(8). For those patients with at unacceptably high risk from invasive surgery and stage I non-small-cell lung cancer (NSCLC) or patients refusing surgery, radiotherapy is the standard of care(9).

While the commonest VADs implanted worldwide, HeartMate 3™ (HM3, Abbott, IL) and HeartWare HVAD™ (Medtronic, MN), are both centrifugal-axial flow pumps, only the HM3 has sensors and memory storage within the implanted pump(10).The susceptibility of the HM3 and its internal controller components to irradiation is unknown.

Previous experience from other cardiac implantable electronic devices (CIEDs) suggests that irradiation can induce device malfunction caused by alterations in the electronic circuit,(11) principally on memory storage components (typically in the complementary metal oxide semiconductors)(12). For this reason, direct irradiation of the device is avoided. Most guidelines and manufacturers recommend a threshold dose of 200-400 cGy for CIEDs, although, there is no proven threshold dose or linear relationship regarding dose and radiation-induced damage(13), with even low dose scatter radiation possibly leading to life-threatening loss of device function (stochastic effect). For photon beam energies above 10 MV the neutron production is enhanced. Therefore photon beams with six to ten MV should be preferred(13,14). In modern linear accelerators, electromagnetic fields are well shielded and therefore do not contribute to CIED failures(15).

Case report

We report the case of a 60-year-old female patient with doxorubicin induced cardiomyopathy secondary to adjuvant therapy for an invasive ductal carcinoma of her right breast 12 years prior. Despite optimal drug therapy for heart failure, mitral valve clipping for severe secondary mitral valve insufficiency and the implantation of a resynchronization and defibrillator device (CRT-D), the patient remained symptomatic of her heart failure. During the pre-heart transplantation assessment, a peri-hilar mass in the middle lobe, 10 - 11 mm, was identified and biopsied, revealing a non-small-cell lung cancer (adenocarcinoma). In the staging positron emission tomography – computed tomography (PET/CT) only local disease was found, with no lymph node or systemic metastases. Based on the 8th edition of the American Joint Committee on Cancer (AJCC) TNM classification (Tumor size, Lymph Nodes affected, Metastases), this corresponds to a stage IA2 (cT1b cN0 cM0) with an expected 1, 3 and 5 years overall survival (OS) of 83.4%, 56.6%, and 41.2% based on a meta-analysis of 40 trials with a comparable treatment(16).

Before treatment planning, a new cardiac decompensation led to significant deterioration of patient's haemodynamic. After careful multidisciplinary evaluation, a semi-urgent implantation of a HM3 VAD was carried out.

After evaluation of the possible treatment strategies, curatively intended radiotherapy was deemed to be the optimal treatment modality. The possibility of a concomitant surgical removal of the tumour during the implantation of the pump and other surgical options were discussed between thoracic and heart surgeons but rejected due to the proximity of the tumor and the need of anticoagulation after the VAD implantation.

Three months after VAD implantation, we proceeded with planned radiotherapy. Prior to the radiotherapy, tumor staging was repeated with PET/CT, showing stable disease. Subsequently, 3-dimensional radiotherapy planning was undertaken aiming to maximally protect the HM3, CRT-D and their accessories.

Stereotactic hypofractionated radiotherapy was planned on iPlan v.4.5 (Brainlab, Feldkirchen, Germany) with a prescribed dose of 5000 cGy in five fractions, which were delivered over 10 days every-other day. The treatment plan consists of a coplanar arc and five coplanar intensity-modulated beams (Figure 2) using the 6-MV photon beam on a Novalis TX linac (Varian, Palo Alto, California, USA). The heart, the VAD and its components were spared as much as possible (Table 1).

In order to protect the intracorporal parts of the VAD, no beam through the pump was permitted. Regarding the treatment application, the extracorporal parts (controller batteries and the

driveline) were placed as far away as possible from the beam and covered with an x-ray protective apron (Pb 0.35 mm, Wirona AG, Nidierscherli, Switzerland) (Figure 3). Although divergences exist in the literature regarding shielding with lead, after discussion with the manufacturer, we opted to use lead shielding in our protocol.

Before, during and after each radiotherapy fraction the VAD system was tested (Table 5). Regarding the CRT-D, we deactivated the defibrillator using a magnet and tested the device after each radiotherapy fraction.

In order to detect VAD dysfunction it is imperative to monitor vital signs. Due to the lack of a pulse and a paced heart rhythm, we decided to use direct camera visualization coupled with cerebral near-infrared spectroscopy as a surrogate of hemodynamics. This technique is routinely employed in our institution during the perioperative phase of VAD implantation(17). During each radiotherapy session, a team of anaesthetists specialized in the cardiovascular field were available.

The total dose could be delivered without any complications. No change in the cerebral near-infrared spectroscopy was observed during the therapy. No malfunctions of the VAD or of the CRT-D was documented during or after irradiation.

Three months after the end of the radiotherapy, surveillance PET/CT demonstrated regression of the tumor. The patient is planned to be followed up in line with international consensus guidelines for NSCLC(18).

Systematic review

Before planning the radiotherapy, a systematic review of the existing literature was performed in accordance with the Preferred Reporting Items for Systematic Reviews and Meta-analysis (PRISMA) statement(19). Five databases; Medline, Google scholar, Embase, Ovid journal and Science direct journal were searched using the search term “mechanical support” (and synonyms, “HVAD”, “LVAD”) associated with “radiotherapy” (Table 4). We included all publications written in German, French and English. A manual search in the reference list of each included article was performed to search for articles not already included in the review.

Of the initial 325 unique records, we excluded 307 on the basis of the title or abstract. The 18 eligible publications were read in detail. Nine were included for final analysis, four publications describing in-vitro testing (Table 2) and six publications describing case reports from a total of eight subjects (Table 3). One of the publications described an in-vivo and in-vitro study.

All the in-vitro studies utilized a similar setup with a testing chamber filled of water to simulate both the blood and the body of the patient. A functioning VAD was submerged in the chamber and then irradiated. Two modalities were used: proton beam and electron beam. In total 12 VADs were tested using this methodology, with direct exposures up to 7560 cGy(20). No change in the parameters of the VADs were found during or after irradiation (Table 2).

The in-vivo studies were more heterogeneous. The indication for implantation, the type of VAD and the radiation doses varied widely between cases. The highest delivered radiotherapy dose to a VAD patient was 5400 cGy in three fractions for a NSCLC (VAD: Mean dose 9.6 cGy, max dose 61 cGy)(14). The maximal reported doses received directly to a VAD was 4900 cGy with a mean of 1922cGy for a gastroesophageal junction tumour.(14) None of the publications reported any complication during or after irradiation (Table 3).

Discussion

The literature on radiotherapy in patients with a mechanical assist device is scarce. Nevertheless, on the available evidence, radiotherapy including thoracic irradiation appears safe for patients with HeartMate II (HMII), HeartWare (HW) and miniaturized ventricular assist device (MVAD, Medtronic, MN). However, case reports may be subject to publication bias and larger cohorts are awaited.

Ours is the first report of radiotherapy administration in a patient with a concomitant HM3 VAD. Given the change in technology to include a sensor within the HM3 pump, further information, such as the current case report, and further in-vitro data are warranted to demonstrate safety of radiotherapy for this pump system.

Here we summarize our approach for the management of radiotherapy in VAD patients with a special focuses on the HM3, modified from Emerson et al (14):

1. A multidisciplinary approach is mandatory for the planning and the delivery of the radiotherapy. Ideally, the multidisciplinary team should involve a heart failure specialist, a radiation oncologist, a medical oncologist (in case of a planned systemic treatment), a VAD-specialised nurse or perfusionist, a medical physicist and an anaesthetist.
2. For radiation planning, lower beam energies (< 10 MV) should be preferred using conformal radiation methods with the lowest dose possible to the VAD components as achievable. Because there still is an unpredictable stochastic risk for loss of function of the device, a specialized team should be prepared to intervene immediately.

3. Shortly before, during and after radiotherapy, especially with the HM3 device, the rapid response team, the cardiac surgeon and the invasive cardiologist should be aware of the situation and be prepared to intervene in case of device failure (such as temporary circulatory support device). A replacement extracorporeal controller and battery must be at hand, ready to be installed.
4. Monitoring of the patient should be carefully considered. One possibility is the use of cerebral near-infrared spectroscopy.
5. The extracorporeal controller and battery have to be secured against mechanical damage (e.g. collision with the radiotherapy equipment, falling down) and shielded with lead blanket.
6. The VAD should be interrogated after each radiation therapy.
7. Close monitoring of the anticoagulation is advisable due to possible interaction between radiation therapy and clotting system(21).

CONCLUSION

Increased implantations of VADs will result in a growing number of VAD patients requiring radiation therapy secondary to the development of malignancies. To the best of our knowledge, we have reported the first case of a patient with a new generation VAD (HM3) who successfully underwent stereotactic hypofractionated radiotherapy in the thoracic region without any malfunction of their device. In contrast to previous generations, the HM3 contains electronic components within the implanted pump which could theoretically make this iteration more vulnerable to irradiation.

This case report and the review of the available literature indicate that it is possible, with interdisciplinary work, to deliver radiation therapy for a thoracic malignancy in patients with a VAD without side effects or malfunction. More definitive comments require in-vitro studies as well as larger case series. Nevertheless, the stochastic nature of possible events is not predictable and should always be kept in mind.

CONSENT

The patient gave a written informed consent for publication of this case and any accompanying images. A copy of the written consent is available to the Editor-in-Chief of this journal.

REFERENCES

1. Kim JH, Singh R, Pagani FD, Desai SS, Haglund NA, Dunlay SM, et al. Ventricular Assist Device Therapy in Older Patients With Heart Failure: Characteristics and Outcomes. *J Card Fail.* 2016 Dec 1;22(12):981–7.
2. Kirklin JK, Xie R, Cowger J, de By TMMH, Nakatani T, Schueler S, et al. Second annual report from the ISHLT Mechanically Assisted Circulatory Support Registry. *J Heart Lung Transplant.* 2018 Jun;37(6):685–91.
3. Malhotra J, Malvezzi M, Negri E, Vecchia CL, Boffetta P. Risk factors for lung cancer worldwide. *Eur Respir J.* 2016 Sep 1;48(3):889–902.
4. Hasin T, Gerber Y, McNallan SM, Weston SA, Kushwaha SS, Nelson TJ, et al. Patients With Heart Failure Have an Increased Risk of Incident Cancer. *J Am Coll Cardiol.* 2013 Sep 3;62(10):881–6.
5. Loyaga-Rendon RY, Inampudi C, Tallaj JA, Acharya D, Pamboukian SV. Cancer in end-stage heart failure patients supported by left ventricular assist devices. *ASAIO J.* 2014;60(5):609–12.
6. Zamorano JL, Lancellotti P, Rodriguez Muñoz D, Aboyans V, Asteggiano R, Galderisi M, et al. 2016 ESC Position Paper on cancer treatments and cardiovascular toxicity developed under the auspices of the ESC Committee for Practice Guidelines The Task Force for cancer treatments and cardiovascular toxicity of the European Society of Cardiology (ESC). *Eur Heart J.* 2016 Sep 21;37(36):2768–801.
7. Mehra MR, Canter CE, Hannan MM, Semigran MJ, Uber PA, Baran DA, et al. The 2016 International Society for Heart Lung Transplantation listing criteria for heart transplantation: A 10-year update. *J Heart Lung Transplant Off Publ Int Soc Heart Transplant.* 2016 Jan;35(1):1–23.
8. Feldman D, Pamboukian SV, Teuteberg JJ, Birks E, Lietz K, Moore SA, et al. The 2013 International Society for Heart and Lung Transplantation Guidelines for mechanical circulatory support: Executive summary. *J Heart Lung Transplant.* 2013 Feb 1;32(2):157–87.
9. Postmus PE, Kerr KM, Oudkerk M, Senan S, Waller DA, Vansteenkiste J, et al. Early and locally advanced non-small-cell lung cancer (NSCLC): ESMO Clinical Practice Guidelines for diagnosis, treatment and follow-up. *Ann Oncol.* 2017 Jul 1;28(suppl_4):iv1–21.

- Accepted Article
10. HeartMate 3™ LVAD - Now Approved in the U.S. - Abbott [Internet]. [cited 2019 Apr 7]. Available from: <https://www.heartmate.com/healthcare-provider/heartmate-3-lvad>
 11. Zaremba T, Jakobsen AR, Sogaard M, Thøgersen AM, Johansen MB, Madsen LB, et al. Risk of device malfunction in cancer patients with implantable cardiac device undergoing radiotherapy: a population-based cohort study. *Pacing Clin Electrophysiol PACE*. 2015 Mar;38(3):343–56.
 12. Lewin AA, Serago CF, Schwade JG, Abitbol AA, Margolis SC. Radiation induced failures of complementary metal oxide semiconductor containing pacemakers: a potentially lethal complication. *Int J Radiat Oncol Biol Phys*. 1984 Oct;10(10):1967–9.
 13. Gauter-Fleckenstein B, Israel CW, Dorenkamp M, Dunst J, Roser M, Schimpf R, et al. DEGRO/DGK guideline for radiotherapy in patients with cardiac implantable electronic devices. *Strahlenther Onkol*. 2015 May 1;191(5):393–404.
 14. Emerson LY, Deek MP, Almendral J, Jabbour SK. Radiation therapy in patients with left ventricular assist device: A case report and literature review. *Pract Radiat Oncol*. 2016 Jul 1;6(4):e145–7.
 15. Hurkmans CW, Kneijens JL, Oei BS, Maas AJ, Uiterwaal G, van der Borden AJ, et al. Management of radiation oncology patients with a pacemaker or ICD: A new comprehensive practical guideline in The Netherlands. *Radiat Oncol Lond Engl*. 2012 Nov 24;7:198.
 16. Zheng X, Schipper M, Kidwell K, Lin J, Reddy R, Ren Y, et al. Survival Outcome After Stereotactic Body Radiation Therapy and Surgery for Stage I Non-Small Cell Lung Cancer: A Meta-Analysis. *Int J Radiat Oncol*. 2014 Nov;90(3):603–11.
 17. Maldonado Y, Singh S, Taylor MA. Cerebral near-infrared spectroscopy in perioperative management of left ventricular assist device and extracorporeal membrane oxygenation patients. *Curr Opin Anesthesiol*. 2014 Feb;27(1):81.
 18. Nguyen TK, Senan S, Bradley JD, Franks K, Giuliani M, Guckenberger M, et al. Optimal imaging surveillance after stereotactic ablative radiation therapy for early-stage non-small cell lung cancer: Findings of an International Delphi Consensus Study. *Pract Radiat Oncol*. 2018 Apr;8(2):e71–8.

19. Moher D, Liberati A, Tetzlaff J, Altman DG, Group TP. Preferred Reporting Items for Systematic Reviews and Meta-Analyses: The PRISMA Statement. *PLOS Med*. 2009 juil;6(7):e1000097.
20. Gossman MS, Graham JD, Tamez D, Voskoboynikov N, Larose JA. Evaluation of a Ventricular Assist Device: Stability Under X-rays and Therapeutic Beam Attenuation. *Asaio J*. 2012 May 1;58(3):212–6.
21. Krigsfeld GS, Sanzari JK, Kennedy AR. The effects of proton radiation on the prothrombin and partial thromboplastin times of irradiated ferrets. *Int J Radiat Biol*. 2012 avril;88(4):327–34.
22. Chelikani NM, Masterson K, Down LA, Gill RS, Farar DJ, Horstmanshof DA, et al. Effects of Gamma Radiation on a Ventricular Assist Device and Its Percutaneous Lead Components. *Asaio J*. 2012 Jan 1;58(1):19–24.
23. Gossman MS, Graham JD, Torres P, Kritzer D, Coutinho L, Tamez D. Evaluation of the MVAD pump: stability under high dose x-ray and proton radiation. *Biomed Phys Eng Express*. 2016 Apr;2(2):025014.
24. Gossman MS, Graham JD, Das IJ, Cheng C, Coutinho L, Tamez D, et al. Evaluation of a ventricular assist device system: stability in a proton beam therapy. *ASAIO J Am Soc Artif Intern Organs* 1992. 2012 Dec;58(6):597–600.
25. Lasher DE, Wojcicka JB, Malcom R, Shears LL. Case study of radiation therapy treatment of a patient with a cardiac ventricular assist device. *J Appl Clin Med Phys*. 2008 Oct 29;9(4):214–20.
26. Netuka I, Stepankova P, Urban M, Maly J, Szarszoi O, Dorazilova Z, et al. Is severe cardiac dysfunction a contraindication for complex combined oncotherapy of Hodgkin's lymphoma? Not any more. *ASAIO J Am Soc Artif Intern Organs* 1992. 2013 Jun;59(3):320–1.
27. Scobioala S, Ernst I, Moustakis C, Haverkamp U, Martens S, Eich HT. A case of radiotherapy for an advanced bronchial carcinoma patient with implanted cardiac rhythm machines as well as heart assist device. *Radiat Oncol Lond Engl*. 2015 Apr 7;10:78.

28. Ostertag-Hill CA, Mudd J, Werle DP, Tieu BH, Nabavizadeh N. Safe delivery of lung stereotactic body radiation therapy in a patient with a left ventricular assist device and implantable cardioverter defibrillator. Clin Case Rep. 2018 Sep;6(9):1704–7.

Table 1: Patient dose parameters

	Mean dose (cGy)	Maximum dose (cGy)	Corresponding color in Fig. 1
VAD	8	29	yellow
Extracorporeal controller	---	0.441 [†]	See Fig. 3 (arrow)
Outflow graft	147	991	dark green
Drive line (DL)	11	34	orange
CRT-D	6	69	lime
CRT-D wires	184	3319	lime
Heart	238	3598	red

Abbreviations: CRT-D: Cardiac resynchronization therapy defibrillator

[†]Measured dose after first irradiation. SC was covered with an x-ray protective apron (Pb 0.35 mm, Wirona AG, Niederscherli, Switzerland). During the first radiotherapy session, the dose besides the SC was measured using a pinpoint ionization chamber (0.015 cm³) (PTW, Freiburg, Germany) with a brass build-up cap, corrected for temperature and air pressure.

Table 2: Existing literature on in-vitro testing of VAD's during radiotherapy

REF	VAD	Test	Total dose [cGy]	VAD function after irradiation
(22)	HMII	X-ray beam: 4Gy/min, 50 × 50 cm ² , 2,5 min, 2 time, up to 20Gy	VAD1: 2000	No changes*
(20)	HW	X-ray beam: 18 MV (linear accelerator), rate of 6 Gy/min, 30 × 30 cm ²	VAD1: 7560 VAD2: 6420	No changes
(23)	MVAD	X-ray beam: 18 MV (linear accelerator), rate of 6 Gy/min, 30×30 cm ²	VAD1: 7500 VAD2: 7500	No changes
	MVAD	Proton beam: 4 Gy/min, 175 MeV(cyclotron), 3 time, up to 70Gy	VAD1: 7000 VAD2: 7000	No changes
(24)	HW	Proton beam: 5 Gy/min, 150 MeV (cyclotron) up to 70 Gy.	VAD1: 7000 VAD2: 7000 VAD3: 7000 VAD4: 7000 VAD5: 7000	No changes

* Minor changes in the polymeric components of the DL

HW: HeartWare; HM II: **HeartMate II™**; MVAD: Miniature ventricular assist device; VAD: ventricular assist device

Table 3: Existing literature on in-vivo testing of VAD's during radiotherapy

REF	VAD	Indication	Neoplasia	RT dose [cGy/n fraction]	Mean VAD dose [cGy]	Max VAD dose [cGy]	Complications
(25)	Thoratec (pulsatile)	BTT	Adenocarcinoma of the rectum	4500 / 25	NR	425	No
(22)	HM II	BTR	Non-Hodgkin's large B-cell lymphoma with abdominal mass	2000 / 14	NR	NR	No
(26)	HM II	BTC	Hodgkin's lymphoma	NR	NR	NR	No
(27)	CPS, Novacor	NR	Squamous cell carcinoma on the left main bronchus	3500 / 5	231	538	No
(14)	HM II	BTT	Lung adenocarcinoma right lower lobe	5400 / 3	9.6	61	No
	HM II	BTT	Right lung lower lobe and vertebral metastasis	NR	1423	2450	No
	HM II	DT	Adenocarcinoma of the gastroesophageal junction	5040 / 28	1922	4900	No
(28)	HW	DT	Left lung lower lobe (no confirmation biopsy with high complication risk)	5000 / 5	45	698	No

VAD: Ventricular Assist device, BTC: Bridge to Candidacy, BTT: Bridge to transplant, BTR: Bridge to recovery, DT: Destination therapy, HW: Heartware, HM II: HeartMate II™, NR: Not reported, RT: Radiotherapy

Table 4: research term used in the different databased

Search engine	Data base	modality	Research query
Pubmed	Medline	MeSH terms, title and abstract	Heart, Artificial and Radiotherapy
Ovide	all Ovid Journals, Embase, Medline	Multiple field search, all filed	“(LVAD OR HVAD) and Radiotherapy”
ScienceDirec	ScienceDirect journals	Free text	““VAD” OR “LVAD” OR “HVAD” and “Radiotherapy” ”
Scopus	Scopus	Free text	“VAD” OR “LVAD” OR “HVAD” and “Radiotherapy”
Googlescholar	Googlescholar	Free text	"Radiotherapy" "VAD" OR OR "LVAD" OR OR "HVAD" -"z VAD" vincristine

Table 5: VAD parameter before the radiation therapy, after two sessions and three months after

	Before the first radiation therapy	After the first radiation therapy	After two radiation therapy	Three months after radiation therapy
Speed [RPM]	5'050	5'050	5'050	5'000*
Flow [l/min]	4.1	4.1	4.1	4.0
PI	4.2	4.3	4.3	3.7
Energy [watt]	3.6	3.6	3.6	3.4

* Speed was adapted after a echocardiography guided ramp-test

FIGURES

Figure 1.: A – C. Anatomic relationship between the VAD, the ICD and the tumour

A. VAD and heart/large vessels B. and tumor and CRT-D/wires C. and lungs

Colors: Yellow: Flow pump; Dark green: Outflow graft; Orange: Drive line; Red: LV/RV/LA/RA; Light red: Aorta; Blue: Pulmonary veins/VCI/VCS; Lime: CRT-D/Wires; White: Lungs; Black/red contoured with an arrow: Tumor

Abbreviations: VAD: ventricular assist device; CRT-D: Cardiac resynchronization therapy defibrillator

Figure 2.: coplanar intensity-modulated beams

A. Radiation plan with a coplanar arc (arrowheads Δ) and five coplanar IMRT beams (asterisk *) using the 6-MV SRS photon beam.

B. Dose color wash isodoses of the treatment volume in coronal view with the corresponding color bar (in cGy). This reveals that the pump (yellow) is outside the beams.

C. Dose color wash isodoses of the treatment volume in axial view at the level of the tumor and the coplanar arc.

Colors for A and B: Red: Tumor; Yellow: Flow pump; Orange: External cable; Green: Outflow graft; Light green: CRT-D, White: Heart,

Abbreviations: IMRT: intensity-modulated radiation therapy; SRS: stereotactic radiosurgery

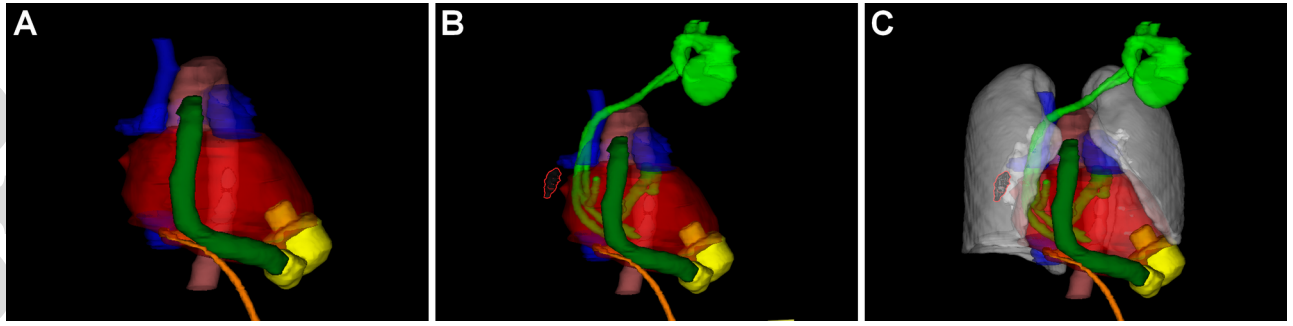Figure 3: Treatment positioning and placement of the extracorporeal Extracorporeal controller

White arrow: The shielding of the Extracorporeal controller

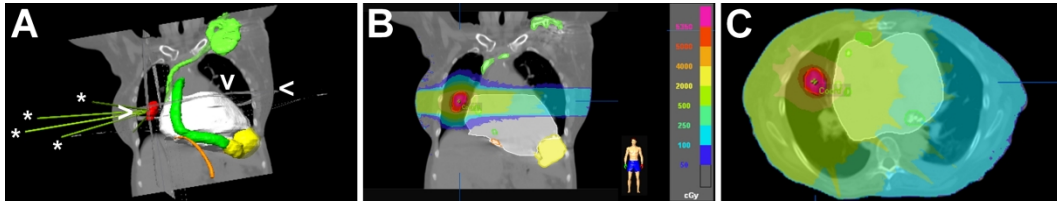
Figure 4: PRISMA flow chart

* An article and a poster from same authors described the exact same case.

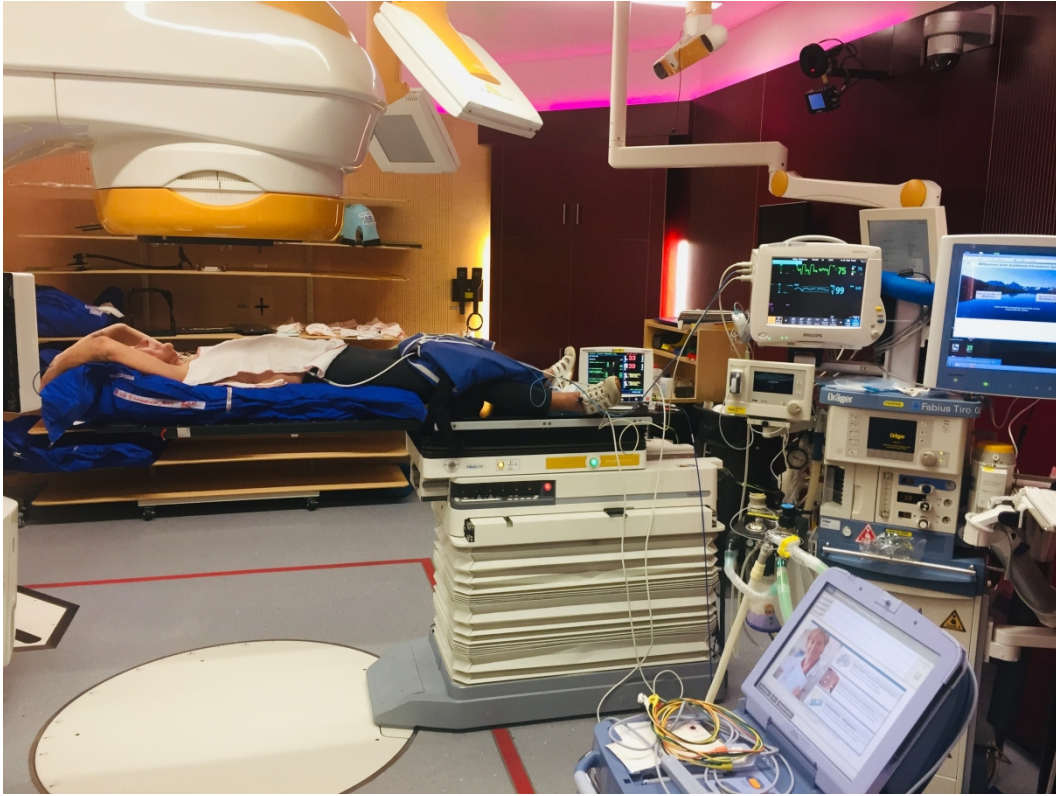** One of the publications describes an in-vivo and in-vitro study



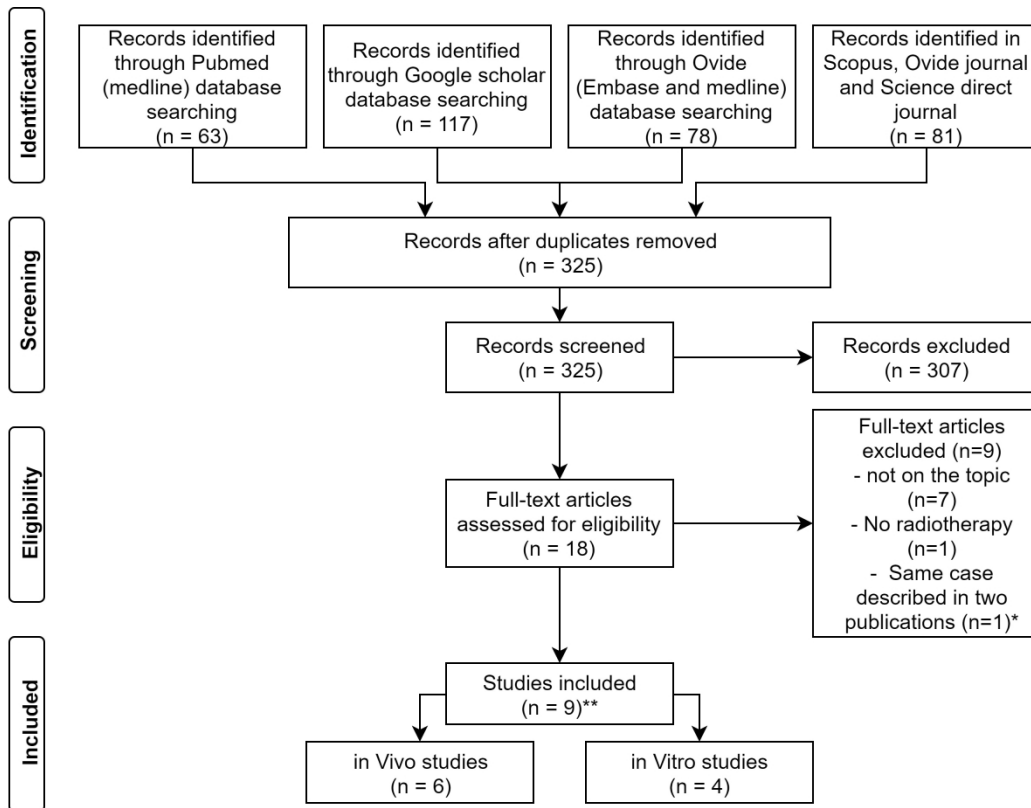
aor_13612_f1.tif



aor_13612_f2.jpg



aor_13612_f3.jpg



aor_13612_f4.jpg