



# NOCARDIAL BRAIN ABSCESS MIMICKING LUNG CANCER METASTASIS IN IMMUNOCOMPETENT PATIENT WITH PULMONARY NOCARDIASIS: A CASE REPORT

Mladen Karan<sup>1,3</sup>, Nada Vučković<sup>2,4</sup>, Petar Vuleković<sup>1,3</sup>, Ante Rotim<sup>5</sup>,  
Nebojša Lasica<sup>3</sup> and Lukas Rasulić<sup>6,7</sup>

<sup>1</sup>Department of Surgery, Faculty of Medicine, University of Novi Sad, Novi Sad, Serbia;

<sup>2</sup>Department of Pathology, Faculty of Medicine, University of Novi Sad, Novi Sad, Serbia;

<sup>3</sup>Department of Neurosurgery, Clinical Centre of Vojvodina, Novi Sad, Serbia;

<sup>4</sup>Pathology and Histology Center, Clinical Centre of Vojvodina, Novi Sad, Serbia;

<sup>5</sup>Department of Neurosurgery, Dubrava University Hospital, Zagreb, Croatia;

<sup>6</sup>Faculty of Medicine, University of Belgrade, Belgrade, Serbia;

<sup>7</sup>Department of Neurosurgery, Clinical Centre of Serbia, Belgrade, Serbia

**SUMMARY** – *Nocardia* is a ubiquitous microorganism which can be the cause of local and disseminated infection in humans. Immunocompetent and immunocompromised patients both can be affected and *Nocardia cyriacigeorgica* was reported as a pathogen isolated in patients worldwide. In most cases, nocardiosis is present as pulmonary infection because inhalation is the primary way of bacterial exposure. Nocardial brain abscess occurs usually secondary to a septic focus elsewhere in the body. Considering the facts that the elderly population is growing, such as the number of immunocompromised patients together with high mortality rate in patients with nocardial infection of the central nervous system, we have to raise awareness of the possibility for this rare but potentially fatal condition. We present a case where nocardial abscesses of lung and brain were initially suspected as lung cancer with brain metastases. The patient was treated with a combination of surgical resection and antimicrobial therapy with good outcome.

**Key words:** *Nocardia*, infections; Brain abscess; Lung neoplasms; Case reports

## Introduction

Nocardial affection of the central nervous system (CNS) is common in immunocompromised patients, but primary cerebral abscess is an unusual presentation in immunocompetent patients. Nocardial brain abscess is an uncommon condition and occurs usually secondary to a septic focus elsewhere in the body<sup>1</sup>. Symptoms of infection are usually nonspecific and patients in most

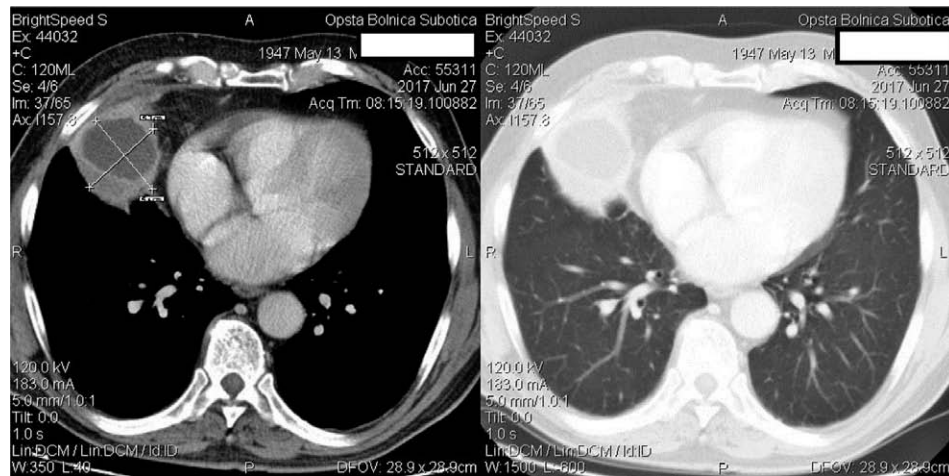
cases present with fever, dyspnea and cough. Mortality is most probably associated with the infection site<sup>2</sup>. *Nocardia* is a very rare causative agent of intracranial abscess (only 1% to 2% of all cerebral abscesses), but its mortality rate (31%) is about three times greater than in others (<10%)<sup>3</sup>. We present a case where nocardial abscesses of the lung and brain were initially suspected as lung cancer with brain metastases.

## Case Report

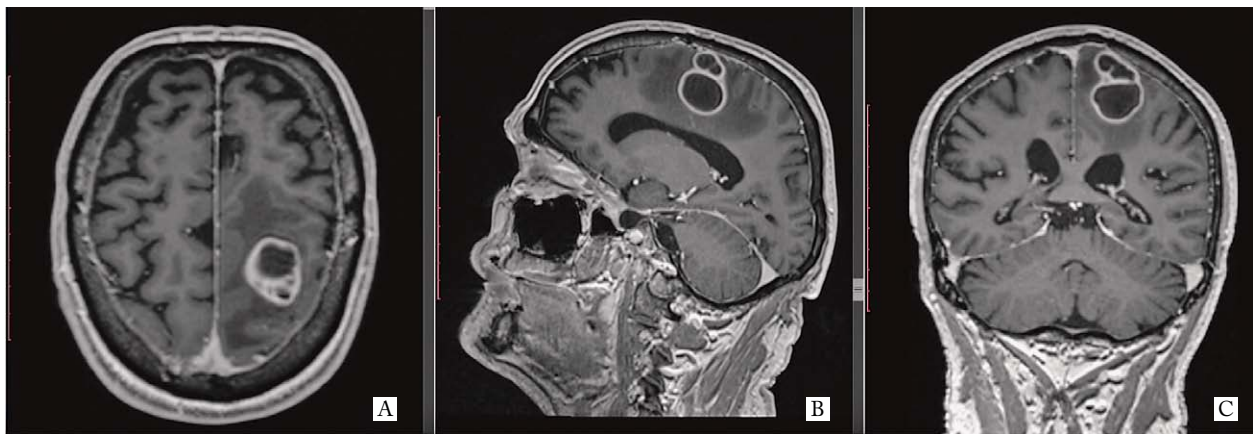A 70-year-old man, retired, divorced, father to three children, with no history of previous diseases, taking no chronic medication, non-smoker, no alcohol abuse, pre-

Correspondence to: *Lukas Rasulić, MD, PhD*, Faculty of Medicine, University of Belgrade, Department of Neurosurgery, Clinical Center of Serbia, Koste Todorovića 26, Belgrade, Serbia  
E-mail: [lukas.rasulic@gmail.com](mailto:lukas.rasulic@gmail.com)

Received January 30, 2019, accepted August 7, 2019



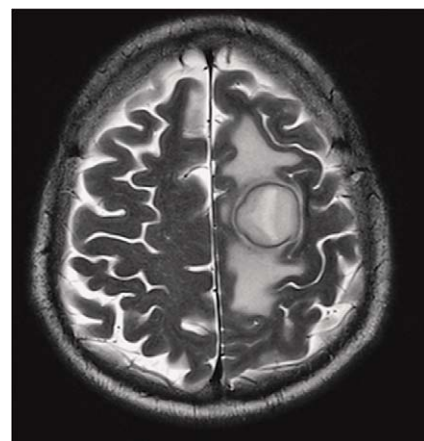
*Fig. 1. Well defined, centrally hypodense lesion in the right middle lobe of the lung, dominantly in S5 segment.*



*Fig. 2. Confluent ring enhancing lesions in the left precentral region in axial (A), sagittal (B) and coronal (C) plane.*

sented to his general practitioner for persistent fever and cough. Chest x-ray revealed lung lesion on the right side. The patient was referred to a regional hospital for further treatment and diagnostics, which he refused.

Two months later, he experienced generalized epileptic seizure and was referred to the University Hospital Emergency Center, where he was examined by a neurologist. He presented as alert, fully oriented with right hemiplegia, muscle power grade 1, according to manual muscle test (MMT). There were no significant neurological deficits found on examination of the sensory or cranial nerves. The patient stated progressive onset of the neurological deficit with significant worsening after the seizure. Computed tomography (CT) of the head showed a lesion in the left precentral region with rim enhancement after administration of



*Fig. 3. Zone of significant perifocal edema surrounding lesion in the left precentral region in T2 axial sequence of magnetic resonance imaging.*

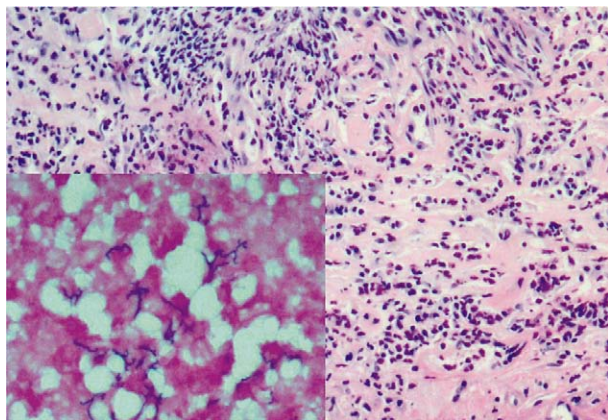


Fig. 4. Area of necrosis with surrounding inflammatory infiltrate and dilated blood vessels (HE $\times$ 100). Inserted: high magnification of gram-positive microorganisms (Gram stain X400).

intravenous contrast agent, surrounded by a zone of white matter edema. Knowing that pulmonary lesion had been present and CT finding was highly suspect of metastasis, the patient was referred to a tertiary level hospital specialized in the treatment of pulmonary diseases for further diagnostics. Laboratory analyses showed raised levels of inflammatory markers: leukocytosis ( $21.5 \times 10^9/L$ ), neutrophilia (87.2%), high C-reactive protein (CRP; 58.1 mg/L; normal range 0.0-5.0 mg/L), fibrinogen 6.59 g/L (normal range 2.2-4.9 g/L) and erythrocyte sedimentation rate (ESR) 60 mm/hour.

Computed tomography (CT) scan of the chest revealed a 6 cm large, well defined, centrally hypodense lesion in the right middle lobe of the lung, dominantly in the S5 segment in contact with parietal pleura, right dome of the diaphragm and pericardial fat pad, with no significant hilar or mediastinal lymphadenopathy (Fig. 1).

Magnetic resonance imaging (MRI) of the brain showed 3 cm large three confluent ring-enhancing lesions in the left precentral region (Fig. 2), with significant perifocal edema and restricted diffusion (Fig. 3). According to imaging characteristics of the cerebral lesion, brain abscess was suspected, but centrally necrotic metastasis of lung cancer was also possible as a differential diagnosis.

After consultation with a neurosurgeon, the patient was transferred to the Neurosurgery Department. Taking into consideration that the lesion together with perilesional edema was compressive and caused

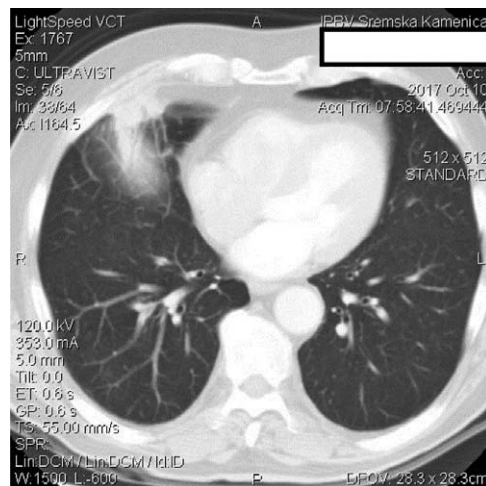


Fig. 5. Complete regression of previously described lung lesion, with minor adhesions left.

severe motor neurological deficit and symptomatic epilepsy, a decision was made to remove it surgically. Left parietal craniotomy was performed and location of the lesion was determined by intraoperative ultrasound. Because of the proximity of motor cortex, intraoperative neurophysiological monitoring was used (motor evoked potentials, somatosensory evoked potentials and free running electroencephalography). At the depth of 5 mm subcortically the lesion was found. It was well delineated from the surrounding brain tissue and had a thin vascularized wall. Inside the lesion, yellow, pus-like fluid was found. Samples were obtained for microbiological and pathological analyses.

Bacteriological investigation revealed gram-positive beaded, branching filaments consisting of *Nocardia cyriacigeorgica*.

Pathological examination of the surgical specimen revealed fragments of brain tissue with zones of necrosis and infiltration with neutrophils, lymphocytes and histiocytes, highly suggestive of brain abscess (Fig. 4).

An early postoperative CT scan showed complete removal of the lesion, without surgical complications. All postoperative laboratory findings were normal, except for ESR (15 mm/h), leukocytosis with neutrophilia ( $16.82 \times 10^9/L$ ) and elevated CRP (9.8 mg/L), which were decreasing in comparison with initial values. The patient's right hemiplegia regressed and his muscle power recovered to grade 4 according to MMT in the first week after surgery; he was transferred to the Infectious Diseases Department and received antimicrobial therapy (sulfamethoxazole and ceftriaxone).



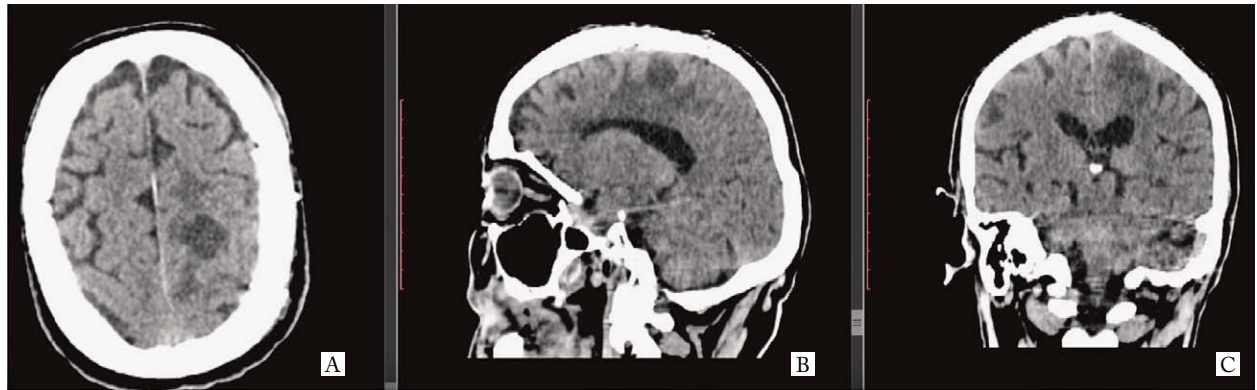


Fig. 6. Follow up computed tomography scan revealed gradual decreasing of brain edema without relapse of the disease in axial (A), sagittal (B) and coronal (C) plane.

Follow up chest CT scan at the Institute for Pulmonary Diseases showed complete regression of the previously described lung lesion, with minor adhesions left (Fig. 5). Pathological examination after bronchoscopy revealed no signs of malignancy.

The follow up brain imaging taken at his outpatient appointments revealed gradual decreasing of brain edema without relapse of the disease (Fig. 6).

## Discussion

*Nocardia* is a ubiquitous microorganism which can be the cause of local and disseminated infection in humans. Immunocompetent and immunocompromised patients both can be affected. There are more than 50 species of *Nocardia* characterized until now. In 2001, Yasin *et al.* reported for the first time nocardiosis caused by a new species named *Nocardia cyriacigeorgica*, which was found in a patient with chronic bronchitis<sup>4</sup>. In the years after their discovery, *Nocardia cyriacigeorgica* was reported as a pathogen isolated in patients worldwide<sup>5-7</sup>. In most cases, nocardiosis is present as a pulmonary infection because inhalation is the primary way of bacterial exposure. The CNS is a common site of extrapulmonary nocardiosis and it is affected by hematogenous dissemination. Characteristic of CNS nocardiosis is formation of a single or multiple abscesses<sup>8</sup>. Pulmonary infection usually starts in a subacute way with unspecific symptoms such as cough, breath shortening, chest pain, hemoptysis, night sweats, weight loss, progressive fatigue and fever. CNS affection also has insidious onset, which makes early diagnosis hard to achieve. In the paper by Mamelak *et al.*, the authors reviewed a significant number of patients with CNS nocardiosis through several decades; the most com-

mon clinical findings were focal neurological deficits, epileptic seizures and non-focal deficits in 42%, 30% and 27% of patients, respectively<sup>9</sup>. Besides clinical and neurological findings, neuroimaging methods and microbiological analyses are a diagnostic pool together with pathological examination. Setting the diagnosis of extrapulmonary nocardiosis (pulmonary, cutaneous, etc.), which occurs in almost 70% of patients with brain abscesses, is an important step in raising suspicion that CNS nocardiosis may be present.

Computed tomography is usually the first diagnostic method used after onset of neurological symptoms and it reveals single or multiple changes with ring enhancement after IV contrast administration, surrounded by more or less extensive zone of vasogenic edema.

Magnetic resonance imaging of the brain is more sensitive in the detection of this type of lesion, especially after administration of gadolinium contrast agents. In some situations, it is very difficult to draw clear distinction between brain abscesses and other multiple brain lesions such as secondary deposits. Additional tools and sequences such as magnetic resonance proton spectroscopy (MRS) or diffusion weighted imaging (DWI) delineating biochemical changes and structural changes at the cellular level in target lesion can be helpful not only in diagnosis but also in following-up the effects of therapy applied<sup>10-12</sup>.

Amplification of specific genetic markers of bacteria using PCR is a foundation of molecular identification at the genus level. The more precise identification at the level of species can be done by further 16S rRNA sequencing<sup>13,14</sup>.

Pathological diagnosis of CNS nocardiosis is based on the use of different staining of specimens obtained after surgical aspiration or excision of CNS lesions.

On hematoxylin and eosin stained (H&E) specimens, abscess formation with neutrophilic infiltrate is most commonly seen. Characteristic right-angle branching filaments of *Nocardia* can be shown with Brown & Brenn stain (an equivalent to Gram stain) with the modified Kinyoun or Fite Faraco staining methods and Gomori methenamine silver stain<sup>3,15</sup>. In the treatment of nocardial brain abscesses, both antimicrobial and surgical treatments can be used. The absence of appropriate prospective trials results in a lack of widely accepted treatment recommendations. If there is extraneural nocardiosis and microbiological diagnosis can be set, brain lesion is smaller than 2.5 centimeter in largest diameter, without compressive manifestations, and the patient is in stable general and neurological condition, antimicrobial therapy can be started empirically<sup>9</sup>. Sulfonamides are antimicrobials of choice to treat nocardiosis, together with other effective antimicrobial drugs such as amikacin, imipenem, meropenem, ceftriaxone, cefotaxime, minocycline, moxifloxacin, levofloxacin, linezolid, tigecycline, and amoxicillin-clavulanic-acid<sup>1</sup>.

In case the surgery is needed, surgical aspiration or complete resection can be offered. According to Lee *et al.*, aspiration alone is a safe, efficacious treatment for the majority of patients with nocardial brain abscesses<sup>7</sup>. In the largest series by Mamelak *et al.*, the mortality rate was 24% after initial craniotomy and excision, and twice higher (50%) after aspiration and drainage<sup>8</sup>.

## Conclusion

According to a growing body of evidence published in the literature recently, one can assume that the incidence of nocardial infection is rising. The explanation probably lies in the facts that the population of the elderly is also growing, such as the number of immunocompromised patients with human immunodeficiency virus or after solid organ transplantation. Considering the high mortality rate in patients with CNS nocardial infection, we want to raise awareness of the possibility of this rare but potentially fatal condition. A combination of antimicrobial therapy with surgical treatment in carefully selected cases can be, as we showed in this report, highly effective if applied timely.

## References

1. Menkü A, Kurtsoy A, Tucer B, Yildiz O, Akdemir H. Nocardia brain abscess mimicking brain tumour in immunocompetent

patients: report of two cases and review of the literature. *Acta Neurochir (Wien)*. 2004 Apr;146(4):411-4; discussion 414. Epub 2004 Feb 16. doi: 10.1007/s00701-004-0215-6.

2. Rivera K, Maldonado J, Dones A, Betancourt M, Fernández R, Colón M. *Nocardia cyriacigeorgica* threatening an immunocompetent host; a rare case of paramediastinal abscess. *Oxf Med Case Reports*. 2017 Dec 11;2017(12):omx061. doi: 10.1093/omcr/omx061. eCollection 2017 Dec.
3. Yorke RF, Rouah E. Nocardiosis with brain abscess due to an unusual species, *Nocardia transvalensis*. *Arch Pathol Lab Med*. 2003 Feb;127(2):224-6. doi:10.1043/0003-9985(2003)127<224:NWBADT>2.0.CO.
4. Yassin AF, Rainey FA, Steiner U. *Nocardia cyriacigeorgica* sp. nov. *Int J Syst Evol Microbiol*. 2001 Jul;51(Pt4):1419-23. doi: 10.1099/00207713-51-4-1419.
5. Schlager R, Huard RC, Della-Latta P. *Nocardia cyriacigeorgica*, an emerging pathogen in the United States. *J Clin Microbiol*. 2008 Jan;46(1):265-73. doi: 10.1128/JCM.00937-07.
6. Kageyama A, Hoshino Y, Yazawa K, Poonwan N, Takeshita N, *et al.* *Nocardia cyriacigeorgica* is a significant pathogen responsible for nocardiosis in Japan and Thailand. *Mycopathologia*. 2005 Aug;160(1):15-9. doi: 10.1007/s11046-005-3050-2.
7. Lee GY, Daniel RT, Brophy BP, Reilly PL. Surgical treatment of nocardial brain abscesses. *Neurosurgery*. 2002 Sep;51(3):668-71; discussion 671-2.
8. Wilson JW. Nocardiosis: updates and clinical overview. *Mayo Clin Proc*. 2012 Apr;87(4):403-7. doi: 10.1016/j.mayocp.2011.11.016.
9. Mamelak AN, Obana WG, Flaherty JF, Rosenblum ML. Nocardial brain abscess: treatment strategies and factors influencing outcome. *Neurosurgery*. 1994 Oct;35(4):622-31.
10. Cartes-Zumelzu FW, Stavrou I, Castillo M, Eisenhuber E, Knosp E, Thurnher MM. Diffusion-weighted imaging in the assessment of brain abscesses therapy. *AJNR Am J Neuroradiol*. 2004 Sep;25(8):1310-7.
11. Murray RJ, Himmelreich U, Gomes L, Ingham NJ, Sorrell TC. Cerebral nocardiosis characterized by magnetic resonance spectroscopy *in vivo*. *Clin Infect Dis*. 2002 Mar 15;34(6):849-52. doi: 10.1086/338869.
12. Stojanoska Medic M, Kozic D, Bjelan M, Vulekovic P, Vuckovic N, Vukovic B, Kovacev Z, Zivacic B. Pituitary abscess with unusual clinical course. *Acta Clin Croat*. 2016;55:650-4. doi: 10.20471/acc.2016.55.04.17.
13. Saubolle MA. Aerobic actinomycetes. In: McClatchey KD, editor. *Clinical Laboratory Medicine*, 2<sup>nd</sup> edn. Philadelphia, Pa: Lippincott Williams & Wilkins; 2002. p. 1201-20.
14. Wilson RW, Steingrube VA, Brown BA, Wallace RJ Jr. Clinical application of PCR-restriction enzyme pattern analysis for rapid identification of aerobic actinomycetes isolates. *J Clin Microbiol*. 1998 Jan;36(1):148-52.
15. Sagar R, Challa S. Pathology and diagnosis of nocardiosis. *JSM Foot Ankle*. 2017;2(5):1040.

## Sažetak

NOKARDIJALNI APSCES MOZGA KOJI JE OPONAŠAO METASTAZU KARCINOMA PLUĆA  
KOD IMUNOKOMPETENTNOG BOLESNIKA S PLUĆNOM NOKARDIJAZOM: PRIKAZ SLUČAJA

M. Karan, N. Vučković, P. Vuleković, A. Rotim, N. Lasica i L. Rasulić

*Nocardia* je ubikvitaran mikroorganizam koji može biti uzročnik lokalnih i sistemskih infekcija kod čovjeka. *Nocardia cyriacigeorgica* je patogen koji je izoliran i prijavljen u svim dijelovima svijeta. I imunokompetentne i imunokompromitirane osobe mogu biti zahvaćene ovom infekcijom. U većini slučajeva prisutna je infekcija pluća budući da je inhalacija primarni put unošenja uzročnika. Nokardijalni apscesi mozga se obično javljaju uslijed postojanja žarišta infekcije u drugim dijelovima organizma. Imajući u vidu činjenicu da raste broj osoba starije životne dobi i broj imunokompromitiranih osoba u ukupnoj populaciji, uz visoku smrtnost bolesnika s nokardijalnom infekcijom središnjega živčanog sustava, moramo biti svjesni mogućnosti za razvoj ovog rijetkog, ali potencijalno fatalnog stanja. Prikazujemo slučaj bolesnika kod kojega su plućna nokardijalna infekcija i nokardijalni apsces mozga inicijalno shvaćeni kao karcinom pluća i metastatski tumor mozga. Bolesnik je liječen kombinacijom kirurškog liječenja i antimikrobne terapije s dobrim ishodom.

Ključne riječi: *Nokardija*, *infekcije*; *Moždani apsces*; *Plućni tumori*; *Prikazi slučaja*