

J HELLENIC VET MED SOC 2017, 68(4): 675-680
ΠΕΚΕ 2017, 68(4): 675-680

Case report Κλινικό περιστατικό

■ Non-metastatic ileal leiomyosarcoma in an aged pouter pigeon (*Columba livia*)

Gornatti Churria C. D.¹, Loukopoulos P.^{2,3}

¹*Cátedra de Patología de Aves y Pilíferos y Laboratorio de Diagnóstico de Enfermedades de las Aves y los Pilíferos, Facultad de Ciencias Veterinarias, Universidad Nacional de La Plata, Argentina*

²*School of Animal and Veterinary Sciences, Charles Sturt University, Australia*

³*Graham Centre for Agricultural Innovation, Charles Sturt University, New South Wales 2678, Australia*

■ Μη-μεταστατικό ειλεακό λειομυοσάρκωμα σε ενήλικο περιστέρι (*Columba livia*)

Gornatti Churria C. D.¹, Λουκόπουλος Π.^{2,3}

ABSTRACT. Intestinal smooth muscle neoplasms are rarely reported in avian species. An aged male pouter pigeon (*Columba livia*) had anorexia, somnolence, progressive emaciation and yellowish diarrhea of four days' duration and died despite antibiotic and antiparasitic treatment. At necropsy, the ileum bore a whitish, nodular, 0.8 cm in diameter mass severely narrowing the lumen. Histopathologically, the ileal mass was a well-demarcated, expansile neoplasm severely expanding the tunica muscularis and invading the mucosa. The neoplasm was composed of densely packed spindle cells with elongated nuclei arranged in broad interlacing bundles, and showing mild anisocytosis and anisokaryosis. Immunohistochemically, the neoplasm was positive for desmin and smooth muscle actin, and negative for cytokeratin, and c-kit. The gross, histopathologic and immunohistochemical findings provided the diagnosis of ileal leiomyosarcoma. This is the first report of an ileal leiomyosarcoma in Columbiformes and one of few intestinal smooth muscle neoplasms described in birds.

Keywords: *Columbiformes, ileum, leiomyosarcoma, neoplasm, pouter pigeon*

Corresponding Author:

C. D. Gornatti Churria, Cátedra de Patología de Aves y Pilíferos y Laboratorio de Diagnóstico de Enfermedades de las Aves y los Pilíferos, Facultad de Ciencias Veterinarias, Universidad Nacional de La Plata, calle 60 y 118 s/n, La Plata, CC 296 B1900AVW, Buenos Aires Province, Argentina.
E-mails: danielgornatti@fcv.unlp.edu.ar / danielgornatti@gmail.com

Date of initial submission: 6-10-2016
Date of revised submission: 5-11-2016
Date of acceptance: 31-7-2017

ΠΕΡΙΛΗΨΗ. Νεοπλάσματα που προέρχονται από το μυϊκό χιτώνα του εντέρου αναφέρονται σπάνια στα πτηνά. Ένα ενήλικο αρσενικό περιστέρι “router” (*Columba livia*) παρουσιάστηκε με ανορεξία, υπνηλία, προοδευτική απίσχναση και κίτρινη διάρροια διάρκειας 4 ημερών και απεβίωσε παρά τη χορήγηση αντιβιοτικών και αντιπαρασιτικής αγωγής. Νεκροτομικά, ο ειλεός έφερε μία λευκωπή, οζώδη μάζα διαμέτρου 0.8 εκ. η οποία προκαλούσε σοβαρού βαθμού στένωση του αυλού. Ιστοπαθολογικά, η μάζα αποτελείτο από ένα καλά περιγεγραμμένο νεόπλασμα που αφορούσε και επέκτεινε το μυϊκό χιτώνα και διείσδυε στο βλεννογόνο. Το νεόπλασμα αποτελείτο από κυτταρικά εμβριθή πληθυσμό ατρακτοειδών κυττάρων διατεταγμένων σε ευρείες αλληλοπλεκόμενες δεσμίδες, με επιμήκεις πυρήνες και ήπια ανισοκυττάρωση και ανισοπυρήνωση. Ανοσοϊστοχημικά, το νεόπλασμα ήταν θετικό στη δεσμίνη και ακτίνη του λείου μυϊκού ιστού και αρνητικό στην κυτταροκερατίνη και c-kit. Με βάση τα μακροσκοπικά, ιστοπαθολογικά και ανοσοϊστοχημικά ευρήματα, ετέθη η διάγνωση του ειλεακού λειομυοσαρκώματος. Η παρούσα είναι η πρώτη αναφορά ειλεακού λειομυοσαρκώματος σε Columbiformes και μία από τις λίγες αναφορές εντερικών νεοπλασμάτων του λείου μυϊκού χιτώνα σε πτηνά.

Λέξεις ευρητηρίασης: Columbiformes, ειλεός, λειομυοσάρκωμα, νεόπλασμα, περιστέρι

INTRODUCTION

Despite the wide range of neoplasms described in avian species, there is a scarcity of reported neoplasms affecting pigeons (*Columba livia*) (Shimonohara et al., 2013). Smooth muscle neoplasms including both leiomyomas and leiomyosarcomas were mainly found in poultry and captive budgerigars but they are also considered scarce in both of them (Steinberg, 1988). Leiomyosarcomas are rarely reported in other avian species (Reece, 2008). Leiomyosarcomas described to date in birds include those affecting the alimentary system [crop of a budgerigar (Sasipreeyajan et al., 1988), ventricular musculature of a broiler chicken (Sato et al., 2002), jejunal wall and mesentery of a broiler chicken (Anderson et al., 1985), jejunal wall of a budgerigar (Steinberg, 1988), small and large intestine of a zebra finch (Cardoso and Levy, 2014), and mesentery of budgerigars (Leach, 1992)], heart and liver of commercial layers infected with J avian leukosis subgroup (Honglei et al., 2010), spleen of budgerigars (Leach, 1992), respiratory system [nasal sinus of a budgerigar (Leach, 1992), tracheal muscle of a broiler chicken (Reece, 2008), and lung of a pigeon (Newman and West, 2001), male reproductive system [testis and vas deferens of budgerigars (Leach,

1992)], female reproductive system [ovary of hens (Reece, 2008) and budgerigars (Steinberg, 1988), oviduct of budgerigars (Leach, 1992; Steinberg, 1988) and backyard chickens (Mete et al., 2013), and mesosalpinx of budgerigars (Steinberg, 1988)], integumentary system [skin of a pigeon (Movassaghi and Sardari, 2008), budgerigar (Zamani-Ahmadm Mahmudi et al., 2015) and crane (Frazier et al., 1993)], and within corporal cavities without differentiating the affected organs [intrathoracic (Sasipreeyajan et al., 1988) and intracelomic (Leach, 1992) presentations in budgerigars].

CASE DESCRIPTION

An aged male pouter pigeon, which belonged to a small flock composed of adult rock, racing and pouter pigeons, was submitted for *postmortem* examination and diagnostic work-up in 2015. The pigeon had a history of anorexia, somnolence, progressive emaciation and yellowish diarrhea of four days' duration. The owner of the flock took care of the bird in a separate facility but the pigeon died at the fifth day after its arrival despite antibiotic and antiparasitic treatment.

At necropsy, the pigeon showed severe atrophy of

the pectoral musculature and mild deformity of the keel bone. The intestinal tract occupied most of the celomic cavity. The small intestine showed severe distension, with a uniform diameter of 3 cm, from the duodenal loop until the ileal region. The ileum bore a whitish nodular 0.8 cm in diameter mass severely narrowing the intestinal lumen. No evidence of intussusception was noted on the affected intestinal segment.

Samples of the brain, heart, esophagus, crop, trachea, lungs, liver, spleen, kidneys, proventriculus, ventriculus, testis, pancreas, and small and large intestine were fixed in 10% buffered formalin, pH 7.2, for 48 h. All tissues were processed by standard histological techniques for the production of 4 µm-thick hematoxylin and eosin stained sections. Fresh samples of the liver and spleen of the pigeon were inoculated onto MacConkey agar (MacConkey Agar, Oxoid Ltd., UK) and sheep blood (Sheep Blood Agar Base, Oxoid Ltd., UK) agar plates and incubated aerobically at 37°C for 24 h.

Droppings were evaluated by a fecal-floatation test. Fresh and formalin-fixed, paraffin-embedded (FFPE) ileal samples were evaluated by the use of Ziehl-Neelsen stain. Immunohistochemical (IHC) analysis was performed to evaluate the expression of desmin (DAKO, North Sydney, Australia), smooth muscle actin (DAKO, North Sydney, Australia), cytokeratin (DAKO, North Sydney, Australia), and c-kit (DAKO, North Sydney, Australia) by the neoplastic cells on 4-µm-thick section, FFPE tissue sections employing a streptavidin-biotin method. Positive avian (kookaburra [*Dacelo* spp.]) and canine tissue sections, negative controls (antibodies omitted) and negative tissue sections were included. Histologically, no noteworthy findings were noted in the brain, heart, esophagus, crop, trachea, lung, liver, spleen, kidney, proventriculus, ventriculus, testis, pancreas, and most of the intestinal regions. The ileal mass

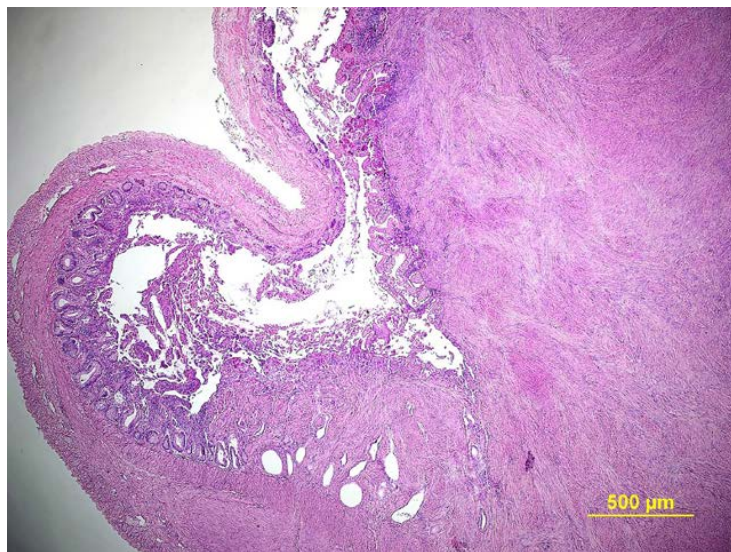
was a mostly well-demarcated, expansile neoplasm severely expanding the tunica muscularis and invading the mucosa (Fig.1). The neoplasm was composed of densely packed spindle cells with elongated nuclei arranged in broad interlacing bundles, and showing mild anisocytosis and anisokaryosis. Ziehl-Neelsen stain was negative for the presence of acid-fast bacteria on fresh and FFPE ileal tissue sections. Immunohistochemically, most tumor cells showed intense cytoplasmic staining for desmin (Fig. 2) and smooth muscle actin (Fig. 3) whereas they were uniformly negative for cytokeratin and c-kit. No nematode eggs neither oocysts were noted in the analyzed droppings by the fecal-floatation test. No bacterial growth was noted on the MacConkey and sheep blood agar plates.

The gross, histopathologic and IHC findings allowed the diagnosis of a low grade ileal leiomyosarcoma.

DISCUSSION

The present case described for the first time a leiomyosarcoma affecting the ileal wall of a pigeon and characterized an intestinal neoplasm of birds rarely reported previously. Based on the absence of concur-

Fig. 1. Aged male pouter pigeon. Ileal leiomyosarcoma. Note a well-demarcated, expansile neoplasm severely expanding the tunica muscularis of the ileal region and invading the mucosa. Hematoxylin and eosin. Bar = 500 µm.



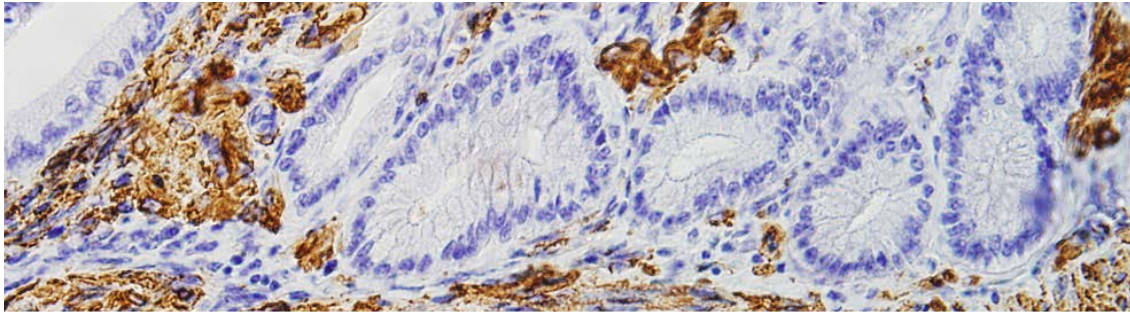


Fig. 2. Aged male pouter pigeon. Ileal leiomyosarcoma. Note numerous tumor cells with intense cytoplasmic staining for desmin. Immunohistochemistry. Bar = 200 μ m.

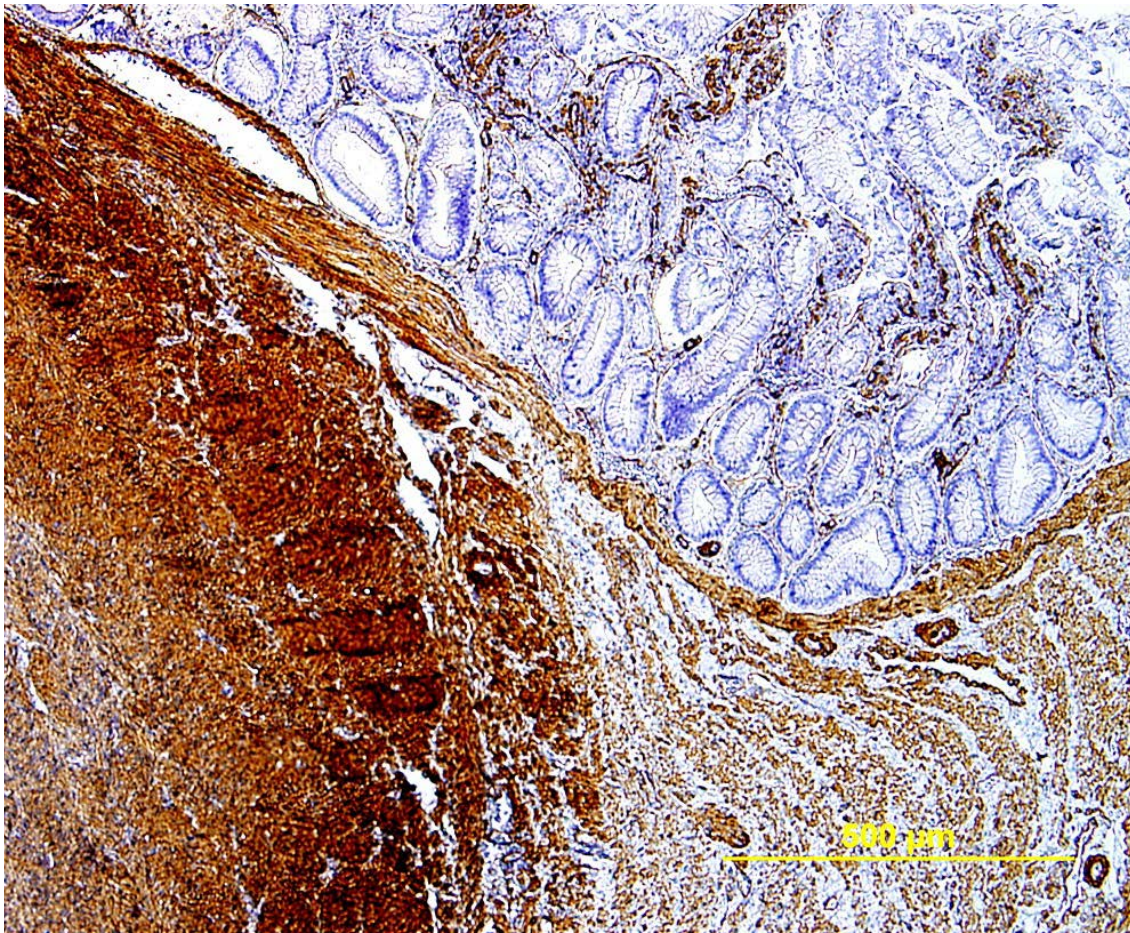


Fig. 3. Aged male pouter pigeon. Ileal leiomyosarcoma. Note numerous tumor cells with intense cytoplasmic staining for smooth muscle actin. Immunohistochemistry. Bar = 100 μ m.

rent diseases, the progressive loss of condition and eventual death of the bird can most likely be attributed to the presence of the intestinal neoplasm.

Intestinal leiomyosarcomas have been only found in three birds previously (Anderson et al., 1985; Steinberg, 1988; Cardoso and Levy, 2014). The first reported bird was a 7-week-old slaughterhouse broiler chicken showing a jejunal leiomyosarcoma with 6 cm in diameter affecting the intestinal wall and neighboring mesentery (Anderson et al., 1985). The second reported bird was a 4-year-old male pet budgerigar which had a 2 cm mass in diameter involving the muscularis layer of the jejunal region without evidence of metastases (Steinberg, 1988). Finally, the third reported bird was an adult zebra finch with a 4 cm in diameter mass causing severe celomic distension and affecting the small and large intestine without the presence of metastases (Cardoso and Levy, 2014).

Similar to several previously reported leiomyosarcomas in birds (Steinberg, 1988; Newman and West, 2001; Movassaghi and Sardari, 2008; Cardoso and Levy, 2014; Zamani-Ahmadmhamudi et al., 2015) the present case showed no evidence of metastatic lesions on the gross and microscopic examination of the wide range of tissues studied.

A recently reported retrospective study of neoplasms in a research colony of pigeons covering a period of 10 years showed 12 types of neoplasms in which seminomas were the most prevalent neoplasm but without evidence of smooth muscle tumors (Shimonohara et al., 2013). There was also

no evidence of leiomyosarcomas in the outstanding retrospective work by Reece (1992) in which 383 non-domestic fowl cases from 69 avian species belonging to 25 Families and 13 Orders were included. Leiomyosarcomas have been mainly reported in captive budgerigars (Sasipreeyajan et al., 1988; Steinberg, 1988; Leach, 1992; Zamani-Ahmadmhamudi et al., 2015) and commercial and backyard chickens (Anderson et al., 1985; Sato et al., 2002; Reece, 2008; Honglei et al., 2010; Mete et al., 2013). Several authors concluded that neoplasms are common in aged pigeons (Shimonohara et al., 2013), however, leiomyosarcomas have been only described in two adult pigeons with cutaneous and pulmonary primary presentations, respectively (Newman and West, 2001; Movassaghi and Sardari, 2008).

Cage and aviary birds are increasingly used for ornamental purposes as individual pets or for breeding purposes living in colonies favoring the increase of their lifespan in both cases (Cardoso and Levy, 2014). Therefore, a higher incidence of neoplasms could be expected in the future.

ACKNOWLEDGEMENT

The authors thank Ms. Cate Hardy for her technical assistance in immunohistochemistry.

CONFLICT OF INTEREST STATEMENT

The authors declare that there is no conflict of interest. ■

REFERENCES

- Anderson WI, McCaskey PC, Langheinrich KA, Dreesen AE (1985) Neurofibrosarcoma and leiomyosarcoma in slaughterhouse broilers. *Avian Dis* 29: 521-527.
- Cardoso JFR, Levy MGB (2014) Pathological and immunohistochemical diagnosis of an intestinal leiomyosarcoma in a zebra finch. *Braz J Vet Pathol* 7: 89-92.
- Frazier KS, Herron AJ, Hines ME II, Miller CL, Hensley GT, Altman NH (1993) Metastasis of a myxoid leiomyosarcoma via the renal and hepatic portal circulation in a sarus crane (*Grus antigone*). *J Comp Pathol* 108: 57-63.
- Honglei S, Mei Q, Yihong X, Feng Y, Wei N, Sidang L (2010) Haemangiomas, leiomyosarcoma and myeloma caused by subgroup J avian leukosis virus in a commercial layer flock. *Acta Vet Hung* 58: 441-451.
- Leach MW (1992) A survey of neoplasia in pet birds. *Sem Avian Exot Pet Med* 1: 52-64.
- Mete A, Giannitti F, Barr B, Woods L, Anderson M (2013) Causes of mortality in backyard chickens in Northern California: 2007-2011. *Avian Dis* 57: 311-315.
- Movassaghi AR, Sardari K (2008) Cutaneous leiomyosarcoma in a pigeon. *Vet Rec* 162: 250-251.
- Newman SJ, West K (2001) Pulmonary leiomyosarcoma in a White Carneau pigeon (*Columba livia*). *J Avian Med Surg* 15: 293-296.
- Reece RL (1992) Observations on naturally occurring neoplasms in birds in the state of Victoria, Australia. *Avian Pathol* 21: 3-32.
- Reece RL (2008) Other tumors of unknown etiology. In: *Diseases of Poultry*. 12th ed (Saif YM, Fadly AM, Glisson JR, McDougald LR, Nolan LK, Swayne DE, eds), Blackwell Publishing, Ames: pp. 593-616.
- Sasipreeyajan J, Newman JA, Brown PA (1988) Leiomyosarcoma in a budgerigar (*Melopsittacus undulatus*). *Avian Dis* 32: 163-165.
- Sato T, Nosaka E, Shibuya H, Momotani E, Fujii Y, Inoue J, Tezuka K, Shirai W (2002) Myxoid leiomyosarcoma of the gizzard in a broiler chicken. *Avian Dis* 48: 256-259.
- Steinberg H (1988) Leiomyosarcoma of the jejunum in a budgerigar. *Avian Dis* 32: 166-168.
- Shimohara N, Holland CH, Lin T-L, Wigle WL (2013) Naturally occurring neoplasms in pigeons in a research colony: a retrospective study. *Avian Dis* 57: 133-139.
- Zamani-Ahmadm Mahmudi M, Nassiri SM, Khaksar E, Solati E (2015) A rare case of cutaneous leiomyosarcoma in budgerigar (*Melopsittacus undulatus*). *Archiv Razi Inst* 70: 57-60