


Accepted Manuscript

Treatment of Ruptured Intracranial Aneurysms Using the Woven EndoBridge Device:
A Two-Center Experience

Rahul Raj, MD, PhD, Riitta Rautio, MD, PhD, Johanna Pekkola, Melissa Rahi, MD,
PhD, Mikko Sillanpää, Jussi Numminen



PII: S1878-8750(18)32832-8

DOI: <https://doi.org/10.1016/j.wneu.2018.12.010>

Reference: WNEU 10955

To appear in: *World Neurosurgery*

Received Date: 6 October 2018

Revised Date: 30 November 2018

Accepted Date: 3 December 2018

Please cite this article as: Raj R, Rautio R, Pekkola J, Rahi M, Sillanpää M, Numminen J, Treatment of Ruptured Intracranial Aneurysms Using the Woven EndoBridge Device: A Two-Center Experience, *World Neurosurgery* (2019), doi: <https://doi.org/10.1016/j.wneu.2018.12.010>.

This is a PDF file of an unedited manuscript that has been accepted for publication. As a service to our customers we are providing this early version of the manuscript. The manuscript will undergo copyediting, typesetting, and review of the resulting proof before it is published in its final form. Please note that during the production process errors may be discovered which could affect the content, and all legal disclaimers that apply to the journal pertain.

Treatment of Ruptured Intracranial Aneurysms Using the Woven EndoBridge Device: A Two-Center Experience

Rahul Raj*[§], MD, PhD, Department of Neurosurgery, University of Helsinki and Helsinki University Hospital, Helsinki, Finland

Riitta Rautio[§], MD, PhD, Department of Radiology, Turku University Hospital, Turku, Finland

Johanna Pekkola, Department of Radiology, University of Helsinki and Helsinki University Hospital, Helsinki, Finland

Melissa Rahi, MD, PhD, Department of Neurosurgery, Turku University Hospital, Turku, Finland

Mikko Sillanpää, Department of Radiology, University of Helsinki and Helsinki University Hospital, Helsinki, Finland

Jussi Numminen, Department of Radiology, University of Helsinki and Helsinki University Hospital, Helsinki, Finland

§Equal contribution

*Corresponding author information:

- E-mail: rahul.raj@hus.fi
- Address: Topeliuksenkatu 5, PB 266, 00029 HUS, Helsinki, Finland
- Phone: +358443191190

Abstract: 226 words

Text: 2,149 words

Tables: 2

Figures: 0

Funding: The study received no external funding

Conflict of interest: The authors declare no conflict of interest

Treatment of Ruptured Intracranial Aneurysms Using the Woven EndoBridge Device: A Two-Center Experience

Abstract

Background: The Woven EndoBridge (WEB) device is a new treatment modality developed for broad-necked unruptured intracranial aneurysms (IA) but shows potential for the treatment of ruptured IAs as well. Our aim was to describe 6-month aneurysm obliteration rates, clinical outcomes and procedure related complications after WEB treatment for ruptured IAs from two academic centers.

Methods: We conducted a retrospective observational study, including all consecutive patients treated with the WEB device (WEB Single Layer [SL] and Single-Layer Sphere [SLS]) for a ruptured IA causing acute subarachnoid hemorrhage (SAH) between 2014 (start of use) and 2017. Primary outcome was angiographic aneurysm obliteration (Beaujon Occlusion Scale Score [BOSS]) rate. Secondary outcomes were early re-bleedings, complications and patient outcome (death and modified Rankin Scale).

Results: A total of 33 patients with ruptured IAs were treated 0-4 days from IA rupture. Out of 27 survivors, six-month angiographic follow-up was available for 26 patients, out of which 81% showed complete occlusion. Of the 27 survivors, 24 patients (89%) had a favorable neurological outcome at six-months after SAH. Two aneurysms were re-treated (8% of all). There was one fatal procedure related complication. No early aneurysm re-bleedings were noted.

Conclusion: For anatomically suitable ruptured IAs, WEB device treatment seems to be safe and results in acceptable occlusion rates. Still, larger studies with long-term results are needed before recommendations can be made.

Introduction

In the past decade, following the International Subarachnoid Aneurysm Trial, there has been a trend towards endovascular treatment of ruptured intracranial aneurysms (IA).¹⁻⁴ The mainstay endovascular treatment of ruptured IAs is coiling. Still, there has been concerns regarding long-term results of ruptured IAs treated with coiling.⁵⁻⁷ Other techniques used for unruptured IAs, such as stent-assisted coiling and the use of flow diverters are associated with higher obliteration rates but their use in ruptured IAs are limited due the risk of thromboembolic and hemorrhagic complications.⁸⁻¹¹

In 2010, the WEB™ device (Sequent Medical, Aliso Viejo, California, USA), an intrasaccular flow diversion device was introduced into the European market.^{12,13} Since its introduction, numerous studies have shown very high obliteration rates for unruptured IAs.¹⁴⁻¹⁸ A major benefit of the WEB device is that it does not require dual antiplatelet therapy. Thus, lately the WEB device has also been used for ruptured IAs in the acute phase of subarachnoid hemorrhage (SAH). Although, there is extensive evidence supporting the use of WEB device in unruptured IAs, only few studies have looked at ruptured IAs.¹⁹⁻²³

The primary aim of this study was to assess aneurysm obliteration rates following endovascular treatment using the WEB device for ruptured IAs. We hypothesized that occlusion rates of WEB treated ruptured IAs would be similar to previous reports of coiled ruptured IAs. Secondary aims was to assess frequency of early aneurysm re-bleedings, procedure related complications and patient neurological outcome.

Methodology

We obtained local research approvals from the two hospitals and the need for informed consent was waived by respective research committee due to the retrospective nature of the study (HUS/125/2017 and T011/014/18).

We conducted an open-cohort retrospective study, including all consecutive patients treated endovascularly with the WEB device for a ruptured intracranial aneurysm at two University hospitals in Finland (Helsinki University Hospital [HUS], Turku University Hospital [TYKS]) from November 2014 (start of use) until December 2017. All patients were treated in the acute SAH stage. The decision to use the WEB device was made by a multidisciplinary team consisting of neurovascular neurosurgeons and neurointerventionalists. The indications for using the WEB device are wide-necked bifurcation aneurysms, although it was occasionally used in “atypical locations” (Fig. 1).²⁴

The WEB™ embolization system and endovascular procedure

The WEB device is an intrasaccular device consisting of braided nitinol wire forming a sphere (WEB SLS) or a more barrel shaped form (WEB SL). The WEB embolization system is well suited for treating broad-neck saccular aneurysms.^{12,13}

All procedures were performed by experienced neurointerventionalists. No antiplatelet treatment was routinely started prior to treatment. All procedures were conducted under heparinization. An 8F/6F combination of guiding catheters or a 6F catheter alone was used. An appropriately sized VIA catheter (Sequent Medical, Aliso Viejo, California, USA) was

placed at the fundus of the aneurysm from which the WEB device was deployed. The type (WEB SL or SLS) and size of the WEB was decided based upon measurements from 3D rotational angiographic and orthogonal 2D projection measurements. In case of suboptimal fitting, the WEB size was changed. Acetylsalicylic acid (Aspirin) was not routinely used.

Extracted variables

We obtained all patient data through electronic health care records (EHRs) and by reviewing radiological images from the hospitals' Picture Archiving Communication Systems (PACS).

We obtained information regarding pre-SAH modified Rankin Scale (mRS, *see below*) history of hypertension and smoking status through EHRs. We obtained the following SAH-related admission characteristics: Glasgow Coma Scale score (GCS), Hunt & Hess Classification of SAH, pupillary light reactivity, modified Fischer scale, external ventricular drain (EVD), days from SAH to hospital admission and days from SAH to WEB treatment. We considered a Hunt & Hess class of 4–5 as poor grade SAH.

Follow-up

We perform routine angiographic follow-up at 6-months after treatment (with small variations depending on the patient's clinical condition). During SAH treatment, we obtain a routine head computerized tomography (CT) on the first post-procedural day. We obtain follow-up head CTs according to clinical indications. Long-term clinical follow-up is conducted through the neurosurgical or neurological outpatient clinics.

Outcomes

As the primary outcome of interest we used radiological aneurysm occlusion. Two neuroradiologists evaluated treatment results according to the Beaujon Occlusion Scale Score (BOSS, 0: no residual flow in the aneurysm/WEB; 0': opacification of the proximal recess of the WEB; 1: residual flow inside the WEB; 2, neck remnant; 3: aneurysm remnant) from the control digital subtraction angiography conducted closest to 6-months after SAH.^{25,26} We considered BOSS 0 and 0' as complete occlusion of the aneurysm.^{14,18} As secondary outcome of interests we looked at aneurysm re-bleeding, and WEB treatment related thromboembolic complications based upon follow-up head CT imaging. We also report death rates and neurological outcomes, according to the modified Rankin Scale (a mRS of 0 [no symptoms at all] to 2 [slight disability] were considered favorable neurological outcome).^{27,28}

Results

Of totally 331 endovascularly treated aneurysmal SAH patients treated, a total of 33 patients (HUS, N=12 treated with WEB out of 166 endovascularly treated SAH patients; TYKS, N=21 treated with WEB out of 165 endovascularly treated SAH patients) were treated between November 2014 and December 2017. Only in one patient a help device (stent) was used and was administered dual antiplatelet therapy (stent used due to protrusion of WEB into parent artery). Three patients with broad based aneurysms were administered acetylsalicylic acid for two to six weeks. All except one patient was admitted to the hospital on the same day of SAH (one patient the next day). Two thirds of patients were treated on the IA rupture day and one third were treated on days 1 to 3. All patients had a pre-SAH mRS of 0. Patient characteristics are shown in Table 1. Median age was 56 years (IQR 49–67), no patients had previously suffered from SAH, 50% of patients were smokers and 44% had a diagnosis of arterial hypertension. Twenty-one percent had poor grade SAH, median modified Fischer scale was 4 (IQR 3–4) and 18% of patients had intracerebral hemorrhage. Median time from SAH to WEB treatment was on 0 (IQR 0–1). Sixty-one percent of all treated aneurysms were located in the anterior circulation. Basilar artery and anterior communicating artery aneurysm were the most common locations. Median aneurysm size was 7 mm.

Primary Outcome: Aneurysm Occlusion Rate

Of 33 patients, 6 patients died and were not subject to follow-up angiography. Out of 27 survivors, follow-up angiography was available for 26 patients. Median time to angiographic follow-up was 193 days (IQR 179–220). Of these 21 of 26 patients (81%) showed complete occlusion of the treated aneurysm. Five of 26 patients (19//23%) showed incomplete

occlusion (four neck remnants [Fig. 2], one aneurysm remnant). Of these incomplete occluded aneurysms, two were anterior communicating artery aneurysms, two were basilar artery aneurysms and one was a middle cerebral artery bifurcation aneurysm. Of these incompletely occluded aneurysms, two were re-treated (8% of all; one anterior communicating aneurysm and one middle cerebral artery bifurcation aneurysm). Both patients undergoing re-treatment had an mRS of 0 and 1 before and after the re-treatment.

Secondary Outcomes: Patient Outcome, Complications and Early Re-Bleedings

Six patients (18%) died following SAH (4 to 44 days following SAH). These non-survivors were significantly older than survivors (median age for non-survivors 70 years [IQR 58-78] versus median age for survivors 52 years [IQR 47-65], $p=0.011$). Sixty-seven percent of non-survivors had a poor grade SAH compared to 11% for survivors ($p=0.003$). Two patients died due to severe delayed cerebral ischemia. One patient experienced re-bleeding in the angio suite prior to treatment. One patient suffered from a massive pulmonary embolism nine days after treatment and was administered intravenous thrombolysis and subsequently developed a fatal massive intracerebral hemorrhage at a distant site from the treated aneurysm (anterior communicating artery) and was, thus, not classified as an early re-bleed (Fig. 3). One elderly poor grade SAH patient suffered out of hospital cardiac arrest in conjunction with aneurysm rupture and died after nine days of treatment. One good grade SAH patient did not wake up after endovascular treatment and died after three weeks of treatment (ruptured left sided pericallosal aneurysm). Autopsy report showed hydrophilic polymeric embolisation of the left hemisphere and this was the only directly treatment related complication. Further, three patients (9%) suffered from clinically silent brain

ischemic lesions related to the WEB treatment (all of these patients had a favorable neurological outcome).

No patient experienced post-WEB treatment re-bleeding (Table 2). Seven patients (21%) experienced SAH related delayed cerebral ischemia (out of which 3 patients died, 2 had an unfavorable neurological outcome and 2 a favorable neurological outcome).

Median time to neurological outcome assessment was 198 days (IQR 177-235). Of 27 survivors, 24 patients (89%) had a favorable neurological outcome (mRS 0-2) and 3 patients (11%) an unfavorable neurological outcome (mRS 3-5). Including all patients, the rate of favorable neurological outcome was 73% (N=24/33) and the rate of unfavorable neurological outcome 27% (N=9/33).

Discussion

Key findings

In this two-center retrospective study, we showed that complete angiographic occlusion rate for WEB device treated ruptured IAs to be 81%. Two aneurysms (8%) required re-treatment. No early re-bleedings were noted but there was one fatal procedure related complication. Of patients surviving the acute phase of SAH, the rate of favorable neurological outcome was 89%.

Comparison with previous studies

There are some previous studies investigating the use of the WEB device for the treatment of ruptured IAs. In 2014, Caroff and colleagues reported their case-series of six ruptured IAs being treated with the WEB device and found an adequate occlusion rate of 67% at 3-months (complete occlusion, small neck remnant, or opacification of the first chamber).¹⁹ Van Rooij WJ and colleagues showed in their 18 angiographically followed up patients a complete occlusion rate of 83%.²⁰ Liebig and colleagues found a complete occlusion rate of 60% (15 out of 25 patients) at 4-months and a complete occlusion rate of 56% (5 out of 9 patients) at 13-months.²² Popielski and colleagues found a complete occlusion rate of 59% at 3-months (13 out of 22 patients) and 58% at 12-months (7 out of 12 patients).²¹ In the largest clinical series on WEB treated ruptured IAs, Van Rooij SBT and colleagues showed a complete occlusion rate of 73% (54 out of 74 patients).²³ Thus, the complete occlusion rate, of WEB treated ruptured IAs, seems to vary between 56% and 83%. Our results fare well with these, with an overall complete occlusion rate of 81%.

It should be mentioned that the BOSS scale for the angiographic evaluation of WEB device treated results is rather strict. As most previous studies, we only considered no flow inside the aneurysm or the WEB and opacification of the proximal recess as complete occlusions.²⁶ Still, it is possible that a slight level of flow inside the WEB (BOSS 1) and a small aneurysm neck remnant (BOSS 2) could be acceptable radiological outcomes. Especially in elderly patients, where the main goal of treatment is prevention of early re-bleedings with less focus on long-term follow-ups. If we would have classified small neck remnants as adequate occlusion, our adequate occlusion rate would have been 96% (25 out of 26). Yet, before long-term studies verify the stability of BOSS grades 1 and 2, we do not think it adequate to accept suboptimal occlusions especially as complication rates after re-treatment is low.^{29,30}

The golden standard for endovascular treatment of ruptured IAs remains to be standard coiling (with or without balloon-remodeling), avoiding implants that require antiplatelet therapy in the acute setting of SAH. In a large retrospective series including ruptured IAs, complete occlusion rate at 3-12 months after coiling was 45% and 38% at 12-months.⁷ In the ISAT study, 66% of endovascularly coiled ruptured IAs were completely occluded at 2 to 12 months.³¹ Thus, angiographic results of WEB device treated ruptured IAs seems to at least match those of coiled ones. Still, one has to remember that all studies on using the WEB device for ruptured IAs, including our study, are rather small observational studies with a selected set of patients with anatomically suitable aneurysms for WEB treatment and, thus, the results cannot be directly compared, especially as the WEB is mainly used for broad based aneurysms, which is associated with a higher recurrence rate.⁷ Furthermore, the WEB device is used for the treatment of aneurysms maximally 10 mm large (max WEB size 11 x 9 mm), while coil embolization does not per se have any upper size limit. Consequently, since

aneurysm size is one of the major risk factors for aneurysm recurrence it biases the results towards better occlusion rates for WEB device treated aneurysms when compared to unselected series of coil embolized aneurysms.⁷ Thus, randomized studies or case-matched series comparing WEB device treatment to coil embolization are needed as are long-term follow-up studies after WEB device treatment.

The rate of complications was low. Three patients suffered from clinically silent ischemic lesions and one patient had an unexpected extremely rare and severe complication, resulting in hydrophilic polymeric embolisation of the left hemisphere, which has been described elsewhere.³² Iatrogenic polymeric embolisation has been associated with a wide range of percutaneous intravascular diagnostics and therapeutic interventions and the fact that it happened in this small series is hardly related to the WEB device itself.^{33,34}

Conclusions

In this selected patient cohort of anatomically suitable ruptured IAs, WEB device treatment seems to be safe and results in acceptable occlusion rates. Still, larger studies with long-term results are needed before recommendations can be made.

Acknowledgments

NA

ACCEPTED MANUSCRIPT

Figure legends

Figure 1: Showing the configuration of typical aneurysms treated with the WEB device (prior to treatment to the left and after WEB device deployment to the right). In the upper part an anterior communicating artery aneurysm and in the middle part a basilar tip artery aneurysm and in the lower part a posterior inferior cerebellar artery aneurysm, the first two locations being “typical locations” and the last one being an “atypical location”.

Figure 2: Showing incomplete occlusion of an anterior communicating artery aneurysm (upper row) and a basilar tip artery aneurysm (lower row). To the left the pre-WEB device images, in the middle the immediate post-WEB deployment images and to the right the 6-month control showing aneurysm neck remnant.

Figure 3: To the left the 1-day post-WEB treatment CT image and to the right the CT image following thrombolysis therapy for a massive pulmonary embolism nine days after treatment.

References

1. Molyneux A. International Subarachnoid Aneurysm Trial (ISAT) of neurosurgical clipping versus endovascular coiling in 2143 patients with ruptured intracranial aneurysms: a randomised trial. *Lancet* 2002;360:1267–74.
2. Lin N, Cahill KS, Frerichs KU, et al. Treatment of ruptured and unruptured cerebral aneurysms in the USA: a paradigm shift. *J Neurointerv Surg* 2012;4:182–9.
3. Qureshi AI, Vazquez G, Tariq N, et al. Impact of International Subarachnoid Aneurysm Trial results on treatment of ruptured intracranial aneurysms in the United States. *J Neurosurg* 2011;114:834–41.
4. Andaluz N, Zuccarello M. Recent trends in the treatment of cerebral aneurysms: analysis of a nationwide inpatient database. *J Neurosurg* 2008;108:1163–9.
5. Molyneux AJ, Birks J, Clarke A, et al. The durability of endovascular coiling versus neurosurgical clipping of ruptured cerebral aneurysms: 18 year follow-up of the UK cohort of the International Subarachnoid Aneurysm Trial (ISAT). *Lancet* 2015;385:691–7.
6. Campi A, Ramzi N, Molyneux AJ, et al. Retreatment of Ruptured Cerebral Aneurysms in Patients Randomized by Coiling or Clipping in the International Subarachnoid Aneurysm Trial (ISAT). *Stroke* 2007;38:1538–44.
7. Raymond J, Guilbert F, Weill A, et al. Long-Term Angiographic Recurrences After Selective Endovascular Treatment of Aneurysms With Detachable Coils. *Stroke* 2003;34:1398–403.
8. Rosenwasser RH, Chalouhi N, Tjoumakaris S, et al. Open vs Endovascular Approach to Intracranial Aneurysms. *Neurosurgery* 2014;61:121–9.
9. Ryu C-W, Park S, Shin HS, et al. Complications in Stent-Assisted Endovascular Therapy of Ruptured Intracranial Aneurysms and Relevance to Antiplatelet Administration: A Systematic Review. *Am J Neuroradiol* 2015;36:1682–8.
10. Zhao B, Tan X, Yang H, et al. Stent-assisted coiling versus coiling alone of poor-grade ruptured intracranial aneurysms: a multicenter study. *J Neurointerv Surg* 2017;9:165–8.
11. Bechan RS, Sprengers ME, Majoie CB, et al. Stent-Assisted Coil Embolization of Intracranial Aneurysms: Complications in Acutely Ruptured versus Unruptured Aneurysms. *AJNR Am J Neuroradiol* 2016;37:502–7.
12. Ding YH, Lewis DA, Kadirvel R, et al. The Woven EndoBridge: A New Aneurysm Occlusion Device. *Am J Neuroradiol* 2011;32:607–11.
13. Pierot L, Liebig T, Sychra V, et al. Intrasaccular Flow-Disruption Treatment of Intracranial Aneurysms: Preliminary Results of a Multicenter Clinical Study. *Am J*

- Neuroradiol* 2012;33:1232–8.
14. Pierot L, Costalat V, Moret J, et al. Safety and efficacy of aneurysm treatment with WEB: results of the WEBCAST study. *J Neurosurg* 2016;124:1250–6.
 15. Pierot L, Moret J, Barreau X, et al. Safety and efficacy of aneurysm treatment with WEB in the cumulative population of three prospective, multicenter series. *J Neurointerv Surg* 2018;10:553–9.
 16. Fiorella D, Molyneux A, Coon A, et al. Demographic, procedural and 30-day safety results from the WEB Intra-saccular Therapy Study (WEB-IT). *J Neurointerv Surg* 2017;9:1191–6.
 17. Pierot L, Moret J, Turjman F, et al. WEB Treatment of Intracranial Aneurysms: Clinical and Anatomic Results in the French Observatory. *Am J Neuroradiol* 2016;37:655–9.
 18. Pierot L, Moret J, Turjman F, et al. WEB Treatment of Intracranial Aneurysms: Feasibility, Complications, and 1-Month Safety Results with the WEB DL and WEB SL/SLS in the French Observatory. *Am J Neuroradiol* 2015;36:922–7.
 19. Caroff J, Mihalea C, Dargento F, et al. Woven Endobridge (WEB) Device for endovascular treatment of ruptured intracranial wide-neck aneurysms: a single-center experience. *Neuroradiology* 2014;56:755–61.
 20. van Rooij WJ, Peluso JP, Bechan RS, et al. WEB Treatment of Ruptured Intracranial Aneurysms. *AJNR Am J Neuroradiol* 2016;37:1679–83.
 21. Popielski J, Berlis A, Weber W, et al. Two-Center Experience in the Endovascular Treatment of Ruptured and Unruptured Intracranial Aneurysms Using the WEB Device: A Retrospective Analysis. *Am J Neuroradiol* 2018;39:111–7.
 22. Liebig T, Kabbasch C, Strasilla C, et al. Intrasaccular Flow Disruption in Acutely Ruptured Aneurysms: A Multicenter Retrospective Review of the Use of the WEB. *Am J Neuroradiol* 2015;36:1721–7.
 23. van Rooij SBT, van Rooij WJ, Peluso JP, et al. WEB Treatment of Ruptured Intracranial Aneurysms: A Single-Center Cohort of 100 Patients. *Am J Neuroradiol* 2017;38:2282–7.
 24. Pierot L, Biondi A, Narata A-P, et al. Should indications for WEB aneurysm treatment be enlarged? Report of a series of 20 patients with aneurysms in “atypical” locations for WEB treatment. *J Neuroradiol* 2017;44:203–9.
 25. Caroff J, Mihalea C, Klisch J, et al. Single-Layer WEBs: Intrasaccular Flow Disrupters for Aneurysm Treatment—Feasibility Results from a European Study. *Am J Neuroradiol* 2015;36:1942–6.
 26. Caroff J, Mihalea C, Ikka L, et al. Interobserver variability in the assessment of aneurysm occlusion with the WEB aneurysm embolisation system. *J Neurointerv Surg* 2017;9:e11–2.

27. van Swieten JC, Koudstaal PJ, Visser MC, et al. Interobserver agreement for the assessment of handicap in stroke patients. *Stroke* 1988;19:604–7.
28. Banks JL, Marotta CA. Outcomes Validity and Reliability of the Modified Rankin Scale: Implications for Stroke Clinical Trials: A Literature Review and Synthesis. *Stroke* 2007;38:1091–6.
29. Renowden SA, Koumellis P, Benes V, et al. Retreatment of Previously Embolized Cerebral Aneurysms: The Risk of Further Coil Embolization Does Not Negate the Advantage of the Initial Embolization. *Am J Neuroradiol* 2008;29:1401–4.
30. CARAT Investigators. Rates of Delayed Rebleeding From Intracranial Aneurysms Are Low After Surgical and Endovascular Treatment. *Stroke* 2006;37:1437–42.
31. Molyneux AJ, Kerr RS, Yu L-M, et al. International subarachnoid aneurysm trial (ISAT) of neurosurgical clipping versus endovascular coiling in 2143 patients with ruptured intracranial aneurysms: a randomised comparison of effects on survival, dependency, seizures, rebleeding, subgroups, and . *Lancet* 2005;366:809–17.
32. Tikka J, Gardberg M, Rautio R, et al. Left cerebral hemisphere hydrophilic polymer embolism associated with endovascular WEB treatment of a ruptured aneurysm of the anterior cerebral artery. *Leg Med* 2018;35:66–8.
33. Ansari SA, Anderson RR, Caron MJ, et al. Hydrophilic polymer embolic complication during diagnostic cerebral angiography presenting with delayed intracranial hemorrhage: case report and literature review. *J Neurointerv Surg* <https://doi.org/10.1136/neurintsurg-2018-014189>.
34. Mehta RI, Mehta RI, Solis OE, et al. Hydrophilic polymer emboli: an under-recognized iatrogenic cause of ischemia and infarct. *Mod Pathol* 2010;23:921–30.

Footnotes

Contributors: All authors contributed to the manuscript through data collection, analysis, manuscript composition, and critical review. All authors provided final approval for publication.

Competing interests: The authors declare no conflict of interest.

Ethics approval: Helsinki University Hospital's research committee (HUS/125/2017) and Turku University Hospital's research committee (T011/014/18).

Provenance and peer review: Not commissioned; externally peer reviewed.

Data sharing statement: Data presented is subject to confidentiality and not allowed to be shared.

Table 1: Patient baseline characteristics

	All (N=33)	HUS (N=12)	TYKS (N=21)
Age, median (IQR)	56 (49-67)	51 (47-58)	60 (52-72)
Previous SAH	0	0	0
Hypertension	14 (44%)	4 (33%)	10 (50%)
Smoking*			
No	10 (42%)	6 (50%)	4 (33%)
Current	12 (50%)	5 (42%)	7 (58%)
Ex-smoker	2 (8%)	1 (8%)	1 (8%)
Admission GCS score	14 (10-15)	14 (5-15)	14 (10-15)
Pupillary light reactivity			
Both react	32 (97%)	12 (100%)	20 (95%)
One react	1 (3%)	0	1 (5%)
None react	0	0	0
Admission motor scale, median (IQR)	6 (5-6)	6 (2-6)	6 (5-6)
Hunt & Hess, median (IQR)	2 (2-3)	3 (2-5)	2 (1-3)
1-3	26 (79%)	9 (75%)	17 (81%)
4-5	7 (21%)	3 (25%)	4 (19%)
Modified Fisher scale, median (IQR)	4 (3-4)	4 (4-4)	3 (3-4)
ICH	6 (18%)	2 (17%)	4 (19%)
External ventricular drain			
Before treatment	8 (24%)	3 (25%)	5 (24%)
After treatment	12 (36%)	4 (33%)	8 (38%)
Not at all	13 (40%)	5 (42%)	
Time from SAH to WEB (d), median (IQR)	0 (0-1)	0 (0-1)	0 (0-1)
Length of ICU stay (d), median (IQR)	10 (6-15)	9 (5-15)	10 (6-16)
Length of hospital stay (d), median (IQR)	15 (12-19)	16 (14-20)	15 (10-18)
Aneurysm location			
ICA	3 (9%)	1 (8%)	2 (10%)
ACoA	9 (28%)	6 (50%)	3 (14%)
MCA bifurcation	7 (21%)	0 (0%)	7 (33%)
Pericallosal	1 (3%)	0 (0%)	1 (5%)
Basilar	12 (36%)	4 (34%)	8 (38%)
PICA	1 (3%)	1 (8%)	0 (0%)
Aneurysm size (mm), median (IQR)			
Length	7 (5-10)	7 (5-10)	7 (6-10)
Width	6 (5-8)	5 (4-8)	7 (6-8)
Depth	7 (5-9)	6 (3-8)	7 (6-10)

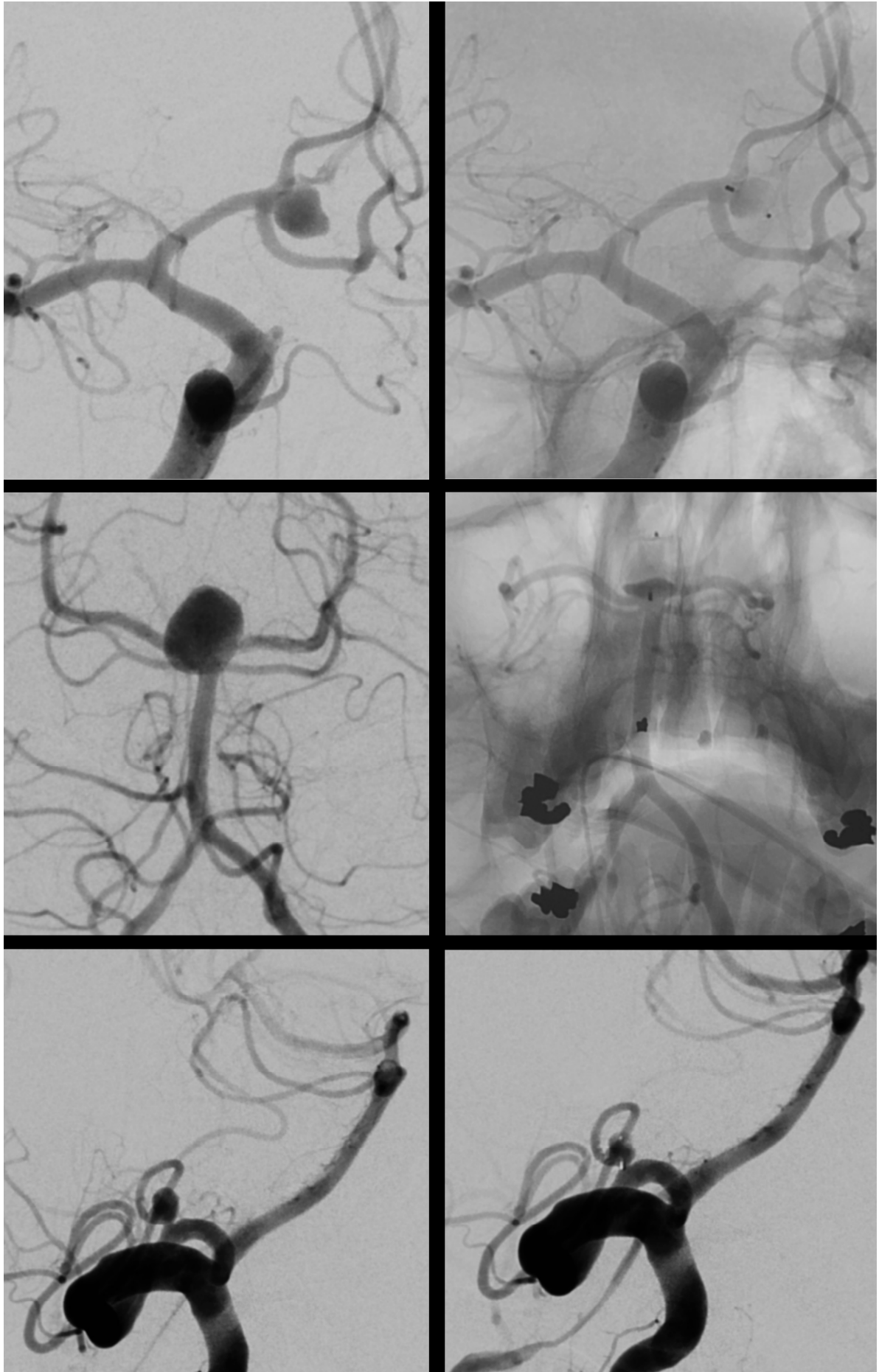
Continuous variables shown as medians with interquartile ranges. Categorical variables shown as numbers and percentages.

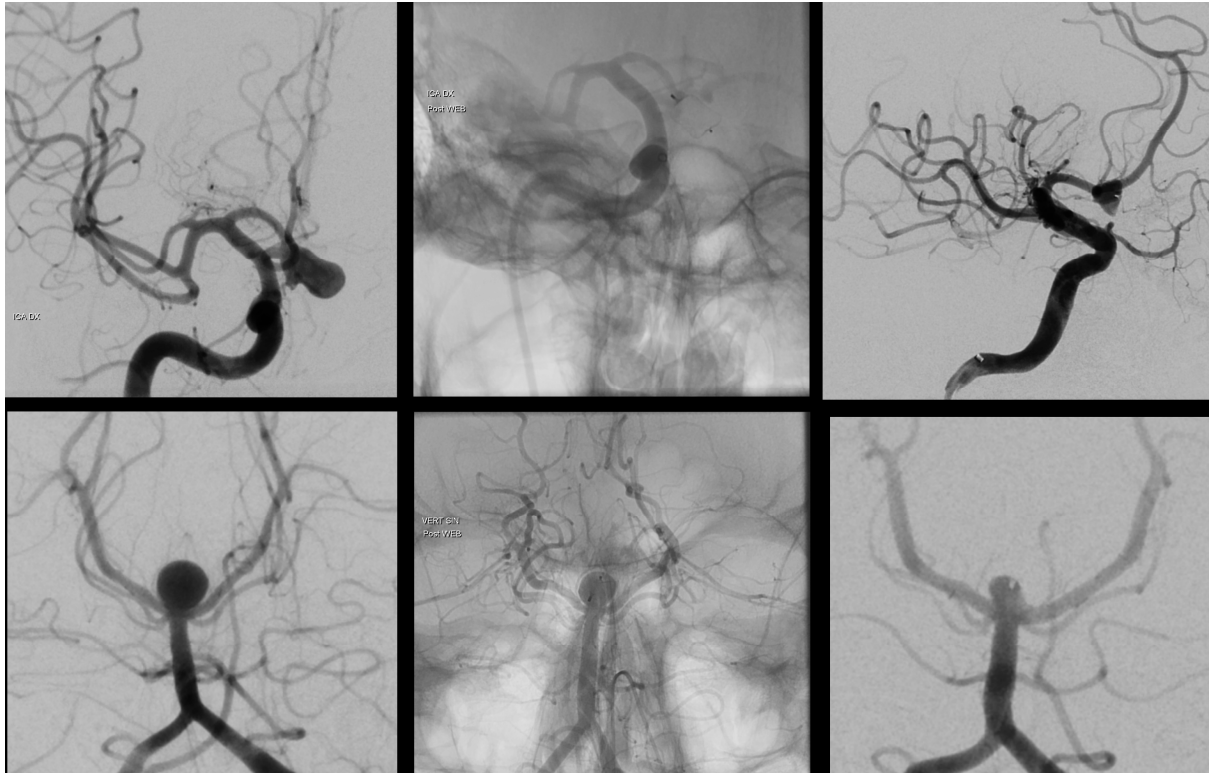
*Data missing for 9 patients.

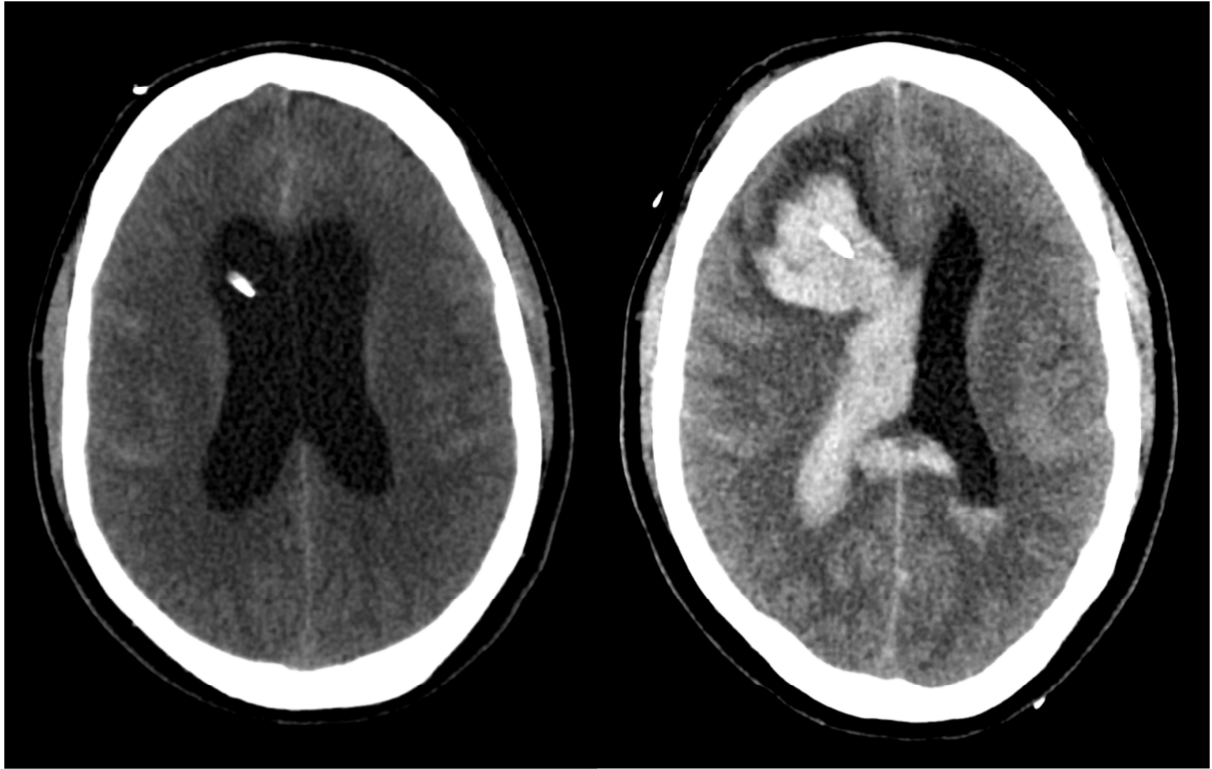
Abbreviations: IQR, Interquartile Range; GCS, Glasgow Coma Scale; ICH, Intracranial Hemorrhage; SAH, Subarachnoid Hemorrhage; WEB, Woven EndoBridge Device; ICU, Intensive Care Unit; ICA, Internal Carotid Artery; ACoA, Anterior Communicating Artery; MCA, Middle Cerebral Artery; PICA, Posterior Inferior Cerebellar Artery.

Table 2: Primary and secondary outcomes

	All patients (N=33)
Aneurysm occlusion (BOSS)*	
Complete occlusion	21/26 (81%)
No residual flow in the aneurysm/WEB	12/26 (46%)
Opacification of the proximal recess of the WEB	9/26 (35%)
Incomplete occlusion	5/26 (19%)
Residual flow inside the WEB	0 (0%)
Neck remnant	4 (15%)
Aneurysm remnant	1 (4%)
Neurological outcome (mRS)	
Favorable neurological outcome	24/33 (73%)
Unfavorable neurological outcome	9/33 (27%)
Deaths	6/33 (18%)
Early aneurysm re-bleedings	0/33 (0%)
Procedure-related ischemia	
Silent infarcts	3/33 (9%)
Lethal infarct	1/33 (3%)
*For 26 patients with available angiographic follow-up.	
Values shown as patients divided with total amount of patients (percentages).	
Complete occlusion is defined as BOSS 0 (no residual flow in the aneurysm) and 0' (opacification of the proximal recess).	
Favorable neurological outcome is defined as a modified Rankin Scale of 0 (no symptoms) to 2 (slight disability).	
<i>Abbreviations:</i> BOSS, Beaujon Occlusion Scale Score; mRS, modified Rankin Scale.	







ACCEPTED MANUSCRIPT

Abbreviations

BOSS, Beaujon Occlusion Scale Score

CT, Computerized Tomography

EHR, Electronic Health Care Record

EVD, External Ventricular Drain

GCS, Glasgow Coma Scale

HUS, Helsinki University Hospital

IA, Intracranial Aneurysm

IQR, Interquartile Range

mRS, modified Rankin Scale

PACS, Picture Achieving Communication Systems

SAH, Subarachnoid Hemorrhage

SL, Single Layer

SLS, Single Layer Sphere

TYKS, Turku University Hospital

WEB, Woven Endobridge Device