

**Review Article:****Central nervous system infections in the intensive care unit****B. Vengamma,<sup>1</sup> M. Rajguru,<sup>1</sup> B.C.M. Prasad,<sup>2</sup> V.V. Ramesh Chandra<sup>2</sup>***Departments of <sup>1</sup>Neurology, <sup>2</sup>Neurosurgery, Sri Venkateswara Institute of Medical Sciences, Tirupati***ABSTRACT**

Neurological infections constitute an uncommon, but important aetiological cause requiring admission to an intensive care unit (ICU). In addition, health-care associated neurological infections may develop in critically ill patients admitted to an ICU for other indications. Central nervous system infections can develop as complications in ICU patients including post-operative neurosurgical patients. While bacterial infections are the most common cause, mycobacterial and fungal infections are also frequently encountered. Delay in institution of specific treatment is considered to be the single most important poor prognostic factor. Empirical antibiotic therapy must be initiated while awaiting specific culture and sensitivity results. Choice of empirical antimicrobial therapy should take into consideration the most likely pathogens involved, locally prevalent drug-resistance patterns, underlying predisposing, co-morbid conditions, and other factors, such as age, immune status. Further, the antibiotic should adequately penetrate the blood-brain and blood-cerebrospinal fluid barriers. The presence of a focal collection of pus warrants immediate surgical drainage. Following strict aseptic precautions during surgery, hand-hygiene and care of catheters, devices constitute important preventive measures. A high index of clinical suspicion and aggressive efforts at identification of aetiological cause and early institution of specific treatment in patients with neurological infections can be life saving.

**Key words:** *Central nervous system infections, Intensive care unit, Meningitis, Ventriculitis*

**Vengamma B, Rajguru M, Prasad BCM, Ramesh Chandra VV. Central nervous system infections in the intensive care unit. J Clin Sci Res 2014;3:106-13. DOI: <http://dx.doi.org/10.15380/2277-5706.JCSR.13.044>.**

**INTRODUCTION**

Neurological intensive care is an emerging speciality globally. In developing countries like India, however, facilities for intensive care are not widely available.<sup>1</sup> Further, very few centres, such as, tertiary care teaching hospitals attached to medical colleges, and some of the corporate sector hospitals in the country have facilities for neurological intensive care. The recent emergence of multidrug-resistant pathogens has added to the complexity of the management of central nervous system (CNS) infections. In this review an attempt has been made to provide an overview regarding the methodological issues, burden of the problem, diagnostic approach and key principles underlying the management of neurological infections requiring admission to the ICU.

**Central nervous system infections in ICU patients**

Neurological infections can be encountered in ICU patients in the following situations. (i) CNS infections constitute an uncommon, but important aetiological cause requiring admission to an intensive care unit (ICU). In addition, (ii) health-care associated neurological infections may develop in critically ill patients admitted to an ICU for other indications. Furthermore, (iii) CNS infections can develop as complications in ICU patients including post-operative neurosurgical patients.<sup>2</sup>

**Burden of the problem****Indian scenario**

Sparse published data are available on the spectrum of neurological infections requiring

Received: 04 August, 2013.

**Corresponding author:** Dr B. Vengamma, Director, Senior Professor and Head, Department of Neurology, Sri Venkateswara Institute of Medical Sciences, Tirupati, India.  
**e-mail:** [bvengamma@yahoo.com](mailto:bvengamma@yahoo.com)



Online access

[http://svimstpt.ap.nic.in/jcsr/apr-jun\\_14\\_files/1ra214.pdf](http://svimstpt.ap.nic.in/jcsr/apr-jun_14_files/1ra214.pdf)

**DOI:** <http://dx.doi.org/10.15380/2277-5706.JCSR.13.044>

ICU admission especially from India. Furthermore, many of the critically ill patients with neurological infections variably get admitted to the medical, neurological or respiratory ICUs depending on the availability and prevailing admission policy. The variability and flexibility of policy for admitting patients with neurological infections into ICUs should be kept in mind while interpreting these data.

### **CNS infections requiring admission into an ICU**

In publication dating back to more than two decades ago<sup>2</sup> CNS infections constituted 2.3% to 10.5% of admissions into medical, surgical and critical care ICUs in India. In another report,<sup>2</sup> neurological infections constituted 51% of admissions to a neurological ICU in South India. At a teaching hospital at Hyderabad, CNS infections had accounted for 17% of admissions to a neurological ICUs.<sup>3</sup>

Coma is a common indication for admission to an ICU. In the Indian scenario CNS

infections constitute an important cause of coma. In published studies from India<sup>4,5</sup> neurological infections accounted for 20% to 57% of aetiological causes in coma patients needing admission to an ICU.

At our tertiary care teaching hospital, neurological infections accounted for 8.7% of all ICU admissions (n=252) seen during the six month period (Dec 2012 to May 2013) in the medical ICU. The spectrum of patients with neurological infections requiring admission to ICU at Sri Venkateswara Institute of Medical Sciences (SVIMS), Tirupati a tertiary care teaching hospital is shown in Table 1.

### **CNS infections developing as complications in ICU patients**

Reliable epidemiological data regarding the true prevalence of health care-associated intracranial infectious complications are not available. Sparse published data refer to post neuro-surgical infectious complications and

**Table 1: Spectrum of neurological infections requiring admission to medical intensive care unit at Sri Venkateswara Institute of Medical Sciences, Tirupati during a six-month period (Dec 2012 to May 2013)**

---

Viral meningoencephalitis (n=6)
Bacterial infections (n=3)
pyogenic meningitis
subdural empyema
cerebral abscess
Mycobacterial (n=3)
tuberculosis meningitis
tuberculomas
miliary tuberculosis with TBM
Protozoal (n=2)
neurocysticercosis
toxoplasmosis
Cryptococcal meningitis (n=1)
Systemic infections <i>with neurological involvement</i> (n=6)
scrub typhus
leptospirosis
cerebral malaria
enteric encephalopathy
dengue haemorrhagic fever
systemic sepsis with multiorgan system failure

---

CNS infections secondary to traumatic brain injury. The following conditions have been considered to be important risk factors for health-care associated CNS infections: history of neurosurgery; CSF leakage; recent head trauma; presence of an evident focus of infection; and an immunocompromised state.

Patients with aneurysmal subarachnoid hemorrhage or severe traumatic brain injury receiving neurocritical care, especially, are considered to be at high risk for infections arising at distant foci, such as, endocarditis, blood stream infections, pneumonia, urinary tract infections, among others. In patients undergoing invasive procedures, such as, craniotomy, intracranial device placement [for e.g., for intracranial pressure (ICP) monitoring, or diversion of the cerebrospinal fluid (CSF) from an obstructed ventricular system], health-care associated CNS infections (Table 2) have been known to develop.<sup>6</sup> As per the National

Healthcare Safety Network, Division of Healthcare Quality Promotion, Centers for Disease Control and Prevention (CDC/NHSN)<sup>6</sup> definition of CNS infection, intracranial infection must satisfy at least one of the criteria listed in Table 3. At least one of the criteria listed in Table 4 must be satisfied for diagnosing meningitis or ventriculitis.<sup>6</sup>

Septic thrombosis of cerebral sinus and/or veins is another documented cause of CNS infection in ICU patients. Also, neuroinfections may arise from more 'exogenous' sources such as transmission of pathogens from ICU personnel or the ICU environment; poor hand hygiene has been identified to be one of the common and important causes of health-care associated infections in ICU patients.

### **CNS infection Vs catheter colonization/contamination**

In critically ill ICU patients, it is important to distinguish CNS infections from catheter

**Table 2: Commonly encountered health-care associated central nervous system infections in ICU patients**

---

Intracranial infections
brain abscess
subdural or epidural infection
encephalitis
Meningitis or ventriculitis
Spinal abscess without meningitis

---

ICU = intensive care unit

Source: reference 6

**Table 3: Criteria for the diagnosis of definition of CNS infection (intracranial infections)**

- 
1. Patient has organisms cultured from brain tissue or dura
  2. Patient has an abscess or evidence of intracranial infection seen during a surgical operation or on histopathologic examination
  3. Patient has at least two of the following signs or symptoms with no other recognized cause: headache, dizziness, fever (>38 °C), localizing neurologic signs, changing level of consciousness, or confusion, and at least one of the following:
    - a. organisms seen on microscopic examination of brain or abscess tissue obtained by needle aspiration or by biopsy during a surgical operation or autopsy
    - b. positive antigen test on blood or urine
    - c. radiographic evidence of infection, and
    - d. diagnostic single antibody titer (IgM) or four-fold increase in paired sera (IgG) for pathogen; and if diagnosis is made antemortem, physician institutes appropriate antimicrobial therapy
- 

CNS = central nervous system; Ig = immunoglobulin

Source: reference 6

**Table 4: Criteria for the diagnosis of definition of CNS infection (meningitis or ventriculitis)**

- 
1. Patient has organisms cultured from CSF
  2. Patient has at least one of the following signs or symptoms with no other recognized cause: fever (>38 °C), headache, stiff neck, meningeal signs, cranial nerve signs, or irritability and at least one of the following:
    - a. increased white cells, elevated protein, and/or decreased glucose in CSF
    - b. organisms seen on Gram's stain of CSF
    - c. organisms cultured from blood
    - d. positive antigen test of CSF, blood, or urine, and
    - e. diagnostic single antibody titer (IgM) or four-fold increase in paired sera (IgG) for pathogen; and if diagnosis is made antemortem, physician institutes appropriate antimicrobial therapy
- 

CNS = central nervous system; CSF = cerebrospinal fluid; Ig = immunoglobulin

Source: *reference 6*

colonization and contamination. In this scenario, a positive CSF culture in the absence of abnormal CSF findings is suggestive of "contamination"; occurrence of at least two positive CSF cultures with expected CSF profiles and lack of clinical signs is suggestive of "catheter colonization".<sup>6,7</sup> Further, pathological CSF findings in the absence of positive cultures is suggestive of device-related infection; and a positive CSF culture accompanied by abnormal CSF findings or appropriate clinical scenario is suggestive of hospital acquired meningitis. It is also important to distinguish CNS infection from aseptic inflammation that occurs as a consequence of tissue response to tissue injury or stimulation by noninfectious agents.

### **CNS manifestations of systemic infections in ICU patients**

Recent trends have indicated that in addition to severe complicated falciparum malaria, enteric fever, systemic infections, such as, leptospirosis, scrub typhus are emerging as important causes for infections with CNS involvement needing ICU admission.

### **Diagnostic approach**

A thorough clinical history and a meticulously conducted physical examination often provide valuable diagnostic clues to the aetiological cause of CNS infections in critically ill patients. Occurrence of fever and deterioration in the level of sensorium; evidence of raised

intracranial pressure in a comatose or sedated patient are important early clues suggestive of CNS infection and should alert the clinicians.

A history of residence or travel from a malaria endemic area (malaria), occupations like farmers working in paddy fields, sewerage workers (leptospirosis) can help in diagnostic work-up. In patients with altered sensorium, a history of prolonged fever with loose stools, gastrointestinal bleeding may raise the possibility of enteric fever. Fever, headache, photophobia and vomiting may point to meningitis. General physical examination clues, such as, eschar (scrub typhus), peticheal rash (dengue fever, falciparum malaria, scrub typhus, leptospirosis), subcutaneous nodules (neurocysticercosis), presence of hepatic dysfunction and /or acute kidney injury (falciparum malaria, leptospirosis) may be helpful in identifying infections. While fever is often present in critically ill patients with neurological infections, some patients with life-threatening neurological infections can present without fever.<sup>8</sup> Fundus examination after mydriatic administration can help in identifying choroid tubercles which are pathognomonic of miliary tuberculosis.<sup>9</sup> Presence of lymphadenopathy, pleural effusion or ascites may point out to disseminated tuberculosis, especially in human immunodeficiency virus (HIV) seropositive individuals.<sup>10</sup> Neurological examination may reveal neck stiffness and other signs of meningeal irritation or focal neurological deficit.

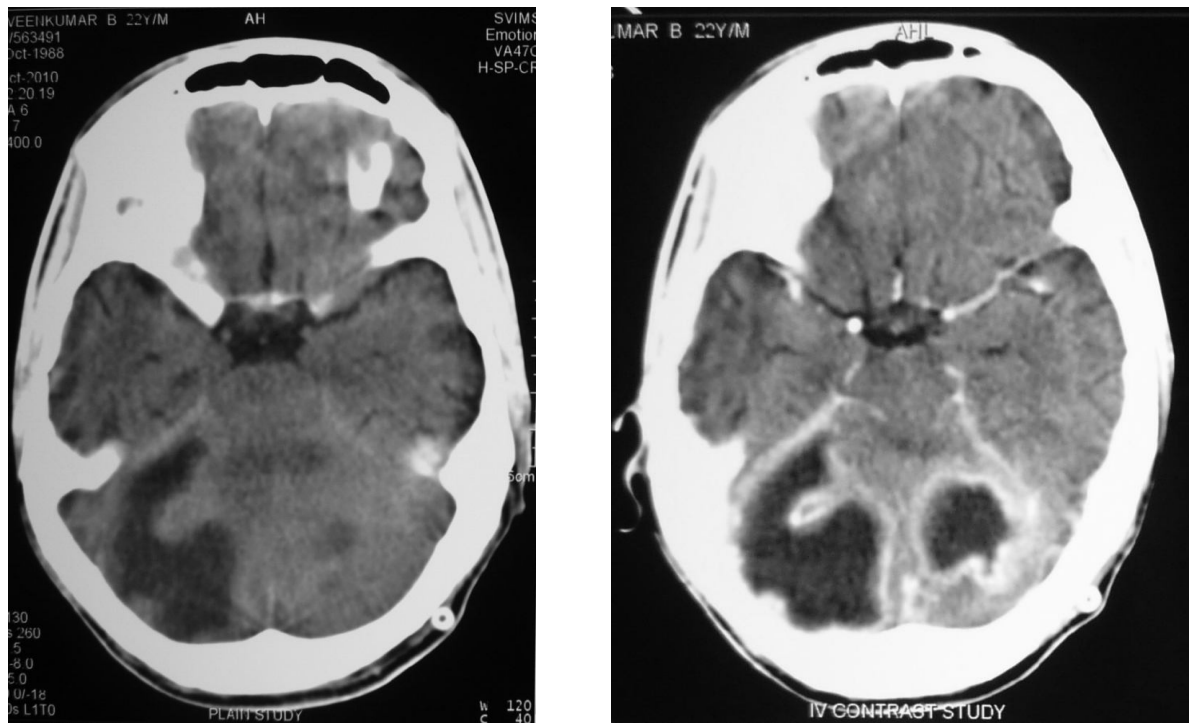
Tuberculosis meningitis (TBM) accounts for more than 70% of cases of neurological tuberculosis (TB) and is a great mimic. In spite of TBM being a commonly encountered disease and widespread physician awareness, there is often a delay in the diagnosis and institution of specific therapy for TBM. This is particularly true in the ICU setting.<sup>9,10</sup> Fungal meningitis is an uncommon but important CNS infections seen in the ICU. Clinical presentation of fungal infections may range from acute fulminant forms to chronic indolent forms causing significant morbidity and mortality. Low index of suspicion, atypical presentation, and variable neuroradiologic findings result in a delayed diagnosis of this condition. Fungal CNS infections should be suspected in patients with poorly controlled diabetes and immunosuppressed patients. Common fungal infections of CNS seen in the ICU include *Cryptococcus meningitis* (especially in HIV-positive patients), *Mucormycosis* (e.g.,

rhinocerebral mucormycosis), *Aspergillosis*, *Scedosporium*, *Candida* among others.<sup>2</sup>

Anthrax is a zoonotic disease which has recently been used as a weapon of bioterrorism. It is a rare but catastrophic cause of haemorrhagic meningoencephalitis. The diagnosis is established by Gram stain of CSF smear examination.<sup>11</sup> Fungal meningitis, viral meningitis and even TBM require extensive laboratory facilities for confirmation of aetiological diagnosis. However, these facilities are seldom available in India and most of these patients get treated empirically.

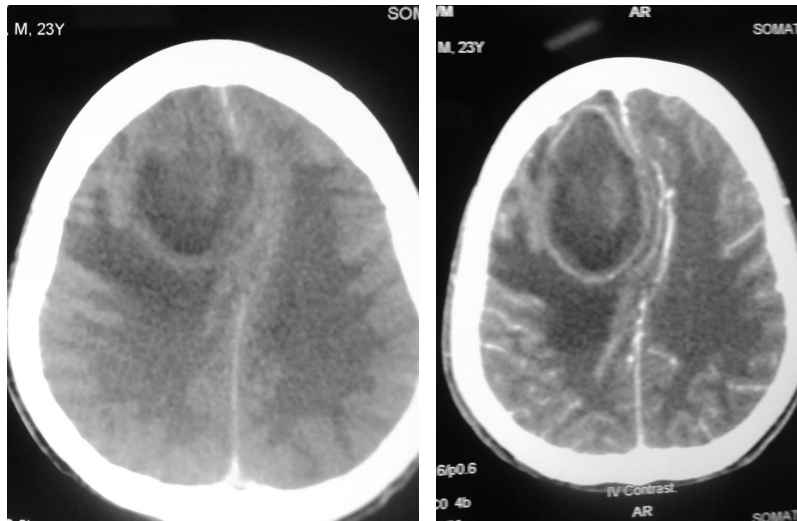
### Imaging and laboratory diagnosis

Neuroimaging and CSF analysis constitute key investigations in establishing the diagnosis of CNS infection in critically ill patients. However, CSF examination may not always be possible in critically ill patients due to the presence of increased intracranial pressure, thrombocytopenia, bleeding tendency, among



**Figure 1:** Cerebellar abscess. A 22-year-old male presented with headache, vomitings and fever of 1 week duration. There was a history of decreased hearing left side associated with ear discharge. Plain (A) and contrast-enhanced (B) CT of the brain showed cerebellar abscess with hydrocephalus. The patient underwent suboccipital craniectomy and evacuation of cerebellar abscess

CT = computed tomography

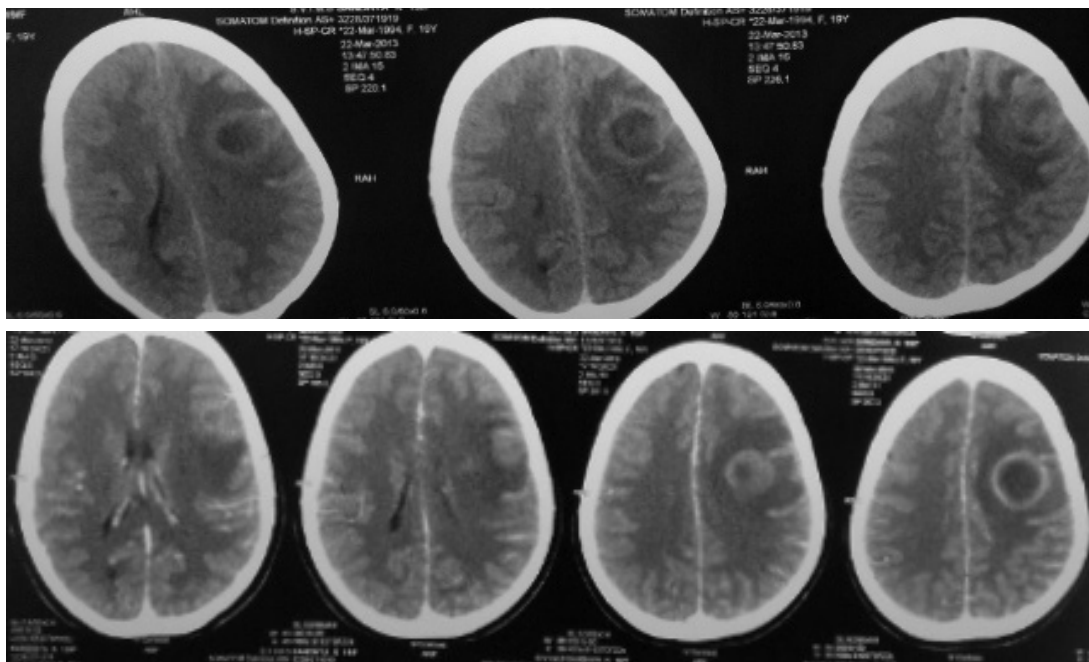
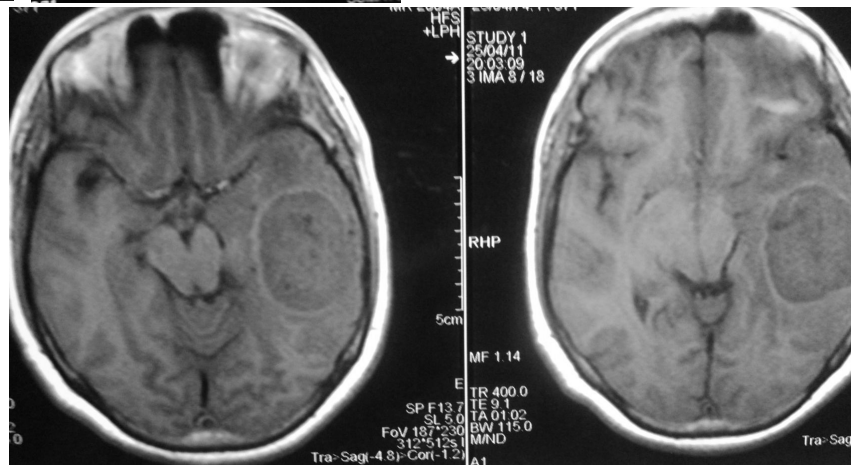


**Figure 2:** Right-sided frontal abscess. A 23-year-old male presented with headache, fever, altered sensorium of 1 week duration. Plain (A) and contrast enhanced (B) CT brain right frontal abscess. The patient underwent right frontal craniotomy and excision of abscess

CT = computed tomography

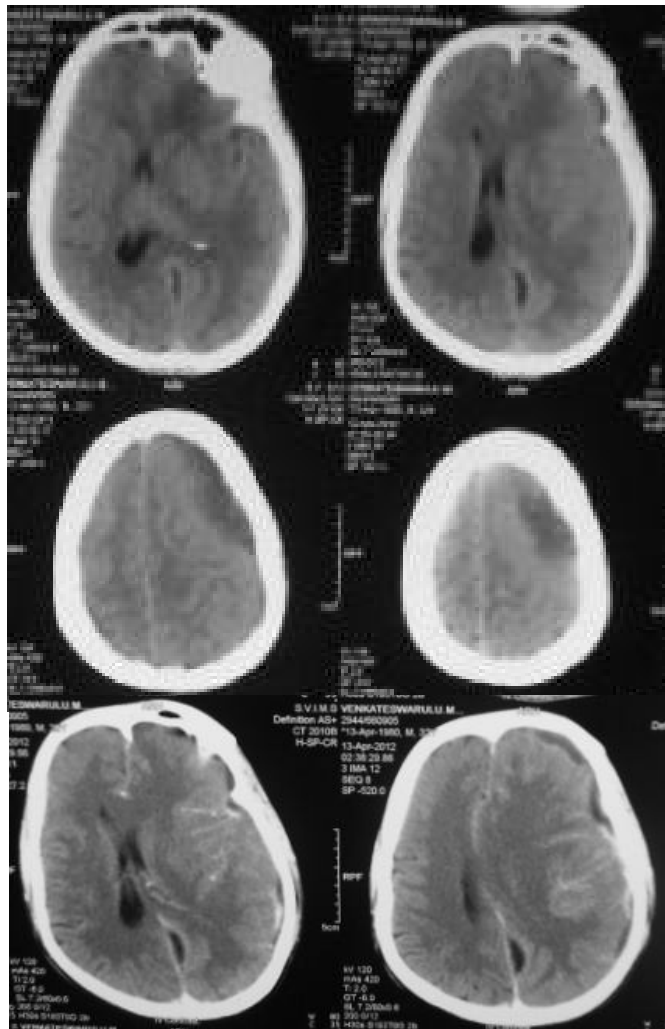
**Figure 3:** Left-sided temporal abscess. A 49-year-old male presented with fever, headache of 15 days and altered sensorium of 1 day duration. MRI brain showed left temporal abscess. The patient underwent left temporoparietal craniotomy and excision of abscess

MRI = magnetic resonance imaging



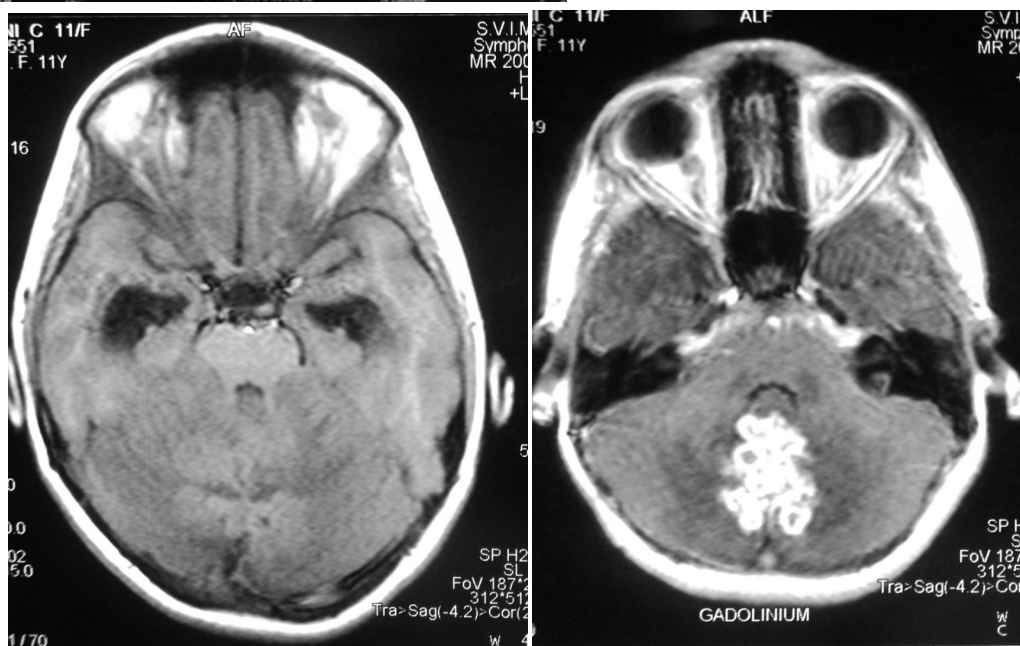
**Figure 4:** Left-sided parietal abscess. A 19-year-old lady presented with headache, vomiting and fever of 1 week, altered sensorium of 1 day and 2 episodes of generalized tonic clonic seizures. CT brain showed left parietal abscess

CT = computed tomography



**Figure 5:** Temporal subdural empyema. A 32-year-old male presented with a history of discharge from left ear and fever of 5 days duration. There was a history of 2 episodes of generalized tonic clonic seizures and 1 episode of vomiting. CT brain showed left temporal subdural empyema. The patient underwent left temporal craniotomy and evacuation of subdural empyema

CT = computed tomography



**Figure 6:** Cerebellar tuberculoma. A 11-year-old girl presented with headache, intermittent fever of 1 month. Over the last 4 days, headache increased and patient developed vomiting. MRI brain was suggestive of midline cerebellar tuberculoma. The patient underwent suboccipital craniectomy and excision of tuberculoma

others and this may hamper the diagnostic work-up.

Imaging modalities like ultrasonography, computed tomography (CT), magnetic resonance imaging (MRI) can help in anatomical localization of the focus of infection (Figures 1,2,3,4,5 and 6). Identification of aetiological cause of neurological infection requires lumbar puncture and cerebrospinal fluid examination by biochemical, microbiological and molecular diagnostic methods; blood culture and culture of urine, pleural, ascitic and other body fluids. Serodiagnostic and molecular tests for dengue fever, leptospirosis and scrub typhus infections must be carried out.

Fungal, viral meningitis and even TBM require extensive laboratory facilities for confirmation of aetiological diagnosis. However, these facilities are seldom available in India and most of these patients get treated empirically.

### Principles of management

In patients admitted to the ICU, monitoring is carried out by noninvasive and if required, invasive methods. Care should be taken regarding fluid, electrolyte and nutritional management. A detailed description of the various therapeutic regimens available for treatment of neurological infections is beyond the scope of this review.

A high index of clinical suspicion and aggressive efforts at identification of aetiological cause and early institution of specific treatment in patients with neurological infections can be life saving. Delay in institution of specific treatment (e.g., antibiotic treatment) is considered to be the single most important poor prognostic factor. Empirical antibiotic therapy must be initiated while awaiting specific culture and sensitivity results. Choice of empirical antimicrobial therapy should take into consideration the most likely pathogens involved, locally prevalent drug-resistance patterns, underlying predisposing,

co-morbid conditions, and other factors, such as age, immune status. Further, the antibiotic should adequately penetrate the blood-brain and blood-CSF barriers. The presence of a focal collection of pus warrants immediate surgical drainage. Following strict aseptic precautions during surgery, hand-hygiene and care of catheters, devices constitute important preventive measures.

---

### REFERENCES

---

1. Mohan A, Bollineni S. Predicting mortality in critically ill obstetric patients requiring intensive care unit admission in India. *Indian J Med Sci.* 2007;61:175-7.
2. Beer R, Pfausler B, Schmutzhard E. Infectious intracranial complications in the neuro-ICU patient population. *Curr Opin Crit Care* 2010;16:117-22.
3. Udawadia FE, Guntupalli KK, Vidyasagar D. Critical care in India. *Crit Care Clin* 1997;13:317-29.
4. Desai BT, Vijayaraghavan A. Neurologic intensive care in India. *Natl Med J India* 1991;4:162-5.
5. Meena AK, Prasad VS, Murthy JM. Neurological intensive care in India-disease spectrum and outcome. *Neurol India* 2001;49 Suppl 1:S1-7.
6. Horan TC, Andrus M, Dudeck MA. CDC/NHSN surveillance definition of healthcare-associated infection and criteria for specific types of infections in the acute care setting. *Am J Infect Control* 2008;36:309-32.
7. Lozier AP, Sciacca RR, Romagnoli MF, Connolly ES Jr. Ventriculostomy-related infections: a critical review of the literature. *Neurosurgery* 2002;51:170-81; discussion 181-2.
8. Launey Y, Nessler N, Mallédant Y, Seguin P. Clinical review: fever in septic ICU patients-friend or foe? *Crit Care* 2011;15:222.
9. Sharma SK, Mohan A, Sharma A. Challenges in the diagnosis & treatment of miliary tuberculosis. *Indian J Med Res* 2012;135:703-30.
10. Sharma SK, Mohan A. Tuberculosis: From an incurable scourge to a curable disease - journey over a millennium. *Indian J Med Res* 2013;137:455-93.
11. Bindu M, Vengamma B, Kumar G. Anthrax meningoencephalitis successfully treated. *Eur J Neurol* 2007;14:e18.