

Disseminated *Saprochaete capitata* in a patient with Diabetes mellitus and HCV Hepatitis; A Case Report

Jamal Wadi Al Ramahi¹,
Walid Jamal², Mustafa
Alaskar³

Abstract

Saprochaete capitata is yeast rarely causes human infections; nonetheless the vast majority of infections were reported in patients with hematological malignancy. Here, we report one of the unusually rare presentations of disseminated *Saprochaete capitata* in a patient without hematological malignancy, but the patient had a prolonged history of chronic active hepatitis C, diabetes mellitus, prolonged ICU stay on mechanical ventilation, and exposure to several antimicrobials. The currently isolated *Saprochaete capitata* showed resistance to amphotericin B, triazoles and echinocandins, but susceptible to 5-fluocytosine with MIC ≤ 1 mg/dl.

Keywords: *Saprochaete capitata*, hematological malignancy, yeast, antimicrobials exposure, antifungal resistance.

- 1 Jordan Hospital Medical Center, Amman – Jordan
- 2 Laboratory Department. Al Khalidi Hospital and Medical Center. Amman – Jordan
- 3 Pharmacy Department, Al Khalidi Hospital and Medical Center, Amman – Jordan

Corresponding author:

Dr. Jamal Wadi Al Ramahi MD, FIDSA

✉ walid_jmm@yahoo.com

Introduction

Saprochaete capitata formerly called *Geotrichum capitatum* and *Blastoschizomyces capitatus* is related to fungi that rarely cause invasive human infections; when it does, usually in the immunocompromised individuals. *Saprochaete capitata* is widely spread in nature and can be isolated from soil, plants, water, and air. It can also be found in the digestive tract in humans and other mammals, and it may be found in food but never reported to cause disease through this route. The number

of recorded *Saprochaete capitata* cases in English literature and related species so far are around 104 cases [1, 2]. Disseminated *Saprochaete capitata* was reported in few case reports of single and five-case series, causing blood stream infection with severe sepsis syndrome, multi-organ failure, and mortality. Occasionally *Saprochaete capitata* is easily missed as *Candida* species for that they share the same epidemiology, the same predisposed host, and morphologically somehow not apparently different [3, 4, 5]. Uncommonly, a related species i.e. *Geotrichum clavatum* was also reported to cause disseminated

infections in few patients with acute myeloid leukemia [6].

Saprochaete capitata breakthrough was also reported in patients suffering from hematological malignancy while being treated with echinocandin therapy; caspofungin was the agent used in those reports [7, 8, 9]. As knowledge regarding this fungus piles up, both fluconazole and echinocandins are recognized for being inadequate strategy as prophylactic or empirical antifungal treatment in patient with hematological malignancy when cases of *Saprochaete capitata* were found colonizing hematology unit and a potential threat to patients. Moreover, there is no consensus on the best antifungal regimen to prescribe in disseminated disease as it is resistant to most antifungal agents in clinical use [4].

Case report

A 78 years old female patient, she was admitted on 3 December 2014 to Al khalidi Hospital and Medical Centre, with the diagnoses of dementia, diabetes mellitus, and previously treated chronic HCV hepatitis. Eighteen months earlier she finished her pegylated interferon and ribavirin treatment. Her acute history dates back to five weeks when she was admitted to another general hospital not feeling well with decreased appetite, she developed sudden onset of nausea and vomiting, few hours later she lost her consciousness and was intubated for respiratory difficulty. She was diagnosed as having had an episode of diabetic ketoacidosis, spent more than two weeks in ICU and was managed to be extubated later. During her ICU stay she was treated as sepsis; suspected ventilator-associated pneumonia (VAP) due to *Acinetobacter baumannii*, and she was started on meropenem and colistin for 14 days. Blood culture grew yeast which was not characterized then.

On arrival to our hospital she was in deep coma with breathing difficulty, no spontaneous movements, puffy face, and mechanical ventilation was resumed; septic work up including blood cultures was commenced, she had pulmonary infiltrates that was progressively improving on daily radiological evaluation, with no stigmata of infective endocarditis. Initial laboratory finding upon admission showed: WBC: 19.7K HB: 7.6, Platelets 60K, INR: 2.18. Blood film showed normochromic anisocytosis with mild rouleaux formation, WBC's showed leucocytosis with neutrophilia, no immature cells seen, reduced platelets without clumps. Normal liver enzymes (ALT = 10 U/L and AST = 26 U/L), and normal liver ultrasound, abdominal CT scan showed "heterogeneous liver with spots of calcifications, no definite liver masses were detected". 2D-echocardiography was normal. Brain CT showed no focal brain changes, but wide spread brain atrophy and de-pneumatized sphenoid sinus filled with fluid and mucosal swelling. She was started on intravenous meropenem, four days later treatment with micafungin 100 mg/day was added (weight = 75 Kg) when her aerobic blood cultures grew yeast, and it was evident from direct smear and gram-stained (**Figure 1**). After 43 hours of incubation in BacT-ALERT (Biomérieux S.A. Chemin de l'Orme 69280. Marcy l'Etoile, FRANCE) the yeast was identified as *Saprochaete capitata*, then meropenem was discontinued. Subculture on Sabouraud dextrose agar plate grew in 24 hours, and was processed in VITEK II (Biomérieux S.A. Chemin de l'Orme,69280. Marcy l'Etoile, FRANCE) using identification card. Susceptibility patterns showed resistance to the tested antifungals; amphotericinB (MIC ≥ 16 mg/dl), echinocandins (caspofungin MIC ≥ 4 mg/dl, micafungin MIC ≥ 4 mg/dl), fluconazole (MIC ≥ 4 mg/dl) and voriconazole (MIC = 4 mg/dl) but 5-fluocytosine was susceptible (MIC ≤ 1 mg/dl). The patient died eleven days after her admission, and seven days of micafungin treatment.

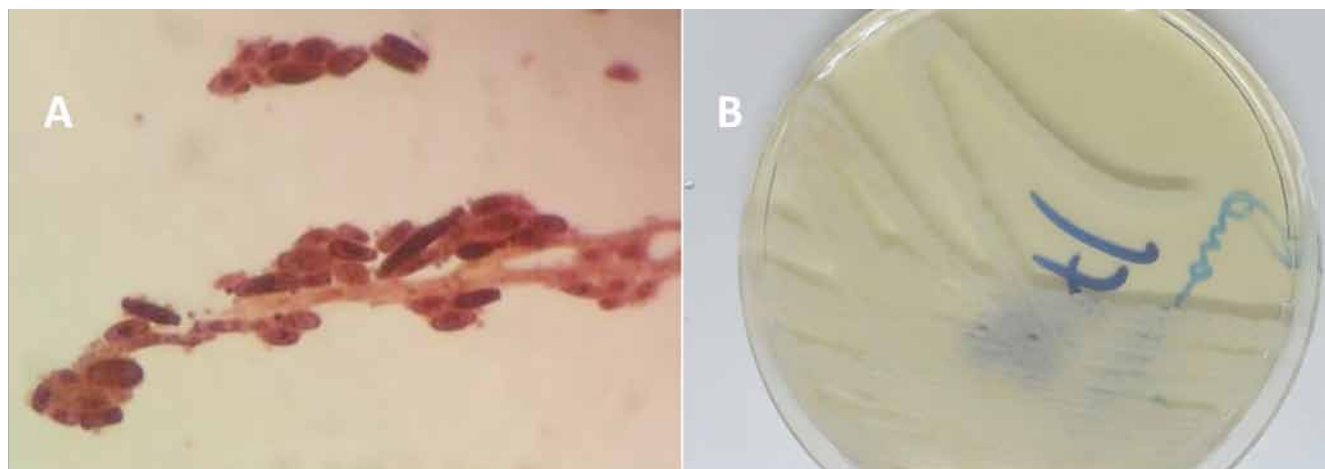


Figure 1. The appearance of *Saprochaete capitata* on gram stain (A), and on Muller-Hinton growth media (B).

Discussion

Mazzocato and his coworkers reported in July 2014, their literature review between 1977 and August 2013, they identified 104 cases of *Saprochaete capitata* including their reported cases. They found that the patients' median age was 56 years, 56% were males, and half of them had acute myeloid leukemia, 22% with acute lymphoid leukemia, and 22% with other malignancies. The majority of patients (82%) were neutropenic at the time of diagnosis, and 75% of *Saprochaete capitata* were isolated from blood. Mortality was about 60% and amphotericin was the mostly prescribed antifungal [2]. After their report, two cases were reported by other investigators as well as our current case [5, 7]. Our patient did not have hematological malignancy like earlier reports, rather diabetes mellitus and HCV hepatitis as comorbidities. Initially, elsewhere the fungus was described as yeast, possibly *Candida*, which may have not been an uncommon occurrence in many microbiological laboratories; in our hospital automated processing revealed the true nature of the yeast as *Saprochaete capitata* [4].

The patient presented to us in coma and looking severely ill, next day she needed ventilator support and vasopressors. She met her demise suffering from multiorgans dysfunction and failure. Here, *Saprochaete capitata* isolate was resistant to the tested antifungals, this agrees with the previously published literature from different authors that disseminated infection with *Saprochaete capitata* is usually difficult to treat and carries high mortality [2, 7,8]. This is one of the rare cases of disseminated *Saprochaete capitata* in a patient without hematological malignancy; however the patient had a prolonged ICU stay, mechanical ventilation, and was exposed to several antibacterials, which are known risk factors for acquiring invasive candidiasis [10, 11]. *Saprochaete capitata* seemed to have similar risk factors like invasive candidiasis. The patient was started on micafungin soon after blood culture revealed yeast; however it was too late for that she had previous untreated and persistent 'yeast' blood infection [12]. It showed that starting antifungal therapy did not alter her expected poor prognosis though a repeat blood culture few days after antifungal therapy showed no growth of *Saprochaete capitata* or any other microorganism.

Acknowledgment

We thank Professor David Denning(Professor of Infectious Diseases in Global Health at The University of Manchester, Global Action Fund for Fungal Infections, The University of Manchester and University Hospital of South Manchester, LIFE - Leading International Fungal Education) for his critical review of the manuscript.

References

- Pottier I, Gente S, Vernoux J Paul, Guéguen M. Safety assessment of dairy microorganisms: *Geotrichum candidum*. *Int J Food Microbiol* 2008 ; 1;126(3):327–332
- Mazzocato S, Marchionni E, Fothergill AW, Sutton DA, Staffolani S, et al. Epidemiology and outcome of systemic infections due to *saprochaete capitata*: case report and review of the literature. *Infection* 2014 July. DOI:10.1007/s15010-014-0668-3
- López I V, Doblas A Carlos, Saavedra JM, Herrera-Carranza M. Multi-organ failure in a patient with fungaemia due to *Saprochaete capitata*. *Rev Iberoam Micol* 2013;30(4):261-263.
- García-Ruiz JC, López-Soria L, Olazábal I, Amutio E, Arrieta-Aguirre I, et al. Invasive infections caused by *Saprochaete capitata* in patients with haematological malignancies: Report of five cases and review of the antifungal therapy. *Rev Iberoam Micol* 2013;30(4):248-255
- Pemmaraju N, Shetty VA, Prieto GV, Jain N, Kontoyiannis PD, Borthakur G. Disseminated *Saprochaete capitata* (formerly known as *Geotrichum capitatum* and *Blastoschizomyces capitatus*) in a patient with acute myeloid leukemia. *Eur J Haematol* 2014; 93(6):543–544
- PicardM, Cassaing S, Letocart P, Verdeil X, Caroline Protin C, et al. Concomitant cases of disseminated *Geotrichum clavatum* infections in patients with acute myeloid leukemia 2014 *MBio* ;55(5):1186-1188.
- Purohit P, Al-Obaid I, Al-Oneizi E, Al-Hindi O, Joseph L, et al. Breakthrough disseminated *Saprochaete capitata* infection in a child with acute myeloid leukaemia receiving caspofungin therapy. *JMM Case Reports* 2014. DOI 10.1099/jmmcr.0.001750
- Schuermans C, van Bergen M, Coorevits L, Verhaegen,J, Lagrou K, et al. Breakthrough *Saprochaete capitata* infections in patients receiving echinocandins: case report and review of the literature. *Med Mycol* 2011; 49 (4): 414-418. doi: 10.3109/13693786.2010.535179
- Gomes ZRM, Jiang Y, Mulanovich VE, Lewis ER, Kontoyiannisa PD. Effectiveness of Primary Anti-*Aspergillus* Prophylaxis during Remission Induction Chemotherapy of Acute Myeloid Leukemia. *Antimicrob Agents Chemother* 2014;58(5):2775–2780
- Bouza E, Patricia M. Epidemiology of candidemia in intensive care units. *Int J Antimicrob Agents* 2008;32:S87–S91
- Blumberg HM, William JR, Soucie MJ, Edwards EJ, Patterson EJ, et al, and the NEMIS Study Group. Risk Factors for Candidal Bloodstream Infections in Surgical Intensive Care Unit Patients: The NEMIS Prospective Multicenter Study. *Clin Infect Dis* 2001; 33:177–86
- Morrell M, Fraser JV, Kollef HM. Delaying the Empiric Treatment of *Candida* Bloodstream Infection until Positive Blood Culture Results Are Obtained: a Potential Risk Factor for Hospital Mortality. *Antimicrob. Agents Chemother.* 2005;49(9): 3640-3645

Comment on this article:



<http://medicalia.org/>

Where Doctors exchange clinical experiences, review their cases and share clinical knowledge. You can also access lots of medical publications for free. **Join Now!**

Publish with iMedPub

<http://www.imed.pub>

The Journal is an open access peer-reviewed journal that publishes scientific papers about all aspects of antimicrobials. The journal will publish original research articles, reviews, brief reports and case reports dealing with basic and clinical antibacterial agents, antiviral, antiprotozoals, antituberculous, antifungal and antihelminthes agents. All manuscripts must be prepared in English, and are subject to a rigorous and fair peer-review process. Accepted papers will immediately appear online. The journal aims to advance the knowledge, attitude and the research of chemotherapy in the Arabic world in cooperation with international, national scientific and public societies as well as research centers with similar aims and objectives.

Submit your manuscript here:
www.iajaa.org