



CASE REPORT

Pancreatic Involvement in Hermansky–Pudlak Syndrome- A Case Report

Abid Nawaz¹, Vinesh Kumar², Nauman Shaukat¹, Aslam Khan³, Bilal Awan, Safia Shaikh⁴, Aqsa Iqbal⁵.

¹ Lady Reading Hospital, Peshawar, Khyber Pakhtunkhwa, 25000, Pakistan.

² South City Hospital, Karachi, Sindh, 75600, Pakistan.

³ Bajwa Hospital, Lahore, Punjab, 54950, Pakistan.

⁴ SSM Health St Mary's Hospital, St. Louis, MO, 63117, USA

⁵ University of Illinois at Chicago, Chicago, Illinois, 60610, USA.

Corresponding Author: Aqsa Iqbal, MD Email: aiqbal20@uic.edu

ARTICLE INFO

Article history Received:
July 12, 2018
Accepted: Sept 21, 2018
Published: Oct 31, 2018
Volume: 3
Issue: 4

Key words:

Hermansky–Pudlak Syndrome, Pulmonary Fibrosis, Renal Complication, Pancreatic Atrophy

ABSTRACT

Hermansky-Pudlak Syndrome (HPS) is a rare autosomal recessive disorder that presents with oculocutaneous albinism, bleeding disorders, and immunodeficiency. Granulomatous colitis and pulmonary fibrosis are two major complications of this syndrome. On rare instances, HPS can involve the heart and lungs. This report discusses a 32-year-old man who presented with oculocutaneous albinism and immunodeficiency along with renal, pulmonary, and pancreatic complications. Pancreatic atrophy is a unique finding in our patient, which has not been reported in the literature. The purpose of our case report is to bring into light unusual complications of HPS so that timely action could be taken to avoid the progression of complications.

INTRODUCTION

Hermansky-Pudlak Syndrome (HPS) usually presents as oculocutaneous albinism, bleeding diathesis, and pulmonary fibrosis (PF). The disease was first described in 1959 and was named after Frantisek Hermansky and Pavel Pudlak [1]. HPS is a rare autosomal recessive disorder which is predominantly seen in northwest Puerto Rican populations [2]. The incidence of disease in the Puerto Rican population is 1/500,000. It most commonly occurs sporadically in the Indian sub-continent. Pulmonary fibrosis is usually diagnosed late in the disease process and is the major cause of early death. There are 10 different types of HPS based on 10 different genetic associations [3]. Here, we describe a 37-year-old male patient who was diagnosed with HPS and had developed pancreatic, renal, and pulmonary complications. This is the first case report of HPS in which we see pancreatic complications.

CASE PRESENTATION

A 32-year-old non-smoker male from Afghanistan presented to North-West General Hospital Peshawar in 2014, with severe shortness of breath and dry cough for one week. The shortness of breath was present at rest. On physical examination, he was in respiratory distress, using accessory muscles of respiration, and cyanotic. Jugular venous pressure was normal. The patient had no pedal edema. Hand examination revealed clubbing present in all fingers. Chest examination showed bilateral diffuse inspiratory crackles and prolonged

expiration with expiratory rhonchi. Oxygen saturation on pulse oximetry was 92% on room air. Chest radiograph revealed bilateral reticular patterns that were predominant in the lower zone, highly suggestive of interstitial lung disease. A high-resolution computed tomography scan of lungs was ordered which showed reticular opacities in both lungs and areas of subpleural honeycombing. On spirometry, the lung volumes showed a severe restrictive pattern with forced vital capacity (FVC) of 27% of the predicted. He was acutely managed with high flow oxygen, salbutamol and ipratropium nebulization, and intravenous steroid.

On detailed medical history and review of medical records, we found that the patient had dry cough refractory to bronchodilator therapy since 2008, which was progressively getting worse. Two years later in 2010, the patient developed shortness of breath on exertion. At that time, his electrocardiogram, echocardiogram, and computed tomography brain scan were normal, but his high resolution computed tomography of the chest showed diffusely distributed small cysts in bilateral lung parenchyma predominantly on the left side. He was treated symptomatically with antibiotics and anti-tussive and was advised for regular follow-up. A year forward, in 2011, the patient developed type 1 respiratory failure, which was managed with corticosteroids and long-term oxygen therapy. In 2012, repeat computed tomography scans showed areas of interstitial thickening with a honey-comb appearance and mild fibrosis suggestive of interstitial lung disease.

Past medical history was significant for recurrent infections,

which include left otitis media in 2010 and urinary tract infection, which were treated with carbapenems. The patient was also diagnosed with hydronephrosis of the right kidney and chronic pyelonephritis of left kidney. His previous computed tomography report revealed extrahepatic portal hypertension and atrophy of body and tail of the pancreas. The patient had been hospitalized multiple times in Afghanistan, Pakistan, and India from 2010 to 2014.

It was noted that his problems started 15 years back, with gradually increasing photophobia, eye pain, and decreased vision for which he had taken treatment from local doctors in Afghanistan.

General examination showed that the patient had hypopigmentation of hair and skin (Figure 1) and clubbing of fingers. The eye examination revealed nystagmus of both eyes. A fundal analysis showed bilateral hypopigmented fundus and hypoplastic fovea.

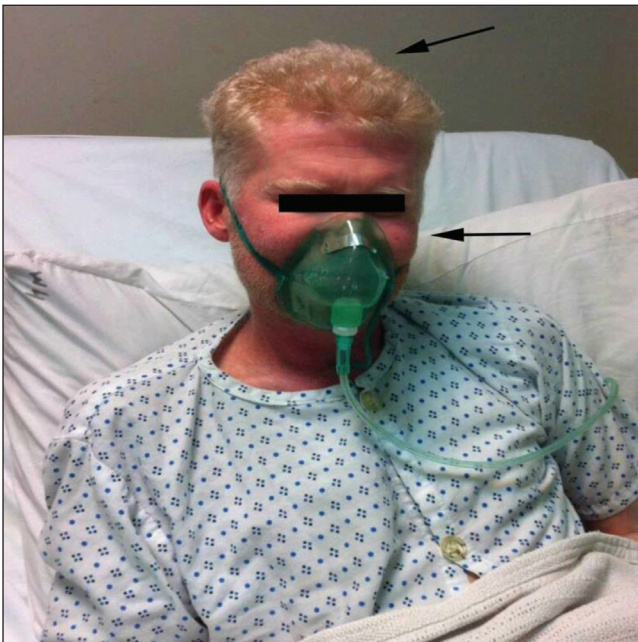


Figure 1: Hypopigmentation of skin and hairs

Laboratory test analysis was significant for slightly elevated urea and creatinine. Blood urea nitrogen levels were 51mg/dl and, creatinine was 1.30mg/dl.

Based on above-mentioned findings, our patient was diagnosed with Hermansky Pudlak Syndrome. He was counseled about the diagnosis, its course, and prognosis. He was treated symptomatically and discharged home on medications and long-term oxygen therapy.

DISCUSSION

We presented a case of a 32-year-old male who came in with oculocutaneous albinism, immunodeficiency, pulmonary, renal, and pancreatic complications of Hermansky-Pudlak Syndrome. Hermansky-Pudlak Syndrome (HPS) is an autosomal recessive disorder which is characterized by oculocutaneous albinism, a storage-pool deficiency, and lysosomal accumulation of ceroid lipofuscin [4]. Mutations in the gene involved in packaging and formation of specialized lysosomes includ-

ing melanosomes and dense platelet granules are involved in the pathogenesis of this syndrome [5]. The albinism causes congenital nystagmus and decreased visual acuity as well as transillumination of the iris and hypopigmentation of skin and hair [6]. Our patient presented with hypopigmented skin and ocular findings, which were typical of HPS. Recurrent otitis media and urinary tract infection define immunodeficiency due to ceroid accumulation in neutrophils.

Our patient presented with respiratory findings of HPS. In HPS, respiratory complications typically occur in the third and fourth decade of life [7]. Pathogenesis of pulmonary involvement in HPS includes dysfunctional alveolar epithelial cells, which leads to increased production of monocyte chemoattractant protein (MCP-1). MCP-1 leads to reactivation and recruitment of lung macrophages, which produce transforming growth factor- β (TGF- β). TGF- β amplifies fibrotic cascade, causing alveolar epithelial cells apoptosis and stimulation of fibrotic remodeling. Several cases on the pulmonary involvement of HPS had been reported. Sugino et al. reported a 30-year-old HPS patient who had pulmonary fibrosis as well as emphysema [8]. Kelil et al. reported a 30-year-old HPS patient who presented with pulmonary fibrosis [9]. Our patient presented with the same complications as the above-mentioned patients.

Our patient also presented with renal complications. Renal findings include hydronephrosis of the right kidney and chronic pyelonephritis of left kidney. Chronic pyelonephritis in our patient could be the result of immunodeficiency whereas hydronephrosis of the right kidney might be the result of renal stones. Abdullah et al. described a 55-year-old HPS patient who developed end-stage renal disease due to interstitial deposits of ceroid lipofuscin [10]. Gordilla et al. described another case of HPS who had stage II chronic kidney disease and developed focal segmental glomerulosclerosis later in life [11]. Our patient presented with different renal manifestations of HPS which had never before been reported.

Besides typical clinical features of HPS and respiratory and renal findings, our patient also had portal hypertension and atrophy of the head and neck of the pancreas. To the best of our knowledge, this is the first case report which mentions pancreatic involvement in HPS. The mechanism behind pancreatic atrophy is unknown. A possible explanation can be the accumulation of ceroid lipofuscin, an amorphous lipid-protein complex, in biliary or pancreatic duct or within pancreatic parenchyma, which could cause pancreatic atrophy in the same way as ceroid lipofuscin causes pulmonary fibrosis [12]. Patients with HPS should undergo screening for pancreatic involvement early in the disease process to avoid progression of pancreatic complication.

All patients with albinism should be searched for other findings of HPS, and if found positive, they should be started on early treatment. More research needs to be done to understand pathogenesis and invent definitive therapy for lysosomal storage disease and ceroid lipofuscin deposition to avoid complications of HPS.

The storage pool defect is because of the absence of platelet dense bodies, which has adenosine diphosphate, adenosine triphosphate, calcium, and serotonin inside it, and is responsible for secondary aggregation response of platelets [13]. Patients

with HPS have easy bruising of soft tissues and prolonged bleeding after dental extraction and surgical procedures; prophylaxis with desmopressin can be effective [14]. Luckily, our patient did not present with bleeding, and bleeding time was normal. Avoidance of aspirin products is essential. The accumulation of ceroid lipofuscin, an amorphous lipid-protein complex, is associated with pulmonary fibrosis and granulomatous colitis [15-16].

CONCLUSION

Hermansky-Pudlak syndrome should be considered in the differential diagnoses in patients presenting with respiratory symptoms in addition to oculocutaneous albinism. Our patient presented with pulmonary, renal, and pancreatic complications along with other usual clinical findings. HPS can involve multiple organs of the body so patients should be actively screened for pulmonary, renal and pancreatic complications.

AUTHOR CONTRIBUTION

All authors contributed equally in this case and manuscript.

CONFLICT OF INTEREST

None.

Funding

None.

REFERENCES

- Hermansky F, Pudlak P: Albinism associated with hemorrhagic diathesis and unusual pigmented reticular cells in the bone marrow: report of two cases with histochemical studies. *Blood*. 1959, 14:162-169.
- Witkop CJ, Babcock MN, Rao GHR, et al.: Albinism and Hermansky-Pudlak syndrome in Puerto Rico. *Bol Asoc Med P R*. 1990, 82:333-339.
- Stearman RS, Cornelius AR, Young LR, et al.: Familial pulmonary fibrosis and Hermansky-Pudlak syndrome rare missense mutations in context. *Am J Respir Crit Care Med*. 2019, 1-11. 10.1164/rccm.201902-0457LE
- Garay SM, Gardella JE, Fazzini EP, Goldring RM: Hermansky-Pudlak syndrome: pulmonary manifestations of a ceroid storage disorder. *Am J Med*. 1979, 66:737-747. 10.1016/0002-9343(79)91111-2
- Loredana M, Schafernak KT, Gray J, Berry A, Paller AS, Mancini AJ: Hermansky-Pudlak syndrome: Report of two patients with updated genetic classification and management recommendations. *Pediatr Dermatol*. 2017, 34:638-646. 10.1111/pde.13266
- Lore Power B, Ferreira CR, Chen D, et al.: Hermansky-Pudlak syndrome and oculocutaneous albinism in Chinese children with pigmentation defects and easy bruising. *Orphanet J Rare Dis*. 2019, 14:1-11. 10.1186/s13023-019-1023-7
- Saeedan M, Faheem MS, Mohammed TL: Hermansky-Pudlak syndrome: high-resolution computed tomography findings and literature review. *Curr Probl Diagn Radiol*. 2015, 44:383-385. 10.1067/j.cpradiol.2015.01.003
- Keishi S, Kyoko G, Naoshi K: Acute exacerbation of combined pulmonary fibrosis and emphysema associated with Hermansky-Pudlak syndrome. *Respirol Case Rep*. 2015, 44:13-15. 10.1002/rcr2.141
- Kelil T, Shen J, O'Neill AC, Howard SA: Hermansky-pudlak syndrome complicated by pulmonary fibrosis: radiologic-pathologic correlation and review of pulmonary complications. *J Clin Imaging Sci*. 2014, 4:1-5. 10.4103/2156-7514.143437
- Abdullah N, Davis NF, Quinn J, Mohan P: Living donor renal transplant in a patient with end-stage renal disease due to Hermansky-Pudlak syndrome. *BMJ Case Rep*. 2018, 2018:10.1136/bcr-2017-223376
- Gordillo R, Del Rio M, Thomas DB, Flynn JT, Woroniecki RP: Hypertension, chronic kidney disease, and renal pathology in a child with Hermansky-Pudlak syndrome. *Int J Nephrol*. 2011, 2011:1-5. 10.4061/2011/324916
- Sánchez-Guiu I, Torregrosa JM, Velasco F, Antón AI, Lozano ML, Vicente V, Rivera J: Hermansky-Pudlak syndrome. overview of clinical and molecular features and case report of a new HPS-1 variant. *Hamostaseologie*. 2014, 34:301-319. 10.5482/HAMO-14-06-0024
- Ambrosio AL, Di Pietro SM: Storage pool diseases illuminate platelet dense granule biogenesis. *Platelets*. 2017, 28:138-146. 10.1080/09537104.2016.1243789
- Rivera-Concepción J, Acevedo-Canabal J, Burés A, Vargas G, Cadilla C, Izquierdo NJ: Bleeding assessment in female patients with the Hermansky-Pudlak syndrome-A case series. *Eur J Haematol*. 2019, 102:432-436. 10.1111/ejh.13210
- Harmon KR, Witkop CJ, White JG, et al.: Pathogenesis of pulmonary fibrosis: platelet-derived growth factor precedes structural alterations in the Hermansky-Pudlak syndrome. *J Lab Clin Med*. 1994, 123:617-627.
- Schinella RA, Greco MA, Cobert BL, Denmark LW, Cox RP: Hermansky-Pudlak syndrome with granulomatous colitis. *Ann Intern Med*. 1980, 92:20-23. 10.7326/0003-4819-92-1-20