

**Dieses Dokument ist eine Zweitveröffentlichung (Verlagsversion) /  
This is a self-archiving document (published version):**

Andrzej Boszczyk, Sławomir Kwapisz, Martin Krümmel, Rene Grass, Stefan Rammelt

## **Correlation of Incisura Anatomy With Syndesmotic Malreduction**

**Erstveröffentlichung in / First published in:**

*Foot & Ankle International*. 2018, 39(3), S. 369 – 375 [Zugriff am: 14.08.2019]. SAGE journals.  
ISSN 1944-7876.

DOI: <https://doi.org/10.1177/1071100717744332>

Diese Version ist verfügbar / This version is available on:

<https://nbn-resolving.org/urn:nbn:de:bsz:14-qucosa2-354904>

„Dieser Beitrag ist mit Zustimmung des Rechteinhabers aufgrund einer (DFGgeförderten) Allianz- bzw. Nationallizenz frei zugänglich.“

This publication is openly accessible with the permission of the copyright owner. The permission is granted within a nationwide license, supported by the German Research Foundation (abbr. in German DFG).

[www.nationallizenzen.de/](http://www.nationallizenzen.de/)

# Correlation of Incisura Anatomy With Syndesmotic Malreduction

Foot & Ankle International  
2018, Vol. 39(3) 369–375  
© The Author(s) 2017  
Reprints and permissions:  
sagepub.com/journalsPermissions.nav  
DOI: 10.1177/1071100717744332  
journals.sagepub.com/home/fai

Andrzej Boszczyk, MD, PhD<sup>1</sup>, Sławomir Kwapisz, MD<sup>1</sup>,  
Martin Krümmel, MD<sup>2</sup>, Rene Grass, MD, PhD<sup>3</sup>, and Stefan Rammelt, MD, PhD<sup>3</sup>

## Abstract

**Background:** The anatomy of the syndesmosis is variable, yet little is known on the correlation between differences in anatomy and syndesmosis reduction results. The aim of this study was to analyze the correlation between syndesmotic anatomy and the modes of syndesmotic malreduction.

**Methods:** Bilateral postreduction ankle computed tomography (CT) scans of 72 patients treated for fractures with syndesmotic disruption were analyzed. Incisura depth, fibular engagement into the incisura, and incisura rotation were correlated with degree of syndesmotic malreduction in coronal and sagittal planes as well as rotational malreduction.

**Results:** Clinically relevant malreduction in the coronal plane, sagittal plane, and rotation affected 8.3%, 27.8%, and 19.4% of syndesmoses, respectively. The syndesmoses with a deep incisura and the fibula not engaged into the tibial incisura were at risk of overcompression, anteverted incisuras at risk of anterior fibular translation, and retroverted incisuras at risk of posterior fibular translation.

**Conclusions:** Certain morphologic configurations of the tibial incisura increased the risk of specific syndesmotic malreduction patterns.

**Level of Evidence:** Level III, comparative study.

**Keywords:** ankle joint, anatomy, tomography, syndesmosis, injury, reduction techniques

The anatomy of the syndesmosis has been found to have great variability.<sup>8-10,14,19,20</sup> While this variability is well known, little is known on the correlation between differences in anatomy and reduction results. Moreover, we are not aware of any reduction technique considering different anatomical configurations of the syndesmosis. To our knowledge, this issue has up to now been studied in only 1 study on 35 patients that focused on the depth of the incisura<sup>4</sup> while incisural rotation and fibular engagement have not yet been studied. We believe that an increased understanding of the influence of syndesmotic anatomy on malreduction patterns may lead to implementation of an individual morphology-based operative technique and improved reduction results.

The aim of this study was to address the question if the differences in the syndesmotic anatomy may affect the quality of reduction of the syndesmosis in malleolar fractures with syndesmotic disruption. We hypothesized that certain anatomic features of the incisura (incisura depth and rotational orientation) as well as the depth to which the fibula enters the incisura (fibular engagement) would influence the accuracy of reduction.

## Methods

The study population consisted of 75 consecutive patients who received bilateral ankle computed tomography (CT) as

a routine postoperative control within 3 days after surgery for unilateral ankle fracture with syndesmotic disruption requiring stabilization.<sup>23</sup> All patients were treated with internal fixation of the malleolar fractures and transsyndesmotic screw placement. From this group, 3 patients were excluded because malreduction of the malleolar fracture, such as fibular shortening, made it impossible to measure the desired parameters. This left a group of 72 patients for analysis. The remaining 3 patients underwent repeat reduction. The study group consisted of 30 women and 42 men, with an average age of 44.3 years (range, 16.7–74.4 years; median, 43.6 years). Medical Centre of Postgraduate Education.

A Weber type C fibular fracture (suprasyndesmotic fracture) was present in 68 patients. The fracture was deemed to

<sup>1</sup>Centre of Postgraduate Medical Education, Prof. Adam Gruca Clinical Hospital, Otwock, Poland

<sup>2</sup>Dritter Orden Clinical Hospital Munich-Nymphenburg, Munich, Germany

<sup>3</sup>University Hospital Carl Gustav Carus at the TU Dresden, Dresden, Germany

## Corresponding Author:

Andrzej Boszczyk, MD, PhD, Centre of Postgraduate Medical Education, Prof. Adam Gruca Clinical Hospital, Konarskiego Str. 13, Otwock, 05-400, Poland.

Email: ortopedia@boszczyk.pl

represent Weber type C if all fracture lines started above 4 cm from the tibial plafond as measured after reduction. In 7 patients, a high fibular fracture (Maisonneuve injury) was present.

The patients underwent standard operative treatment with open reduction and internal fixation.<sup>7,24</sup> If a posterior malleolus fracture extending into the fibular incisura of the distal tibia was present, the posterior tibial fragment was reduced and fixed first with screws or a plate via a posterolateral approach.<sup>1</sup> Then, the fibular fracture was anatomically reduced and stabilized with a posterior or lateral plate followed by screw fixation of a medial malleolar fracture when present. After fracture fixation, an intraoperative external rotation test was performed. After confirming syndesmotic instability, a clamp was applied to reduce the syndesmosis. The surgeon aimed at placing the clamp parallel to the intermalleolar axis running from the tip of the medial and lateral malleolus.<sup>24</sup> After confirming the quality of reduction fluoroscopically with a lateral and mortise view, a tricortical 3.5-mm set screw was introduced. In Maisonneuve fractures, 2 syndesmotic screws were used.

CT examination was performed with the patient supine with a multidetector scanner (General Electric, Germany). Both feet were placed with the ankle in neutral position and parallel to each other in a holding device. The operated extremity was protected in a splint. The parameters for image acquisition were as follows: section collimation 0.75 mm and section thickness 0.75 mm, with a reconstruction overlap of 0.5 mm, 120 kV, and 120 mA.

At each CT, 2 pairs of horizontal cuts were identified—one pair for the affected and one for the unaffected extremity. The cuts were parallel to the tibial plafond, the first cut 10 mm proximal and the second 10 mm distal to the plafond. The overview of the measurements performed is summarized in Table 1 while the detailed descriptions are in the text.

### **Assessment of Incisura Anatomy**

The anatomy of the fibular incisura of the tibia was assessed with 3 parameters: depth, engagement, and rotation of the incisura (Table 1).<sup>2</sup> All measurements were performed on a horizontal cut 10 mm proximal to the tibial plafond on the unaffected extremity.

#### **Incisura Depth—Depth**

First, a line tangential to the anterior and posterior border of the incisura was drawn—the intertubercular line (IL). Then, the depth of the incisura at its deepest point was measured perpendicular to the IL.

#### **Fibular Engagement Within the Incisura—Engagement**

The engagement of the fibula within the incisura was measured as a distance between the medial fibular cortex and the IL. The engagement value was positive if the fibula crossed the IL and negative if it was not crossing the IL. The measurement of fibular engagement is illustrated in Table 1.<sup>2</sup>

#### **Rotational Orientation of Incisura—Rotation**

To measure the rotational orientation of the incisura, first the center of the tibia was defined as the center of the circle fitted to the anterior, posterior, and medial border of the tibia. Second, the center of the incisura was defined as the middle of the IL. Then, the line orthogonal to the line connecting these points was drawn. The angle between this line and the IL was measured.

#### **Assessment of Reduction**

To assess the quality of reduction, 3 parameters have been calculated to quantify the position of the fibula within the syndesmosis in 3 planes (Table 1): compression (coronal plane reduction), protrusion (sagittal plane reduction), and torsion (horizontal plane reduction). The unaffected side served as a baseline for all measurements.

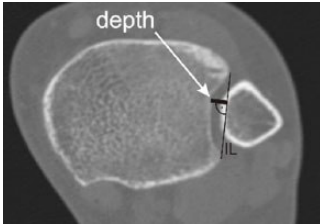
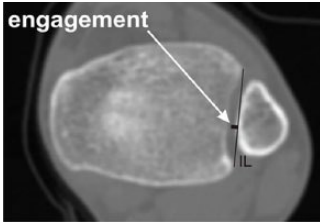
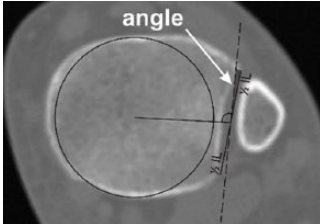

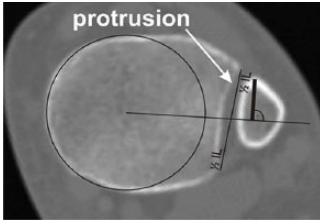
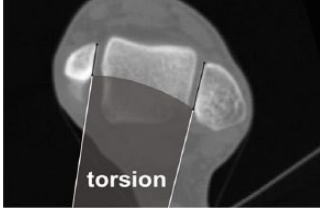
#### **Coronal Plane Reduction—Compression**

To assess the reduction quality in the coronal plane, compression was calculated as the difference in the engagement of affected and unaffected side. First, engagement was measured on both sides on proximal cuts as described above. Then the value of engagement for the affected side was subtracted from the value of engagement of the unaffected side. A positive value represented overcompression and negative value represented undercompression of the fibula into the incisura.

#### **Sagittal Plane Reduction—Protrusion**

To assess sagittal plane orientation, protrusion of the fibula was measured for both sides in proximal cuts. Protrusion represented the distance between the most anteriorly prominent point of the fibula and the line connecting the center of the tibia and the center of the IL. Protrusion was measured for the affected and unaffected sides. The quality of the reduction was quantified by subtracting the value of protrusion for the affected side from that of the unaffected side. A positive value represented anterior displacement of the fibula within the syndesmosis, and a negative value

**Table 1.** Summary of the Measured Parameters.

Parameter		Site of Measurement	Graphic Depiction <sup>a</sup>
Assessment of syndesmotic anatomy	Depth	Unaffected side, proximal cut	
	Engagement	Unaffected side, proximal cut	
	Rotation	Unaffected side, proximal cut	
Assessment of reduction quality	Compression	Difference between both sides, proximal cut	
	Protrusion	Difference between both sides, proximal cut	
	Torsion	Difference between both sides, distal cut	

<sup>a</sup>Reprinted from Boszczyk et al, with permission from Elsevier.<sup>2</sup>

represented posterior displacement of the fibula (sagittal plane malreduction).

**Rotational Reduction—Torsion**

Rotational reduction of the fibula in the incisura was assessed in the distal scans of the unaffected and affected

extremity. Lines were constructed tangential to the subchondral bone of the medial malleolus and the fibula, and the angle between them was measured. The difference between the angles for the affected and unaffected sides represented rotational malreduction, with a positive value representing external rotation of the affected fibula and a negative value representing internal rotation of the fibula.

**Table 2.** Summary of the Reduction Results.

	Reduction Error Range	Clinically Relevant Malreductions
Coronal plane reduction	-2.4 mm (undercompression) to 3.7 mm (overcompression)	8.3% more than 2-mm side-to-side difference
Sagittal plane reduction	-3.7 mm (posterior translation) to 6.4 mm (anterior translation)	27.8% more than 2-mm side-to-side difference
Horizontal plane reduction	-16 degrees (internal rotation) to 14 degrees (external rotation)	19.4% more than 5-degree side-to-side difference

### Reliability Testing

For intrarater variability assessment, all measurements were performed by 2 independent investigators. For interrater variability assessment, the measurements were repeated at least 1 week apart. For further analysis, the results for each variable were averaged. The differences (error) between the measured values and the means were calculated.

### Statistical Analysis

Normality of the data was tested with the Shapiro-Wilk test. The differences between each measurement for each group were compared with the Wilcoxon signed-rank test. Interrater and intrarater reliability was tested by calculating Cronbach's  $\alpha$  for each measurement repeated by a single investigator and between the 2 investigators. The correlation between the groups was compared with Spearman's coefficient.

## Results

### Reliability

In assessment of syndesmotomy anatomy, Cronbach's  $\alpha$  for intrarater reliability was 0.97, 0.92, and 0.94 for depth, engagement, and rotation and 0.93, 0.93, and 0.96 for interrater reliability, respectively. For parameters of reduction quality, Cronbach's  $\alpha$  for intrarater reliability was 0.95, 0.93, and 0.94 for compression, protrusion, and torsion and 0.93, 0.96, and 0.95 for interrater reliability, respectively. These numbers are consistent with excellent intrarater and interrater reliability for each measurement.

The mean (standard deviation [SD]) error between the measured values and the calculated means was 0.2 (0.19) mm for depth, 0.2 (0.23) mm for engagement, and 0.84 (0.7) degrees for rotation and 0.4 (0.5) mm for compression, 0.5 (0.4) mm for protrusion, and 1.5 (1.4) degrees for torsion.

### Coronal Plane Reduction

The results of reduction are summarized in Table 2. The coronal plane error of reduction varied from -2.4 mm

(representing undercompression) to 3.7 mm (representing overcompression), with a mean of 0.3 mm, median of 0.1 mm, and SD of 1.2 mm. Applying a threshold of a 2-mm side-to-side difference revealed 1 undercompressed and 5 overcompressed syndesmoses. This resulted in a clinically relevant coronal plane malreduction rate of 8.3%. With 1 mm as a threshold, there would have been 10 undercompressed and 22 overcompressed syndesmoses.

### Sagittal Plane Reduction

The sagittal plane error of reduction varied from -3.7 mm (posterior translation) to 6.4 mm (anterior translation), with a mean of 0.1 mm, a median of 0.2 mm, and standard deviation of 1.8 mm. With a cutoff of a 2-mm side-to-side difference, 10 syndesmoses were malreduced in anterior translation and 10 were malreduced in posterior translation. This resulted in a clinically relevant sagittal plane malreduction rate of 27.8%.

### Horizontal Plane Reduction

The torsional error of reduction varied from -16 degrees (internal rotation) to 14 degrees (external rotation), with a mean of 1.3 degrees, median of 0.5 degrees, and standard deviation of 4.6 degrees. With a threshold of 5 degrees, there was 1 internally rotated syndesmosis and 13 syndesmoses with external rotation. This resulted in a potentially relevant horizontal plane malreduction rate of 19.4%. With 15 degrees as threshold, as has been described to be clinically relevant,<sup>26</sup> there would have been only 1 internally rotated fibula (1.4%).

### Effect of Incisura Depth

To analyze the correlation of incisura depth and coronal plane reduction, all reductions were ordered from most compressed to most undercompressed. Then, the patients were split in 3 even subgroups of 24 "overcompressed," 24 "well-compressed," and 24 "undercompressed" syndesmoses. The patients in the subgroup with "overcompressed" syndesmoses had on average a 0.8-mm deeper incisura than those with a "well-compressed" syndesmosis ( $P < .05$ ).

Spearman's correlation coefficient between incisura depth and compression was  $-0.25$ .

To analyze the correlation of incisura depth and sagittal plane reduction, all reductions were ordered from most anteriorly translated to most posteriorly translated. Then, patients were split in 3 even subgroups with 24 more anteriorly translated, 24 "well-reduced," and 24 more posteriorly translated syndesmoses. The patients with more anterior translation of the fibula had on average a 1.0-mm shallower incisura than those in the "well-reduced" subgroup ( $P < .05$ ). Spearman's coefficient for correlation between incisura depth and sagittal reduction was  $-0.28$ .

We did not observe a significant correlation between depth of the incisura and horizontal plane reduction.

### *Effect of Fibular Engagement*

The syndesmoses in the subgroup with "overcompression" were on average 1.2 mm less engaged than those in the "well-compressed" subgroup ( $P < .05$ ). Spearman's coefficient of correlation between engagement and compression was  $-0.38$ .

We did not observe a significant correlation between fibular engagement and either sagittal or horizontal plane reduction.

### *Effect of Incisura Rotation*

Patients with anterior translation of the distal fibula had on average a 3.1-degree more anteriorly oriented incisura than those in the "well-reduced" subgroup ( $P < .05$ ) while patients with posterior translation of the fibula had on average a 0.9-degree more posteriorly oriented incisura than those in the "well-reduced" subgroup ( $P < .05$ ). Spearman's coefficient correlation between fibular translation and incisura rotation was 0.36.

We did not observe a significant correlation between incisura rotation and either coronal or horizontal plane reduction.

## **Discussion**

The problem of syndesmotom malreduction has received increased attention over recent years since anatomic reduction of the distal fibula into the tibial incisura is an important prognostic factor in the treatment of ankle fractures.<sup>25,27,28</sup> Simultaneously, relatively high rates of malreduction have been reported.<sup>22,23</sup>

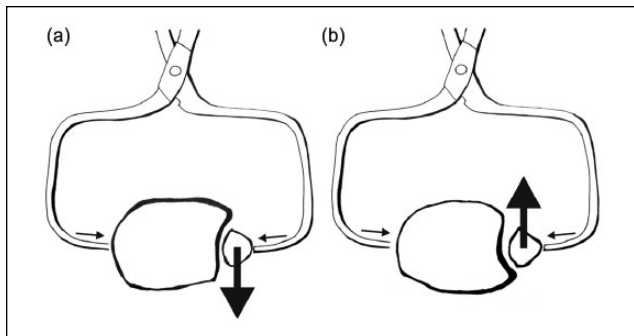
The anatomy of the syndesmosis has been shown to present great interindividual variability.<sup>8-10,14,19,20</sup> Current reduction techniques do not take into account this variable anatomy.<sup>16</sup> The current approach to reduction of the syndesmosis can be described as a "one technique fits all" approach, although there is renewed interest in optimizing

clamp position.<sup>5,21</sup> While this approach may be appropriate for most patients, we think it is logical to ask if differences in syndesmotom anatomy correlate with the mode of malreduction. To our knowledge, this issue has been studied only once in a study analyzing the effect of incisura depth in a group of 35 Weber type B and C fractures.<sup>4</sup> The effect of incisura rotation and fibular engagement has never been studied.

In the present study, we found that (1) overcompression of the incisura was significantly more common in patients with a deep and less engaged incisura, (2) anteversion of the incisura correlated with anterior displacement of the fibula while retroversion of the incisura was correlated with posterior fibular displacement, and (3) fibular malrotation was not associated with variations in syndesmotom anatomy.

The higher prevalence of syndesmosis overcompression in patients with a deep and less engaged incisura may be due to the fact that this incisura morphology represents a syndesmosis with a thick layer of soft tissues separating the distal tibia and fibula. Without a strong bony contour to rely on, it is easy to overcompress the soft tissues within the syndesmosis. The problem of overcompression is subject to debate. While 2 cadaveric studies had conflicting results,<sup>20,26</sup> overcompression of the fibula has been reported clinically.<sup>3</sup> It has been shown in a biomechanical study that overcompression may be caused by excessive clamp force.<sup>13</sup> We believe that the present study is the first to show that overcompression is more common with a certain syndesmotom anatomy. This observation may potentially lead to the identification of patients requiring special attention intraoperatively.

Anteversion of the incisura led to anterior displacement of the fibula while retroversion of the incisura led to posterior fibular displacement. We believe that these effects are caused by the current technique of syndesmotom clamp reduction. As has been proposed by Mendelsohn et al,<sup>19</sup> malpositioning of the clamp leads to malreduction of the syndesmosis. We believe that the standard technique of clamp reduction is effective in patients with neutral version of the incisura. In the extremes of incisural torsion, the standard technique will not be optimal. With an anteverted or retroverted incisura, standard axial clamp application will lead to nonparallel clamp positioning, thus squeezing the fibula out anteriorly or posteriorly, respectively (Figure 1). We believe we are the first to show that rotational variations of the incisura correlate with certain modes of syndesmotom malreduction, which may have clinical implications. As a consequence, in patients with an anteverted incisura, the clamp might have to be placed more anteriorly on the distal fibula, while in patients with a retroverted incisura, the clamp might have to be placed more posteriorly on the distal fibula. Finally, rotatory fibular malreduction seems to be solely surgeon dependent, as it did not correlate with syndesmotom anatomy. We believe that in Weber type C fractures, rotation of the



**Figure 1.** (a) With a retroverted incisura, standard clamp positioning pushes the fibula posteriorly, (b) while with an anteverted incisura, standard clamp positioning pushes the fibula anteriorly.

fibula is more dependent on quality of fibular fracture reduction than it is influenced by syndesmotic reduction.

As a consequence of our observations, one should consider to routinely obtain bilateral preoperative ankle CT scans in patients with syndesmotic disruption on plain radiographs to familiarize the surgeon with ankle anatomy and possible malreduction patterns. Whether this practice or the use of alternative reduction and fixation techniques (eg, with a flexible implant) reduces the rate of malreduction remains to be elucidated in further studies. Intraoperatively, the assessment of the syndesmotic reduction can be enhanced by comparison of fluoroscopy images to mortise<sup>11</sup> and lateral<sup>15</sup> views of the uninjured ankle.

The results of our study partly agree with the results of Cherney et al.<sup>4</sup> They observed anterior displacement of the fibula with a shallow incisura and posterior displacement of fibula with a deep incisura. We have seen the same tendency in anteverted and retroverted incisurae. The rotational version of the incisura has not been reported previously. Cherney et al<sup>4</sup> also observed that deeper syndesmoses were prone to malreduction of the distal fibula in external rotation. We did not see this association in our study. One possible explanation is that the patient cohort reported by Cherney et al<sup>4</sup> also included Weber type B fractures while our patient cohort consisted of only patients with full disruption of syndesmosis documented as pronation-external rotation (PE) II, PE III, and PE IV fractures according to the Lauge-Hansen classification.<sup>17</sup>

The overall rates of malreduction as detected with postoperative CT scanning compare favorably with earlier studies on that topic.<sup>5,21,24,26</sup> We routinely have used postoperative CT scans for unstable malleolar fractures requiring syndesmotic fixation for 15 years.<sup>23</sup> A higher awareness of frequent malreduction patterns may have led to improved reduction techniques with direct intraoperative visualization. Similarly, Cherney et al<sup>4</sup> observed that the malreduction rate decreased toward the latter part of their study.

They attribute this to improvements in operative technique. We believe that the results of our series may lead to improved reduction techniques for specific anatomic configurations of the syndesmosis, thus further reducing the rates of malreduction. Our results also underline the importance of anatomic reduction of fractures of the anterior tibial tubercle and the posterior malleolus that involve the incisura as fracture reduction will also restore the anatomy of the incisura.<sup>1,22</sup>

Our study has several potential shortcomings. First, while we made every effort to collect a homogeneous group, it is never possible to have identical injury patterns. The common denominator of our patients was full syndesmotic disruption with an accompanying malleolar fracture. This is defined as a pronation-external rotation injury stage II, III, and IV according to Lauge-Hansen.<sup>17</sup> Second, while we strived to apply clinically relevant thresholds for malreduction of the syndesmosis, the relatively low number of malreduced patients forced us to use surrogate subgroups. In this study, however, we focused rather on mechanisms of malreduction and not on clinical outcomes.

Third, we performed measurements at 10 mm proximal and 10 mm distal to the tibial plafond. The value of 10 mm is absolute and does not respect different heights of individual patients and thus different lengths of the lower leg. However, the chosen height represents a standard point of reference in the literature for analyzing the bony configuration of the incisura, thus making our results comparable to the literature.<sup>6,8-10,14,19</sup> Fourth, as we used a nonaffected extremity to define syndesmotic anatomy, the results of the study are based on the assumption of the extremities being symmetric. We believe this assumption is well supported by numerous studies on syndesmotic anatomy where a high degree of symmetry has been observed.<sup>6,12,15,18</sup> Finally, it should be noted that the Spearman correlation coefficients between the morphology and malreduction patterns are in the “weak” range. We believe that this highlights the influence of the treating surgeon: there can be excellent reduction in cases with a syndesmotic configuration prone to malreduction, and there can be gross malreduction in cases with a more “forgiving” syndesmotic anatomy. Thus, it is the surgeon and not the anatomy that leads to malreduction.

## Conclusion

In summary, the results of our study indicate that certain morphologic configurations of the tibial incisura increased the risk of specific syndesmotic malreduction patterns. Anteversion of the incisura correlated with anterior displacement of the fibula, while retroversion of the incisura correlated with posterior fibular displacement. We also showed for the first time that deep and disengaged syndesmoses were more prone to overcompression. As a consequence of these

observations, further investigations are warranted that work on anatomy-adjusted reduction techniques.

### Acknowledgment

The authors thank Agata Boszczyk, BEng, MSc, for help in preparing the illustrations.

### Declaration of Conflicting Interests

The author(s) declared no potential conflicts of interest with respect to the research, authorship, and/or publication of this article. ICMJE forms for all authors are available online.

### Funding

The author(s) disclosed receipt of the following financial support for the research, authorship, and/or publication of this article: The work was supported by Centre of Postgraduate Medical Education (grant 501-1-07-18-16).

### Ethical approval

Ethical approval was granted on August 6, 2016, by the Ethic Committee of the Medical Centre of Postgraduate Education.

### References

- Bartoníček J, Rammelt S, Kostlivý K, Vaněček V, Klika D, Trešl I. Anatomy and classification of the posterior tibial fragment in ankle fractures. *Arch Orthop Trauma Surg.* 2015;135(4):505-516.
- Boszczyk A, Kwapisz S, Krümmel M, Grass R, Rammelt S. Anatomy of the tibial incisura as a risk factor for syndesmotric injury [published online August 16, 2017]. *Foot Ankle Surg.*
- Cherney SM, Haynes JA, Spraggs-Hughes AG, McAndrew CM, Ricci WM, Gardner MJ. In vivo syndesmotric overcompression after fixation of ankle fractures with a syndesmotric injury. *J Orthop Trauma.* 2015;29(9):414-419.
- Cherney SM, Spraggs-Hughes AG, McAndrew CM, Ricci WM, Gardner MJ. Incisura morphology as a risk factor for syndesmotric malreduction. *Foot Ankle Int.* 2016;37(7):748-754.
- Cosgrove CT, Putnam SM, Cherney SM, et al. Medial clamp tine positioning affects ankle syndesmosis malreduction. *J Orthop Trauma.* 2017;31(8):440-446.
- Dikos GD, Heisler J, Choplin RH, Weber TG. Normal tibiofibular relationships at the syndesmosis on axial CT imaging. *J Orthop Trauma.* 2012;26(7):433-438.
- Driesman AS, Egol KA. An update on the treatment of malleolar fractures. *FussSprungg.* 2016;14:55-65.
- Ebinger T, Goetz J, Dolan L, Phisitkul P. 3D model analysis of existing CT syndesmosis measurements. *Iowa Orthop J.* 2013;33:40-46.
- Ebraheim NA, Lu J, Yang H, Rollins J. The fibular incisure of the tibia on CT scan: a cadaver study. *Foot Ankle Int.* 1998;19(5):318-321.
- Elgafy H, Semaan HB, Blessinger B. Computed tomography of normal distal tibiofibular syndesmosis. *Skeletal Radiol.* 2010;39(6):559-564.
- Futamura K, Baba T, Mogami A, et al. Malreduction of syndesmosis injury associated with malleolar ankle fracture can be avoided using Weber's three indexes in the mortise view. *Injury.* 2017;48(4):954-959.
- Grenier S, Benoit B, Rouleau DM, Leduc S, Laflamme G-Y, Liew A. APTF: anteroposterior tibiofibular ratio, a new reliable measure to assess syndesmotric reduction. *J Orthop Trauma.* 2013;27(4):207-211.
- Haynes J, Cherney S, Spraggs-Hughes A, McAndrew CM, Ricci WM, Gardner MJ. Increased reduction clamp force associated with syndesmotric overcompression. *Foot Ankle Int.* 2016;37(7):722-729.
- Höcker K, Pachucki A. The fibular incisure of the tibia: the cross-sectional position of the fibula in distal syndesmosis [in German]. *Unfallchirurg.* 1989;92(8):401-406.
- Koenig SJ, Tornetta P, Merlin G, et al. Can we tell if the syndesmosis is reduced using fluoroscopy? *J Orthop Trauma.* 2015;29(9):e326-e330.
- LaMothe J, Baxter JR, Gilbert S, Murphy CI, Karnovsky SC, Drakos MC. Effect of complete syndesmotric disruption and deltoid injuries and different reduction methods on ankle joint contact mechanics. *Foot Ankle Int.* 2017;38(6):694-700.
- Lauge-Hansen N. Fractures of the ankle. II. Combined experimental-surgical and experimental-roentgenologic investigations. *Arch Surg.* 1950;60(5):957-985.
- Lepojärvi S, Pakarinen H, Savola O, Haapea M, Sequeiros RB, Niinimäki J. Posterior translation of the fibula may indicate malreduction: CT study of normal variation in uninjured ankles. *J Orthop Trauma.* 2014;28(4):205-209.
- Mendelsohn ES, Hoshino CM, Harris TG, Zinar DM. CT Characterizing the anatomy of uninjured ankle syndesmosis. *Orthopaedics.* 2014;37(2):157-160.
- Phisitkul P, Ebinger T, Goetz J, Vaseenon T, Marsh JL. Forceps reduction of the syndesmosis in rotational ankle fractures: a cadaveric study. *J Bone Joint Surg Am.* 2012;94(24):2256-2261.
- Putnam SM, Linn MS, Spraggs-Hughes A, McAndrew CM, Ricci WM, Gardner MJ. Simulating clamp placement across the trans-syndesmotric angle of the ankle to minimize malreduction: a radiological study. *Injury.* 2017;48(3):770-775.
- Rammelt S, Ogruba P. An update on the evaluation and treatment of syndesmotric injuries. *Eur J Trauma Emerg Surg.* 2015;41(6):601-614.
- Rammelt S, Zwipp H, Grass R. Injuries to the distal tibiofibular syndesmosis: an evidence-based approach to acute and chronic lesions. *Foot Ankle Clin.* 2008;13(4):611-633.
- Rammelt S, Zwipp H, Mittlmeier T. Operative treatment of pronation fracture—dislocations of the ankle [in German]. *Oper Orthop Traumatol.* 2013;25(3):273-293.
- Sagi HC, Shah AR, Sanders RW. The functional consequence of syndesmotric joint malreduction at a minimum 2-year follow-up. *J Orthop Trauma.* 2012;26(7):439-443.
- Tornetta P, Spoo JE, Reynolds FA, Lee C. Overtightening of the ankle syndesmosis: is it really possible? *J Bone Joint Surg Am.* 2001;83(4):489-492.
- Vasarhelyi A, Lubitz J, Gierer P, et al. Detection of fibular torsional deformities after surgery for ankle fractures with a novel CT method. *Foot Ankle Int.* 2006;27(12):1115-1121.
- Weening B, Bhandari M. Predictors of functional outcome following transsyndesmotric screw fixation of ankle fractures. *J Orthop Trauma.* 2005;19(2):102-108.