

Jurnal Riset Veteriner Indonesia

Journal of the Indonesian Veterinary Research

P-ISSN: 2614-0187, E-ISSN:2615-2835

Volume 3 No. 2 (July 2019), pp. 68-71

journal.unhas.ac.id/index.php/jrvi/

This work is licensed under a Creative Commons Attribution 4.0 International License.



Case Report

Case Study of Nephritis in Domestic Cats (*Felis Catus*) Male in Veterinary Teaching Clinic of Hasanuddin University

Wa Ode Santa Monica¹, Indah Windy Octaviyani², Musdalifah³

¹Division of Internal Medicine and Clinical Pathology, Hasanuddin University, Jl. Perintis Kemerdekaan kampus Tamalanrea Km. 10 Makassar

²Student of Veterinary Profession Education Program, Hasanuddin University, Jl. Perintis Kemerdekaan kampus Tamalanrea Km. 10 Makassar

³Veterinary Teaching Clinic, Hasanuddin University, Jl. Al Markas Al Islami Kompleks Dosen IX

*Correspondence: wa_ode_evолlet@yahoo.com

Abstract

A sterile male cat (*Felis catus*), aged 1 year 7 months with a bodyweight of 3.7 kg was affected by urinary system disorders namely nephritis. Nephritis is kidney inflammation that occurs in the glomerulus, pyelum or tubules. Clinical symptoms shown in patients include polyuria, decreased appetite, and vomiting. Nephritis is clinically diagnosed based on urination behavior changes, palpation of the dorsal abdominal of the right and left side, urine dipstick test containing protein ++ (± 100 mg / dL), leukocytes valued at +, urine specific gravity of 1,015, and thickening of the renal cortex, the absence of medullary and cortical border, renal size, hyperechoic appearance of kidney capsules, and ascites in the abdomen by ultrasound examination. Cat was treated with isotonic fluid infusion fluids, wet and dry diet diets, antibiotics, multivitamins, and anti-inflammatory. After 4 days of treatment, the patient showed health improvement such as drinking well, active and urinate clearer urine.

Key words: *Nephritis, kidney, domestic cat, urinary system disorder*

Copyright © 2019 JRVI. All rights reserved.

Introduction

Cats are pets that are susceptible to various diseases including disorders of the urinary system (Maryani, 2009). One of them is nephritis which is kidney inflammation that in glomerulus, pyelum or tubules. Bacteria that commonly cause urinary tract infections in dogs and cats are *Escherichia coli*, *Staphylococcus*, *Streptococcus*, *Klebsiella pneumoniae*, *Pseudomonas aeruginosa*, *Proteus* and *Enterobacter* (Wijayanti, 2008). Systemic infection or inflammatory process produces complex immunity that is attached to glomerulus, viral and bacterial infections (Carlton and McGavin, 2001). Other infections can be caused by leptospira, herpes viruses, drug induction for long periods of time. Toxic effects of heavy metals, hereditary, and the presence of metabolic disorders (hypercalcemia and hyperkalemia), fibers in the presence of disorders of the kidney itself such as glomerular disorders, vascular disorders, and kidney structure disorders (cystic renal and renal obstruction) (Setiawan, 2015).

Case Reports

Anamnesa: Signs first, followed by symptoms Cats often urinate observed for about 4 days, decreased appetite, vomiting cats, and given a high-protein commercial dry feed. Signs: Domestic cat, male sex, 1 year and 7 months old, body weight 3.7 kg, and white and gray bicolor. Clinical symptoms: polydipsia, polyuria, anorexia, changes in urination behavior, difficulty in moving, and palpation of the dorsal abdominal caudal thoracic section experience pain in the right or right kidney. Physical examination: Heart rate 116x/ minute, breathing frequency 28x / minute and temperature surface 38.10°C, hydration level 8%, CRT value 3 seconds, skin turgor 3 seconds, dry mouth mucosa, gloomy face, conjunctival eyes are rather pale and membrane nictitans are sparse, gums are inflamed. Supporting Diagnose: Ultrasound imaging to observe the urinary system in the abdominal cavity, and chemical analysis of urine using a dysptic test to evaluate the function of the urinary system. Diagnosis: nephritis or inflammation of the kidneys. Prognosis: Dubius - infausta. Treatment: Ceftriaxone® antibiotics and anti-inflammatory Meloxicam, Supportive therapy by giving isingeric Ringer lactate infusion fluid, Royal Canin Recovery diet feed, and Bionsu TP® multivitamin,.

Results and Discussion

Thickening of the renal cortex and renal capsules that appeared hyperechoic (Figures 1a and 1d), shows the existence of high echogenicity in the form of a collection of connective tissue (fibrosis) and added to the presence of inflammatory debris cells. According Wijayanti (2008), increased echogenicity can be caused by accumulation of oxalate crystals and tubular necrose. In Figure 1b, the renal cortex is thicker and the medulla looks smaller which shows that the kidney loses its normal structure, this can be caused by the formation of connective tissue in the kidney due to an inflammatory reaction. In Figure 1c, a line is drawn to determine the patient's kidney size, and size the kidney reaches 4.21 cm.

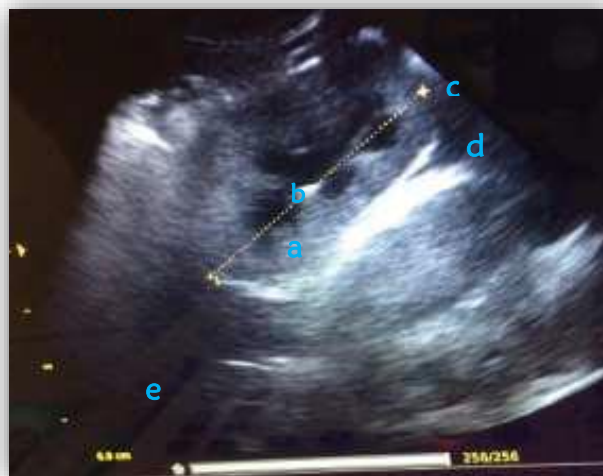

Figure 1. Ultrasonography (USG) investigations of domestic cats a) thickening of the renal cortex, b) renal medulla appeared small, c) kidney size 4.21 cm. d) capsules appeared hyperechoic. e) fluid accumulation in the abdominal cavity

Based on data from Debruyne (2013), the normal size of a cat's kidney is 3.2-4.2 cm, so it can be said that the size of the kidney is still in normal condition. In Figure 1e, an anechoic structure was appeared on the ventral part of the kidney. This is a pathological state of fluid accumulation in the abdominal cavity, called ascites or peritoneal effusion. One of the causes of ascites is the damage from the glomerulus which will affect the kidneys causing the release

of protein in the urine (proteinuria), known as protein-losing nephropathies (Carlton & McGavin 2001). Ascites can also be caused by infiltration of inflammatory cells in the kidneys.

Samples were collected using the urohidropropulsion method. Circular arms above the cat's neck and pressing the animal's head down, the other hand holding both cat's legs while another colleague palpates urinary bladder or urinary bladder compression to stimulate the cat to release urine while collecting urine out using urine containers. and after the urine has been collected, it is put in a cool box to keep the sample in good condition (Idexx Laboratories, 2014).

Dipstick test is an examination of urine content to determine the levels of components in the urine such as erythrocytes, leukocytes, pH nitrite, urobilinogen, bilirubin, ketones, glucose and urine specific gravity (Loesnihari, 2012). Based on dipstick testing the following test results have been found, urine containing protein up to ++ (± 100 mg / dL) is called proteinuria. The condition of proteinuria can occur due to increased permeability and glomerular barrier damage in protein filtration, besides proteinuria is also caused by a decrease in tubular reabsorption so that a lot of protein passes into the urine (National Institute of Health, 2011).

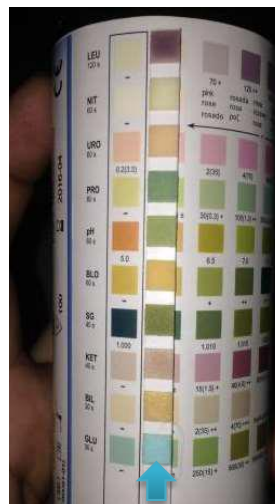


Figure 2. Dipstick Test Results

Dipstick chemical analysis results also showed the specific gravity of urine reached a value of 1.015, while the normal value for specific gravity of cat urine was ≤ 1.035 . The low value of urine specific gravity indicates that the kidneys are unable to concentrate urine so that urine concentration is very low. Decreased urine specific gravity can be found in patients with diabetes insipidus, pyelonephritis and glomerulonephritis. Increased specific gravity in patients with dehydration, adrenal insufficiency, liver disease and heart failure (Loesnihari, 2012).

The initial action that must be taken to deal with Nephritis cases is to restore fluids lost due to polyuria and vomiting, with fluid therapy and to replace feed to increase the patient's appetite. Ringer lactate Isotonic fluid type Indications Given to patients who have hypovolemic (lack of body fluids) so that it will reduce blood pressure with a dose of 5 seconds / drop for 8% dehydration rate (Suartha, I. N. 2010).

The condition of patients who lack appetite must be induced by wet food in order to arouse the patient's appetite, for that commercial feed Royal Canine Recovery, bribed 3 times a day. Royal Canin Recovery product name for Indication of nutritional restoration during recovery from illness with high energy density and very easily digested with its own composition of meat

and vegetables, oil and fat, milk, minerals, eggs, vitamins D3, E1, E2, E4, E5 and E7, EPA / DHA, energy and complex antioxidants (Royal Canine Recovery, Product description).

Treatment for Nephritis cases can be done by giving antibiotics and anti-inflammatory. Ceftriaxone antibiotics as much as 2 times a day by intravenous route. Ceftriaxone is a broad-spectrum antibiotic but is more effectively used for gram-negative bacteria. Ceftriaxone will spread throughout the body, down to the cerebrospinal fluid. Ceftriaxone will be excreted by the kidneys (33-67%) without changing the structure and components of ceftriaxone. The absorption rate of ceftriaxone can reach 95%. Ceftriaxone cannot be absorbed orally and therefore must be given IM, SC or IV (Plumb, 2000). Antiinflammation given is meloxicam with frequency as much as once a day at a dose of 0.2 mg / kg BW orally. The mechanism of NSAIDs works by inhibiting the action of cyclooxygenase, phospholipase A2, and inhibiting prostaglandin synthesis as an inflammatory induction agent. Orally, meloxicam will be well absorbed, food will not affect the absorption of the drug so that the effect of the drug will be maximal. About 97% of these drugs will bind to plasma proteins. Giving meloxicam so far has not shown toxicity to the liver and kidneys. The half-life of the drug is 15 hours. Indications Anti-inflammatory, analgesic, antipyretic.

Conclusion

Based on the results of physical examination and supporting examination, domestic cats are diagnosed with nephritis. Cat is treated with Ringer lactate isotonic infusion, Royal Canine Recovery diet feed, Ceftriaxone® antibiotics, Bionsu TP® multivitamin, and Meloxicam anti-inflammatory. Animals are still being treated for nephritis because it takes a long time for the healing process.

References

- Birchard SJ dan Sherding RG. 2000. Saunders Manual of Small Animal Practice. 2 nd edition. Pennsylvania: W. B. Saunders Company. page. 913-957.
- Carlton WW dan McGavin MD. 2001. Thomson's Special Veterinary Pathology. St. Louis: Mosby-Year Book, Inc. page 209-245.
- Debruyne K, Paepe D, Daminet S, Combes A, Duchateau L, Peremans K, Saunders JH. 2013. Renal dimensions at ultrasonography in healthy Ragdoll cats with normal kidney morphology: correlation with age, gender and bodyweight. *Journal of Feline Medicine and Surgery* 15 (12): 1046–1051
- Idexx Laboratories. 2014. Urine Collection Methods. <https://www.idexx.com/files/urine-collection-methods-en.pdf>
- Loesnihari, R. 2012. Peran analisa urin pada penanganan penyakit ginjal dan traktus urinarius. *Majalah Kedokteran Nusantara*, Vol. 45, No.3 Desember 2012, Hal :167-176
- Maryani, 2009. Kasus Urolithiasis Pada Anjing dan Kucing . Fakultas Kedokteran Hewan Institut Pertanian Bogor. Bogor.
- Plumb, D. C. 2000. *Veterinary Drug Handbook Eighth Edition*. Wiley Blackwell, New Jersey.
- National Institute of Health. 2011. Association of estimated glomerular filtration rate and albuminuria with mortality and end-stage renal disease: a collaborative meta-analysis of kidney disease cohorts. *Kidney Int.* 2011 June;79(12):1331–40.
- Setiawan, Anjar Adi. 2015. *Nefritis Pada Anjing English Bulldog*. Universitas Brawijaya: Malang.
- Wijayanti, T. 2008. Diagnosa Ultrasonografi Untuk Mendeteksi Kelainan Pada Organ Urinaria Kucing (*Felis catus*). SKripsi. Fakultas Kedokteran Hewan, Institut Pertanian Bogor. Bogor
- Suartha, I. N. 2010. Terapi Cairan pada Anjing dan Kucing. *Buletin Veteriner Udayana* 2 (2) : 69-83.