

12-1985

## Intraocular Lens Implant Image Quality: The Optico-Retinal Interface

David D. Bogorad

Follow this and additional works at: <https://scholarlycommons.henryford.com/hfhmedjournal>



Part of the [Life Sciences Commons](#), [Medical Specialties Commons](#), and the [Public Health Commons](#)

---

### Recommended Citation

Bogorad, David D. (1985) "Intraocular Lens Implant Image Quality: The Optico-Retinal Interface," *Henry Ford Hospital Medical Journal* : Vol. 33 : No. 4 , 153-159.

Available at: <https://scholarlycommons.henryford.com/hfhmedjournal/vol33/iss4/2>

This Article is brought to you for free and open access by Henry Ford Health System Scholarly Commons. It has been accepted for inclusion in Henry Ford Hospital Medical Journal by an authorized editor of Henry Ford Health System Scholarly Commons.

## Feature Articles

### Intraocular Lens Implant Image Quality: The Optico-Retinal Interface

David D. Bogorad, MD\*

*Improvements in intraocular lens implants during the past ten years have revolutionized cataract surgery. Both anterior and posterior chamber lenses are currently in wide use, but the optical superiority of the posterior chamber location has yet to be demonstrated. To do so, a more detailed analysis is required of visual function than is clinically routine. Also required is appreciation that the retina is an integral part of the eye's optical system because of its directional character-*

Cataract surgery has been drastically altered with the evolution of increasingly well-tolerated intraocular lens implants. These lens implants have provided a dramatic improvement in optical quality, as compared to previous forms of aphakic correction, and have offered effective visual rehabilitation to a wider variety of patients than was previously possible. The severe spatial distortions created by aphakic spectacles, which make postoperative adjustment so difficult, are eliminated with lens implants (1), and hip fractures no longer occur among elderly patients who are prone to such accidents during the initial adjustment period of wearing aphakic glasses.

While most older individuals are reluctant to wear contact lenses, the decline in the quality and quantity of ocular lubrication with advancing age reduces the likelihood that contact lenses will be well tolerated by these individuals. Extended-wear contact lenses allow some patients with arthritis or other dexterity-reducing conditions to wear lenses without daily handling, but such contacts do require periodic maintenance and replacement (2). Intraocular lenses are clearly more cost-effective since no maintenance is required.

Of all surgical rehabilitative procedures, cataract extraction with lens implantation is currently the most frequently performed operation, with an estimated 496,000 lenses implanted in 1982 (3). The increasing pace of implant development and improvement during the past decade has been remarkable. Implant designs that were popular just seven to eight years ago have been virtually abandoned, with dramatically improved designs taking their place (4). Poste-

*istics, which are known as the Stiles-Crawford effect. The optical quality of the pseudophakic eye is affected by the optics of the implant, its centration, and its anteroposterior position. Contrast sensitivity measurements in numerous pseudophakic patients are therefore necessary to determine the actual differences of in situ optical performances among different types of lens implants.*

rior chamber lenses (Fig 1) presently account for about 70% of all intraocular lenses implanted, whereas almost all of the remainder are of the anterior chamber type (5). Although each type of lens implant has its advantages in specific situations, the popularity of posterior chamber lenses has continually increased during the past several years.

Some of the less well-known optical differences between the two major types of implants will be addressed herein, particularly regarding the quality of the interface between the image projected within the eye and the receptive elements of the sensory retina, ie, the optico-retinal interface.

Although both anterior and posterior chamber lenses can produce excellent results, posterior chamber lenses must be superior because their optic position more closely mimics that of the natural lens. Whether this difference is perceptible to the most acute patient remains a question that the most widely employed method of acuity measurement cannot answer.

The Snellen method (Fig 2), named after the Dutch ophthalmologist who developed the technique in 1862, requires the recognition of characters that subtend visual angles of varying, calibrated size. The characters are generally presented at high contrast, which reveals the limitation of the

---

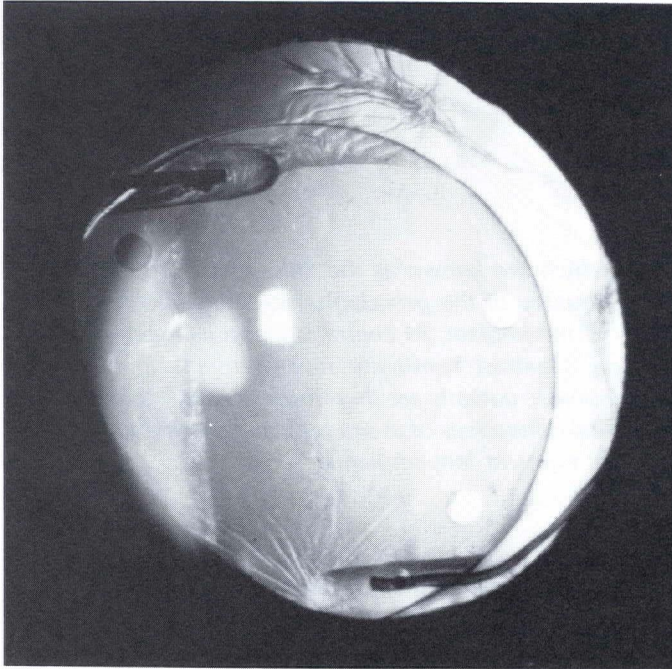
Submitted for publication: April 2, 1985

Accepted for publication: September 3, 1985

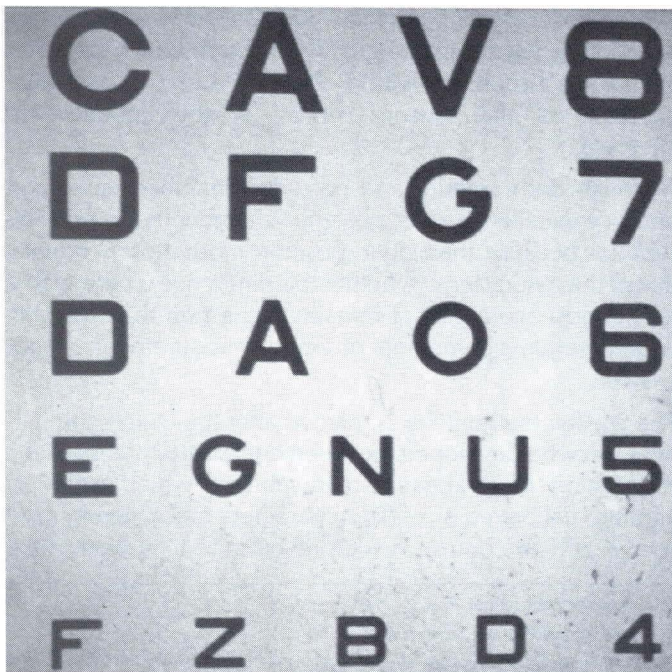
\*Department of Ophthalmology, Henry Ford Hospital; University of Michigan, School of Medicine, Ann Arbor, MI

Address reprint requests to Dr Bogorad, Department of Ophthalmology, Henry Ford Hospital, 2799 W Grand Blvd, Detroit, MI 48202.

technique. In reality, many visual tasks require discrimination between adjacent areas that differ only slightly in brightness (6). Thus, differences between implants, in their ability to transmit small brightness variations, might have a



**Fig 1**  
Posterior chamber intraocular lens implant in situ, with intact posterior lens capsule.



**Fig 2**  
Projected Snellen acuity test chart, designed to be viewed from 20 ft.


real impact on image quality, regardless of their similar performance under the Snellen acuity testing conditions.

The image-forming quality of an optical system is best expressed by its modulation transfer function (7). No lens can perfectly transmit brightness variations over a wide range of spatial frequencies. Some light is always absorbed by the system, which reduces the maximum brightness transmitted, and some light is always scattered by the system, which increases the light level in the darkest areas of the image. The contrast and sharpness of the image, therefore, can never equal that of the source. Modulation transfer assessment allows quantification of an optical system's ability to faithfully transmit brightness variations over both small and large areas in all portions of the image.

Although it is impossible to measure directly the modulation transfer characteristics of the eye's optical system, these characteristics can be studied indirectly by measuring contrast sensitivity. This psychophysical evaluation is achieved by presenting the subject with a series of patterns which vary sinusoidally in brightness at various spatial frequencies (Fig 3). With appropriate presentation strategy, contrast thresholds across a wide range of spatial frequencies can be determined (8).

While contrast sensitivity measurement evaluates the entire visual pathway, its measurement in groups of age-matched patients with anterior and posterior chamber lenses would make it possible to compare and determine the actual differences of in situ optical performances between these two lens types. Although this would help in better understanding the optico-retinal interface, such a study has yet to be attempted.

The retina is an integral part of the eye's optical system; it is not simply a passive reception screen but rather an



**Fig 3**  
Contrast sensitivity measurement gratings of two different spatial frequencies. Vary sinusoidally in reflectance, with decreasing contrast to left and right.

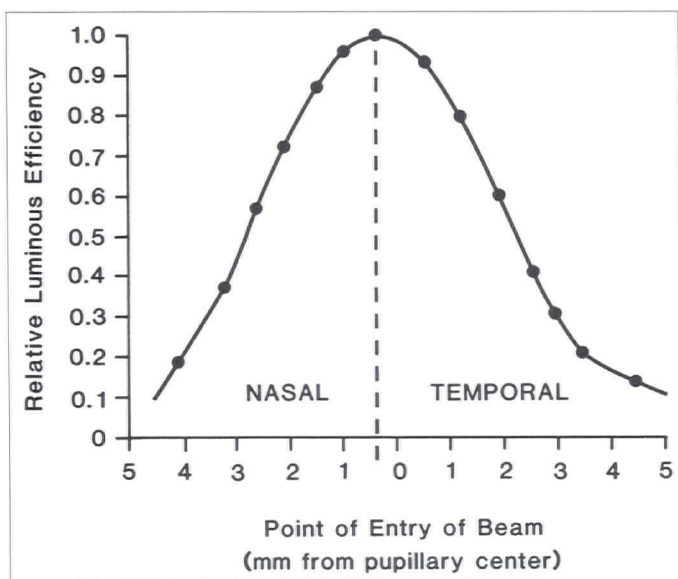


Fig 4  
Stiles-Crawford effect. Light entering center of pupil is perceived as being brighter than same light entering off axis.

exhibitor of directional characteristics. Each photoreceptor's sensitivity varies according to the angle of incidence of light impinging upon it. Therefore, changes in the way the image is projected on the retina can alter the quality of modulation transfer and, hence, visual performance.

The Stiles-Crawford effect Type I is the psychophysical demonstration of retinal directivity (9). Light rays that enter the center of the pupil are a more effective stimulus than those entering off axis (Fig 4). Photoreceptors are oriented such that their maximum sensitivity is directed toward the center of the eye's entrance pupil (Fig 5). Enoch postulated that this directional sensitivity occurs because the photoreceptors act as optical waveguides, favoring the absorption of light traveling axially down the receptor (10).

The Stiles-Crawford effect provides two major optical benefits to the eye by 1) greatly reducing the retina's sensitivity to light scattered within the integrating sphere of the eye (Fig 6) and 2) improving the modulation transfer characteristics of the system. The visual system's natural ability to ignore the contrast-degrading effects of light scattered within the eye is remarkable, which is readily appreciated by anyone who has studied the image quality achieved by the Omnimax motion picture projection system. Omnimax can project an image on a section of a sphere subtending 180° horizontally and 120° vertically, thereby mimicking in configuration the visually functional portion of the retina. Unlike the retina, however, the screen used is nondirectional; thus, much more image degradation occurs from the considerable light scattered and diffused within the sphere. This degradation in modulation transfer significantly

reduces the contrast that can be achieved when high luminance exists over a major portion of the image, which results in a washed out picture quality under these conditions.

Retinal directivity has the effect of reducing the retina's sensitivity to spherical aberration in the projected image, which results in another improvement in modulation transfer. While spherical aberration exerts its greatest effect on light rays that enter the lens nearest its periphery, the peripheral rays are partially ignored by the retina because of its directivity (Fig 7).




Fig 5  
Eye's photoreceptors are more effectively stimulated by light that strikes on axis. Physical basis of psychophysically demonstrated Stiles-Crawford effect.

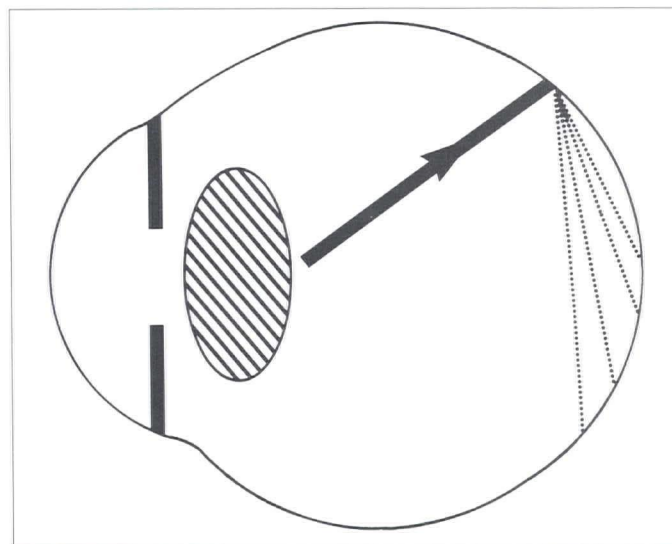


Fig 6  
As a result of its near-spherical curvature, retina should be susceptible to contrast-degrading effects of light reflected and scattered within eye. Retinal directivity, however, minimizes impact of scattered light within eye.

The entrance pupil is the image of the real pupil formed by the cornea of the eye (11). As a result of the fact that they are located in front of the iris, anterior chamber lenses shift

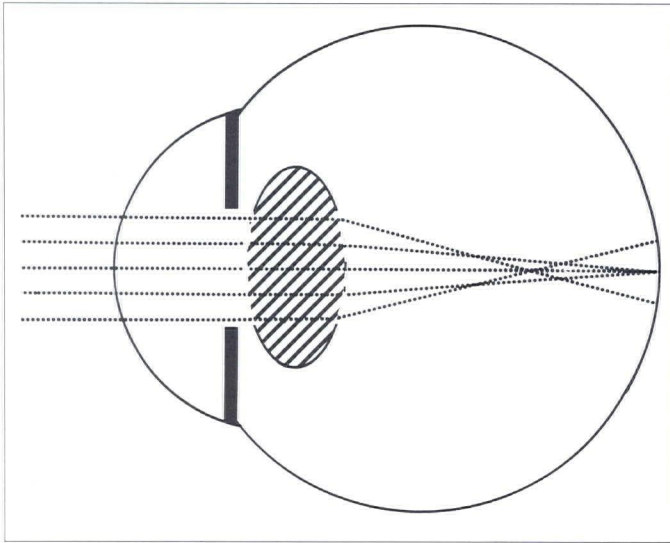


Fig 7

Retina's sensitivity to image-degrading effects of spherical aberration is minimized by its directive properties.

the entrance pupil forward from the natural position. When the entrance pupil is shifted forward, the optico-retinal interface is degraded in that a misalignment develops between off-axis photoreceptors and the center of the entrance pupil (Fig 8). Whether this misalignment causes a perceptible decrease in image quality remains to be determined. Posterior chamber lenses, however, do not cause any shift in the position of the entrance pupil and are thus, in this sense, more physiologic.

Consistent centration of lens implants is impossible to achieve with current surgical technology, which may explain why decentration aberration is rarely discussed in the literature. A properly centered implant would eliminate prismatic shifts in the position of the center of the entrance pupil (Fig 9), and proper image/photoreceptor alignment would thus be maintained. A decentered implant, however, would shift the entrance pupil off axis and create misalignment between the photoreceptor's preferred orientation and that of the projected image, thus degrading modulation transfer (Fig 10).

Although some ophthalmologists question whether the anterior or posterior implant position is least sensitive to this

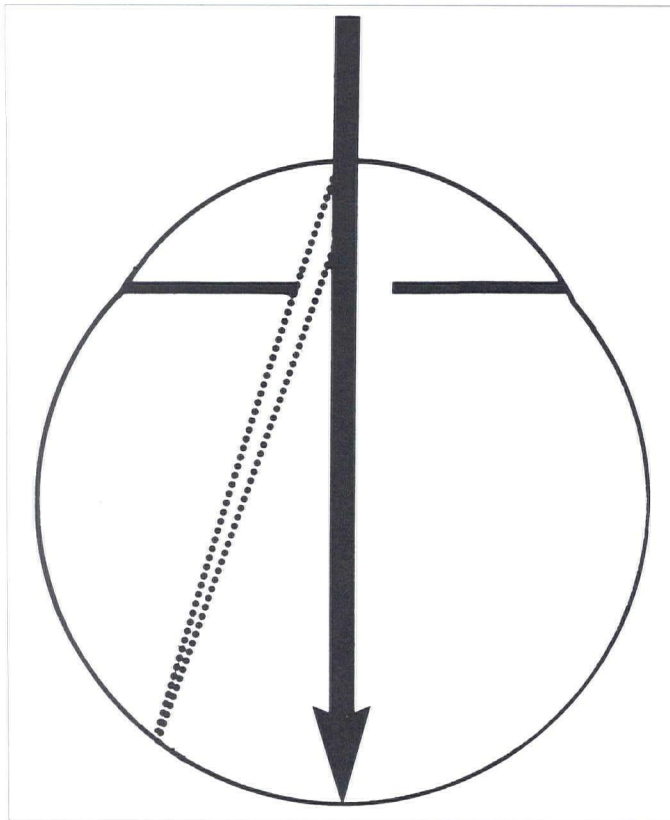


Fig 8

Anterior chamber lens implant shifts entrance pupil of eye forward. Shift in position of projected image source would be expected to degrade modulation transfer.

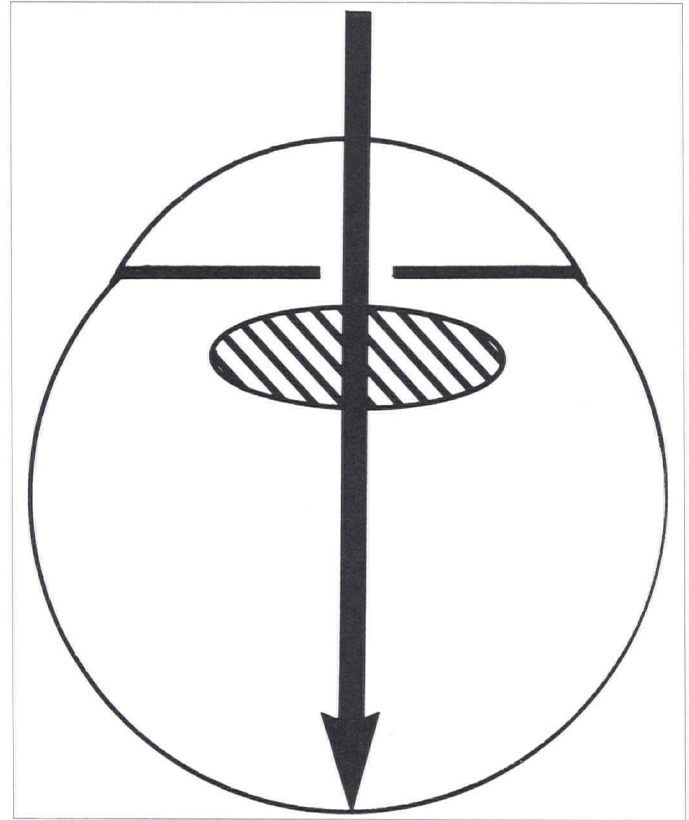


Fig 9

Properly centered lens implant will prevent prismatic shifts in position of projected image source, maintaining proper image/photoreceptor alignment.

form of decentration aberration, no difference actually exists. The lower required power of an anterior chamber lens offsets its greater physical distance from the retina, which otherwise would cause the anterior chamber lens to create more misalignment for a given amount of decentration.

The pseudophakic eye always has a greater risk for increased glare and secondary reflections, as compared to the naturally phakic eye, because the eye's natural lens is con-

structed in such a way that no artificial lens has yet been able to imitate. The eye's natural lens is inhomogeneous and has a nonuniform refractive index (12). While the natural refractive index increases gradually from the lens surface toward the nucleus (Fig 11), artificial lenses have a uniform refractive index that is higher at the surface than that of the natural lens, which results in stronger reflections being generated within the eye.

When light travels from a medium of lower refractive index to that of a higher one, some light is transmitted across the interface, and some is reflected. The greater the difference in refractive index between the two media, the more light

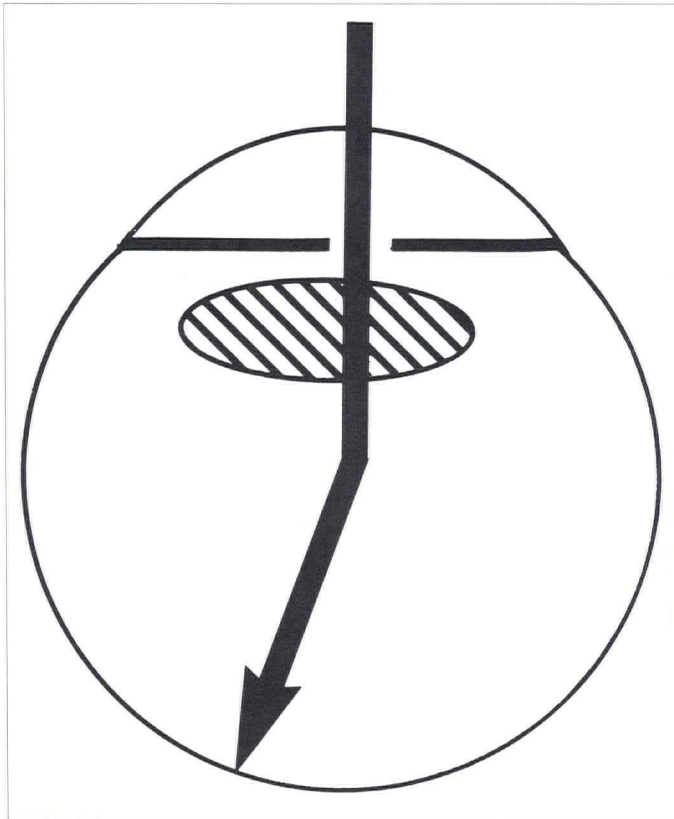


Fig 10

Decentered implant causes displacement in apparent source of projected image, presumably degrading apparent brightness and contrast.

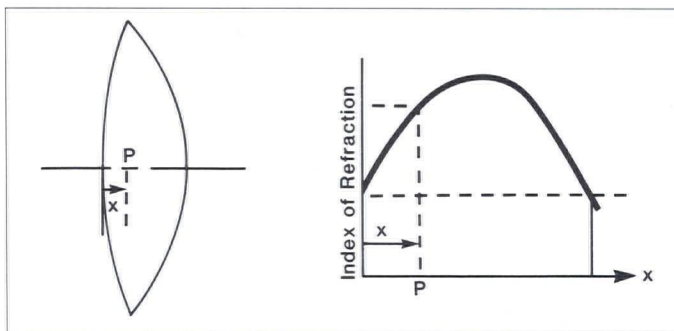


Fig 11

Inhomogeneous structure of eye's natural lens reduces reflections from front and rear surfaces.

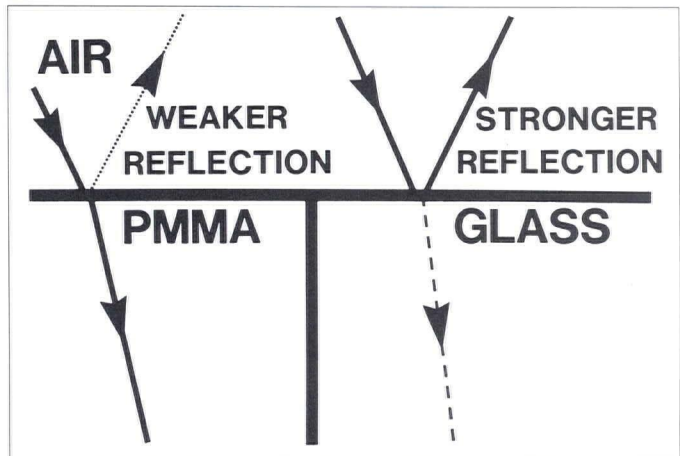


Fig 12

The greater the difference in refractive index between two media, the stronger the reflection generated when light passes across interface. Glass has higher refractive index than PMMA.

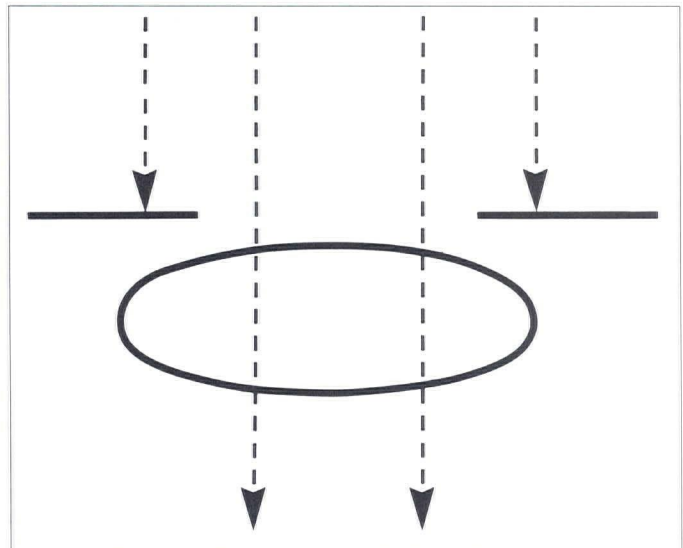


Fig 13

Posterior chamber implant does not have edges illuminated directly because of location behind iris, which is aperture stop of eye's optical system.

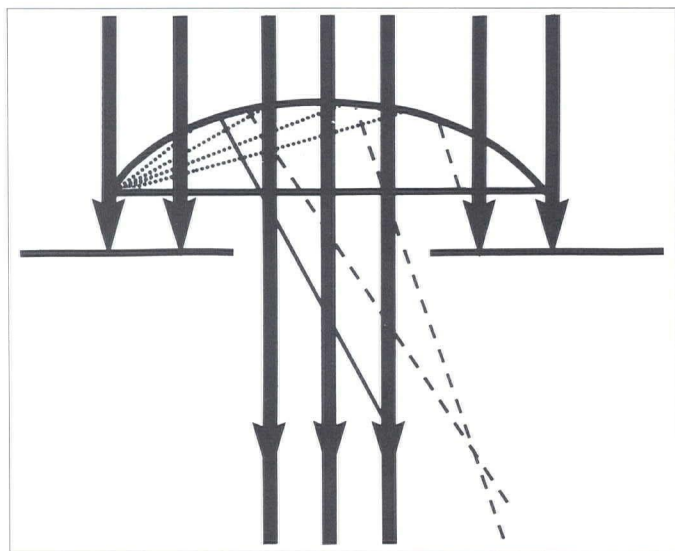


Fig 14

Direct illumination of edges of anterior chamber lens causes more light to be scattered than if aperture stop were in front of implant.

is reflected and the less transmitted. This phenomenon is diagrammatically represented in Fig 12, where air is the medium of the lowest refractive index, PMMA intermediate, and glass the highest. The air/glass interface generates a stronger reflection than the air/PMMA interface; and the reflected light is scattered and degrades contrast. When in situ, PMMA intraocular lens has reflections about 0.5% to 1.0% at each surface (13).

The posterior chamber lens is positioned behind the iris, which serves as the aperture stop of the eye's optical system. The location of the posterior chamber lens behind the aperture stop reduces internal reflections because the edge of the lens is not illuminated directly (Fig 13). Light that strikes the lens edge directly is a source of scatter and degraded contrast. In high-quality optical systems, the lens edges are always blackened to reduce reflections, which is impractical in lenses that are designed to be well-tolerated in an intraocular location. In this respect, anterior chamber lenses are inferior (Fig 14). While of theoretical interest, this scatter, however, does not appear to have a significant effect on visual quality.

The location of the anterior chamber lens in front of the aperture stop has another disadvantage in that it presents a large frontal area for reflection, with the entire front surface of the lens being illuminated at all times. The light reflected off the front of the optic can reflect off the concave surface of the cornea and enter the pupil. This represents yet another source of increased reflection, which may correlate with patients' complaints of glare (Fig 15). The posterior chamber

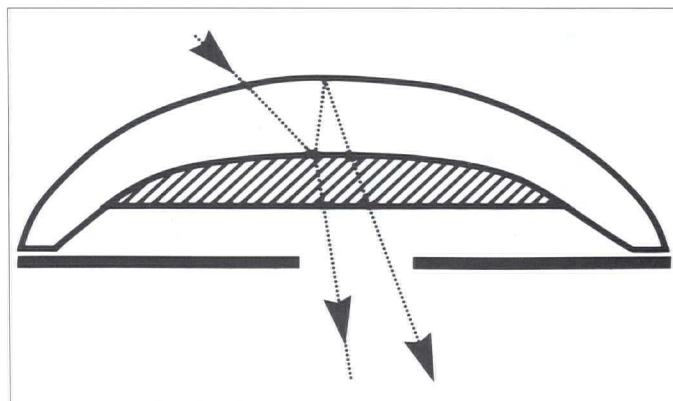


Fig 15

Concave mirror effect. Exposed frontal area available for generation of internal reflections is always maximal in anterior chamber lens position. Some of this light could be re-reflected off surface of cornea and thus enter pupil, degrading contrast.

lenses, however, present a much smaller frontal area for reflection; the brighter the overall level of ambient illumination, the smaller the area for reflection because of the constriction of the iris aperture.

Lens shape is another parameter that may have some clinical significance. The natural lens is both biconvex and aspheric in shape (14). These characteristics appear to minimize spherical aberration in the eye's optical system. Significant spherical aberration might be expected to cause blurring of the image when the pupil size reaches 5 mm to 6 mm in diameter (15). How retinal directivity serves to minimize the retina's sensitivity to whatever residual spherical aberration exists in the projected image has already been seen; however, the need to minimize spherical aberration in a lens implant has not been shown clinically (16). Computer ray-trace studies have demonstrated that a biconvex implant with the posterior curve approximately three times greater than the anterior curve produces less spherical aberration than the more commonly employed plano-convex design (17). The plano-convex design is also inferior regarding internal reflections. Since the plano surface tends to behave as a mirror, the risk of visible secondary images of point sources, such as car headlights at night, is increased (18).

An aspheric implant also serves to minimize spherical aberration, but any decentration of an aspheric lens results in more aberration than with a spherical lens (19).

In the past few years, intraocular lens implant placement has become one of the most widely performed and most successful surgical prosthetic procedures. Although the ability to mimic nature is far from perfect, further refinements in both the optical and mechanical quality of lens implants can be expected in the near future.

### References

1. Woods AC. Adjustment to aphakia. *Am J Ophthalmol* 1952;35:118-22.
2. Martin NF, Kracher GP, Stark WJ, Maumenee AE. Extended-wear soft contact lenses for aphakic correction. *Arch Ophthalmol* 1983;101:39-41.
3. Stark WJ, Leske MC, Worthen DM, Murray GC. Trends in cataract surgery and intraocular lenses in the United States. *Am J Ophthalmol* 1983;96:304-10.
4. Stark WJ, Worthen DM, Holladay JT, et al. The FDA report on intraocular lenses. *Ophthalmology* 1983;90:311-7.
5. Stark WJ, Terry AC, Worthen D, Murray GC. Update of intraocular lenses implanted in the United States. *Am J Ophthalmol* 1984;98:238-9.
6. Leibowitz H, Post R, Ginzburg A. The role of fine detail in visually controlled behavior. *Invest Ophthalmol Vis Sci* 1980;19:846-7.
7. Rossman K. Point spread function, line spread function and modulation transfer function. *Radiology* 1969;93:257.
8. Bodis-Wollner I. Detection of visual defects using the contrast sensitivity function. *Int Ophthalmol Clin* 1980;20:135-53.
9. Stiles WS, Crawford BH. The luminous efficiency of rays entering the eye pupils at different points. *Proc R Soc Lond [Biol]* 1933;112:428-50.
10. Enoch JM. Vertebrate receptor optics and orientation. *Doc Ophthalmol* 1979;48:373-88.
11. Ogle KN. Optics: An introduction for ophthalmologists. Springfield: Charles C. Thomas, 1961:143,197.
12. Nakao S, Mine K, Nishioka K, Kamiya S. The distribution of the refractive indices in the human crystalline lens. *Jpn J Clin Ophthalmol* 1969;23:41-4.
13. Miller D. Intraocular lenses. *Ann Ophthalmol* 1981;13:541-3.
14. Millodot M, Sivak J. Contribution of the cornea and lens to the spherical aberration of the eye. *Vision Res* 1979;19:685.
15. Smith WJ. Modern optical engineering. New York: McGraw-Hill, 1966:62-4.
16. Holladay JT, Bishop JE, Prager TC, Blaker JW. The ideal intraocular lens. *CLAO J* 1983;9:15-9.
17. Wang G, Pomerantzeff O. Obtaining a high-quality retinal image with a biconvex intraocular lens. *Am J Ophthalmol* 1982;94:87-90.
18. Holladay JT, Bishop JE, Prager TC, Blaker JW. Letters to the Editor. *CLAO J* 1983;9:204-7.
19. Kingslake R. Lens design fundamentals. New York: Academic Press, 1978:6.