

6-1985

## Preliminary Experience with Digital Subtraction Angiography in Cardiac Evaluation

Matthew W. Burke

P. C. Shetty

Rajinder Sharma

James F. Brymer

Fareed Khaja

Follow this and additional works at: <https://scholarlycommons.henryford.com/hfhmedjournal>



Part of the [Life Sciences Commons](#), [Medical Specialties Commons](#), and the [Public Health Commons](#)

---

### Recommended Citation

Burke, Matthew W.; Shetty, P. C.; Sharma, Rajinder; Brymer, James F.; and Khaja, Fareed (1985)  
"Preliminary Experience with Digital Subtraction Angiography in Cardiac Evaluation," *Henry Ford Hospital Medical Journal* : Vol. 33 : No. 2 , 95-101.

Available at: <https://scholarlycommons.henryford.com/hfhmedjournal/vol33/iss2/7>

This Article is brought to you for free and open access by Henry Ford Health System Scholarly Commons. It has been accepted for inclusion in Henry Ford Hospital Medical Journal by an authorized editor of Henry Ford Health System Scholarly Commons.

## Preliminary Experience with Digital Subtraction Angiography in Cardiac Evaluation

Matthew W. Burke, MD,\* P. C. Shetty, MD,\* Rajinder Sharma, MD,\* James F. Brymer, MD,† and Fareed Khaja, MD†

*We report our initial experience using digital subtraction angiography (DSA) techniques for cardiac evaluation. DSA of the heart may be performed with intravenous or right atrial injection of contrast medium (IVDSA) and with left ventricular or aortic root contrast injection (IADSA). The right ventricle and the atria are best demonstrated by IVDSA, while*

*the left ventricle and coronary arteries are best demonstrated by IADSA. The advantages and disadvantages of DSA of the heart are discussed. Present equipment limitations restrict the routine use of cardiac DSA, but these should be overcome with advances in technology.*

Catheterization of the left heart with left ventriculography and coronary angiography is the currently accepted radiographic procedure for evaluating the anatomy and physiology of the heart. In this procedure, images of the left ventricle and the coronary arteries are obtained following selective injection of radiopaque contrast medium and are recorded on videotape and cine film to permit dynamic evaluation of cardiac function. The imaging data are correlated with multiple physiologic pressure measurements recorded during the examination. In selected patients, cardiac response to various pharmacologic interventions can be analyzed.

The introduction of digital subtraction angiography (DSA) has stimulated much interest in applying this modality to cardiac evaluation (1,2). Recent developments in computer hardware have increased the practicality of DSA for routine cardiac procedures; however, general acceptance of DSA for this purpose awaits studies proving its reliability. This paper reports our preliminary experience with DSA in several aspects of cardiac evaluation.

### Materials and Methods

#### Patient studies

We have performed cardiac DSA on 25 patients, including 10 patients who were studied with injection of contrast media into the right atrium (IVDSA) and 15 who were studied with contrast injection into the left ventricle or aortic root (IADSA). In the group of patients undergoing IVDSA, three were examined as part of a research study comparing IVDSA left ventriculography with conventional left ventriculography for the determination of ejection fraction (EF). IVDSA of the left ventricle was performed in five additional patients undergoing aortic arch examinations for evaluation of atherosclerotic disease. Two patients underwent IVDSA for evaluation following cardiac surgery: one for evaluation of a left ventricle to aorta conduit and the other following repair of tetralogy of

Fallot anomaly. Another patient was studied specifically to exclude congenital heart disease.

Views of the coronary arteries were obtained in all patients who had IADSA. IADSA of the left ventricle was also performed in two of these patients. Three patients were evaluated for aortic aneurysm or dissecting aortic aneurysm. Conventional coronary angiography was performed in one of these patients for further evaluation of DSA findings. Two patients had postoperative evaluation of coronary artery bypass grafts, and ten patients had IADSA of the coronary arteries as part of evaluation of the aortic arch for either atherosclerotic disease or inflammatory processes.

#### Equipment and DSA procedures

All DSA examinations were performed on a Technicare DR-960 DSA unit. For IVDSA examinations, a 5 French pigtail catheter was placed in the right atrium via an antecubital or common femoral vein, and 30 mL of 76% w/v sodium/meglumine diatrizoate was injected at a rate of 25 mL/sec (Fig 1). For IADSA of the left ventricle, a 5 French pigtail catheter was placed into the left ventricle via a common femoral artery, and 30 mL of a 1:2 dilution of 60% w/v meglumine diatrizoate in normal saline was injected at a rate of 15 mL/sec (Fig 2A,B). During our early experience, IADSA of the coronary arteries was performed following injection of 30 mL of 60% w/v meglumine diatrizoate at 15 mL/sec through a conventional 5 French pigtail catheter placed in the aortic

Submitted for publication: March 25, 1985

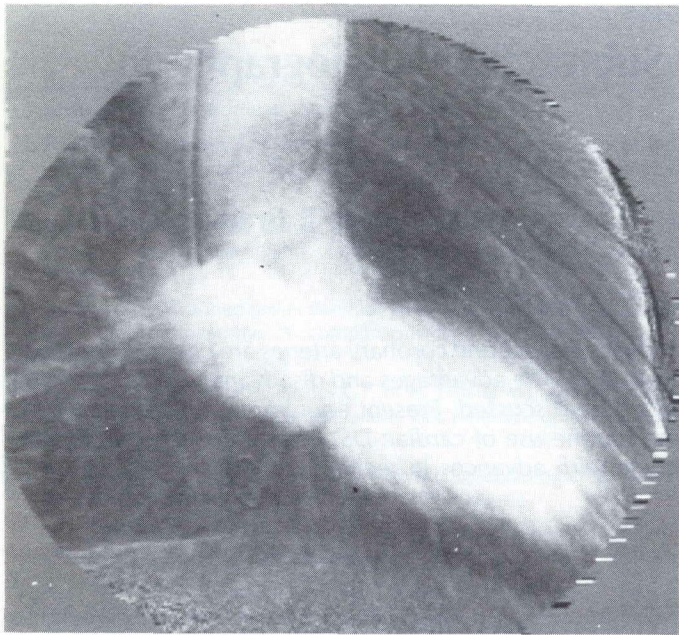
Accepted for publication: July 18, 1985

\*Department of Diagnostic Radiology, Division of Special Procedures and Interventional Radiology, Henry Ford Hospital

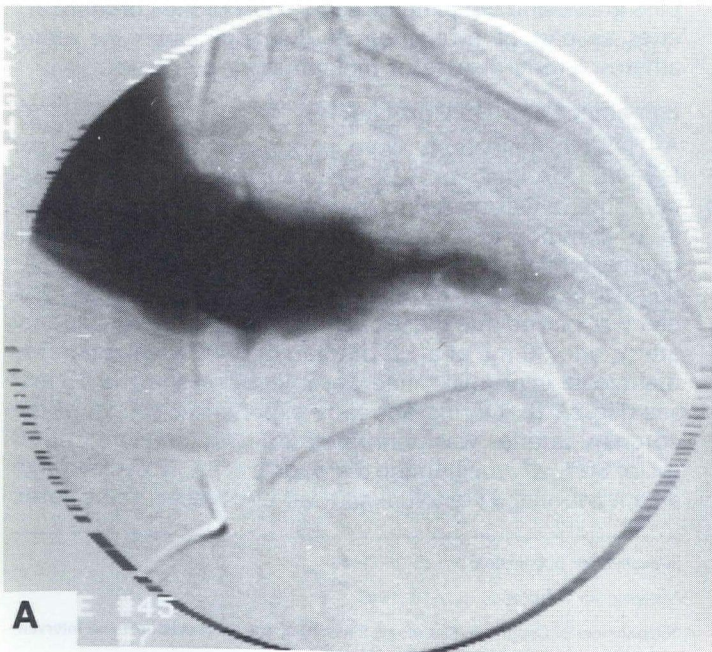
†Department of Internal Medicine, Division of Cardiovascular Medicine, Henry Ford Hospital

Address reprint requests to Dr Burke, Department of Diagnostic Radiology, Henry Ford Hospital, 2799 W Grand Blvd, Detroit, MI 48202.





**Fig 1**  
**Intravenous digital subtraction angiography (IVDSA) of left ventricle in 30° right anterior oblique (RAO) projection. Left atrium and aorta are superimposed, and aortic and mitral valve planes are not clearly seen in image.**



**Fig 2**  
**DSA of left ventricle in 30° RAO projection using intraventricular injection of dilute contrast material. Ventricular contours and aortic valve plane are demonstrated well. A. End-systole; B. End-diastole.**

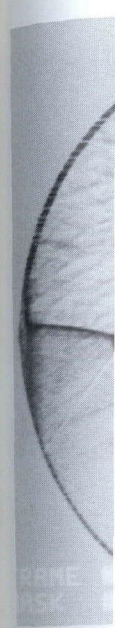
root via a common femoral artery. Recently, we used a specially designed 5 French catheter (Lariat catheter, Mallinckrodt, Inc) for this purpose (Fig 3).

IVDSA of the atria and ventricles and IADSA of the left ventricle were obtained at 256 x 256 x 10 matrix using ECG gating techniques and with a maximum instantaneous exposure rate of 15 frames per second. With ECG gating, an electrical signal (a "trigger") is generated when the R-wave is detected. This trigger is sent to the computer, causing it to perform an operator-programmed pattern of X-ray exposures. The pattern can be programmed to obtain selected exposures at end-systole and end-diastole and is repeated for each cardiac cycle.

To calculate left ventricle ejection fraction, end-systole and end-diastole images are selected, and the contour and long axis of the left ventricle are traced on these images (Fig 4A,B). With IVDSA, the mitral and aortic valve planes may be obscured by the superimposed left atrium and therefore must be approximated. Software programs in the DSA computer subsequently use these data to calculate ejection fraction.

IADSA of the coronary arteries was performed using 512 x 512 x 10 matrix without ECG gating and with a maximum exposure rate of three frames per second.

IVDSA and IADSA examinations can generally be performed within 20 to 45 minutes depending on the number of views



DSA of coronary root. Right

obtained and left side with IVDSA so that th

**Left vent**  
 The Table  
 culated u  
 in three p  
 ventricul  
 anc in t  
 have bee  
 piratory a  
 tion fract  
 the two l  
 tricle, bu  
 was not  
 Analysis  
 onstrated  
 tient wh

Comparis  
 Conventio

Patient
1
2
3



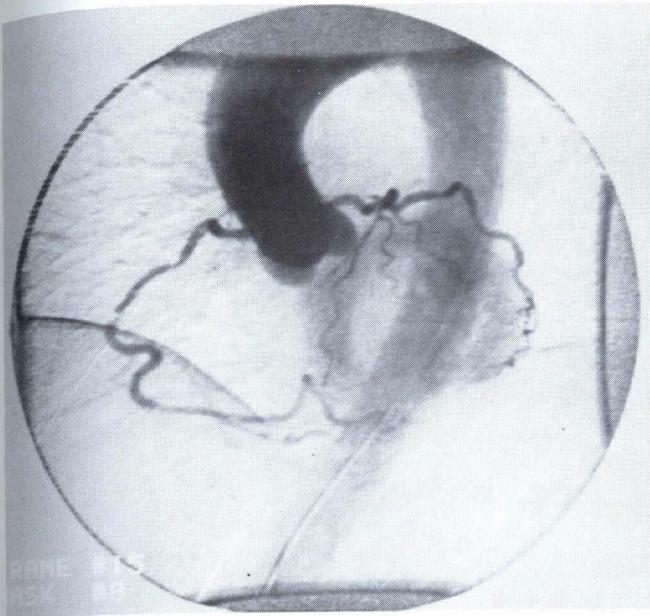


Fig 3

DSA of coronary arteries following injection of contrast material into aortic root. Right coronary artery is dominant and has two stenotic lesions. Patient had symptoms of coronary artery disease.

obtained of the heart and coronary arteries. Both the right and left sides of the heart can be imaged in the same sitting with IVDSA (Fig 5A,B). DSA images are displayed in real time so that they are immediately available for interpretation.

### Results

#### Left ventricular morphology and function

The Table compares the left ventricular ejection fractions calculated using both IVDSA and conventional ventriculography in three patients. DSA compared favorably with conventional ventriculography in two patients and showed a large discrepancy in the third. The discrepancy in this third patient may have been due to the large degree of patient motion and respiratory artifact associated with the DSA examination. Ejection fractions were calculated in the additional IVDSA and the two IADSA patients undergoing evaluation of the left ventricle, but comparison with conventional ventriculography was not performed.

Analysis of left ventricular morphology and wall motion demonstrated hypokinesis of the anterior wall in an IVDSA patient who had undergone previous coronary artery bypass.

Table

Comparison of Intravenous Digital Subtraction Angiography (IVDSA) and Conventional Ventriculography for Calculation of Ejection Fraction (EF)

Patient	IVDSA EF	Conventional EF
1	79%	88%
2	89%	82%
3	58%	82%

Global hypokinesis with an abnormal ejection fraction of 39% was observed in one of the IADSA patients. The left ventricle appeared normal in the remainder of the patients.

#### Presurgical and postsurgical examinations

Patency of the conduit was observed in the patient with the left ventricle to aorta conduit. The patient with tetralogy of Fallot presented preoperatively with a large ventricular septal defect with overriding aorta. The postoperative IVDSA examination showed no evidence of interventricular or interatrial shunt following closure of the septal defect (Fig 6). Normal atria, ventricles, pulmonary arteries, veins and aorta were clearly demonstrated in a child specifically referred for exclusion of congenital heart disease.

#### Coronary artery evaluations

The major branches of the coronary arteries were demonstrated in 14 of the 15 patients who underwent the IADSA procedure. Early in our experience, we were unable to demonstrate the coronary arteries in one case probably because a conventional pigtail catheter was used rather than the special catheter used in our later cases. Using the specially designed catheter, we are able to demonstrate smaller branches of the coronary arteries more consistently than with the conventional pigtail catheter. Myocardial blush and coronary veins can also be seen. Use of the aortic root injection technique reduces the time required by selective catheterization of the coronary arteries. In one patient, an IADSA finding interpreted as occlusion of the left anterior descending artery was shown at coronary angiography to be a bifurcation of this artery into two very tortuous, equally sized branches.

### Discussion

#### Technical considerations

Compared to conventional cardiac angiography, the main advantages of DSA are its greater contrast sensitivity and its capacity for real-time image display. Its main disadvantages are poorer spatial resolution and greater susceptibility to degradation by motion artifacts.

The background subtraction techniques inherent to DSA increase the sensitivity for detection of administered contrast media. This factor permits the intravenous administration of contrast media for many diagnostic applications that would require a more invasive arterial administration using conventional angiography. Similarly, if an IADSA procedure is warranted, less concentrated contrast medium is required, thus decreasing the potential chemotoxic load to the patient. The volume of dilute contrast media used for IADSA must be maintained, however, to ensure complete filling of the ventricle or vessel being examined. Compared to IADSA, IVDSA procedures require larger volumes of more concentrated contrast media, but the administered doses are compatible with outpatient examinations. As previously discussed, it is possible to image both the right and left sides of the heart using one IVDSA injection.



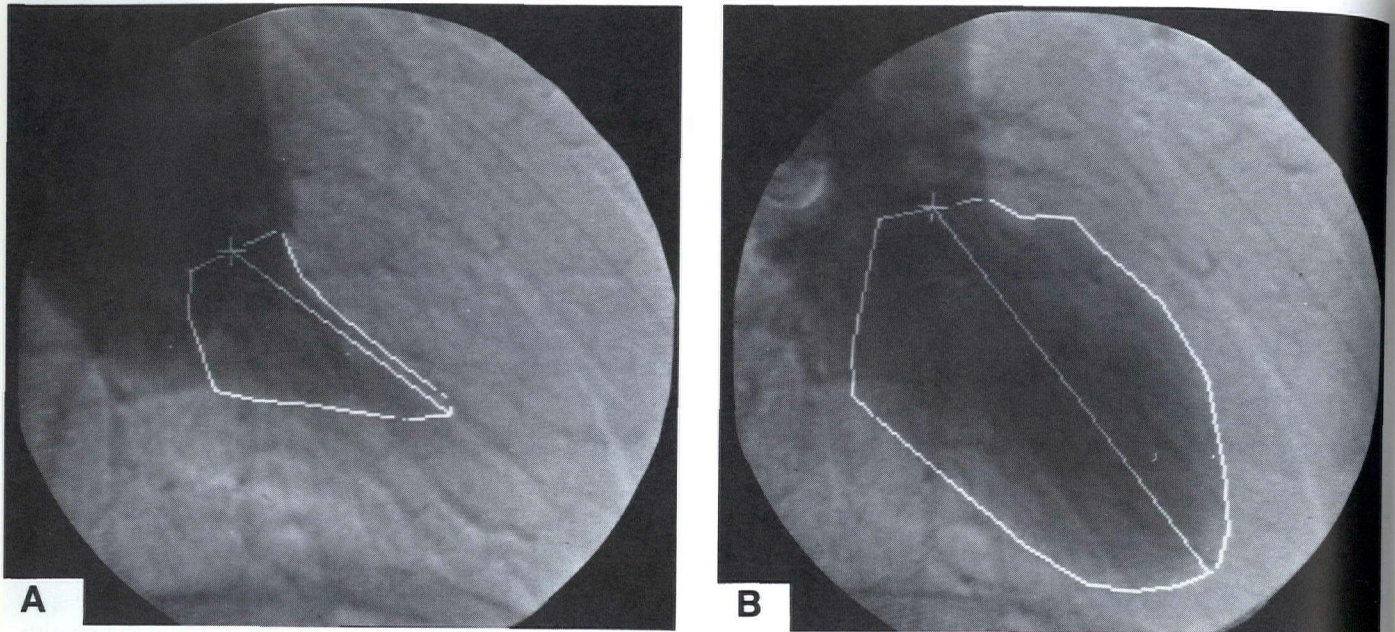


Fig 4

IVDSA of left ventricle in 30° RAO projection. Outlines of left ventricle, aortic valve plane, and long axis of left ventricle are drawn on images. Left atrium is opacified and partially obscures mitral and aortic valve planes. These are approximated on images. A. End-systole; B. End-diastole.

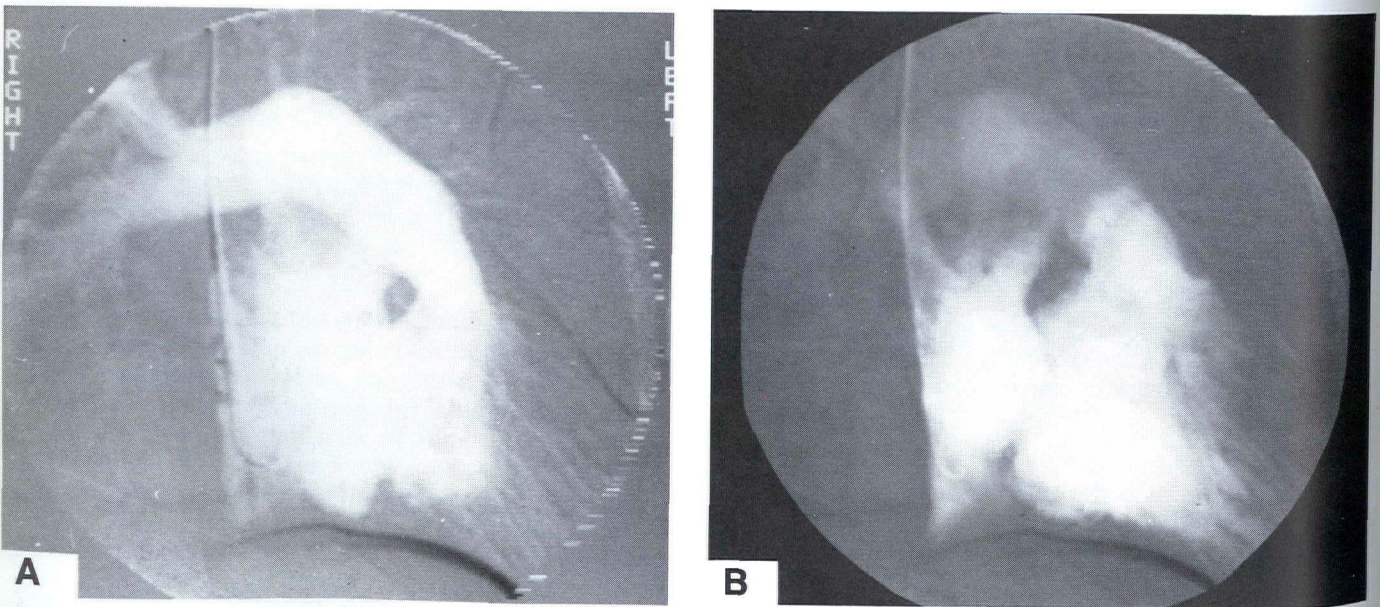


Fig 5

DSA of the right atrium, right ventricle, and main pulmonary artery. A. End-systole; B. End-diastole.

A 22-year-old  
of ventricular  
of pulmonary  
anterior obliqu  
digitally int

On the other  
DSA make t  
gan, or vess  
particularly  
of complex  
motion.

DSA and co  
in the recor  
verted to a  
making ther  
ing. Howev  
is significant  
raphy. Rate  
diac angiog  
for detailed  
DSA equip  
15 frames p  
during a D  
ond, using  
speed at w  
the magnet  
three frame  
ond are cor  
volumes (3  
order to ok  
diastole. Ar



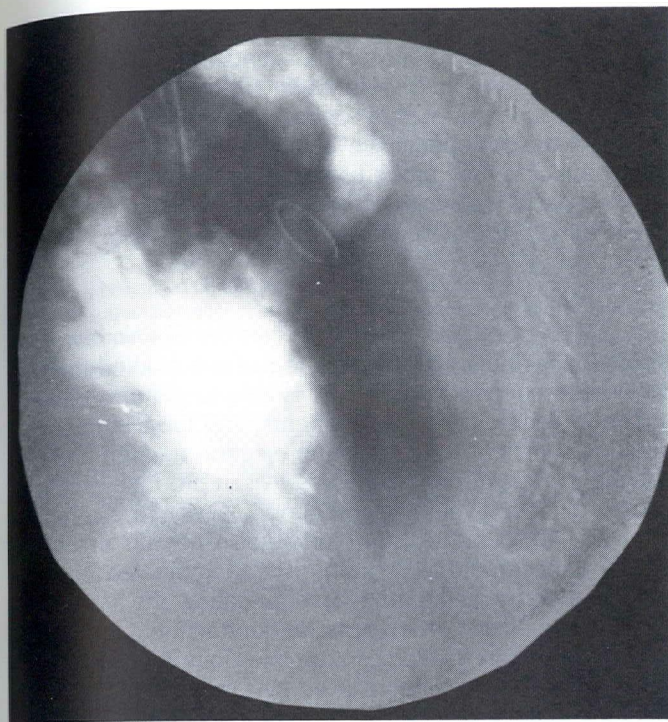


Fig 6

A 22-year-old woman who had tetralogy of Fallot. She underwent repair of ventricular septal defect, correction of Potts procedure, and insertion of pulmonary Hancock valve conduit. IVDSA was performed in 45° left anterior oblique projection. Right and left ventriculograms are combined digitally into one image. There was no residual left-to-right shunt.

On the other hand, the subtraction techniques inherent to DSA make the procedure particularly sensitive to body, organ, or vessel movement. Resulting motion artifacts may be particularly significant when dealing with the combination of complex cardiac motion, respiratory motion, and patient motion.

DSA and conventional angiography have primary differences in the recording medium. In DSA, images are directly converted to a digital format and stored in computer memory, making them immediately available for review and processing. However, the rate at which DSA images can be obtained is significantly slower than with conventional cardiac angiography. Rates of 60 frames per second are possible with cardiac angiography, permitting excellent temporal resolution for detailed analysis of cardiac motion. While our current DSA equipment can achieve a maximum exposure rate of 15 frames per second, the average exposure rate achieved during a DSA examination is limited to 10 frames per second, using a 256 x 256 x 10 matrix, because of the slower speed at which images are transferred from the camera to the magnetic disk. With 512 x 512 x 10 matrix, the limit is three frames per second. Exposures at a rate of 10 per second are considered adequate for measuring left ventricular volumes (3); however, ECG gating techniques are used in order to obtain images accurately at end-systole and end-diastole. An exposure rate of 15 per second is probably the

minimal acceptable rate for measuring segmental left ventricular contraction (3). In addition, spatial resolution is affected by the matrix size; a 256 x 256 matrix is adequate for measuring left ventricular volumes, but 512 x 512 matrix is probably the minimum necessary for evaluating the coronary arteries.

#### Ventricular morphology and function

IVDSA of the left ventricle has been proposed as a less invasive imaging method than is conventional left ventriculography. It does not produce premature ventricular contractions, which commonly occur with the conventional procedure (4-6). Imaging can be easily repeated and performed on either inpatients or outpatients (4,7). IVDSA images of the left ventricle in the right anterior oblique projection generally show the anterior and inferior walls clearly (Fig 1). The mitral and aortic valve planes may be somewhat difficult to outline because the left atrium is opacified with contrast material and is superimposed on this portion of the heart. These margins can be reasonably estimated by analysis of the entire DSA image sequence. End-systolic and end-diastolic volumes can be calculated using a reference grid to correct for magnification. Wall motion can be analyzed by reviewing the DSA image sequence. IVDSA may have an advantage in evaluating patients whose left ventricle is difficult to enter, eg, patients with prosthetic aortic valves.

Various studies have compared IVDSA of the left ventricle with conventional left ventriculography (4,5,7). The investigators used different DSA techniques to obtain cardiac images but found good correlation between ejection fraction, end-systolic volume, and end-diastolic volume measurements by the two techniques. They described their observations of wall motion as "diagnostic."

IVDSA is very susceptible to registration artifacts caused by patient motion, and the studies may be significantly degraded in patients who are unable to hold their breath or otherwise cooperate in the examination. We have on occasion allowed patients to breathe quietly during the examination and have still been able to obtain diagnostic images. Insufficient opacification of the left ventricle may occur in patients with low cardiac output, LVEF less than 45%, and tricuspid regurgitation. Pressure measurements in the left ventricle and aorta cannot be obtained during IVDSA, nor can the competency of valves be evaluated since adjacent chambers and vessels fill almost simultaneously.

IADSA of the left ventricle following intraventricular injection of contrast material is performed in similar fashion to the IVDSA study; the same patient positioning, exposure rates, and ECG gating techniques are used. Compared to IVDSA, the IADSA images demonstrate the ventricular contours and the mitral and aortic valve planes in better detail (Fig 2A,B).

Comparisons of conventional left ventriculography with IADSA of the left ventricle have demonstrated good correlation in ejection fraction, end-systolic volume, end-diastolic



volume and wall motion (6,8). In addition, the use of more dilute concentrations of contrast media resulted in no significant measurable changes in myocardial contractility during the IADSA examinations. This factor makes it possible to perform multiple injections of contrast media into the left ventricle to observe the effects of various interventions, such as atrial pacing. Pressure measurements can also be obtained with this IADSA procedure.

The right ventricle has not been studied as extensively as the left using either conventional angiography or DSA techniques. To date, volumetric calculations for the right ventricle do not correlate well with autopsy studies, probably due to the irregular shape of the right ventricle. DSA of the right ventricle can be performed as part of an IVDSA study of the left ventricle. In fact, the right side of the heart is demonstrated very well during IVDSA because the contrast bolus is most concentrated in this part of the heart (Fig 5A,B). In a study of patients with congenital heart disease, Lange found good correlation between conventional techniques and DSA in evaluation of right ventricular volumes (9). He also found the ability to use smaller amounts of contrast an advantage of DSA. Densitometric measurements of DSA data, which are independent of the geometry of the heart, may represent an improvement over current methods for volumetric measurement of the right ventricle.

#### Presurgical and postsurgical examinations

DSA of the heart in a postoperative setting can spare the patient some of the risk and discomfort of conventional heart catheterization while producing diagnostic quality images. Similar advantages are gained in evaluating the pediatric patient with suspected cardiac abnormalities. Various investigators have used IVDSA to evaluate patients having congenital heart disease (9,10), aneurysms of the ventricular and atrial septa (11), and intracardiac masses (12).

#### Coronary artery examinations

An IADSA approach is required for evaluation of the coronary arteries since, at present, the coronary arteries cannot be adequately demonstrated by IVDSA. The ability to demonstrate adequately the coronary arteries following injection of contrast media into the aortic root may render IADSA of the coronary arteries an adjunct procedure during the evaluation of the aorta and cerebral vessels for atherosclerotic disease.

The current limitation of three frames per second using a 512 x 512 x 10 matrix is adequate for evaluating patency or significant stenosis of the coronary arteries; however, faster frame rates with short exposure times are necessary for obtaining finer detail. This technique has been useful in evalu-

ating the aortic root and coronary arteries in patients with possible aortic dissection who had concurrent renal compromise and who would therefore benefit from the administration of a reduced amount of contrast material. It has also been helpful in the postoperative evaluation of coronary artery bypass grafts and may prove useful as a screening procedure for unsuspected coronary artery lesions in patients being evaluated for cerebrovascular atherosclerotic disease.

### Summary

Preliminary results of DSA on the patients studied thus far have been encouraging. IVDSA is able to demonstrate the atria and ventricles in most patients, and the angiographic detail is sufficient for calculating ejection fraction and observing cardiac morphology. IADSA can produce excellent images of the left ventricle and good images of the coronary arteries. IADSA of the left ventricle also permits use of reduced concentrations of administered iodinated contrast media, thereby decreasing or eliminating the respective chemotoxic effects on myocardial contractility, and consequently allowing repeated contrast injections into the left ventricle. DSA examinations can be performed quickly, since selective catheterization can be avoided, and the adequacy of the study can be determined immediately because of the real-time subtraction and display capabilities of DSA equipment.

Digital subtraction imaging techniques are being applied increasingly to cardiac evaluation, a procedure that requires good spatial resolution and rapid image acquisition which formerly could be achieved only with conventional radiographic techniques. The relatively poorer spatial resolution and slower framing rates need to be overcome before DSA of the heart becomes a standard procedure. Some DSA equipment manufacturers have circumvented the framing rate problem by using a fluoroscopic method and storing images rapidly on videotape. Other manufacturers are developing methods for the high-speed transfer of image data to magnetic disks. The problem of spatial resolution is being addressed by increasing the image matrix to 1024 x 1024 and greater.

We anticipate that DSA will be used routinely in the future as a screening tool, as a part of cardiac catheterization procedures, and for follow-up evaluations.

### Acknowledgment

The authors thank Dennis P. Swanson, RPh, MS, for his advice and help in the preparation of this manuscript.

1. Mancini GBJ, digital subtraction: 6:252-62.
2. Tobis JM, Na 1983;84:68-
3. Freeman E, graphic frame 1970;96:58;
4. Tobis J, Nalc digital subtraction fluoroscopic
5. Goldberg H subtraction convention: 1:858-62.
6. Tobis JM, N digital subtraction angiograms



References

1. Mancini GBJ, Higgins CB, Norris SL, Slutsky RA. Cardiac imaging with digital subtraction angiography. *Cardiovasc Intervent Radiol* 1983;6:252-62.
2. Tobis JM, Nalcioglu O, Henry WL. Digital subtraction angiography. *Chest* 1983;84:68-75.
3. Freeman E, Ziskin MC, Bove AA, Gilmenz JL, Lynch PR. Cineradiographic frame rate selection for left ventricular volumetry. *Radiology* 1970;96:587-91.
4. Tobis J, Nalcioglu O, Johnston WD, et al. Left ventricular imaging with digital subtraction angiography using intravenous contrast injection and fluoroscopic exposure levels. *Am Heart J* 1982;104:20-7.
5. Goldberg HL, Borer JS, Moses JW, Fisher J, Cohen B, Skelly NT. Digital subtraction intravenous left ventricular angiography: Comparison with conventional intraventricular angiography. *J Am Coll Cardiol* 1983;1:858-62.
6. Tobis JM, Nalcioglu O, Johnston WD, et al. Correlation of 10-milliliter digital subtraction ventriculograms compared with standard cineangiograms. *Am Heart J* 1983;105:946-52.
7. Greenbaum RA, Evans TR. Investigation of left ventricular function by digital subtraction angiography. *Br Heart J* 1984;51:163-7.
8. Nichols AB, Martin EC, Fles TP, et al. Validation of the angiographic accuracy of digital left ventriculography. *Am J Cardiol* 1983;51:224-30.
9. Lange PE, Budach W, Radtke W, Onnasch DGW, Heintzen PH. Right ventricular imaging with digital subtraction angiography using intraventricular contrast injection. *Am J Cardiol* 1984;54:839-42.
10. Buonocore E, Pavlicek W, Modic MT, et al. Anatomic and functional imaging of congenital heart disease with digital subtraction angiography. *Radiology* 1983;147:647-54.
11. Yiannikas J, Moodie DS, Sterba R, Gill CC. Intravenous digital subtraction angiography to assess aneurysms of the ventricular and atrial septum pre- and postoperatively. *Am J Cardiol* 1984;53:383-5.
12. Yiannikas J, Zaidi AR, Moodie DS. Evaluation of intracardiac masses by digital subtraction angiography. *Am Heart J* 1984;108:600-3.