

9-1983

## Posttraumatic Hernia of the Bladder

Joseph L. Ponka

Farouck N. Obeid

Follow this and additional works at: <https://scholarlycommons.henryford.com/hfhmedjournal>



Part of the [Life Sciences Commons](#), [Medical Specialties Commons](#), and the [Public Health Commons](#)

---

### Recommended Citation

Ponka, Joseph L. and Obeid, Farouck N. (1983) "Posttraumatic Hernia of the Bladder," *Henry Ford Hospital Medical Journal* : Vol. 31 : No. 3 , 173-176.

Available at: <https://scholarlycommons.henryford.com/hfhmedjournal/vol31/iss3/12>

This Article is brought to you for free and open access by Henry Ford Health System Scholarly Commons. It has been accepted for inclusion in Henry Ford Hospital Medical Journal by an authorized editor of Henry Ford Health System Scholarly Commons.

## Posttraumatic Hernia of the Bladder

Joseph L. Ponka, MD\* and Farouck N. Obeid, MD\*\*

*Fractures of the pelvis occur commonly in patients who are involved in high speed vehicle accidents or who fall from a substantial height. Fortunately, with improved surgical management, these patients usually recover not only from the pelvic fractures but from associated visceral injuries as well. Some survivors of pelvic fractures subsequently develop unusual hernias.*

*We report the case of a man who developed hernia of the urinary bladder following pelvic fracture. Two pre-*

*vious operations had failed to eliminate his hernia. We describe the technique of repair used successfully in this case and review similar reported cases.*

*Surgeons who care for traumatized patients must be alert to the possible presence of a pelvic fracture whenever pelvic laparotomy is performed for visceral injury. Reduction of the fracture and internal fixation are necessary to prevent posttraumatic hernia.*

Severe pelvic trauma usually occurs as the result of a vehicle accident or in a fall from substantial heights. Such injuries may involve the bladder or urethra, or both. Because medical care is improving, more of such injured patients survive to develop a subsequent pelvic hernia. Consequently, an unusual type of posttraumatic hernia is being recognized and reported with greater frequency.

Because reported injuries to the urinary tract and pelvis usually appear in specialty journals concerned with trauma (1,2), orthopedic surgery (3-6), or urology (7,8), general surgeons might not be fully aware of reports of bladder hernias resulting from pelvic fractures.

We report the case of a young man who sustained a pelvic fracture in a motorcycle accident and subsequently developed a posttraumatic hernia. Two repair attempts were unsuccessful. Subsequently, we successfully repaired his hernia by using Marlex mesh. Others have reported success in repairing posttraumatic hernias of the bladder by procedures that use stainless steel wire, angled metal plates, and synthetic meshes.

Fixation of the pelvis during operative treatment of

injured pelvic viscera is recommended as a measure to prevent these posttraumatic hernias.

### Case Report

A 28-year-old man sustained multiple injuries in a motorcycle accident in 1975. He had multiple pelvic fractures and a deep perineal laceration. Diastasis of the symphysis pubis was estimated to measure at least four centimeters. Intraabdominal visceral injuries were suspected, but when a laparotomy was performed, none were found. A diverting colostomy was performed because of the severe perineal injuries. In addition, the patient suffered fractures of the right hip and several ribs as well as a head injury. The colostomy was closed four months after the accident, but the patient noted a protrusion in the right groin and pubic area.

In January 1976, the first attempt was made elsewhere to repair the groin hernia through an inguinal incision. This repair failed, and a second attempt at repair in January 1977 was also followed by prompt recurrence.

In March 1981 the patient came to Henry Ford Hospital because he still had swelling in the right groin area. Swelling in the perineum was prominent when the bladder was full, but noticeably less after voiding.

Physical examination revealed a well-healed incision in the inguinal area. No protrusion was visible or palpable at this site. When asked to point out the hernia, the

Submitted for publication: December 10, 1982

Accepted for publication: March 2, 1983

\*Department of Surgery, Henry Ford Hospital

\*\*Department of Trauma and Emergency Surgery, Henry Ford Hospital

Address reprint requests to Dr. Ponka, Henry Ford Hospital, West Bloomfield Center, 6777 W Maple Rd, West Bloomfield, MI 48033.

patient placed his finger upon a defect in the perineum in the region of the pubic arch, where it was easily identified by digital examination.

X-ray studies of the pelvis showed wide separation of the pubic symphysis (Fig. 1). Cystograms were obtained to identify the relationship of the bladder both to the defect in the bony pelvis and the herniation. We diagnosed a posttraumatic pelvic hernia and advised repair by means of a synthetic mesh.

### Operative Procedure

A transverse incision was made approximately three centimeters above the symphysis. The anterior sheath of the rectus abdominis was incised transversely, and the muscle was retracted to the left, giving access to its posterior sheath. The peritoneal cavity was entered, and the bladder was identified where it had herniated into the defect in the pubic symphysis. With dissection at the preperitoneal level, the bladder was freed completely from the defect, and Cooper's ligaments were identified on either side. The mesh was attached bilaterally to Cooper's ligaments. Posteriorly, a rim of dense connective tissue was used in the repair, while anteriorly, the

Marlex mesh was sutured to the posterior sheath of the rectus abdominis muscle (Figs. 2,3).

The patient was discharged on the seventh postoperative day. When he was reexamined approximately one year later, the repair was sound.

### Discussion

Pelvic fractures resulting from vehicle and industrial accidents are increasingly frequent and are often associated with injuries to the genito-urinary tract. Between 1907 and 1942, improved treatment of these injuries (including prompt, accurate diagnosis, correction of hypotension, diversion of the urinary stream, and drainage of extravasated urine) reduced the mortality rate from 78% to 23% (9).

In 1953, Newland reported that when antibiotics were added to these principles of management, death could usually be prevented. When death occurred in such cases, it was often due to multiple injuries remote from the genito-urinary tract (9). As a result of better management, however, more patients with complex pelvic injury develop late complications, such as the hernia of our patient.

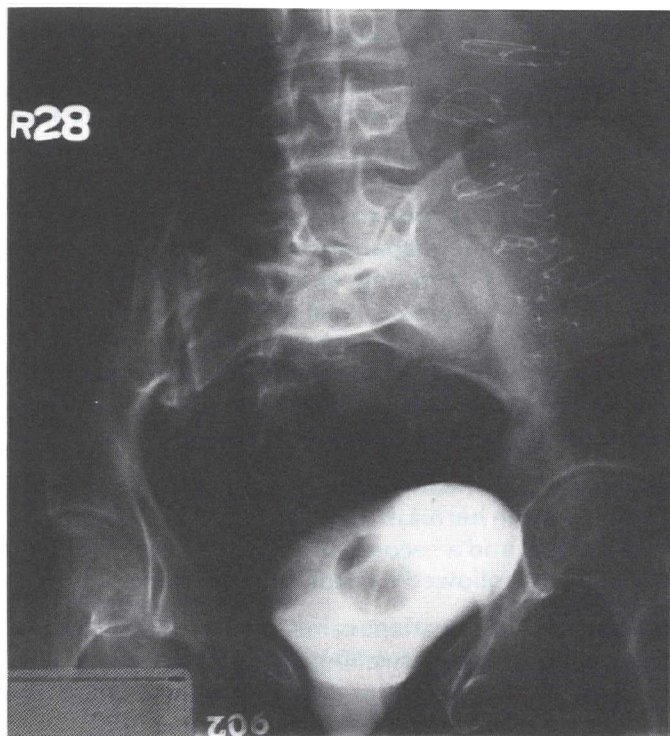

Fig. 1

Preoperative cystograms illustrate wide separation of the symphysis, measuring 3.7 cm. Protrusion of the bladder between the pubic bones can be seen.

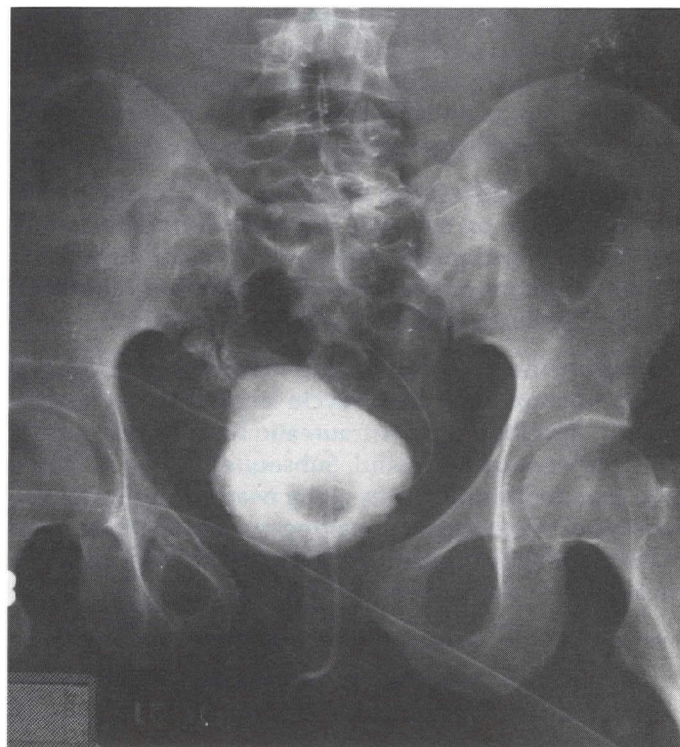


Fig. 2

Postoperative cystograms illustrating widening of the distance between the pubic rami. Herniation of the bladder has been corrected.

## Posttraumatic Hernia of Bladder

While the bony pelvis offers strong protection for the pelvic viscera, severe trauma can cause a variety of fractures. The strength of the pelvic arch depends on the integrity of the anterior interpubic ligament (3). If the ligament is severed, the sacroiliac ligaments provide relatively little support.

Peltier (4) classified pelvic fractures according to their effect on weight bearing. Fractures of the pubic arch near or actually involving the symphysis can usually be demonstrated when there is clinical evidence of urinary tract injury (7,8). Severe involvement of the genitourinary tract often complicates displaced comminuted fractures, symphyseal separation, and bilateral fractures of the pubic arch (7,8). In such cases, cystograms and urethrograms are useful diagnostic measures. Brosman and Fay (1) believe that every patient with a pelvic fracture should be suspected of a bladder injury, and they recommend radiologic visualization of the bladder and urethra for most such patients.

Several cases of posttraumatic hernias following pelvic fracture have been reported. Fuhs, et al (5) described bladder herniation in a 53-year-old man who was injured in a fall from a bucking horse. The patient suffered pubic diastasis of ten centimeters and widening of both sacroiliac joints. He was treated initially with a pelvic sling, but his urinary tract symptoms persisted.

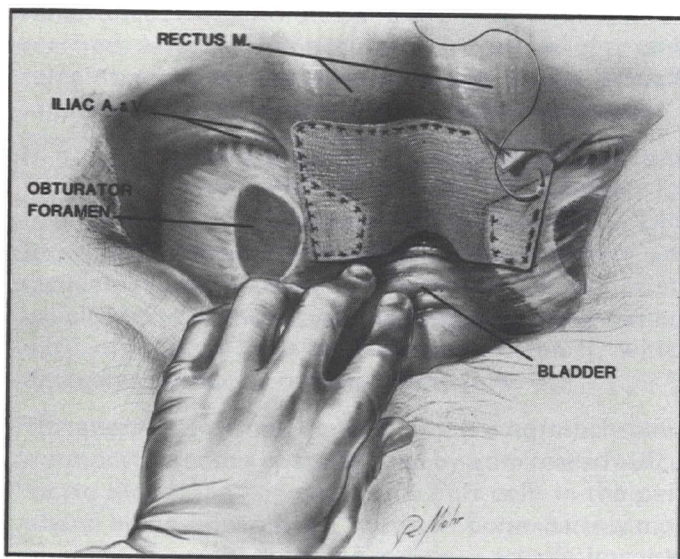


Fig. 3

**Drawing of the method of repair viewed from within the pelvis seen anteriorly. The hand is applying traction downward on the bladder. Marlex mesh is attached to Cooper's ligament on each side. The deepest, or inferior margin, is attached to the periosteum of the posterior sheath of the rectus abdominus muscle.**

Surgical exploration performed through a Pfannenstiel incision disclosed herniation of the bladder, while the right pubic bone had eroded through the bladder. Wire was used to hold the pubic bones in place, and the pelvic floor was repaired with Mersilene mesh (5). As a result of the successful repair, the patient remained free of symptoms for two years.

In the second case, Foster, et al (2) reported bladder herniation complicating posttraumatic pubic diastasis. This 68-year-old man had been run over by a truck when he was nine years old and had suffered pubic diastasis, ruptured bladder, and bowel and rectal injuries. After he recovered, he had residual diastasis pubis of seven centimeters and an incisional hernia. At 53, the patient had a prostatectomy through a vertical midline incision. Subsequently, he developed a suprapubic mass and had difficulty voiding. Roentgenographic studies revealed that the bladder was prolapsing into the mass. Three attempts at fascial repair of the defect failed, but in a fourth attempt, a cortical strut graft (10 x 1 cm), which was removed from the tibia, was secured between the pubic bones and fixed with a wire suture. This repair succeeded, and ten years later, the patient had no urinary tract symptoms (2).

Our case is the third instance of bladder hernia present long after severe trauma to the pelvis. In the past, traumatic diastasis of the symphysis with fractures of the pelvis carried a high mortality rate. Now, patients with severe pelvic injuries survive but may develop delayed complications. Accordingly, the trauma surgeon should take measures to prevent posttraumatic bladder hernias from developing in these patients.

Internal fixation of the pelvis has been used to treat pelvic fractures for many years. A pelvic canvas sling used for six to ten weeks is established practice. In 1953, Whiston (6) described internal fixation for certain types of pelvic fractures and dislocations, using stainless steel pins driven obliquely across the symphysis in both directions. In 1969, Gustafsson (10) used a stainless steel wire inserted through the foramina obturatoria as a cerclage. This method permitted the patient to return to normal activity sooner than did more conservative procedures. In 1973, Sharp (11) described the use of an angled plate to achieve internal fixation of the disrupted pelvis in five patients. In two cases we have discussed, synthetic mesh was used for internal fixation. The effectiveness of Marlex mesh in repairing traumatic hernias is encouraging. We recommend its use with internal fixation for disrupting injuries of the symphysis pubis.

## References

1. Brosman SA, Fay R. Diagnosis and management of bladder trauma. *J Trauma* 1973;13:687-94.
2. Foster EJ, Murray DG, Gregg RO. Chronic bladder herniation associated with pubic diastasis. *J Trauma* 1981;21:80-2.
3. Domisse JF. Diametric fractures of the pelvis. *J Bone Joint Surg* 1960;42B:432-43.
4. Peltier LF. Complications associated with fractures of the pelvis. *J Bone Joint Surg* 1965;47A:1060-9.
5. Fuhs SE, Herndon JH, Gould FR. Herniation of the bladder. *J Bone Joint Surg* 1978;60A:704-7.
6. Whiston J. Internal fixation for fractures and dislocations of the pelvis. *J Bone Joint Surg* 1953;35A:701-6.
7. Flaherty JJ, Kelley R, Burnett B, et al. Relationship of pelvic bone fracture patterns to injuries of urethra and bladder. *J Urol* 1968;99:297-300.
8. Cass AS. Bladder trauma in the multiple injured patient. *J Urol* 1976;115:667-9.
9. Newland DE. Genitourinary complications of pelvic fracture. *JAMA* 1953;152:1515-20.
10. Gustafsson A. Operative adaptation with cerclage in traumatic rupture of the symphysis. *Acta Orthop Scand* 1970;41:446-53.
11. Sharp IK. Plate fixation of disrupted symphysis pubis. *J Bone Joint Surg* 1973;55B:618-20.