

3-1980

ARDS and Cerebral Infarction Complicating Mycoplasma Pneumonia in Sickle Cell Trait

Mark I. Pensler

Jan R. Radke

Follow this and additional works at: <https://scholarlycommons.henryford.com/hfhmedjournal>



Part of the [Life Sciences Commons](#), [Medical Specialties Commons](#), and the [Public Health Commons](#)

Recommended Citation

Pensler, Mark I. and Radke, Jan R. (1980) "ARDS and Cerebral Infarction Complicating Mycoplasma Pneumonia in Sickle Cell Trait," *Henry Ford Hospital Medical Journal* : Vol. 28 : No. 1 , 60-62.

Available at: <https://scholarlycommons.henryford.com/hfhmedjournal/vol28/iss1/12>

This Article is brought to you for free and open access by Henry Ford Health System Scholarly Commons. It has been accepted for inclusion in Henry Ford Hospital Medical Journal by an authorized editor of Henry Ford Health System Scholarly Commons.

ARDS and Cerebral Infarction Complicating Mycoplasma Pneumonia in Sickle Cell Trait†

Mark I. Pensler, MD* and Jan R. Radke, MD*

A patient with Down's syndrome and sickle cell trait developed the adult respiratory distress syndrome and cerebral infarction during infection with Mycoplasma pneumoniae. The slow recovery of pulmonary function was unrelated to antimicrobial therapy. Sickle cell trait may

be a risk factor for severe M. pneumoniae infection. The possible underlying mechanism for this relationship is explored, and the relationship between sickle cell trait, cold agglutinins, and the cerebral infarction is discussed.

Mycoplasma pneumoniae usually causes upper respiratory tract symptoms or a mild pneumonia (1), although severe complications (2,3) are occasionally seen. Unusually severe cases have been reported previously in both sickle cell (4) and sickle cell-hemoglobin C disease (5,6). This report describes the clinical course of a patient with sickle cell trait who developed rising complement fixation titers to M. pneumoniae.

Case Report

A 21-year-old black man with Down's syndrome was admitted to Henry Ford Hospital in severe respiratory distress with a one-week history of sore throat, sneezing, and increased respiratory secretions. An older brother had similar symptoms. After admission, the patient developed anorexia, fever, headache, and shortness of breath followed by sudden weakness of his right side. He had no known cardiac disease.

Physical examination revealed an agitated patient in marked respiratory distress. His temperature was 39.5°C, blood pressure 100/80 mm Hg, and pulse 104/minute and regular. Typical stigmata of Down's syndrome were present. The tympanic membranes and the carotid pulses were normal; no bruits were noted. Inspiratory crackles were heard over both lower lung fields anteriorly and posteriorly. There was conjugate deviation of the eyes to the left. His right arm and leg exhibited flaccid hemiparesis,

and the Babinski response was extensor on the right. The remainder of the examination was unremarkable.

A chest radiograph (Fig. 1) revealed diffuse infiltrates in both lung fields. The hemoglobin was 8.3 gm% with no sickle forms noted on peripheral smear. On room air the arterial blood oxygen tension (PaO₂) was 32 mm Hg, arterial blood carbon dioxide (PaCO₂) was 40 mm Hg, and pH 7.32. Gram stain of the yellowish sputum revealed numerous polymorphonuclear leukocytes but no organisms. Cerebrospinal fluid was clear, colorless, and without cells or organisms.

Because of the progressive respiratory failure, the patient required ventilatory support. Pulmonary and femoral arterial catheters were inserted. Positive end expiratory pressure (PEEP) of 10 cm of water was added to help decrease inspired oxygen concentration and venous admixture. The patient received erythromycin (1 gm every 6 hours), nafcillin, and gentamycin, although only the erythromycin was continued after sputum and blood cultures were reported to be negative. A neurology consultant agreed with the diagnosis of a large infarct in the distribution of the left middle cerebral artery.

The cold agglutinin titer was 1:2,048 on day 1 and 1:131,072 on day 11. Complement fixation level for M. pneumoniae was 1:64 on day 1 and 1:512 on day 11. Hemoglobin electrophoresis revealed hemoglobin A at 65.1%, hemoglobin A₂ at 2.6%, and hemoglobin S at 32.3%. The patient was anergic. Serum protein and immunoelectrophoresis showed no immunoglobulin deficiency. Intracerebral hemorrhage, abscess, and subdural hematoma were ruled out because computerized tomography of the brain revealed no abnormality on day 1. An echocardiogram was normal.

The patient's respiratory status stabilized, and he was switched to continuous positive airway pressure (CPAP) on day 6. Progress was slow, and CPAP was required until day 18. Finally, on day 30 the patient was discharged with an expressive aphasia, complete paralysis of the right arm, and minimal weakness of the right leg.

Submitted for publication: November 2, 1979

Accepted for publication: December 14, 1979

* Department of Internal Medicine, Division of Pulmonary Medicine, Henry Ford Hospital

Address reprint requests to Dr. Pensler, Department of Internal Medicine, Henry Ford Hospital, 2799 W Grand Blvd, Detroit, MI 48202

† This paper received the Annual In-Training Manuscript Award.

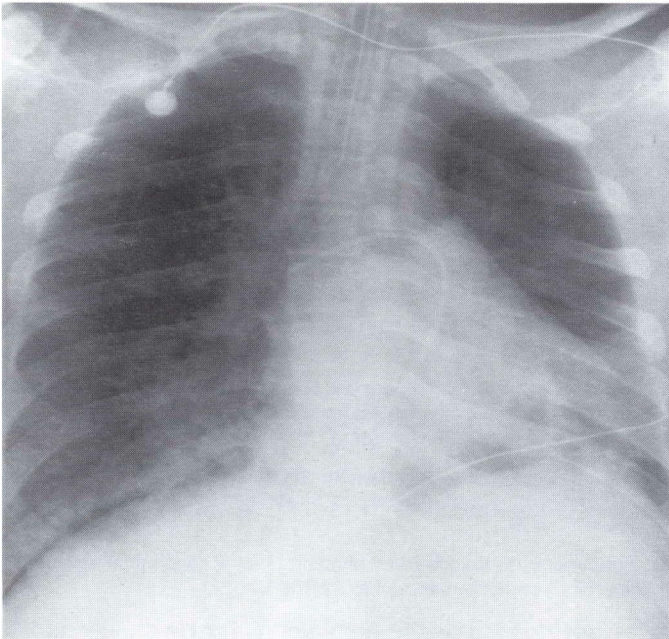


Fig. 1
Chest radiograph on admission revealed diffuse infiltrates.

Discussion

Frequent symptoms in the usual benign case of *Mycoplasma pneumoniae* infection include fever, cough, headache, chills, and malaise. Nasal symptoms and sore throat are seen in approximately half the cases (1). When the lung becomes involved, the radiograph typically reveals unilateral broncho-pneumonia of the lower lobes (3). Patients who are adequately treated improve rapidly with defervescence in one to three days. Our patient presented in this typical fashion, with upper respiratory tract symptoms and a recent family history of a similar illness. However, the onset of the pneumonia was extremely rapid and fulminant, and he developed the adult respiratory distress syndrome (ARDS), which is a rarely reported complication of *M. pneumoniae* infection.

Fishman et al (2) described two cases of ARDS caused by *M. pneumoniae*, but the diagnosis was made retrospectively, and no specific therapy was given. Jastremski (7) reported three cases of ARDS in *M. pneumoniae* infection. One patient died within 24 hours, and the other two needed seven to ten days of PEEP before they recovered. The prolonged requirement for PEEP/CPAP (18 days) in our patient suggests that early administration of erythromycin (started on day 1) does not alter the clinical course of this complication.

M. pneumoniae has been reported to cause unusually severe infections in both sickle cell (4) and sickle cell-hemoglobin C (5, 6) disease. The reason for this relation-

ship is unclear, although complicating pulmonary infarction has been suggested. In situ pulmonary thrombosis has been diagnosed in a patient with sickle cell trait (9), but whether in situ pulmonary thrombosis occurred in our patient and perpetuated the ARDS cannot be proven.

The second feature of interest is the development of cerebral infarction in a patient with sickle cell trait. Sears (8) states that sickle cell trait is a benign disease in which only rare kidney and splenic abnormalities are proven complications. Although he cited case reports of large vessel occlusions involving cerebral and pulmonary arteries, he did not believe an association had been clearly established. Also, there have been no documented cases of hemiplegia in *M. pneumoniae* infection (3). Therefore, the etiology of the cerebral thrombosis in our patient is speculative; however, two explanations seem feasible.

Sickle cell trait erythrocytes have been shown to sickle in vitro when conditions of acidosis and hypoxia exist (14, 15). It is possible that the profound hypoxemia and acidosis secondary to the ARDS induced sickling, with resulting thrombosis in the cerebral circulation. A second possible mechanism involves cold agglutinins which cause a disease of skin capillaries of exposed extremities, resulting in acrocyanosis and Raynaud's phenomenon (13). These alone, however, would not cause large vessel thrombosis. Burchmore (16) documented a case of tibial artery occlusion in a patient with sickle cell-hemoglobin C disease and high levels of cold agglutinins. Thus, some interaction between sickling and cold agglutinins is possible.

Finally, it is doubtful that Down's syndrome had anything to do with the severity of our case, since Down's patients have only mild immunologic deficiencies (10, 11). In fact, there is some indication that immunodeficient states actually lessen the degree of pneumonia in patients with *M. pneumoniae* infection (6, 12). We speculate that the unusually prolonged and severe course of *M. pneumoniae* infection in this patient, with complications of ARDS and cerebral thrombosis, are due to the synergistic effects of hypoxemia, acidosis, high cold agglutinins, and sickle cell trait.

References

1. Purcell RH, Chanock RM. Role of Mycoplasma in human respiratory disease. *Med Clin NA* 1967;51:791.
2. Fishman RA, Marschall KE, Kislak JW, et al. Adult respiratory distress syndrome caused by Mycoplasma pneumoniae. *CHEST* 1978;74:471.
3. Murray HW, Masur H, Senterfit LB, et al. The protean manifestations of Mycoplasma pneumoniae infection in adults. *Am J Med* 1975;58:229.
4. Schulman ST, Bartlett J, Clyde WA, et al. The unusual severity of Mycoplasma pneumonia in children with sickle-cell disease. *N Engl J Med* 1972;287:164.
5. Chusid MJ, Lachman BS, Lazerson J. Severe mycoplasma pneumonia and vesicular eruption in SC hemoglobinopathy. *J Pediatr* 1978;93:449.
6. Solanki DL, Bordoff RL. Severe Mycoplasma pneumonia with pleural effusions in a patient with sickle cell-hemoglobin C (SC) disease. *Am J Med* 1979;66:707.
7. Jastremski MS. Adult respiratory distress syndrome due to Mycoplasma pneumoniae. *CHEST* 1979;75:529.
8. Sears DA. The morbidity of sickle cell trait. *Am J Med* 1978;64:21.
9. Israel RH, Saliponte JS. Pulmonary infarction in sickle cell trait. *Am J Med* 1979;66:867.
10. Steihm ER, Fulginiti VA. Immunologic disorders in infants and children. Philadelphia: WB Saunders, 1973:556.
11. Miller DG. Immunological disturbances in lymphoma and leukemia. In: Somter M, ed. Immunological diseases. Boston: Little, Brown, 1971.
12. Foy HM, Ochs H, Dans SD, et al. Mycoplasma pneumoniae infection in patients with immunodeficiency syndromes: Report of four cases. *J Infect Dis* 1973;127:388.
13. Schuboth H. The cold hemagglutinin disease. *Semin Hematol* 1966;3:27.
14. Lange RD, Minnich V, Moore CV. Effect of oxygen tension and of pH on the sickling and mechanical fragility of erythrocytes with sickle cell anemia and the sickle cell trait. *J Lab Clin Med* 1951;37:789.
15. Barreras L, Diggs LW. Bicarbonate, pH and percentage of sickle cells in venous blood of patients in sickle cell crisis. *Am J Med Sci* 1964;274:710.
16. Burchmore JW, Buckle RM, Lehmann H, et al. Agglutinating-sickling arterial thrombosis. *Lancet* 1962;2:1008.