

Radionuclide Evaluation of Renal Transplant Patients

Daniel S. Marks

Follow this and additional works at: <https://scholarlycommons.henryford.com/hfhmedjournal>



Part of the [Life Sciences Commons](#), [Medical Specialties Commons](#), and the [Public Health Commons](#)

Radionuclide Evaluation of Renal Transplant Patients

Daniel S. Marks, MD*

Radionuclide examinations provide considerable information in evaluating patients who have received renal transplants. In the uncomplicated case, baseline data should be obtained so that subsequent changes in renal function can be better documented. In the complicated case, rapid delineation of the problem may result in more effective therapy. Serial examinations with several radiopharmaceuticals represent the best nuclear approach to the transplant patient. This paper describes the application and performance of these tests as currently performed at Henry Ford Hospital.

POSTOPERATIVELY, many complications face the renal transplant patient. Some, such as rejection and acute tubular necrosis, may be expected but not predicted as to onset or severity. Others, which may be secondary to surgery itself, include the hematomas, urinomas, obstructions, and lymphocoeles. Whatever the potential problems, radionuclide evaluation can play an important role, either to elucidate the complication, or as a complement to other examinations. While other procedures such as arteriography may provide more precise anatomic information, the noninvasive nature of a nuclear examination is advantageous for the patient. Ultrasound is also noninvasive but cannot provide functional data about the transplant. All three modalities, therefore, have their uses in the evaluation and management of the transplant patient. When renal failure occurs, excretory urography is of minimal value and its routine use should be discontinued.

This paper will concern itself with radionuclide methods that can be applied to renal transplants. Ideally, one would hope to clearly separate the various complications from each other, particularly acute tubular necrosis (ATN) and rejection. Practically, however, we are looking only at manifestations of renal blood flow and tubular function, which when correlated with the chronology of the clinical setting, allow us to make reasonable assumptions about the transplant. Moreover, complications may be multiple, occurring either sequentially or concurrently.

Methods

Two radionuclides linked to three radiopharmaceuticals (Tc-99m sulfur colloid, Tc-99m DTPA, and I-131 orthoiodohippuric acid) are used in the routine examination of the transplant patient. Tc-99m is an ideal radionuclide because of its photon energy (140 KeV), which allows for efficient detection, lack of any beta (electron) radiations, and a short half-life of six hours. Iodine-131 suffers from poor imaging energy (364 KeV), significant beta radiations, and an eight-day half-life. For these reasons, I-131 must be used

Submitted for publication: June 30, 1978
Accepted for publication: July 31, 1978

* Department of Diagnostic Radiology, Division of Nuclear Medicine, Henry Ford Hospital

Address reprint requests to Dr. Marks, Department of Diagnostic Radiology, Division of Nuclear Medicine, Henry Ford Hospital, 2799 W Grand Blvd, Detroit, MI 48202

in microcurie doses, although it remains the only widely available radionuclide which can be chemically linked to ortho-hippuric acid. Hopefully, progress with I-123 (almost as ideal an isotope as Tc-99m) will soon provide us with I-123 hippuric acid.

When a request for examination of a transplant patient is received, it is handled as an urgent case, especially in the immediate postoperative period. The first examination should be performed within 24 to 72 hours after implantation. Serial examinations to document improvement or deterioration in renal function are much better than a single examination¹ and are obtained as frequently as the clinical situation dictates. Typically, two or three examinations may be performed at weekly intervals until renal dynamics become stabilized. Except where individualized to fit the particular case, all patients are routinely given the three radiopharmaceuticals in the sequence described below.

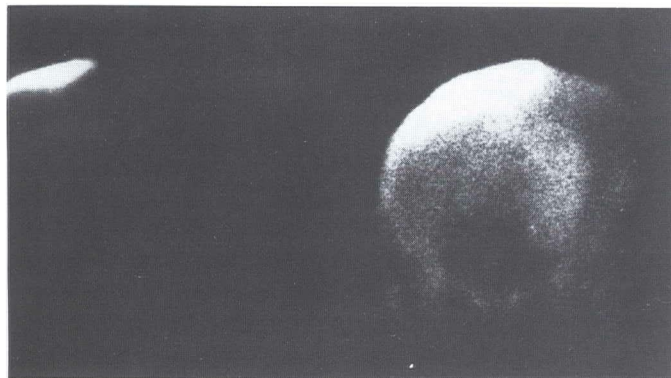


Fig. 1
Tc-99m Sulfur Colloid

Anterior view over pelvis. Note moderate uptake in transplant (top). Two weeks later marked uptake is seen during a rejection episode (bottom).

Tc-99m sulfur colloid

In 1974, Solaric-George, *et al*² first described radiocolloid uptake in renal transplants. Their findings suggested a high degree of correlation in differentiating chronic rejection from other causes of transplant dysfunction. Those patients with chronic rejection showed marked uptake, whereas those with ATN and acute rejection showed little or no uptake.^{3,4,5} In using sulfur colloid to image the liver, spleen, or bone marrow, one depends on the ability of macrophages to trap the colloidal particle. This mechanism is not respon-

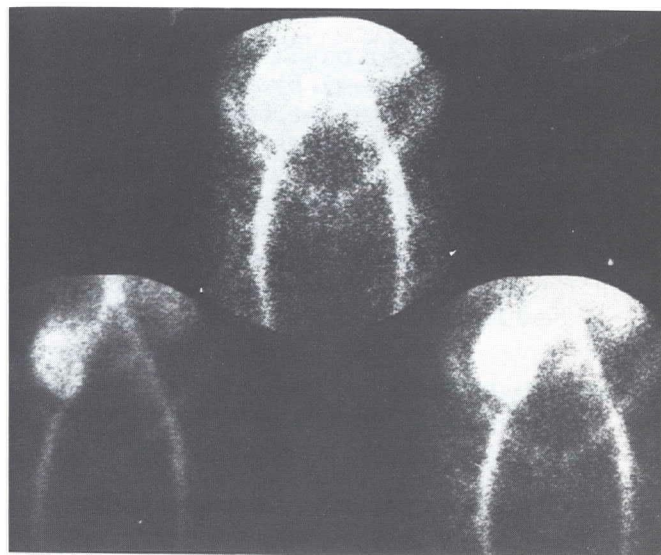

Fig. 2
Tc-99m DTPA

Images obtained from the gamma camera just after IV injection. Note well visualized lower abdominal aorta, transplant, iliac, and femoral vessels.

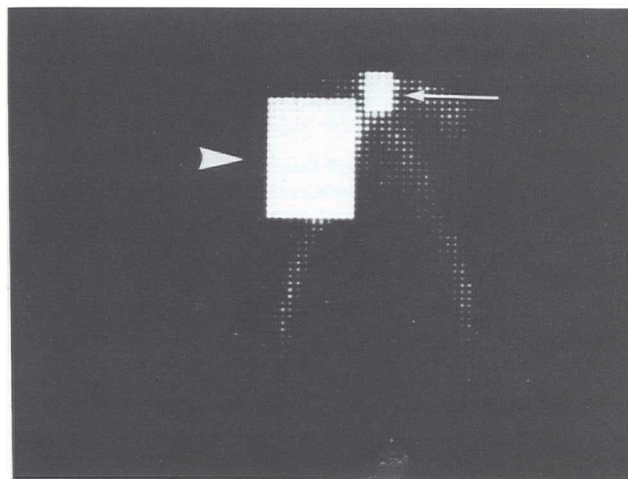


Fig. 3

Computer image from Tc-99m DTPA flow study showing placement of regions-of-interest over distal aorta (small arrow) and transplant (large arrow).




Fig. 4

Computer printout showing determination of aorto-renal transit time by finding the separation between peak arrival time in each area (X = Transplant □ = Aorta).

sible for transplant visualization. Rather, it seems that the particles "stick" to intravascular fibrin deposits which form during rejection. However, Frick, et al⁶ found that while 89% of rejecting transplants showed activity, 30% of those with acute tubular necrosis and 30% of those with sepsis also showed significant activity. In their view, these findings diminish the specificity of colloid uptake as a means of differentiation. It must also be remembered that, for unknown reasons, patients with both right- and left-sided congestive heart failure may show renal radiocolloid uptake.⁷ The frequent coexistence of ATN and rejection also clouds the issue. We hope to evaluate our results with sulfur colloid in a future report. A case demonstrating progression from minimal to marked uptake is shown in Figure 1.

A dose of 5 mCi is administered and the patient imaged 10-20 minutes later. Since most activity is accumulated by liver and spleen, care must be taken to exclude these organs from the field of view, or the bone marrow and transplant will not be visualized for technical reasons. In our experience, most transplants have shown at least some activity. If no activity is seen in the transplant (Figure 5C), one must consider the possibility of vascular occlusion.

Tc-99m DTPA

DTPA is the chemical compound diethylenetriaminepentaacetic acid, which is a chelating agent. Coupled to Tc-99m

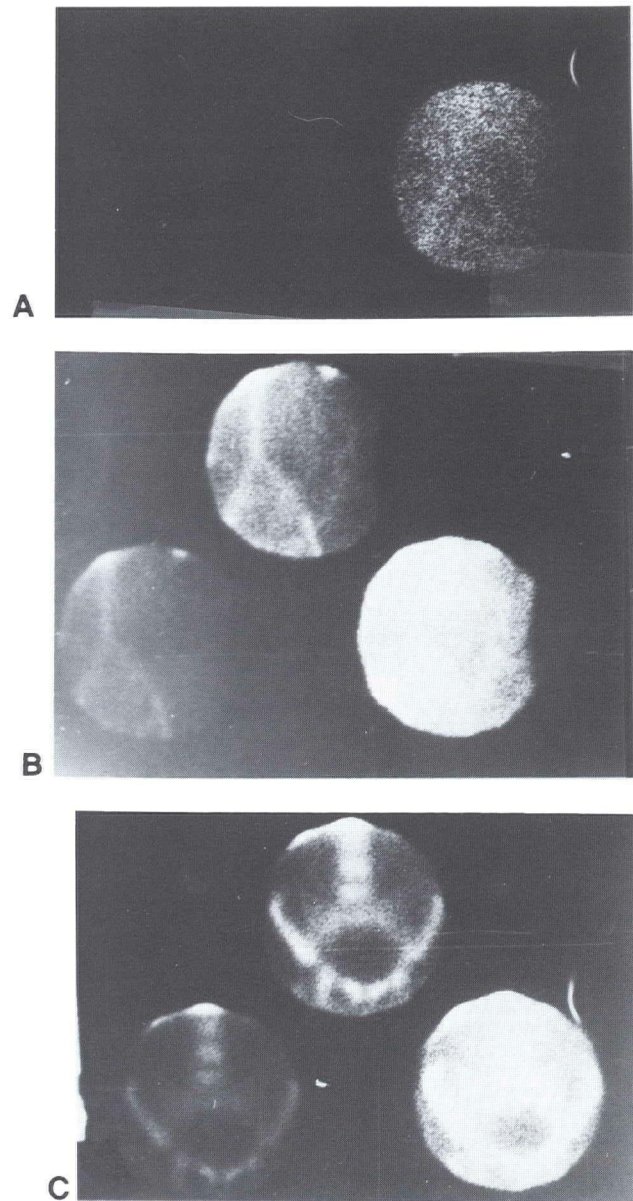


Fig. 5

Nonperfused and nonfunctioning transplant. Note absence of any activity with OIH (A), Tc-99m DTPA (B), or Tc-99m sulfur colloid (C).

via a reducing agent (tin), DTPA is handled in the kidney by glomerular filtration, although only a relatively small fraction is filtered during each circulation through the kidney. The tubules do not play any significant secretory or resorptive role in DTPA excretion. Thus, because there is some renal concentration of DTPA and because of the high photon flux of Tc-99m, we have an excellent compound for evaluating renal perfusion.

Ten to 15 mCi are injected through an antecubital vein as a bolus, while the patient lies beneath the gamma camera

Radionuclide Evaluation of Renal Transplant Patients

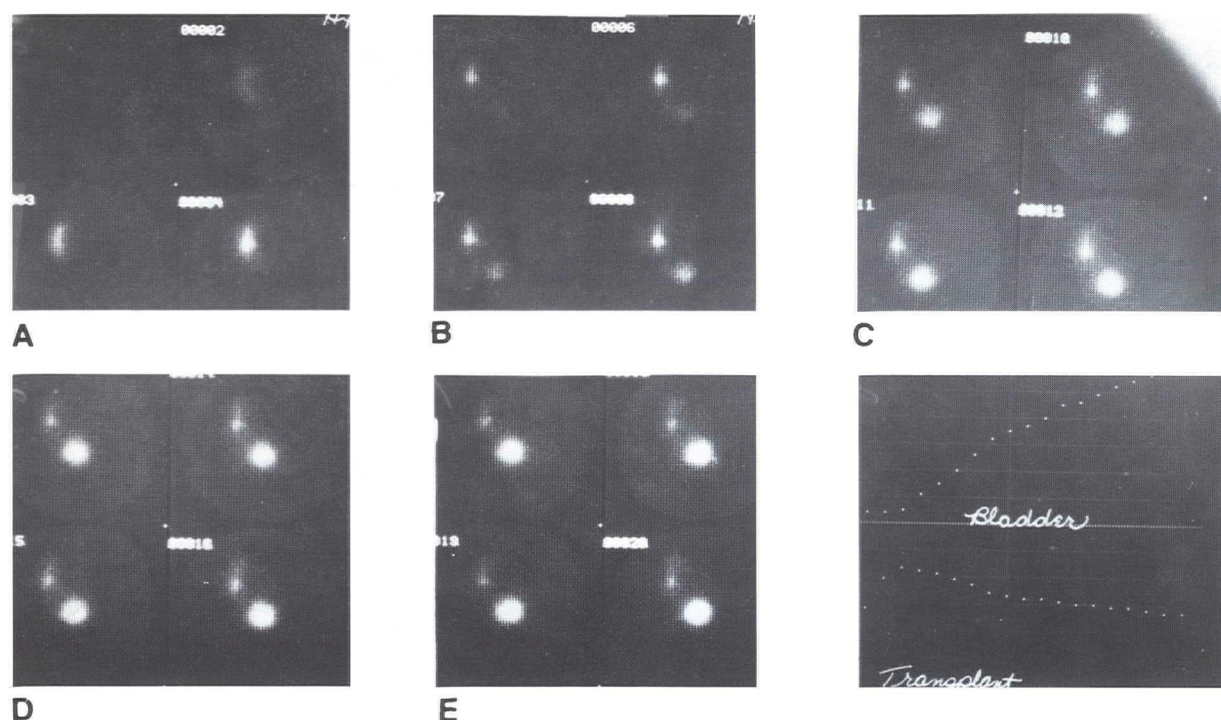


Fig. 8
Computer images (I-131 OIH renogram) demonstrating normal cortical accumulation (A) with rapid progression of activity into collecting system and bladder (B - E).

over each region, which are graphic representations of bolus arrival, peak activity, and equilibration in the aorta and transplant.

The time between peak activity in aorta and in the transplant is the aorto-renal transit time (Figure 4). It provides a more objective measurement of perfusion and is another tool to help differentiate between ATN and rejection.⁹ Normal values are between two to eight seconds. Generally, rejection causes a greater delay in transit time than does ATN, probably because of edema and intravascular fibrin deposition in the transplant. Most cases of ATN are a result of the varying periods of anoxia suffered by cadaver transplants in the donor during harvesting, rather than acute vascular compromise in the recipient. More sophisticated measurements, such as the transplant perfusion index¹⁰ and kidney/aortic blood flow index (K/A ratio),¹¹ have also been described, but their ability to differentiate between ATN and rejection may be no better than the transit time. Complete lack of perfusion (Figure 5B), or marked delay, is an indication for additional study, since one cannot differentiate between the various possible vascular abnormalities with radionuclides. Major occlusions of the renal artery or vein and diffuse intrarenal vascular problems require angiographic diagnosis.

A DTPA image is also obtained after a delay of 30 minutes (post injection). Using this image and those from the early flow study, one can evaluate for space-occupying complications, such as urinoma or hematoma (Figure 6), in addition to looking for possible urinary tract obstruction. In our experience, such problems have been rare, but their presence (or absence) has great importance for patient care.

I-131 ortho-Iodohippuric acid

Ortho-iodohippuric acid (OIH) is a derivative of para-amino hippuric acid (PAH). Both share important physiologic properties, and functional parameters are reflected by the way in which the kidney handles these compounds.

Their first important property is that, in small doses, 90% of the PAH (or OIH) concentration in renal arterial blood is removed in a single circulation,¹² which, for clinical purposes, can be considered a total extraction. When this compound is given as a radioactive bolus, it is thus possible to evaluate renal function as reflected in a single pass phenomenon seen by an external detector. Secondly, since PAH/OIH is handled both by glomerular filtration (20%) and by tubular secretion (80%),¹ it is also possible to view the two basic renal functional compartments during that single circulation. Finally, there is no tubular reabsorption,

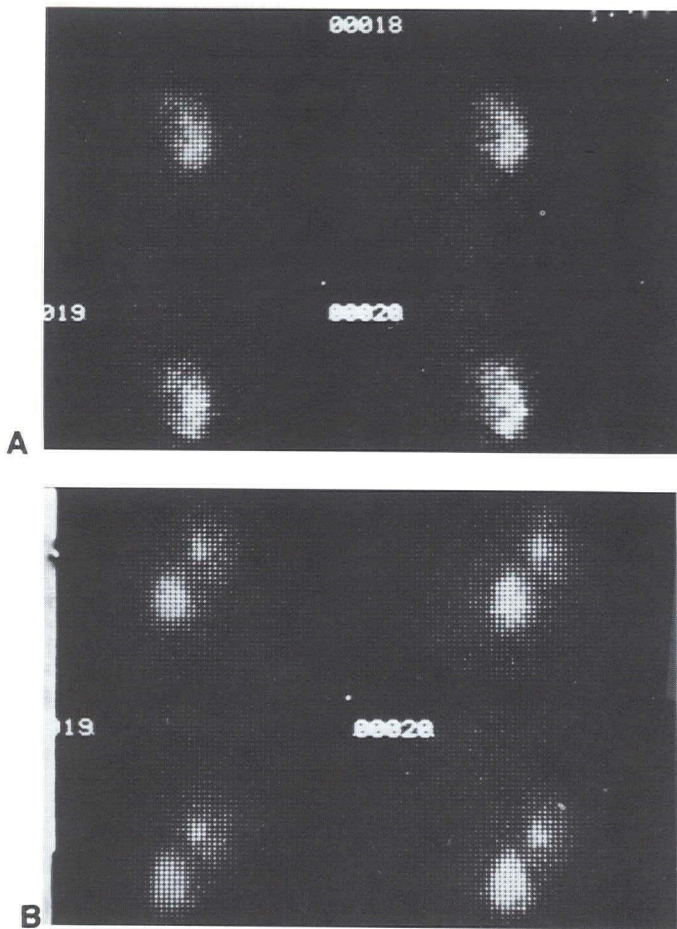


Fig. 9

- A.** Computer images (I-131 OIH) at 17-20 minutes demonstrating delayed retention of activity in renal parenchyma during episode of ATN. No activity seen in collecting system.
- B.** Two weeks later: I-131 OIH computer images at 17-20 minutes now show activity in renal pelvis and bladder indicating resolution.

and PAH/OIH secretion occurs by active transport, which occurs mostly in proximal tubular cells.¹² This last fact has important implications for renal transplants, as will be described later.

With the patient lying beneath the camera detector, a 400 μ Ci (0.4 mCi) bolus of I-131 OIH is injected through an antecubital vein. No images are made during this time, but for the next 20 minutes data are being sent to the computer from which a time-activity curve over both the transplant and bladder will be generated (Figure 7). The renal curve has three phases. The first reflects delivery of isotope to the kidney and its accumulation by the proximal tubular cells. The rate-of-rise of the accumulative phase is a rough estimate of the function of those cells. The second phase, called the peak, represents a very short equilibrium between accumulation and excretion and normally will occur between three to five minutes. The third phase represents

excretion, as the isotope moves down the distal tubules to the collecting system, removing itself from view, until it reappears in the bladder. Naturally, all phases of the curve are interrelated, and abnormality in any one portion may produce an abnormality elsewhere in the curve. For example, a vascular problem will cause delay in delivery of isotope, with subsequent delay in tubular accumulation. Both factors will lead to a delay in appearance-time of the peak and some prolongation of the excretory phase. Relative count-rates over the transplant (compared to background) are generally lower when vascular complications are present. Intra- or extrarenal urinary obstruction also causes a delay in peak time secondary to prolonged and continued accumulation due to nonremoval. Relative count-rates will thus be higher than normal, presuming that renal function has not been significantly reduced. The point to emphasize is that the shape and relative height of the time-activity curves represent effective renal plasma flow, glomerular filtration ratio, proximal tubular function, and tubular urine flow.

In addition to the curves, the computer will reconstruct images that visually interpret the same information used to generate the curves. The 20-minute period of observation will be reconstructed as 20 sequentially-displayed, one-minute images, from which one expects to see normal progression of the radioisotope through the transplant (Figure 8). This consists of initial appearance of activity in the cortical region, movement into the medulla (causing apparent decrease in renal size), and finally, visualization of the renal pelvis and bladder. In ATN there is obstruction to urine flow within distal tubules and collecting ducts probably due to cellular debris. Figure 9 shows prolonged intraparenchymal retention of activity. The proximal tubular cells are more resistant to anoxic damage¹ and their function is relatively preserved. Delivery and accumulation of activity are maintained, unless ATN is secondary to acute vascular obstruction. When rejection predominates, parenchymal retention is also seen but is usually less severe than ATN.

One last note: Patients receiving I-131 OIH should be given a blocking dose of Lugol's solution to reduce radioiodine uptake by the thyroid, and subsequent daily doses should be continued for one to two weeks.

Conclusion

Radionuclides provide a rapid, noninvasive method for evaluating renal transplant patients. Both functional and anatomic information is readily obtained. While the exact differentiation between ATN and rejection remains an elusive goal, the use of multiple radionuclides and serial examinations has made significant inroads towards solving this problem. The accompanying table summarizes the

Radionuclide Evaluation of Renal Transplant Patients

DIFFERENTIATION OF ATN AND REJECTION USING THREE RADIOPHARMACEUTICALS

| RADIONUCLIDE | NORMAL | ATN | REJECTION |
|--------------------------------|---|--|--|
| Tc-99m SULFUR COLLOID | ACTIVITY = NONE - MINIMAL | ACTIVITY = NONE - MODERATE | ACTIVITY = MODERATE - MARKED |
| Tc-99m DTPA (FLOW STUDY) | AORTO - RENAL TRANSIT TIME = 2 - 8 SEC. | MILD - MODERATE PROLONGATION, TRANSIT TIME = 8 - 12 SEC. | MODERATE - MARKED PROLONGATION, TRANSIT TIME = 10 - 16 SEC. |
| | | NO ACTIVITY IN TRANSPLANT = VASCULAR OCCLUSION | |
| I-131 OIH | RAPID ACCUMULATION, NORMAL RADIONUCLIDE PROGRESSION | RAPID - FAIR ACCUMULATION, MARKED PARENCHYMAL RETENTION | POOR ACCUMULATION, MILD PARENCHYMAL RETENTION |

findings in both ATN and rejection, but it should be emphasized that these cannot always be easily categorized, and the table provides only a guideline.

Some authors^{1,3} have also reported on the use of I-125 fibrinogen and Ga-67 in renal transplants. Each of these radionuclides can accumulate in the transplant during rejection. Unfortunately, in the postoperative period (often the most crucial), they may accumulate secondary to the operation itself. In addition, because I-125 also has a photon energy (27 KeV) that is too low to be imaged effectively, one

must rely on counting statistics alone. Further development of I-123¹³ is eagerly awaited, as this will allow for a single study capable of providing functional and anatomic information.

Acknowledgments

I would like to thank Kamilia F. Gitschlag, M.D., Ronald S. Petrocelli, M.D., and Mark F. Pezda, M.D. for their professional criticism and helpful suggestions in writing this paper.

References

1. zum Winkel K, Harbst H, Das KB, and Newiger T: Applications of radionuclides in renal transplantation. *Semin Nucl Med* **4**:169-186, 1974.
2. Solaric-George EA, Fletcher JW, Newton WT, et al: Renal accumulation of Tc-99m sulfur colloid in transplant rejection. *Radiology* **111**:465-466, 1974.
3. George EA, Codd JE, Newton WT, et al: Comparative evaluation of renal transplant rejection with radioiodinated fibrinogen, Tc-99m sulfur colloid, and Ga-67 citrate. *J Nucl Med* **17**:175-180, 1976.
4. George EA, Codd JE, Newton WT, et al: Further evaluation of Tc-99m sulfur colloid accumulation in rejecting renal transplants in man and a canine model. *Radiology* **116**:121-126, 1975.
5. Kim YC, Massari PU, Brown ML, et al: Clinical significance of Tc-99m sulfur colloid accumulation in renal transplant patients. *Radiology* **124**:745-748, 1977.
6. Frick MP, Loken MK, Goldberg ME, and Simmons RL: Use of Tc-99m sulfur colloid in evaluation of renal transplant complications. *J Nucl Med* **17**:181-183, 1976.
7. Higgins CB, Taketa RM, Taylor A, et al: Renal uptake of Tc-99m sulfur colloid. *J Nucl Med* **15**:564-566, 1974.
8. Shimshak RR, Hattner RS, Tucker C, and Salvatierra O: Segmental acute tubular necrosis in kidneys with multiple renal arteries transplanted from living donors. *J Nucl Med* **18**:1074-1078, 1977.
9. Delmonico FL, McKusick KA, Cosimi AB, and Russel PS: Differentiation between renal allograft rejection and acute tubular necrosis by renal scan. *Am J Roentgenol* **128**:625-628, 1977.
10. Hilson AJW, Maisey MN, Ogg CS, et al: Quantitative assessment of renal transplants with Tc-99m DTPA: Experience with 955 cases. *J Nucl Med* **18**:595, 1977.
11. Kirchner PT, Goldman M, Leapman S, and Kiepfner RF: Accuracy of the kidney/aortic blood flow index (K/A ratio) for assessing renal transplant function. *J Nucl Med* **18**:595-596, 1977.
12. Ganong WF: *Review of Medical Physiology*. Los Altos, Calif, Lange Medical Publishers, 1963, pp 524, 530.
13. Zielinski FW, Holly FE, Robinson GD, et al: Total and individual kidney function assessment with Iodine-123 ortho-iodohippurate. *Radiology* **125**:753-759, 1977.