

**Clinical profile and pathogenesis of
idiopathic non-cirrhotic intra-hepatic portal
hypertension (NCIPH)**

Thesis submitted to

The Tamil Nadu Dr. MGR Medical University, Chennai

for the degree of

Doctor of Philosophy

by

Dr. Goel Ashish Anilkumar

Department of Hepatology, Division of Gastrointestinal Sciences

Christian Medical College, Vellore – 632004



January 2018



DEPARTMENT OF HEPATOLOGY

CHRISTIAN MEDICAL COLLEGE

Ida Scudder Road, Vellore -632 004, Tamil Nadu

Dr. C.E.Eapen, MD, DM, DNB (Gastro) – Professor
Dr. Uday George Zachariah, MD, DM (Gastro) – Professor
Dr. Sajith KG. MD, DM (Gastro) – Professor (On Leave)
Dr. Ashish Goel MD, DM (Gastro) –Professor
Dr. Zanwar Shankar Shyam MD., DNB - Assistant Professor

DECLARATION OF THE CANDIDATE

I, **Dr. Goel Ashish Anilkumar**, hereby declare that this thesis entitled '**CLINICAL PROFILE AND PATHOGENESIS OF IDIOPATHIC NONCIRRHOTIC INTRA-HEPATIC PORTAL HYPERTENSION (NCIPH)**' is based on the results of the work carried out by me for the degree of DOCTOR OF PHILOSOPHY under the supervision of **Professor C.E.Eapen**, Head, Department of GI Sciences, Christian Medical College, Vellore. This work has not formed the basis of any associateship, fellowship, degree or diploma of any other university. The thesis was written on the basis of regulations prescribed by The Tamil Nadu Dr. MGR Medical University, Chennai.

Dr. Ashish Goel
PhD Candidate; Department of Hepatology
Christian Medical College, Vellore

Station : Vellore
Date : 27.12.2017



DEPARTMENT OF HEPATOLOGY
CHRISTIAN MEDICAL COLLEGE
Ida Scudder Road, Vellore -632 004, Tamil Nadu

Dr. C.E.Eapen, MD, DM, DNB (Gastro) – Professor
Dr. Uday George Zachariah, MD, DM (Gastro) – Professor
Dr. Sajith KG. MD, DM (Gastro) – Professor (On Leave)
Dr. Ashish Goel MD, DM (Gastro) –Professor
Dr. Zanwar Shankar Shyam MD., DNB - Assistant Professor

CERTIFICATE FROM THE GUIDE

This is to certify that the thesis titled ‘**CLINICAL PROFILE AND PATHOGENESIS OF IDIOPATHIC NONCIRRHOTIC INTRA-HEPATIC PORTAL HYPERTENSION (NCIPH)**’ is based on the results of the work done by **Dr. Goel Ashish Anilkumar** during the period of study under my supervision and guidance. This work has not formed the basis of any associateship, fellowship, degree, diploma or other similar title of any other university.

The candidate has independently reviewed the literature, recruited the patients, conducted the clinical studies, performed the statistical analysis and drafted the relevant manuscripts as part of his thesis. He has written up the work independently.

Dr. C.E.Eapen
Professor; Department of Hepatology
Division of GI Sciences,
Christian Medical College, Vellore

Station : Vellore
Date : 27.12.2017



DEPARTMENT OF HEPATOLOGY
CHRISTIAN MEDICAL COLLEGE
Ida Scudder Road, Vellore -632 004, Tamil Nadu

Dr. C.E.Eapen, MD, DM, DNB (Gastro) – Professor
Dr. Uday George Zachariah, MD, DM (Gastro) – Professor
Dr. Sajith KG. MD, DM (Gastro) – Professor (On Leave)
Dr. Ashish Goel MD, DM (Gastro) –Professor
Dr. Zanwar Shankar Shyam MD., DNB - Assistant Professor

CERTIFICATE FROM THE CO-GUIDE

This is to certify that the thesis titled ‘**CLINICAL PROFILE AND PATHOGENESIS OF IDIOPATHIC NONCIRRHOTIC INTRA-HEPATIC PORTAL HYPERTENSION (NCIPH)**’ is based on the results of the work done by **Dr. Goel Ashish Anilkumar** during the period of study under my supervision and guidance. This work has not formed the basis of any associateship, fellowship, degree, diploma or other similar title of any other university.

The candidate has independently reviewed the literature, recruited the patients, conducted the clinical studies, performed the statistical analysis and drafted the relevant manuscripts as part of his thesis. He has written up the work independently.

Dr. Uday Zachariah
Professor; Department of Hepatology
Christian Medical College, Vellore

Station : Vellore
Date : 27.12.2017



DEPARTMENT OF HEPATOLOGY
CHRISTIAN MEDICAL COLLEGE
Ida Scudder Road, Vellore -632 004, Tamil Nadu

Dr. C.E.Eapen, MD, DM, DNB (Gastro) – Professor
Dr. Uday George Zachariah, MD, DM (Gastro) – Professor
Dr. Sajith KG. MD, DM (Gastro) – Professor (On Leave)
Dr. Ashish Goel MD, DM (Gastro) –Professor
Dr. Zanwar Shankar Shyam MD., DNB - Assistant Professor

PLAGIARISM CERTIFICATE

This is to certify that this dissertation work titled ‘**CLINICAL PROFILE AND PATHOGENESIS OF IDIOPATHIC NONCIRRHOTIC INTRA-HEPATIC PORTAL HYPERTENSION (NCIPH)**’ of the candidate **Dr. Goel Ashish Anilkumar** with registration Number **141410003 (Ref No. Ex.II(5)/57651/2013** for the award of **Doctor of Philosophy** in the branch of Hepatology. I personally verified the urkund.com website for the purpose of plagiarism Check. I found that the uploaded thesis file contains from introduction to conclusion pages and result shows **0% (zero percentage)** of plagiarism in the dissertation.

Guide & Supervisor sign with Seal.




DEPARTMENT OF HEPATOLOGY
CHRISTIAN MEDICAL COLLEGE
Ida Scudder Road, Vellore -632 004, Tamil Nadu

Dr. C.E.Eapen, MD, DM, DNB (Gastro) – Professor
Dr. Uday George Zachariah, MD, DM (Gastro) – Professor
Dr. Sajith KG. MD, DM (Gastro) – Professor (On Leave)
Dr. Ashish Goel MD, DM (Gastro) –Professor
Dr. Zanwar Shankar Shyam MD., DNB - Assistant Professor

CERTIFICATE FROM THE GUIDE

This is to certify that the thesis titled '**CLINICAL PROFILE AND PATHOGENESIS OF IDIOPATHIC NONCIRRHOTIC INTRA-HEPATIC PORTAL HYPERTENSION (NCIPH)**' is based on the results of the work done by **Dr. Goel Ashish Anilkumar** during the period of study under my supervision and guidance. This work has not formed the basis of any associateship, fellowship, degree, diploma or other similar title of any other university.

The candidate has independently reviewed the literature, recruited the patients, conducted the clinical studies, performed the statistical analysis and drafted the relevant manuscripts as part of his thesis. He has written up the work independently.


Dr. C.E. Eapen
Professor; Department of Hepatology
Division of GI Sciences,
Christian Medical College, Vellore



Station : Vellore
Date : 27.12.2017



DEPARTMENT OF HEPATOLOGY

CHRISTIAN MEDICAL COLLEGE

Ida Scudder Road, Vellore -632 004, Tamil Nadu

Dr. C.E.Eapen, MD, DM, DNB (Gastro) – Professor
Dr. Uday George Zachariah, MD, DM (Gastro) – Professor
Dr. Sajith KG. MD, DM (Gastro) – Professor (On Leave)
Dr. Ashish Goel MD, DM (Gastro) –Professor
Dr. Zanwar Shankar Shyam MD., DNB - Assistant Professor

PLAGIARISM CERTIFICATE

This is to certify that this dissertation work titled '**CLINICAL PROFILE AND PATHOGENESIS OF IDIOPATHIC NONCIRRHOTIC INTRA-HEPATIC PORTAL HYPERTENSION (NCIPH)**' of the candidate **Dr. Goel Ashish Anilkumar** with registration Number **141410003 (Ref No. Ex.II(5)/57651/2013** for the award of **Doctor of Philosophy** in the branch of Hepatology. I personally verified the urkund.com website for the purpose of plagiarism Check. I found that the uploaded thesis file contains from introduction to conclusion pages and result shows **0% (zero percentage)** of plagiarism in the dissertation.

Eap

Guide & Supervisor sign with Seal.

29 DECEMBER 2017



Tel: 0416 – 2282496/ 2148 Fax : 0416 -2232035,2232103

E- mail: hepatology@cmcvellore.ac.in/ liverresearch@cmcvellore.ac.in

Out Patient OPD (600B – Liver Clinic) - : Liver Clinic – Monday & Thursday – 8am to 4pm
Liver Transplant Clinic - Saturday – 9am to 11am



DEPARTMENT OF HEPATOLOGY
CHRISTIAN MEDICAL COLLEGE
Ida Scudder Road, Vellore -632 004, Tamil Nadu

Dr. C.E.Eapen, MD, DM, DNB (Gastro) – Professor
Dr. Uday George Zachariah, MD, DM (Gastro) – Professor
Dr. Sajith KG. MD, DM (Gastro) – Professor (On Leave)
Dr. Ashish Goel MD, DM (Gastro) –Professor
Dr. Zanwar Shankar Shyam MD., DNB - Assistant Professor

CERTIFICATE FROM THE CO-GUIDE

This is to certify that the thesis titled '**CLINICAL PROFILE AND PATHOGENESIS OF IDIOPATHIC NONCIRRHOTIC INTRA-HEPATIC PORTAL HYPERTENSION (NCIPH)**' is based on the results of the work done by **Dr. Goel Ashish Anilkumar** during the period of study under my supervision and guidance. This work has not formed the basis of any associateship, fellowship, degree, diploma or other similar title of any other university.

The candidate has independently reviewed the literature, recruited the patients, conducted the clinical studies, performed the statistical analysis and drafted the relevant manuscripts as part of his thesis. He has written up the work independently.

Dr. Uday Zachariah
Professor; Department of Hepatology
Christian Medical College, Vellore

Station : Vellore
Date : 27.12.2017





DEPARTMENT OF HEPATOLOGY
CHRISTIAN MEDICAL COLLEGE
Ida Scudder Road, Vellore -632 004, Tamil Nadu

Dr. C.E.Eapen, MD, DM, DNB (Gastro) – Professor
Dr. Uday George Zachariah, MD, DM (Gastro) – Professor
Dr. Sajith KG. MD, DM (Gastro) – Professor (On Leave)
Dr. Ashish Goel MD, DM (Gastro) –Professor
Dr. Zanwar Shankar Shyam MD., DNB - Assistant Professor

DECLARATION OF THE CANDIDATE

I, **Dr. Goel Ashish Anilkumar**, hereby declare that this thesis entitled '**CLINICAL PROFILE AND PATHOGENESIS OF IDIOPATHIC NONCIRRHOTIC INTRA-HEPATIC PORTAL HYPERTENSION (NCIPH)**' is based on the results of the work carried out by me for the degree of DOCTOR OF PHILOSOPHY under the supervision of **Professor C.E.Eapen**, Head, Department of GI Sciences, Christian Medical College, Vellore. This work has not formed the basis of any associateship, fellowship, degree or diploma of any other university. The thesis was written on the basis of regulations prescribed by The Tamil Nadu Dr. MGR Medical University, Chennai.

Dr. Ashish Goel
PhD Candidate; Department of Hepatology
Christian Medical College, Vellore



Station : Vellore
Date : 27.12.2017

Urkund Analysis Result

Analysed Document: PhD Thesis 23122017 (for plagiarism 1).docx (D34230204)
Submitted: 12/28/2017 1:29:00 PM
Submitted By: drashishgoel@cmcvellore.ac.in
Significance: 0 %

Sources included in the report:

Instances where selected sources appear:

0



New file
Ph.D.

**OFFICE OF RESEARCH
INSTITUTIONAL REVIEW BOARD (IRB)
CHRISTIAN MEDICAL COLLEGE, VELLORE, INDIA.**

Ethics Committee Registration No : ECR/326/INST/TN/2013 issued under Rule 122D of the Drugs & Cosmetics Rules 1945, Govt. Of India.

Dr. George Thomas, D Ortho., Ph.D.,
Chairperson, Ethics Committee

Dr. Alfred Job Daniel, D Ortho, MS Ortho, DNB Ortho
Chairperson, Research Committee & Principal

Dr. B. Antonisamy, M.Sc., Ph.D., FSMS, FRSS.,
Secretary, Research Committee

Dr. Nihal Thomas,
MD., MNAMS., DNB (Endo), FRACP (Endo), FRCP (Glas) (EDIN)
Deputy Chairperson
Secretary, Ethics Committee, IRB
Additional Vice Principal (Research)

Prof. Keith Gomez, B.Sc., M.A (S.W), M.Phil.,
Deputy Chairperson, Ethics Committee

November 13th 2013

Dr. Ashish Goel
Associate Professor
Department of Hepatology
Christian Medical College
Vellore 632 002

Sub: **Fluid Research grant project: (PhD Proposal)**

Clinical profile and pathogenesis of idiopathic noncirrhotic intra-hepatic portal hypertension (NCIPH)

Dr. Ashish Goel, Associate Professor, Hepatology, Dr. C. E. Eapen, Dr. Uday Zachariah, Hepatology, Dr. Anup Ramachandran, Wellcome Research Unit, Gastrointestinal Sciences.

Ref: IRB Min. No 8500 [OBSERVE] dated 30.10.2013

Dear Dr. Ashish Goel,

The Institutional Review Board (Blue, Research and Ethics Committee) of the Christian Medical College, Vellore, reviewed and discussed your project titled "Clinical profile and pathogenesis of idiopathic noncirrhotic intra-hepatic portal hypertension (NCIPH)." on October 30th 2013.

The Committee reviewed the following documents:

1. IRB application format
2. Curriculum Vitae' of Drs. Ashish Goel, C. E. Eapen, Uday Zachariah, Anup Ramachandran.
3. Patient Consent form (English Tamil, Bengali & Hindi)
4. No of documents 1-3

1 of 4



**OFFICE OF RESEARCH
INSTITUTIONAL REVIEW BOARD (IRB)
CHRISTIAN MEDICAL COLLEGE, VELLORE, INDIA.**

Ethics Committee Registration No : ECR/326/INST/TN/2013 issued under Rule 122D of the Drugs & Cosmetics Rules 1945, Govt. Of India.

Dr. George Thomas, D Ortho., Ph.D.,
Chairperson, Ethics Committee

Dr. Alfred Job Daniel, D Ortho, MS Ortho, DNB Ortho
Chairperson, Research Committee & Principal

Dr. B. Antonisamy, M.Sc., Ph.D., FSMS, FRSS.,
Secretary, Research Committee

Dr. Nihal Thomas,
MD., MNAMS., DNB (Endo), FRACP (Endo), FRCP (Glas) (EDIN)
Deputy Chairperson
Secretary, Ethics Committee, IRB
Additional Vice Principal (Research)

Prof. Keith Gomez, B.Sc., M.A (S.W), M.Phil.,
Deputy Chairperson, Ethics Committee

The following Institutional Review Board (Research & Ethics Committee) members were present at the meeting held on September 25, 2013 at 9.45 am in the CREST/SACN Conference Room, Christian Medical College, Bagayam, Vellore 632002.

Name	Qualification	Designation	Other Affiliations
Dr. George Thomas	MBBS, D Ortho, PhD	Orthopaedic Surgeon, St. Isabella Hospital, Chennai, Chairperson, Ethics Committee, IRB.	External, Clinician
Dr. B. Poonkuzhali	MSC, PhD	Professor, Haematology, CMCH.	Internal, Basic Medical Scientist
Dr. Asha Mary Abraham	MBBS, MD, PhD	Professor, Virology, CMCH.	Internal, Clinician
Dr. Molly Jacob	MBBS, MD, PhD	Professor, Biochemistry, CMCH.	Internal, Clinician
Dr. B.S. Ramakrishna	MBBS, MD, DM, PhD, FAMS, FA Sc, AGAF, FNA	Retired Professor, Vellore	External, Clinician
Dr. Anuradha Bose	MBBS, DCH, MD, MRCP, FRCPC	Professor, Child Health, CMCH.	Internal, Clinician
Dr. Biju George	MBBS, MD, DM	Professor, Haematology, CMCH.	Internal, Clinician
Dr. Vinod Joseph Abraham	MBBS, MD, MPH	Professor, Community Medicine, CMCH.	Internal, Clinician
Dr. Sukriya Nayak	MBBS, MS	Professor, General Surgery, CMCH	Internal, Clinician

2 of 4



**OFFICE OF RESEARCH
INSTITUTIONAL REVIEW BOARD (IRB)
CHRISTIAN MEDICAL COLLEGE, VELLORE, INDIA.**

Ethics Committee Registration No : ECR/326/INST/TN/2013 issued under Rule 122D of the Drugs & Cosmetics Rules 1945, Govt. Of India.

Dr. George Thomas, D Ortho., Ph.D.,
Chairperson, Ethics Committee

Dr. Alfred Job Daniel, D Ortho, MS Ortho, DNB Ortho
Chairperson, Research Committee & Principal

Dr. B. Antonisamy, M.Sc., Ph.D., FSMS, FRSS.,
Secretary, Research Committee

Dr. Nihal Thomas,
MD., MNAMS., DNB (Endo), FRACP (Endo), FRCP (Glas) (EDIN)
Deputy Chairperson
Secretary, Ethics Committee, IRB
Additional Vice Principal (Research)

Prof. Keith Gomez, B.Sc., M.A (S.W), M.Phil.,
Deputy Chairperson, Ethics Committee

Dr. Deepak Abraham	MBBS, MS	Professor, Endocrine Surgery, CMCH.	Internal, Clinician
Rev. Dr. T. Arul Dhas	M.Sc, BD, DPC, PhD(Edin)	Chaplaincy Department, CMCH.	Internal, Social Scientist
Dr. Suresh Devasahayam	BE, MS, PhD	Professor of Bio-Engineering, CMCH.	Internal, Basic Medical Scientist
Dr. Binu Susan Mathew	MBBS, MD	Associate Professor, Clinical Pharmacology CMCH.	Internal, Pharmacologist
Mrs. Mary Johnson	M.Sc	Professor, Child Health Nursing	Internal, Nurse
Dr. B. Antonisamy	M.Sc, PhD, FSMS, FRSS	Professor, Biostatistics, CMCH, Member Secretary, Research Committee, IRB.	Internal, Statistician
Prof. Keith Gomez	BSc, MA (S.W), M. Phil (Psychiatry Social Work)	Student counselor, Loyola College, Chennai, Deputy Chairperson, Ethics Committee, IRB	External, Lay Person & Social Scientist
Mrs. Pattabiraman	B. Sc, DSSA	Social Worker, Vellore	External, Lay person
Mr. C. Sampath	B. Sc, BL	Legal Expert, Vellore	External, Legal Expert
Mrs. Selva Titus Chacko	M.Sc	Professor, Medical Surgical Nursing, CMCH.	Internal, Nurse
Dr. P. Zachariah	MBBS, PhD	Retired Professor, Vellore	External, Scientist

3 of 4



**OFFICE OF RESEARCH
INSTITUTIONAL REVIEW BOARD (IRB)
CHRISTIAN MEDICAL COLLEGE, VELLORE, INDIA.**

Ethics Committee Registration No : ECR/326/INST/TN/2013 issued under Rule 122D of the Drugs & Cosmetics Rules 1945, Govt. Of India.

Dr. George Thomas, D Ortho., Ph.D.,
Chairperson, Ethics Committee

Dr. Alfred Job Daniel, D Ortho, MS Ortho, DNB Ortho
Chairperson, Research Committee & Principal

Dr. B. Antonisamy, M.Sc., Ph.D., FSMS, FRSS.,
Secretary, Research Committee

Dr. Nihal Thomas,
MD., MNAMS., DNB (Endo), FRACP (Endo), FRCP (Glas) (EDIN)
Deputy Chairperson
Secretary, Ethics Committee, IRB
Additional Vice Principal (Research)

Prof. Keith Gomez, B.Sc., M.A (S.W), M.Phil.,
Deputy Chairperson, Ethics Committee

Mr. Samuel Abraham	MA, PGDBA, PGDPM, M. Phil, BL.	Sr. Legal Officer, CMCH.	Internal, Legal Expert
Dr. Jayaprakash Muliyl	B. Sc, MBBS, MD, MPH, Dr PH (Epid), DMHC	Retired Professor, Vellore	External, Scientist & Epidemiologist
Dr. Nihal Thomas	MD MNAMS DNB(Endo) FRACP(Endo) FRCP(Edin) FRCP (Glasg)	Secretary IRB (EC)& Dy. Chairperson (IRB), Professor of Endocrinology & Addl. Vice Principal (Research), CMC.	Internal, Clinician

We approve the project to be conducted as presented.

The Institutional Ethics Committee expects to be informed about the progress of the project, any **adverse events** occurring in the course of the project, any **amendments in the protocol and the patient information / informed consent**. On completion of the study you are expected to submit a copy of the **final report**. Respective forms can be downloaded from the following link: [http://172.16.11.136/Research/IRB Polices.html](http://172.16.11.136/Research/IRB%20Polices.html) in the CMC Intranet and in the CMC website link address: <http://www.cmch-vellore.edu/static/research/Index.html>.

Yours sincerely

Dr. B. Antonisamy
Secretary (Research Committee)
Institutional Review Board
SECRETARY,
Institutional Review Board
(Research Committee)
Christian Medical College,
Vellore - 632 002. Tamil Nadu. India.

4 of 4

ACKNOWLEDGEMENTS

I wish to acknowledge the contributions of various people during the conduct of this thesis :

Dr. CE Eapen (guide) : For his constant support and words of wisdom/ encouragement.

Dr. Uday Zachariah (co-guide) : For his constant support.

Dr. Elwyn Elias (Professor Emeritus, Department of Hepatology, Queen's Hospital Birmingham, UK) : For being a constant mentor and support.

My Collaborators :

- *Department of Pathology, Christian Medical College, Vellore :*
 - Dr. Banumathi Ramakrishna
 - Dr. Anna Pulimood
 - Dr. Deepak Burad
 - Dr. Thomas Alex
- *Wellcome Research Unit, Division of GI Sciences, CMC*
 - Dr. K.A. Balasubramanian
 - Dr. Anup Ramachandran
 - Dr. G. Jayakumar
- *Department of Radiology, CMC*
 - Dr. Shyam kumar
 - Dr. Vinu Moses
- *Department of Clinical Biochemistry, CMC*
 - Dr. Pamela Christudoss
 - Dr. Joe Fleming
- *Department of Transfusion Medicine, CMC*

- Dr. Sukesh C. Nair
- ***Overseas collaborators***
 - Dr. Ian Mackie (Department of Hematology, University College London, London, UK)

I wish to thank my **patients and colleagues** for support and trust.

I wish to acknowledge the financial support for conduct of the various studies involved in the thesis :

Funding agencies

1. Science and Education Research Board, Government of India
2. Fluid Research Fund, Christian Medical College, Vellore

LIST OF ABBREVIATIONS

- NCIPH : Idiopathic non-cirrhotic intra-hepatic portal hypertension
- V-WF : von-Willebrand factor
- ADAMTS-13 : a disintegrin and matrix metalloprotease with thrombospondin- type 1 motifs member 13
- IHPVO: intra-hepatic portal vein obstruction
- NRH : Nodular regenerative hyperplasia
- CVID : Common variable immunodeficiency
- HPS: Hepato-pulmonary syndrome
- PPH: Porto-pulmonary hypertension
- TIPSS: Trans-jugular intra-hepatic portosystemic shunt
- TJLB: Transjugular liver biopsy
- HBsAg : Hepatitis B surface antigen
- HCV: Hepatitis C Virus
- IQR: Intra-quartile range
- HVPG: Hepatic venous pressure gradient
- MELD: Model for end-stage liver disease
- US : Ultra-sound
- PVT : Portal vein thrombosis
- CBA: Collagen binding assay
- FRET : Fluorescence Resonance Transfer
- Ag: Antigen
- CLD : Chronic liver disease
- AMA : Anti-mitochondrial antibody
- ANA: Anti-nuclear antibody

- SLA: Antibody to Soluble liver antigen
- Anti-LKM: Anti liver kidney microsome antibody
- tTG: Tissue transglutaminase
- CD: Coeliac disease
- D2Bx : Duodenal biopsy
- IEL : Intra-epithelial lymphocytes
- L/M ratio: Lactulose/Mannitol ratio
- APRI: aspartate amino-transferase to platelet ratio index
- WHO : World Health Organisation

Table of Contents

S No.	Title	Page No.
1	Introduction	1
2	Objectives	5
3	Review of Literature	7
4	Objective 1 : To study the clinical profile, natural history and prognostic factors of patients with NCIPH	26
4.1	<i>Patients and Methods</i>	27
4.2	<i>Results</i>	31
4.3	<i>Analysis and discussion</i>	43
5	Objective 2 : To explore pathogenic mechanisms involved in NCIPH	49
5.1	<i>Patients and Methods</i>	51
5.2	<i>Results</i>	56
5.3	<i>Analysis and Discussion</i>	68
6	Objective 3 : To study the associated disorders in patients with NCIPH (Gut)	74
6.1	<i>Patients and Methods</i>	76
6.2	<i>Results</i>	82
6.3	<i>Analysis and Discussion</i>	92
7	Objective 3b : To study the associated disorders in patients with NCIPH (Others)	95
7.1	<i>Patients and Methods</i>	97
7.2	<i>Results</i>	101
7.3	<i>Analysis and Discussion</i>	114
8	Overall Summary and Conclusion	118
9	Implications for future research	119
10	Bibliography	
11	List of publications and abstracts	

Clinical profile and pathogenesis of idiopathic non-cirrhotic intra-hepatic portal hypertension (NCIPH)

Introduction

Idiopathic non-cirrhotic intra-hepatic portal hypertension (NCIPH) is a disorder characterised by occlusion of small intra-hepatic portal venous radicles (3rd/ 4th order branches). It is thus a cause of pre-sinusoidal intra-hepatic portal hypertension. NCIPH is clinically characterised by portal hypertension (gastro-oesophageal varices and subsequent bleeding), hypersplenism (low blood counts secondary to peripheral destruction) and liver functions that deteriorate, albeit much later in comparison to cirrhosis^{1, 2}. A proportion of NCIPH patients develop liver failure and require liver transplant. Even the explant liver at the time of transplant grossly gives the appearance of cirrhosis¹.

Thus, NCIPH can mimic cirrhosis in all respects and the diagnosis at present is dependent on presence of cryptogenic intra-hepatic portal hypertension with absence of advanced fibrosis in liver biopsy. The diagnostic criteria is briefly described³

1. Portal hypertension – evidenced by presence of gastro-oesophageal varices on upper gastrointestinal endoscopy
2. Patent portal vein (inflow) and hepatic venous outflow tract

3. Absence of known aetiology of chronic liver disease – e.g. Hepatitis B/ C virus, alcohol intake etc.
4. Absence of cirrhosis or advanced fibrosis (bridging fibrosis) on liver biopsy
5. Absence of any aetiology known to cause portal venous lesions similar to NCIPH – e.g. sarcoidosis, congenital hepatic fibrosis etc.

NCIPH is known by various terminologies all over the world – idiopathic portal hypertension (In Japan), non-cirrhotic portal fibrosis (In India), nodular regenerative hyperplasia, incomplete septal cirrhosis, hepato-portal sclerosis, partial nodular transformation and benign intra-hepatic portal hypertension¹.

Pathogenesis – Hypothesis (Figure 1):

Initial description of NCIPH has been from India⁴⁻⁷, and the largest series describing the condition also have been from this country⁸⁻¹¹. NCIPH still remains prevalent in India and other developing nations and also has been termed as an ‘Indian’ disease¹². In contrast, it is an extremely rare cause of portal hypertension in the developed world. Genetic predisposition or shared environmental exposure may explain the increased prevalence of NCIPH in Indian context. As the disease in India is rarely segregated into families, we feel NCIPH is a complex disease with a possible combined role of genetic predisposition and environmental risk factor triggering the disease manifestations.

The pathogenesis of NCIPH remains unclear and various hypotheses are being explored. As the disease is confined to portal venous inflow, the role of gut and gut derived toxins was

explored in this research work. The blood from gut is filtered in the liver, thus exposing the liver inflow to maximum concentrations of gut derived toxins.

Being a portal venous micro-angiopathy, we also hypothesised the role of v-WF-ADAMTS-13 imbalance in pathogenesis of NCIPH. v-WF (Von-Willebrand factor) is a protein expressed on endothelial cell which provides scaffold for platelet plug formation. ADAMTS-13 (a disintegrin and matrix metalloprotease with thrombospondin- type 1 motifs member 13) is a v-WF-cleaving protease. Low ADAMTS-13 increases v-WF ultra-large multimers, leading to extensive platelet plug formations and thrombotic micro-angiopathy syndromes e.g. thrombotic thrombocytopenic purpura.

In this research thesis, we attempted to explore various aspects of this hypothesis. We studied v-WF-ADAMTS-13 balance in patients with NCIPH and compared these with disease and healthy controls. We also assessed the presence of gut inflammation, coeliac disease, gut derived toxins (e.g. Arsenic) and other associated disorders in patients with NCIPH.

Epidemiology :

Though NCIPH is thought to be declining in India, we have shown in both retrospective and prospective studies that NCIPH is still a persistent problem¹³⁻¹⁵. Little is known of the natural history and progression of the disease, at least in Indian context. In this thesis, we also aim to describe the varied clinical presentation and elucidate the natural course of disease as prevalent in India.

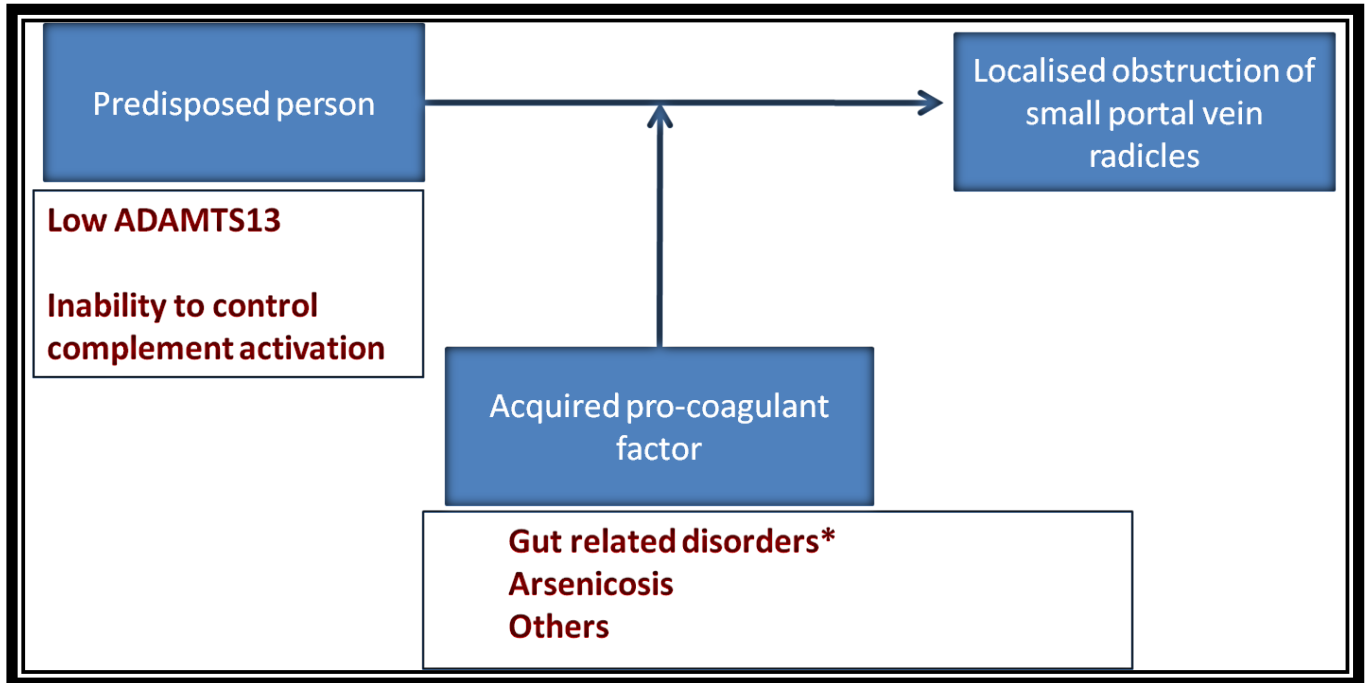


Figure 1: Hypothesis for pathogenesis of NCIPH

Objectives

AIM

The studies will explore the natural history and pathogenesis of idiopathic non-cirrhotic intra-hepatic portal hypertension (NCIPH). We also plan to study the associated disorders in patients with NCIPH.

Case definition of NCIPH : For all the studies, diagnosis of NCIPH will be based on the following published criteria :

1. Portal hypertension – evidenced by gastro-oesophageal varices on upper gastrointestinal endoscopy
2. Patent portal vein (inflow) and hepatic venous outflow tract on Doppler of the intra-abdominal vessels
3. Absence of known aetiology of chronic liver disease – e.g. Hepatitis B/ C virus, alcohol intake etc.
4. Absence of cirrhosis or advanced fibrosis (bridging fibrosis) on liver biopsy
5. Absence of any aetiology known to cause portal venous lesions similar to NCIPH – e.g. sarcoidosis, congenital hepatic fibrosis etc.

SPECIFIC OBJECTIVES

- Objective 1. To study the clinical profile, natural history and prognostic factors of patients with NCIPH
- Objective 2. To explore pathogenic mechanisms involved in NCIPH
- Objective 3. To study the associated disorders in patients with NCIPH

Review of Literature

DEFINITION :

Portal hypertension can be classified based on the level of obstruction to flow. Figure 2 depicts the classification and the major causes of portal hypertension in each class. Idiopathic non-cirrhotic intra-hepatic portal hypertension (NCIPH) is classified as intra-hepatic pre-sinusoidal portal hypertension.

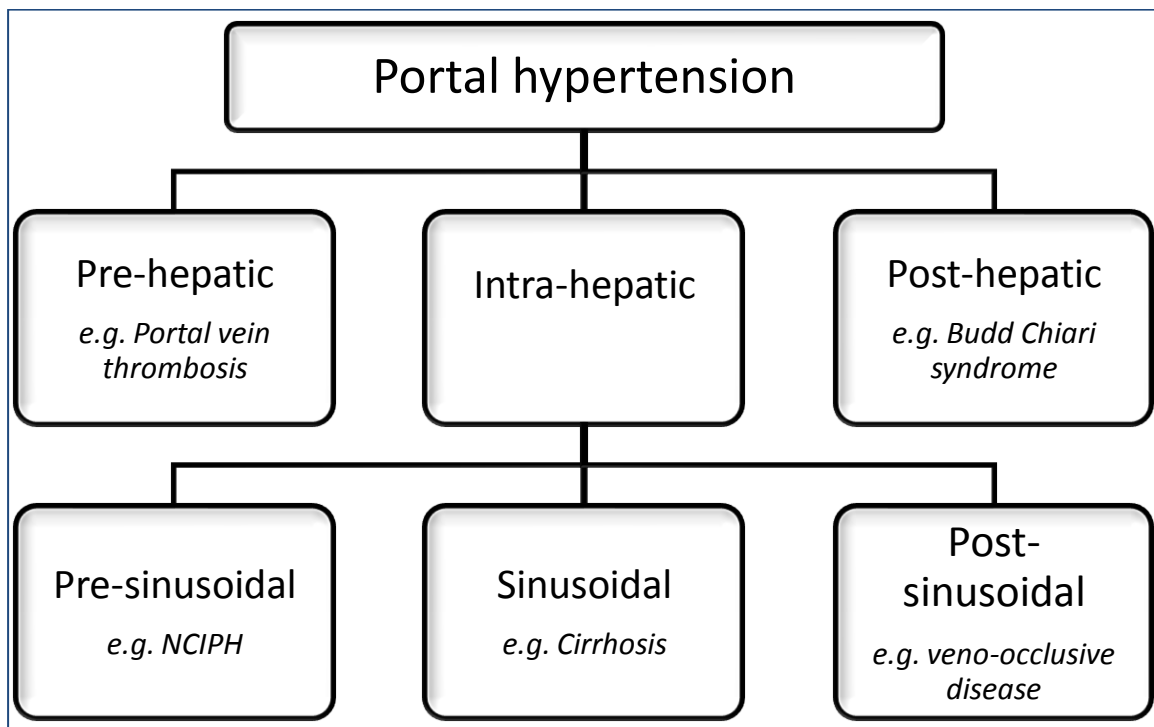


Figure 2: Classification of portal hypertension as per the level of vascular obstruction

Corrosion cast and detailed morphometric studies have localised the site of portal venous inflow block as the 3rd and 4th order intra-hepatic portal vein radicles^{16, 17}. As the site of block cannot yet be possibly delineated by the available imaging techniques, the diagnosis of NCIPH is dependent on excluding various disorders and is based on the following criteria^{3, 18}:

1. Portal hypertension – evidenced by gastroesophageal varices on upper gastrointestinal endoscopy/ splenomegaly
2. Patent portal vein (inflow) and hepatic venous outflow tract on a Doppler scan of abdominal vessels
3. Absence of known aetiology of chronic liver disease – e.g. Hepatitis B/ C virus, alcohol intake etc.
4. Absence of cirrhosis or advanced fibrosis (bridging fibrosis) on liver biopsy
5. Absence of any aetiology known to cause portal venous lesions similar to NCIPH – e.g. sarcoidosis, congenital hepatic fibrosis, primary biliary cirrhosis, schistosomiasis

Besides the essential criteria, there may be evidence of blockage of small intra-hepatic portal vein radicles on needle liver biopsy. Although these are not necessary for reaching a diagnosis, the presence of such histological equivalents strengthens it. These tell-tale signs are described in the section of *Nomenclature* and *Histopathology*.

Thus, to define NCIPH at present requires an extensive evaluation, including liver biopsy, essentially to rule out competing aetiologies.

NOMENCLATURE :

Various names have been and are used to describe NCIPH. As the disease patho-physiology is limited to small portal vein radicles, intra-hepatic portal vein obstruction (IHPVO) may be termed as patho-physiological equivalent.

NCIPH has been called as non-cirrhotic portal fibrosis (India)^{19, 20}, idiopathic portal hypertension (Japan)²¹ and idiopathic non-cirrhotic portal hypertension (INCPH)².

Besides, there are various histological equivalents :

- a. Nodular regenerative hyperplasia (NRH)²²
- b. Hepato-portal sclerosis²³
- c. Obliterative portal venopathy²⁴
- d. Incomplete septal cirrhosis

We prefer to use the term NCIPH as it denotes the level of blockade (intra-hepatic) and also refers to the essential criteria of absence of advance fibrosis/ cirrhosis on liver biopsy.

EPIDEMIOLOGY :

NCIPH remains a disease reported predominantly from the developing countries, where it is commonly encountered in young males and present in 3rd/ 4th decade of life^{8, 15, 18}.

In Japan, this disease has become increasingly rare, coinciding with improvement in sanitation and general living standards. Similar trend has been recently reported from some parts in India²⁵. The relative rarity of the disease in the West and an apparent decline in its

incidence elsewhere as living standards and hygienic conditions improve support the notion that enteropathy plays a role in disease pathogenesis¹⁸.

Table 1 presents the various recent studies from India reporting the prevalence of NCIPH^{8, 14, 15, 26-29}. The prevalence greatly varies depending on the group of patients and modalities used for diagnosis. Sarin et al³⁰, based on personal communications from multiple tertiary centres across the country, estimated that NCIPH accounted for 23% of patients with portal hypertension in 1980's but only 5.6% more recently. This reduction in incidence accords with improving standards of hygiene and healthcare and reduction of diarrheal illnesses including tropical sprue.

Table 1 : Prevalence of NCIPH in various studies from India

Study	Year	Nature of study	Patient population (N)	Prevalence of NCIPH	Basis of diagnosis
Goel et al ¹⁴	2013	Prospective	Adult portal hypertension (583)	2.7%	Liver biopsy
Simon et al ²⁸	2009	Retrospective	Paediatric portal hypertension (171)	3.5%	Liver biopsy
Madhu et al ¹⁵	2009	Retrospective	Adult cryptogenic portal hypertension (62)	48%	Liver biopsy
Nayak et al ²⁶	2012	Retrospective	Adult liver transplant (372)	2.4%	Liver biopsy
Poddar et al ²⁹	2008	Retrospective	Paediatric portal hypertension (517)	2%	Liver biopsy
Dhiman et al ⁸	2001	Retrospective	Portal hypertension (?)	15%	Liver biopsy only in a proportion
Bhargava et al ²⁷	1991	Prospective	Portal hypertensive bleed (404)	20.5%	??

NCIPH can mimic cryptogenic ‘cirrhosis’ closely and liver biopsy is required for a confirmatory diagnosis. Trans-jugular route of liver biopsy is often preferred due to co-existent coagulopathy. Most centres in India have limited access to trans-jugular liver biopsy and hepatic venous pressure measurement. In addition, pathogenesis of NCIPH remains poorly understood and consequently has limited treatment options available. These factors may discourage physicians from aggressively establishing the diagnosis of NCIPH.

The condition is almost certainly under-diagnosed. Krasinskas et al³¹, reported that in 13 (81%) of 16 patients in whom unsuspected NCIPH was diagnosed on histological examination after liver transplantation, cirrhosis was the pre-operative diagnosis. Similar observations were recorded in a study by Radomski et al³², where four patients diagnosed with NCIPH post liver transplantation were mis-labelled as cirrhosis pre-operatively.

Goel et al¹⁴, in a prospective study (spanning 2009-10), from a tertiary centre in southern India observed ‘cryptogenic cirrhosis’ in 203 (35%) of 583 consecutive adult new portal hypertensive patients. The diagnosis of ‘cryptogenic cirrhosis’ was made only after a detailed, negative aetiology evaluation. 39 patients with ‘cryptogenic cirrhosis’ underwent liver biopsy, revealing NCIPH in 16 (41%) of them; Figure 3. These NCIPH patients were predominantly males (10/16) in their 3rd decade of life (age: 31, 20–59 years; median, range). Fourteen patients belonged to middle/lower socioeconomic class and most belonged to eastern India (10), 2 from southern India, 3 from northern India and 1 patient from Nepal. Thus, NCIPH remains an important cause of portal hypertension in India¹³.

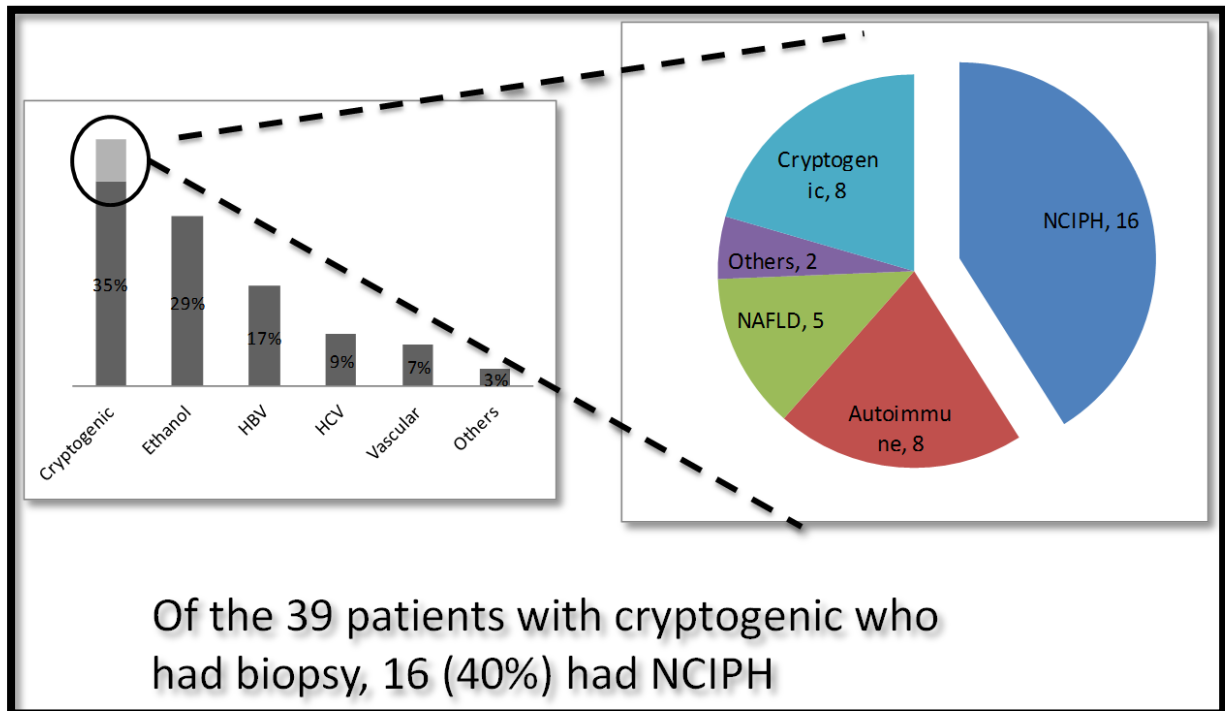


Figure 3: Figure depicting aetiology of portal hypertension (initially after a non-invasive workup and then after liver biopsy in a subset of patients with cryptogenic ‘chronic liver disease’ (Data from prospective study by Goel et al, spanning 1 year (2009-10) exploring the aetiology of new and consecutive adult patients with portal hypertension¹⁴)

PATHOGENESIS :

Multiple hypotheses of pathogenesis include – infection, toxin exposure, immune mediated damage and pro-thrombotic state. A subset of patients also seems to harbour possible genetic predisposition. At present there is no single proven mechanism for NCIPH. Various possible factors involved in pathogenesis are being discussed.

Poverty : ‘Poverty-linked-thrombophilia’ is probably secondary to environmental factors especially related to gut inflammation¹⁸. Limited access to clean drinking water, adequate sewage facilities and continued close-existence with animals ensures a state of mild gut inflammation in most Indian people. In a prospective study, we noted that most patients of portal hypertension belong to lower and middle socio-economic status¹⁴. This gut inflammation creates a pro-thrombotic milieu in portal circulation¹⁸, and can drive NCIPH.

Gut inflammation : The limited involvement of small portal vein radicles, suggest the active involvement of gut in the pathogenesis of NCIPH. Omanwar et al³³, created a rabbit model of NCIPH with repeatedly injecting E.coli in the portal circulation. Similarly Kathayat et al³⁴, created an animal model of NCIPH with immune-sensitisation with splenic extract.

Studies have shown increased prevalence of silent/ symptomatic gut disorders (coeliac disease, ulcerative colitis) in patients with NCIPH³⁵. Presence of these disorders was also associated with worse outcome. In addition, higher plasma titers of gut derived IgA anti-cardiolipin antibodies^{35, 36}, and deposition of IgA₂-complement complexes in the kidneys of up to 1/3rd of 200 NCIPH patients who developed nephrotic syndrome after splenorenal shunt also suggests the dominant role of gut in pathogenesis of this disorder⁹.

Increasing gut permeability is known to occur in patients with worsening cirrhosis and is often a marker/ harbinger of decompensation and clinical worsening. It has been shown that, as compared to western counterparts. In general, possibly secondary to poor socio-economic condition and consequent poor sanitation³⁷, the gut of Indians is more contaminated and inflamed³⁸⁻⁴¹. This may explain the increased prevalence of NCIPH in India and also declining prevalence in developed nations like Japan.

Imbalance between v-WF and ADAMTS-13 : In a previous study from the UK, the role of dysfunctional primary haemostasis in NCIPH was evaluated. Imbalance of von-Willebrand factor (v-WF) and its cleavage protein ADAMTS-13 (a disintegrin and matrix metalloprotease with thrombospondin- type 1 motifs member 13) was noted even in early stages of liver disease in NCIPH⁴². The role of primary haemostasis in Indian NCIPH patients need to be evaluated.

As of now ADAMTS-13 replacement (as fresh frozen plasma and recombinant ADAMTS-13) is an acceptable treatment option for thrombotic thrombocytopenic purpura, a disease associated with very low ADAMTS-13 levels. In a single patient with NCIPH and porto-pulmonary hypertension, fresh frozen plasma infusion was shown to be beneficial⁴³. This further strengthens the case for dysfunctional primary haemostasis as a primary event in pathogenesis of NCIPH and also gives us a lead towards a specific therapeutic option in future. This led to our hypothesis that NCIPH occurs in patients with low ADAMTS-13 levels who encounter raised v-WF levels in the portal circulation.

Hypovitaminosis B12 : Tropical sprue and tropical enteropathy are still prevalent in the country⁴⁴. Hypovitaminosis B12 is highly prevalent in general Indian population⁴⁵, and is also a salient feature of these tropical gut syndromes. Low vitamin B12 can be secondary to sub-clinical malabsorption (e.g. tropical/environmental enteropathy³⁸), genetic variations⁴⁶, or low intake (vegetarianism)⁴⁷.

We have previously noted that NCIPH patients more often have low serum vitamin B12 levels as compared to patients with cirrhosis⁴⁸. We have also noted that low vitamin B12 can be a marker of absence of advanced fibrosis in patients with intra-hepatic portal hypertension⁴⁹.

In an animal model vitamin B12 supplementation had a protective role against NDMA induced hepatic fibrosis⁵⁰. Although it was felt that low vitamin B12 in NCIPH indicates intact hepatocytes and consequent absence of vitamin B12 leaking in the bloodstream, whether this is secondary to an underlying environmental enteropathy is not well studied.

Besides having a possible role as a marker of NCIPH, the exact role (if any) that hypovitaminosis B12 (and possibly consequent hyperhomocysteinemia) plays in the pathogenesis remains unclear. Hypovitaminosis B12 can possibly exacerbate the problems secondary to arsenic exposure⁵¹. Whether this translates to increased risk of NCIPH in Indian population, especially in areas with endemic arsenicosis, remains to be studied.

Increased gut inflammation (and possibly hypovitaminosis B12) can be a link to explain the 'poverty linked' thrombophilia, especially manifesting in the portal circulation. This may thus be one of the reasons why NCIPH remains an Indian disease and also partially explains the slow disappearance in certain parts of India with better living condition.

Toxins : In the gangetic plains, arsenic contaminated ground water is the source of continued health problem of endemic proportions. Arsenicosis predominantly affects the skin and lungs with liver being only rarely involved. NCIPH, though is the most common serious liver problem associated with arsenicosis^{52, 53}. Initial cases linking the two disease entities were published from the state of Bengal⁵⁴. Since then several cases underlining this association have been reported from eastern parts of India and Bangladesh^{55, 56}. Studies have shown increased liver arsenic content in patients with NCIPH as compared to cirrhosis⁵⁶. Animal studies have also shown that chronic arsenic ingestion causes hepatic fibrosis^{57, 58}. Several of the alternative medications prevalent in India may be contaminated with arsenic and may represent another risk factor for exposure^{59, 60}.

Increasingly drugs, especially anti-retroviral drugs⁶¹ and Azathioprine have also been reported as a causative factor for NCIPH.

Immune mediated : Variety of immune disorders have been reported to be associated with NCIPH – e.g. common variable immunodeficiency (CVID), Rheumatoid arthritis, coeliac disease. The exact mechanism needs to be studied in greater details¹⁸.

Pro-thrombotic factors : Myeloproliferative disorders have been reported to be associated with NCIPH. An occasional patient also has been reported with other inherited pro-thrombotic disorders^{17, 62}.

Others : Various other disorders are associated with NCIPH. Immunological, haematological and malignant disorders are the most common associations reported with NCIPH at least from the studies done in the West⁶³.

Genetic predisposition : There have been isolated reports of NCIPH occurring in childhood and families suggesting a possible role of genetic predisposition⁶⁴⁻⁷⁰. In large western study on natural history of NCIPH, none of the 69 patients reportedly had a family history of liver disease⁶².

In addition, NCIPH has been occasionally reported in various genetic disorders - cystic fibrosis⁷¹, protein C & S deficiency⁷², primary antibody deficiencies⁷³, hereditary cystinosis⁷⁴,

mucopolysaccharidosis⁷⁵, chronic granulomatous disorder⁷⁶, telomere syndromes⁷⁷, Adams-Oliver syndrome⁷⁸ and Turner syndrome⁷⁹.

Multiple studies have attempted to explore the role of genetic influence in pathogenesis of NCIPH. Whole exome sequencing in familial NCIPH revealed potential pathogenic mutations needing further studies^{80, 81}.

Table 2 lists various genetic influences that have been explored in association with NCIPH⁸²⁻⁸⁷. Various possible genetic influences have been studied – immuno-genetic (major histocompatibility complex), thrombophilic and metabolic (especially drug susceptibility).

Table 2 : Studies exploring genetic component to pathogenesis of NCIPH

Study	Phenotype	n	Mutation	Inheritance	Suggested mechanism	Comments
Villarinho et al ⁸⁰	Onset during childhood within families	8	DGUOK (a deoxyguanosine kinase)	Autosomal Recessive	Impaired mitochondrial DNA replication	Whole exome sequencing
Vispo et al ⁸²	HIV associated	22	5' nucleotidase (rs11191561, rs11598702) Xanthine oxidase (rs1429376, rs1594160)	Associated polymorphism	Impaired purine metabolism	Tagged 36 SNPs at enzymes involved in the purine metabolism
Koot et al ⁸¹	Single father with children from three different mothers	4	KCNN3 gene (encodes for Ca ²⁺ dependent K ⁺ channel) (c.1348G>C)	Autosomal Dominant	Unclear, may affect endothelial vasoregulation	Whole exome sequencing
Blogowski et al ⁸³	Crohn's disease patient on Azathioprine	1	thiopurine S-methyltransferase (TPMT) heterozygous genotype (*1/*3A)	Associated polymorphism	Lowers activity of TPMT enzyme	SNP study
Bayan et al ⁸⁴	Adults	11	Multiple associated polymorphisms	Associated polymorphism	Increases thrombogenic tendency	Assessing 12 thrombophilic mutation
Buchel et al ⁸⁵	NRH with portal vein thrombosis and avascular necrosis of hip	1	MTHFR (c.677C>T)	Heterozygous mutation	Hyperhomocysteinemia	Prothrombin / Factor V Leiden and MTHFR gene mutation screening
Ishii et al ⁸⁶	Co-existent systemic sclerosis	1	Factor V Leiden	Associated polymorphism	Increases thrombogenic potential	-
Taneja et al ⁸⁷	Unrelated N. Indian patients	48	HLADR3 (increasing susceptibility) and HLA DR2 (conferring protection)	Associated polymorphism	HLA mediated autoimmunity	HLA A, B and DR antigens

NCIPH, thus is an example of a complex disorder caused due to interplay between genetic predisposition and environmental triggers.

CLINICAL PRESENTATION :

Patient typically presents in early adulthood with portal hypertension and its related complications. Usual presentation is with splenomegaly and/or well tolerated bleeds⁶².

Decompensation (ascites and encephalopathy) is uncommon till very late, but transient ascites developing post variceal bleed can be seen. Often massive splenomegaly and hypersplenism with preserved liver function raises the possibility of primary haematological pathology. Thus, it is not uncommon to have a patient presenting to Haematology department prior to Hepatology^{2, 18}.

Vascular complications of liver disease i.e. hepato-pulmonary syndrome and porto-pulmonary hypertension can also develop in these patients.

INVESTIGATIONS (INCLUDING HISTOPATHOLOGY) :

Laboratory evaluation : Usually the patient present with portal hypertensive complications. The liver synthetic functions (prothrombin time and serum albumin) are usually normal. The liver enzymes are also usually within a normal range. Hypersplenism (usually asymptomatic) is common with pancytopenia noted on routine haemogram. Indirect hyperbilirubinemia, possibly secondary to intra-splenic haemolysis, is often noted.

We have previously noted that NCIPH patients more often have low serum vitamin B12 levels as compared to patients with cirrhosis (figure 4)⁴⁸. We have also noted that low vitamin B12 can be a marker of absence of advanced fibrosis in patients with intra-hepatic portal hypertension⁴⁹. Although it was felt that low vitamin B12 in NCIPH indicates intact hepatocytes and consequent absence of vitamin B12 leaking in the bloodstream, whether this is secondary to an underlying environmental enteropathy is not well studied. Besides having a possible role as a marker of NCIPH, the exact role (if any) that hypovitaminosis B12 (and possibly consequent hyperhomocysteinemia) plays in the pathogenesis remains unclear.

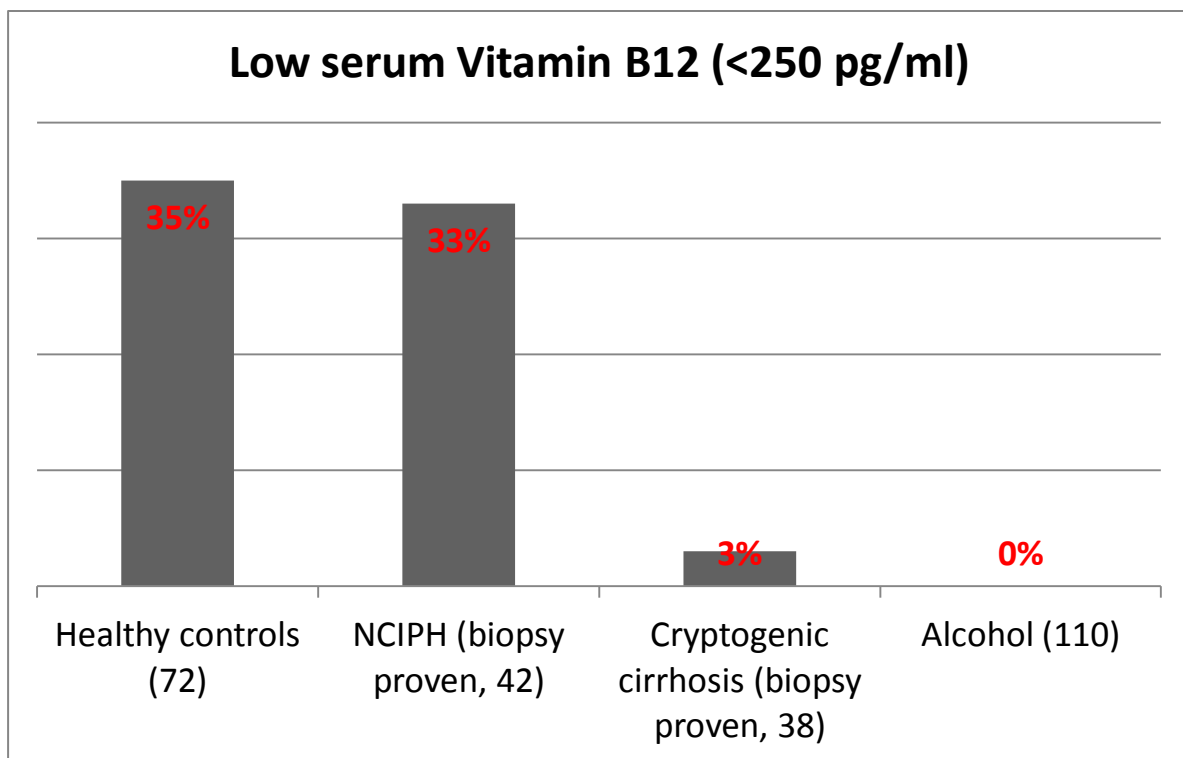


Figure 4 : Prevalence of hypovitaminosis B12 in NCIPH patients as compared to cirrhosis of varied aetiology

Imaging : NCIPH is secondary to blockage of small portal vein radicles. The current routine imaging techniques (ultrasound, computerized tomography, magnetic resonance imaging, MR elastography), although are unable to visualise such small vessels, are nevertheless required to ensure patency of main portal vein and hepatic venous outflow tract. Role of Tc99mSulfur colloid scintigraphy⁸⁸, fibroscan⁸⁹ and MR-elastography⁹⁰ needs further clarification. Although, none of the imaging modalities truly differentiate cirrhosis from NCIPH, occasional tell tale signs may help in this distinction.

Hepatic venous pressure studies : Hepatic venous pressure gradient (HVPG) is an adjunct to diagnosis of NCIPH^{18, 91}. As NCIPH involves blockage of small portal vein radicles, i.e. the block is pre-sinusoidal, HVPG is expected to be normal (≤ 5 mm Hg). In previous studies, we have noted a normal HVPG in only 1/4th of patients with NCIPH. Rest of the patients have raised HVPG, suggesting a peri-sinusoidal block as seen typically in cirrhosis¹⁴. Sarin et al, have also recognised pre-sinusoidal and peri-sinusoidal pressure gradients in these patients with NCIPH⁹².

Pathology of Liver : Liver biopsy is usually complicated by coagulopathy (raised prothrombin time), low platelets and presence of ascites. Majority of these patients can only undergo biopsy through trans-jugular route, as the above-mentioned risk factors preclude percutaneous route for biopsy. Interpretation of liver biopsy requires adequate specimen, i.e. length of the liver biopsy core being > 1 cm or presence of multiple cores with adequate number of portal tracts (> 5 in number). As the sub-capsular liver biopsies tend to have disproportionate fibrosis, a deep needle biopsy, in addition to wedge biopsy, is warranted in per-operative setting.

Grossly liver looks atrophic and nodular. It is often difficult to differentiate NCIPH liver from cirrhosis liver on gross appearance¹. Liver biopsy is mandatory criteria for diagnosis, where an adequate specimen is required to rule out advanced fibrosis/ cirrhosis. In addition, liver biopsy may show changes suggesting portal vein obliteration - portal vein ectasia/ angiomas, atretic/ sclerosed portal vein and sinusoidal dilatation. Nodular regenerative hyperplasia, incomplete septal cirrhosis and partial nodular transformation can be noticed in liver biopsy specimens at explant.

NATURAL HISTORY AND PROGNOSIS

Most published studies report an excellent overall survival of NCIPH patients³⁰. This may be just a reflection of relatively earlier presentation with compensated liver function. Most transplant centres would encounter patients with advanced liver disease secondary to NCIPH³¹. In a recent study, Schouten et al⁶², reported an overall 1,5 and 10 years survival of 100% , 78% and 56% respectively. This was significantly less than general population.

Eapen et al, reported a significantly diminished survival in NCIPH patients with undiagnosed/ late diagnosed active coeliac disease³⁵. Therefore, the associated factors of NCIPH may determine the prognosis, in addition to usual liver decompensation.

Liver transplantation is warranted in patients with decompensation (ascites, encephalopathy etc.) or any other complication e.g. porto-pulmonary hypertension (PPH) and hepato-pulmonary syndrome. A proportion of patients may also develop hepatocellular carcinoma, therefore regular surveillance may be required¹⁸.

COMPLICATIONS

In addition to portal vein thrombosis and decompensation, certain complications are more often associated with NCIPH. This may be secondary to prolonged survival in these patients after the initial presentation or may have a common pathogenic mechanism to the parent illness of IHPVO.

Hepato-pulmonary Syndrome (HPS): Orthostatic hypoxemia due to dilatation of intrapulmonary capillaries may occur late in many liver diseases including NCIPH. HPS is a relatively common indication of transplant in patients with NCIPH³¹.

Porto-Pulmonary Hypertension (PPH) : There have been recent reports of PPH happening secondary to low ADAMTS-13 in a patient with NCIPH. In this case report, Elias et al showed a significant decrease in pulmonary artery pressures on replacement of ADAMTS-13 as fresh frozen plasma⁹³. Platelet transfusions, on the other hand, exacerbated the pulmonary pressures. This suggested a role of micro-vascular occlusion in the pathogenesis of PPH.

Cryptogenic Cirrhosis : It is uncertain whether the evolution of NCIPH may in some cases progress to cirrhosis⁹⁴. In our previous studies, we have demonstrated that NCIPH can mimic cirrhosis, and these patients therefore can be termed as ‘cryptogenic’ cirrhosis prior to liver histology¹³⁻¹⁵. This suggests that in India, NCIPH remains under-diagnosed.

Nephropathy : 1/3rd of NCIPH patients, who had underwent meso-caval shunt surgery for bleeding varices, developed glomerulonephritis within a post-op period of 5 years. This was not evident in patients who had similar surgery for chronic portal vein thrombosis. Kidney biopsy, done in those NCIPH patients with glomerulonephritis, showed deposition of immune-complexes containing immunoglobulin subfraction derived from gut origin (IgA₂)⁹.

This development of glomerulonephritis and the histological findings thereof, suggests presence of pro-inflammatory drive from the intestine, which when confined to liver results in NCIPH, but on spill-over into the systemic circulation (i.e. lungs and kidney) may cause PPH, HPS or glomerulonephritis.

Hepatocellular Carcinoma : Hepatocellular carcinoma can be rarely seen in patients with NCIPH⁹⁵. The exact mechanism and prognosis thereof is not well studied.

MANAGEMENT

Intestinal pro-inflammatory drive (often unrecognized) is expected to influence the prognosis and therefore early recognition and adequate management of these gut disorders in all NCIPH patients is recommended³⁵.

Variceal bleed is the commonest initial presentation in NCIPH. The evidence for various therapies for variceal bleed in these patients is highly limited. It is expected that standard therapy for immediate control of bleed (Terlipressin/ Octreotide/ Somatostatin with endoscopic variceal ligation), primary prophylaxis (beta-blockers or endoscopic variceal ligation) and secondary prophylaxis (endotherapy + beta blockers) are valid in these patients as well^{2, 96, 97}. Small single centre, randomised trial from India, showed an equal efficacy of endoscopic sclerotherapy and beta-blockers in these patients⁹⁸. Surgical shunts early in the course of disease can be considered albeit for refractory bleeding, but with considerably increased long-term morbidity chronic renal failure (glomerulonephritis), encephalopathy, HPS and ascites⁹⁹. Trans-jugular intra-hepatic porto-systemic shunt (TIPSS) use, however, has been reported to be associated with increased liver failure and consequent mortality, and is thus limited in its utility³⁵.

Management of other complications is as per standard guidelines pertaining to cirrhosis patients. Need for liver transplantation has to be decided as per the standard guidelines in cirrhosis.

OBJECTIVE 1

**{TO STUDY THE CLINICAL PROFILE, NATURAL HISTORY AND
PROGNOSTIC FACTORS OF PATIENTS WITH NCIPH}**

OBJECTIVE 1.

{TO STUDY THE CLINICAL PROFILE, NATURAL HISTORY AND PROGNOSTIC FACTORS OF PATIENTS WITH NCIPH}

PATIENTS AND METHODS

Prospectively maintained database of patients diagnosed with idiopathic non-cirrhotic intra-hepatic portal hypertension (NCIPH) was retrospectively analysed. NCIPH was diagnosed as per published criteria, briefly – intra-hepatic portal hypertension with no definite aetiology and liver biopsy showing absence of advanced fibrosis/ cirrhosis.

Case definition

As per diagnostic criteria, all included NCIPH patients had a baseline colour doppler documenting normal inflow (portal vein) and outflow tract (hepatic venous outflow tract), detailed non-yielding etiological work-up for any known aetiology of liver disease (e.g. HBsAg, HCV antibody, workup for iron and copper overload, markers for autoimmune liver disease and others on markers and others on a case-to-case basis), a liver biopsy documenting absence of bridging fibrosis/ cirrhosis and excluding other causes that can closely mimic NCIPH (e.g. schistosomiasis, primary biliary cirrhosis, sarcoidosis etc.). Patients with history of significant alcohol intake (>20 gm/d), risk factors for non-alcoholic fatty liver disease (metabolic syndrome) and portal vein thrombosis at initial presentation were excluded.

Liver biopsy

141 of 207 NCIPH patients who were recruited, had undergone liver biopsy via the trans-jugular route, remaining patients had it either per-cutaneously (50) or per-operatively (14) or during the examination of the explant liver (2). Six patients had liver biopsy done elsewhere (the biopsy slides were reviewed at our centre). During trans-jugular biopsy, 3 (2-4); median, (IQR) cores of maximum length of 11 (8-14) mm having 10 (7-13) portal tracts were obtained. Similarly, by per-cutaneous route, 2 (1-3) cores of maximum length of 13 (10-15) mm having 10 (8-15) portal tracts were obtained. In addition to wedge biopsies, tru-cut biopsies were also obtained from the liver during per-operative sampling.

The liver biopsy revealed sinusoidal dilatation (78% of patients), portal vein ectasia (52%), peri-sinusoidal fibrosis (34%) and portal vein hypoplasia / obliteration (10%). Portal fibrosis was absent (29%), mild (51%), moderate (4%) or with thin focal peri-portal bridging incomplete septae in 16% of patients. Patients with liver biopsy finding suggesting alternative aetiology (e.g. steatosis, steato-hepatitis and significant inflammation) were excluded.

Hepatic venous pressure studies

Hepatic venous pressure measurements were carried out, whenever feasible using catheter wedge technique. A hepatic venous pressure gradient (HVPG) of <5 mm Hg was considered as normal.

Evaluation of associated factors

Besides baseline demographics, all patients were specifically interviewed regarding toxins/drug intake that can potentially cause NCIPH (e.g. Vitamin A, Azathioprine and Anti-retroviral therapy). Other associated factors were assessed on a case-to-case basis.

Celiac disease was defined as by a suggestive duodenal histology and positive IgA antibody to tissue transglutaminase. Arsenicosis was defined by a suggestive dermatological assessment and nail arsenic estimation was done in a subset (pre-digested nails tested by inductively coupled mass spectrometry). Haematological and immunological disorders were assessed for as felt needed by a clinician.

A subset of these patients was evaluated for ADAMTS-13 (a disintegrin and metalloproteinase with thrombospondin type 1 motif, member 13) activity by an in-house assay measuring the residual collagen binding activity of purified v-WF (von-Willebrand Factor) after exposure to platelet poor patient plasma.

Serum vitamin B12 was estimated by an electrochemiluminescence technique using a Roche E170 modular system. Normal range of serum vitamin B12 level was 200 – 950 pg/ml.

Follow up

All patients were followed up individually with regular clinical examination and USG-Doppler studies. All patients were managed in a standard protocol.

For variceal bleed, non-selective beta blockers were used in primary prophylaxis setting and combination of endotherapy protocol with non-selective beta blockers was used for secondary prophylaxis. Periodic USG abdomen (every 6 months-1 year) was advocated in all

patients while on follow up. Standard management for ascites included salt restriction, diuretics and therapeutic paracentesis.

Besides mortality and liver transplant, new onset decompensating event (encephalopathy, ascites, haematemesis or hepato-pulmonary syndrome) and occurrence of portal vein thrombosis and hepatocellular carcinoma was recorded.

Statistical analysis

Continuous variables were summarised as mean±standard deviation or median, inter-quartile range (IQR) and categorical variables as numbers (%). Kaplan Meier survival method was used to calculate overall survival and portal vein thrombosis and decompensation free survival at various time periods. Death and liver transplant were considered as terminal events. Log-rank test was used to compare survival in two sub-groups. Cox regression analysis was used to assess potential predictors of mortality/ decompensation/ portal vein thrombosis. A p-value of <0.05 was considered as statistically significant. All statistical analysis was performed by SPSS version 15.

OBJECTIVE 1.

{TO STUDY THE CLINICAL PROFILE, NATURAL HISTORY AND PROGNOSTIC FACTORS OF PATIENTS WITH NCIPH}

RESULTS

Demography, clinical and laboratory features of 207 NCIPH patients (Table 1)

During 1996 - 2017 (Figure 5), 207 patients (males : 131; age: 32 ± 12 years; Child's score : 5, 5 - 6; median, IQR) with liver biopsy proven NCIPH were recruited for the study. All patients fulfilled the diagnostic criteria for NCIPH.

Most of the patients belonged to eastern and southern parts of India. State-wise break up of patients – Tamil Nadu (49), West Bengal (44), Jharkhand (40), Andhra Pradesh (28), Bihar (12), North-eastern states (6), Kerala (3), Karnataka (3), Orissa (2), Chhattisgarh (2), Maharashtra (2). In addition, few patients belonged to Bangladesh (14), Nigeria (1) and Nepal (1).

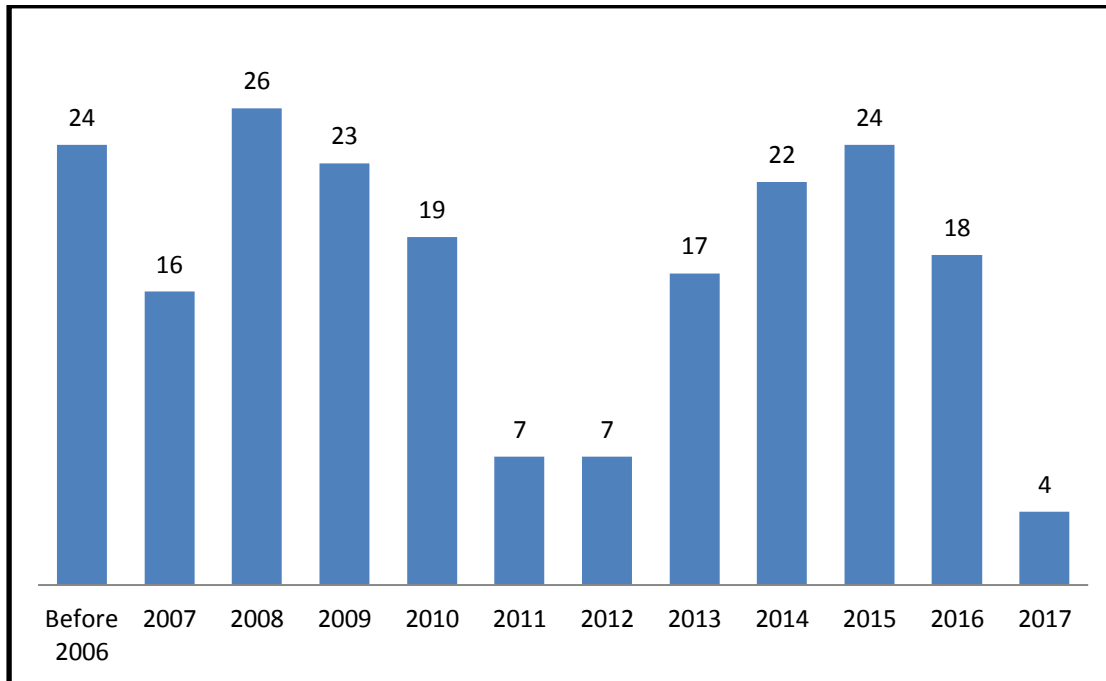


Figure 5: Number of new NCIPH patients (liver biopsy proven) diagnosed in a single tertiary centre in southern India from 1996 to 2017.

The most common initial presentation was sense of lump in left upper quadrant of abdomen (due to splenomegaly) and hypersplenism (50%) followed by variceal bleed (35%). Transient ascites was present in 14% of patients at presentation. 93% of patients had varices at the initial presentation, while rest had other signs of portal hypertension (high serum to ascites albumin gradient ascites and/or HVPG > 5 mm Hg).

Liver function tests were normal in the majority and consequently, most patients were in Child's class A at presentation. 43 (21%) patients had low serum vitamin B12 (< 250 pg / ml) at presentation.

Of 146 NCIPH patients tested, HVPG was ≤ 5 mm Hg (measured with catheter-wedge technique), in 52 (36%) patients. No patient gave history of prolonged complementary

medicine intake. No patient had history of prolonged intake of any drug which could potentially cause NCIPH (like vitamin A, azathioprine, anti - retroviral therapy).

Table 3 : Baseline characteristics of the cohort of 207 NCIPH patients

Characteristics	
Duration of symptoms prior to presentation (months)*	8 (4-32)
Residence (S/E/NE/W/O) [#]	83/100/6/2/1/16
Initial clinical presentation	
• Enlarged spleen / hypersplenism	104 (50%)
• Haematemesis	73 (35%)
• Transient ascites	29 (14%)
Laboratory parameters*	
• Serum bilirubin (mg%)	1.2 (0.8-2)
• Serum albumin (g/dl)	4 (3.6-4.4)
• Serum aspartate aminotransferase (U/L)	38 (28-48)
• Serum alkaline phosphatase (U/L)	92 (72-134)
• Prothrombin Time (International Normalised Ratio)	1.13 (1.06-1.24)
• Serum creatinine (mg/dl)	0.8 (0.7-1)
• Haemoglobin (gm/dl)	10.7 (9.1-12.7)
• Platelet count (X10 ⁵ /cmm)	0.54 (0.36-0.91)
• Child's score	5 (5-6)
• Plasma ADAMTS-13 activity (n=40) %	48% (15%-71%)
Radiological parameters*	
• Spleen size (cms)	17.9 (15-20)
• Portal vein size (mm)	13 (10.4-15)
• HVPG (n=146) (mm Hg)	7 (4-10)
• HVPG ≤5 mm Hg (n)	52 (36%)

ADAMTS-13 : a disintegrin and metalloproteinase with thrombospondin type 1 motif, member 13; HVPG: Hepatic venous pressure gradient; *Median (IQR); # S: Southern India, E: Eastern India, NE: North Eastern India, W: Western India, O: Outside India

Baseline characteristics of 18 paediatric NCIPH patients

Of the 207 NCIPH patients, 18 patients (males: 8; age: 14.2 ± 4 years) were in paediatric age group (< 18 years at initial presentation). As in adults, most patients underwent trans-jugular liver biopsy (13 patients). The clinical presentation was hypersplenism (72%), variceal bleed (28%) and ascites (17%). Most patients were in Child's class A at presentation (Child's score: 5, 5 - 6; median, IQR). HVPG was ≤ 5 mm Hg in 3 of the 9 patients tested. Low serum vitamin B12 was noted in two of the 16 patients (13%) tested. Coeliac disease (1 patient), glomerulonephritis (1) and selective IgA deficiency (1) were associated conditions noted in this subgroup.

Follow up

A subset of patients recruited during 1996-2015, 174 patients (M:112; Age: 32 ± 11.7 years; Child's score: 5, 5-6; median, IQR) with liver biopsy proven NCIPH were recruited for the follow up study. The duration of follow up in these NCIPH patients after the initial symptoms was 52.5 months (IQR: 13-93 months).

Decompensation (figure 6)

During follow up, 26 patients developed decompensating event after a median of 89 months (IQR: 66-147 months). New onset ascites (n=18), haematemesis (4), encephalopathy (2), hepatopulmonary syndrome (1) and porto-pulmonary hypertension (1) were the decompensating events during the follow up. Two of the patients developed ascites as an initial presentation of advanced hepatocellular carcinoma and one patient with ascites died on

follow up. Rest of the patients were managed conservatively with medications and were on regular follow up.

The median decompensation free survival was 176 months (95% C.I: 148-204 months) with 1, 5 and 10 year decompensation free survival being 0.99 (SE: 0.01), 0.95 (SE: 0.02) and 0.77 (SE: 0.05) respectively.

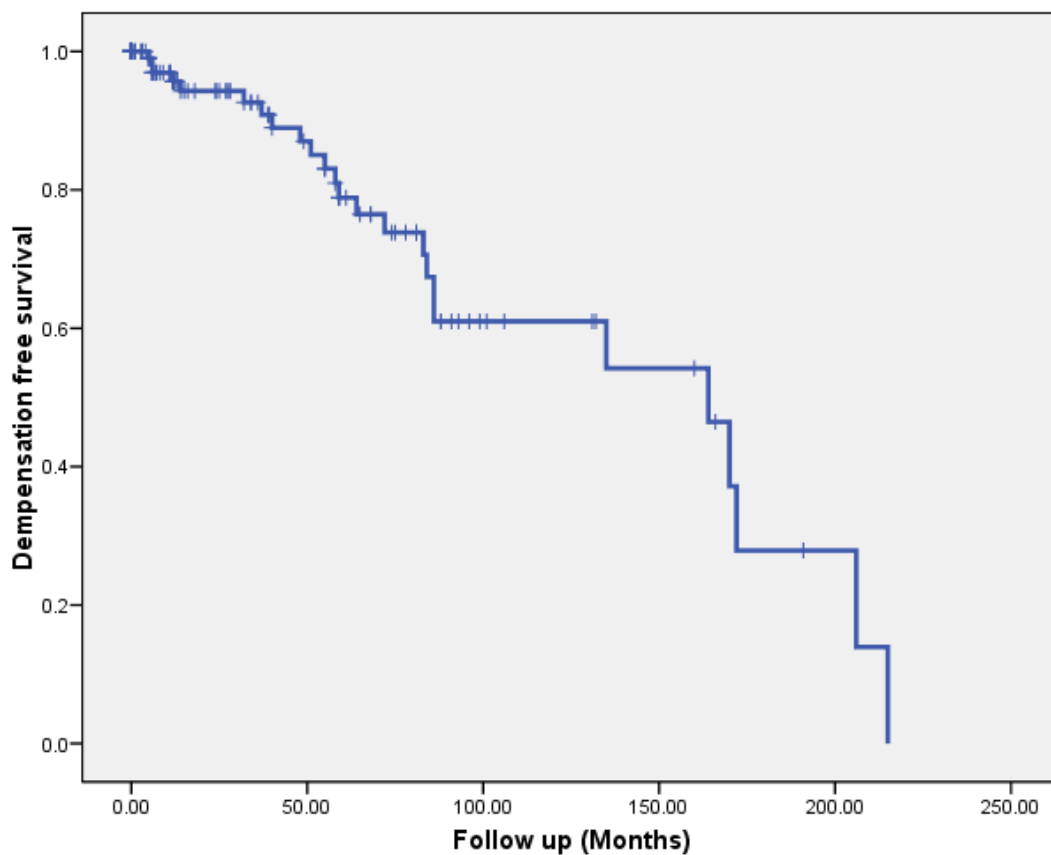


Figure 6 : Cumulative decompensation free survival of non-cirrhotic intra-hepatic portal hypertension (NCIPH) patients.

Portal vein thrombosis (figure 7)

During follow up, 28 patients developed portal vein thrombosis after a median follow up of 87.5 months (IQR: 50-143 months). The portal vein thrombosis was infrequently associated with ascites (7), haematemesis (1), encephalopathy (1) and portopulmonary hypertension (1). In rest of the patients, portal vein thrombosis was detected on routine US-doppler study.

The median portal vein thrombosis free survival was 202 months (95% C.I: 125-279 months) with 1, 5 and 10 year portal vein thrombosis free survival being 0.98 (SE: 0.01), 0.88 (SE: 0.03) and 0.75 (SE: 0.06) respectively.

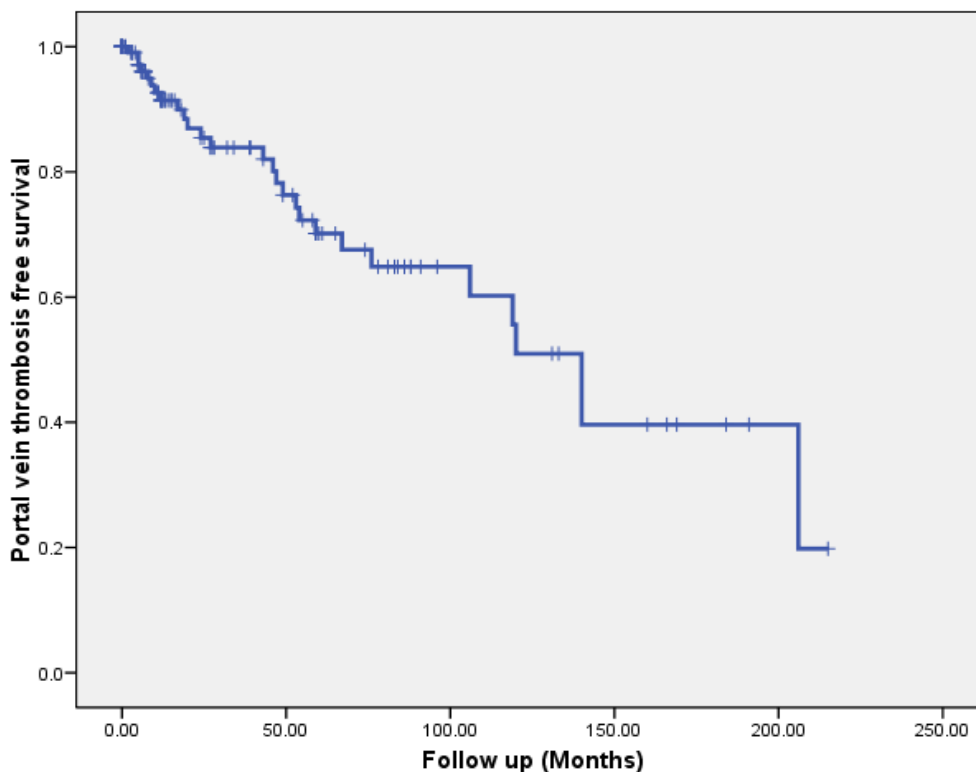
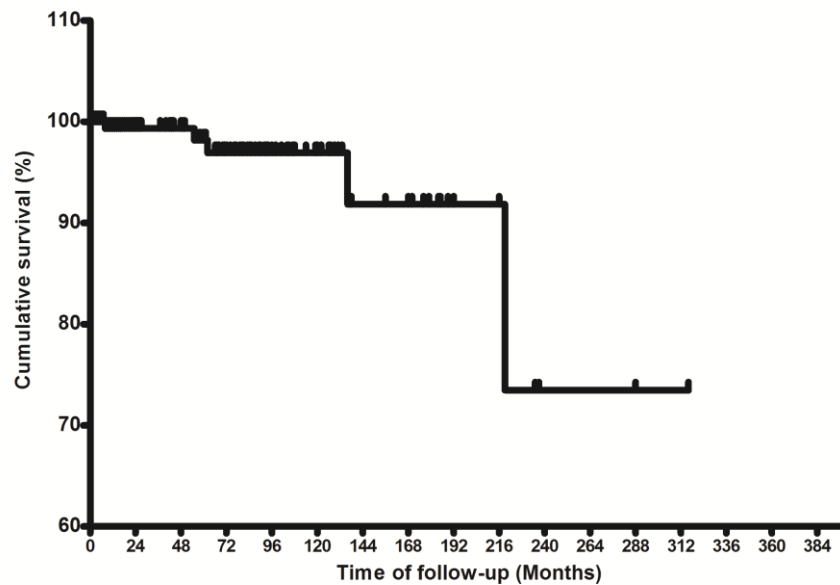


Figure 7 : Cumulative overall survival of non-cirrhotic intra-hepatic portal hypertension (NCIPH) patients.

Hepatocellular carcinoma, liver transplant and death

During follow up, 5 patients developed terminal outcome {advanced hepato-cellular carcinoma (2), death (1) and transplant (2)} after a median follow up of 62 months (IQR: 31.5-177.5 months).



Months	0	24	48	72	96	120	144	168	192	216	240	264	288	312	316
Patients at risk	174	106	91	69	40	29	17	15	7	6	3	3	2	2	1
Overall adverse outcome	0	1	1	3	3	3	4	4	4	5	5	5	5	5	5

Figure 8 : Cumulative overall survival of non-cirrhotic intra-hepatic portal hypertension (NCIPH) patients.

Single patient (age at presentation: 34 years, male) died at follow up of 219 months due to lower limb cellulitis followed by sepsis and consequent hepatic encephalopathy/ liver failure. Two patients were diagnosed as NCIPH on explant biopsies at the time of liver transplant –

one due to recurrent haematemesis (age at presentation: 15 years, male) and the other due to ascites and acute-on-chronic liver failure (age: 27 years, male). One of the patients developed recurrence of NCIPH (gastroscopy: small varices, HVPG: 5 mm Hg, liver biopsy: preserved architecture, mild portal fibrosis and sinusoidal dilation/ portal vein ectasia) 136 months post-liver transplant.

One, 5 and 10 year overall survival being 0.99 (SE: 0.01), 0.98 (SE: 0.01) and 0.97 (SE: 0.02) respectively. Figure 9 depicts cumulative incidence of various events happening in patients with NCIPH.

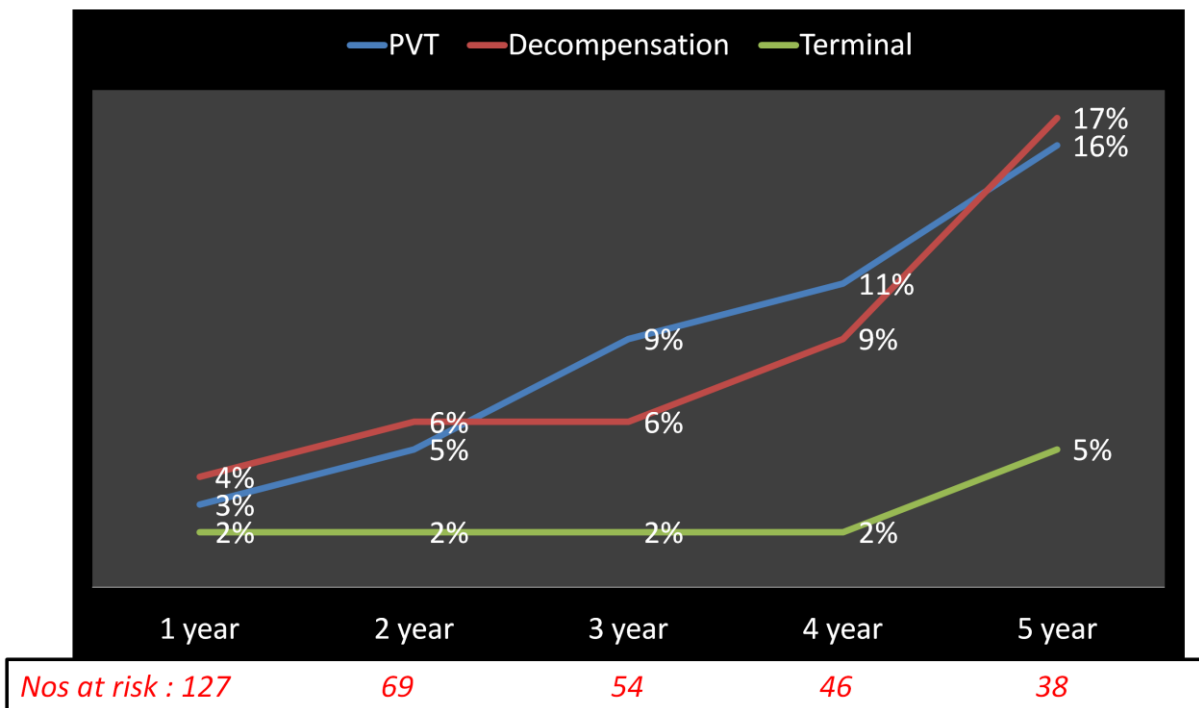


Figure 9 : Cumulative incidence of complications occurring in non-cirrhotic intra-hepatic portal hypertension (NCIPH) patients.

Outcome in patients with initial presentation as haematemesis

The patients with initial presentation as haematemesis (n=66) were compared to patients with alternative presentation (n=108), Table 2. Patients presented with haematemesis did not differ in their overall survival (p-value:0.311), decompensation-free survival (p-value: 0.7) and portal vein thrombosis free survival (0.8) from patients with alternate presentations.

Table 4 : Comparison of baseline factors and outcome in NCIPH patients presenting with/without haematemesis

	Initial presentation as haematemesis (n=66)	Alternate presentation (n=108)	p-value
Age (years)	32 (24-43.5)	32 (23-38)	0.4
Sex (M:F)	52:14	60:48	0.002
Child's score	5 (5-6)	5 (5-6)	0.9
Platelet count (x10⁵/cmm)	0.62 (0.43-0.97)	0.49 (0.33-0.74)	0.04
HVPG (>5 mm Hg)	23/39 (59%)	56/82 (68%)	0.4
Low ADAMTS-13 activity (≤55%)	13/20 (65%)	11/20 (55%)	0.7
Overall survival*	280 (243-317)	202 (179-227)	
Decompensation-free survival*	197 (158-237)	157 (131-182)	0.7
PVT-free survival (survival)*	179 (146-212)	164 (139-190)	0.8

HVPG : Hepatic venous pressure gradient; ADAMTS-13 : a disintegrin and metalloproteinase with thrombospondin type 1 motif, member 13

*Depicted as mean survival (95% CI) and compared by log-rank test

Predictors of outcome

Child's score increased the risk of overall mortality, but had no impact on decompensation-free or PVT-free survival. There was a trend towards association of low ADAMTS-13 activity with an increasing portal vein thrombosis on follow up. There was a trend towards higher HVPG being associated with decrease in decompensation and PVT on follow up. Similar trend was noted with higher baseline platelet count associated with higher incidence of decompensation.

Table 5 : Univariate analysis of baseline predictors associated with overall survival, decompensation-free survival and portal vein thrombosis (PVT)-free survival in NCIPH patients

Variable*	Overall survival		Decompensation free survival		PVT free survival	
	HR (95% CI)	p-value	HR (95% CI)	p-value	HR (95% CI)	p-value
Age	0.96 (0.89-1.04)	0.3	0.97 (0.94-1.01)	0.09	1 (0.96-1.03)	0.84
Haematemesis as initial presentation (Y/N)	3.1 (0.3-30.8)	0.3	0.86 (0.38-1.96)	0.7	1.1 (0.48-2.5)	0.82
Child's score	1.6 (1.15-2.1)	0.004	1.14 (0.88-1.46)	0.32	0.93 (0.63-1.39)	0.73
Platelet count (X10 ⁵ /cmm)	1.06 (0.2-5.3)	0.95	1.46 (0.93-2.28)	0.097	1.14 (0.61-2.11)	0.69
Spleen size (cm)	0.77 (0.58-1.03)	0.08	0.96 (0.85-1.09)	0.5	0.97 (0.86-1.09)	0.63
Portal vein diameter (mm)	0.9 (0.7-1.3)	0.5	0.95 (0.85-1.07)	0.4	0.99 (0.89-1.11)	0.91
HVPG (mm Hg)	0.78 (0.4-1.5)	0.45	0.9 (0.78-1.04)	0.15	0.83(0.7-0.97)	0.02
Co-existent coeliac disease (Y/N)	-	-	0.83 (0.19-3.6)	0.8	0.37 (0.05-2.7)	0.33
ADAMTS-13 activity (%)	1 (0.95-1.05)	0.85	0.99 (0.96-1.02)	0.39	0.98 (0.95-1.01)	0.13

*All variables are analysed at baseline

HVPG : Hepatic venous pressure gradient; ADAMTS-13 : a disintegrin and metalloproteinase with thrombospondin type 1 motif, member 13

Associated disorders

Various disorders that were found to be associated with NCIPH in the prospective database are :

• Celiac disease	15 (9%)
• Arsenicosis	4 (2%)
• Glomerulonephritis	6 (3%)
• Prior history of eclampsia	3 (2%)
• History of similar illness in the family member	3 (2%)
• Hematological disorders [§]	5 (3%)
• Immunological disorders [^]	7 (4%)
• Others ^{&}	11 (6%)

§ Aplastic anemia : 3; Monoclonal gammopathy of uncertain significance: 2;

^ Systemic lupus erythematosus:1; Rheumatoid Arthritis:1; selective IgA deficiency :2; Psoriasis:1; Autoimmune gastritis :1; Common variable immunodeficiency:1;

& Avascular necrosis of hip: 2; spinocerebellar ataxia:1; Plummer Vinson syndrome : 1; Mental retardation:1; Gaucher’s disease:1; WPW syndrome:1; Chronic pancreatitis:1; Hansen’s disease:1; Neurofibromatosis-1 : 1; Severe aortic stenosis: 1

OBJECTIVE 1

{TO STUDY THE CLINICAL PROFILE, NATURAL HISTORY AND PROGNOSTIC FACTORS OF PATIENTS WITH NCIPH}

DISCUSSION

A retrospective analysis of a large prospectively collected database of NCIPH patients, demonstrate a good medium/ long term overall survival in these patients. We also demonstrate that a notable proportion of these patients develop decompensation and portal vein thrombosis on follow up. The traditional baseline prognostic factors, including presentation as haematemesis, that predict outcomes in cirrhosis are not operative in patients with NCIPH.

Diagnosis of NCIPH is based on criteria which includes liver biopsy¹⁸. All patients with portal hypertension were subjected to a detailed aetiological evaluation. The patients with cryptogenic (no cause evident) intra-hepatic portal hypertension were then assessed for feasibility of performing a liver biopsy. The route of liver biopsy was decided on clinical and laboratory parameters and on a case-to-case basis with majority undergoing liver biopsy through trans-jugular route (68%). While obtaining per-operative liver biopsies, care was taken to obtain tru-cut sample (from deep parenchyma) in addition to wedge sample (from superficial parenchyma), to avoid misinterpretation.

In this study, all patients underwent liver biopsy, which was initially assessed by an experienced pathologist for adequacy of sample. Only patients with liver biopsy deemed

interpretable by the pathologist were included in the study. None of the patients had complications secondary to liver biopsy.

As mandated by the diagnostic criteria, all patients had absence of advanced fibrosis (i.e. bridging fibrosis/ cirrhosis). Specific findings that suggest obliterative portal venopathy were present in a minority. Most common specific finding was ectatic portal vein radicles, which often showed herniation in to the liver parenchyma.

NCIPH patients in the present study were young with most presenting in 2nd to 4th decade of life (mean: 32±12 years). Although we noted a male pre-ponderance (63%), in the study, females were over-represented in NCIPH cohort when compared to expected sex-ratio in patients with alternate aetiology of intra-hepatic portal hypertension. This was shown in our previous prospective study exploring the aetiology of portal hypertension in India¹⁴.

The patients belonged to various states across the nation, but hailed mainly from southern and eastern parts. This may reflect the general patient inflow to the tertiary centre, or may reflect a shared environmental factor (e.g. arsenic groundwater contamination in gangetic plains or in the mining areas).

In the present study, one-two new patient with NCIPH was diagnosed every month (figure 5). This suggests, continued occurrence of NCIPH in India. As the tertiary centre generally caters to upper lower and lower middle class, this probably reflects presence of NCIPH in this socio-economic class. This was previously shown by a prospective study from the department¹⁴. This also suggests to a possibility of ‘poverty linked thrombophilia’ as a possible mechanism behind NCIPH in India¹⁸, especially when more developed countries (e.g. Japan) have shown a declining trend in recent years.

Most common mode of presentation was splenomegaly and variceal bleeds. The liver function at baseline revealed a well preserved liver function at presentation. The synthetic function of liver (as reflected by prothrombin time and serum albumin) were normal for most patients at presentation. Most patients on the other hand had features suggesting portal hypertension - gross splenomegaly, thrombocytopenia and dilated portal vein. This is true with most other studies in these patients in the past^{2, 8, 62, 96, 100}. The patients usually present with complications of portal hypertension and otherwise preserved liver function.

Hepatic venous pressure gradient (HVPG) was measured in majority (70%) of the study patients. HVPG helps in ascertaining the site of gradient in portal hypertension and thus differentiating cirrhosis (sinusoidal) from NCIPH (pre-sinusoidal). In NCIPH, as the site of gradient is pre-sinusoidal, hepatic venous pressure gradient does not reflect the severity of portal hypertension. In our study patients (all with intra-hepatic portal hypertension and varices), 36% patients had normal HVPG (<5 mm Hg), suggesting a pre-sinusoidal cause. In rest of 64% patients, HVPG was above normal. This is expected in NCIPH, as the site of gradient can be peri-sinusoidal as well⁹².

Nine percent of NCIPH study patients presented at age of <18 years. The initial presentation, baseline parameters and associated factors were similar to the general cohort of adult patients.

All patients with NCIPH were encouraged to come for regular clinical follow up visits at 6 monthly intervals. For studying the natural history, patients presenting till 2015 (n=174, 84%) were included. This ensured an adequate follow up of close to 5 years for this cohort, where occurrence of new complications was assessed in these patients.

For the purpose of study, new-onset decompensation was defined as occurrence of new complications of liver disease e.g. variceal bleed, ascites, encephalopathy etc. Patients with variceal bleed and transient ascites at baseline were also included and the data recorded for

any other new decompensating events. Most patients developed ascites, which was often transient and easily controllable with diuretics. The median time to decompensation was 15 years with increasing incidence of decompensation on follow up. This suggests, although late in natural history, these patients do develop complications of liver cell failure.

Overt hepato-pulmonary syndrome (HPS) and porto-pulmonary hypertension (PPH) was noted in a single NCIPH patient each. This may be secondary to exposure of the lung circulation to hitherto unidentified vaso-active substances in the gut derived portal venous blood. This needs to be further studied. As the present study did not systematically assess for prevalence of HPS/ PPH at various time-points on follow up, it is difficult to comment on the incidence of these complications over time. This should be a subject of further research, with possibility of increased incidence in NCIPH as compared to cirrhosis.

None of the factors pertaining to severity of portal hypertension (e.g. HVPG, platelet count, haematemesis at presentation) predicted decompensation risk (Table 5). This suggests that the factors determining prognosis in NCIPH may be different from those that determine prognosis in patients with cirrhosis.

Portal vein thrombosis (PVT) is known to develop secondary to cirrhosis and NCIPH as well. This is considered secondary to local vascular stasis in the portal circulation. Although PVT can be asymptomatic, it can herald worsening of liver function with decompensation. In this study, 28 patients develop portal vein thrombosis on follow up with median time to PVT being 17 years. PVT was usually asymptomatic, but was associated with transient ascites in 1/4th of these patients. The subsequent natural history of PVT was not documented.

In a univariate analysis (Table 5), there was trend to low ADAMTS-13 activity being associated with PVT. Contrary to patients with cirrhosis, low HVPG predicted occurrence of PVT. This finding needs to be confirmed and further evaluated.

Figure 8 represents the overall risk of mortality in these patients on follow up. For the ease of analysis, occurrence of hepato-cellular carcinoma/ death or need for transplant were bundled together. The 10 year survival of 97% was contrary to the other studies from the west⁶².

As in cirrhosis, Child's score was a good predictor of mortality in univariate analysis (Table 5). But contrary to cirrhosis, none of the factors pertaining to severity of portal hypertension predicted survival.

Occurrence of variceal bleed is a prognostic event in natural history of cirrhosis. Patients with variceal bleed tend to have significantly poorer prognosis as compared to patients who have not had variceal bleed⁹⁷. In table 4, we attempted to assess the effect of variceal bleed in natural history of patients with NCIPH. The mortality, decompensation or portal vein thrombosis was not different in patients with or without variceal bleed at the initial presentation. Surprisingly, females preferentially presented with non-variceal bleed complaints.

This is the largest study till date on natural history of NCIPH patients. The strength of the study is the number of patients, strict inclusion criteria and relatively long follow-up. As is the case with any retrospective analysis, missing data remains a limitation.

From this study we can conclude that NCIPH patients, even though clinical picture may mimic cirrhosis, they behave very differently as far as the prognosis and factors determining prognosis are concerned.

The patients with NCIPH are prone to develop decompensation and portal vein thrombosis on follow up, and close follow up is warranted. The liver related mortality and development of hepatoma, albeit lower than cirrhosis, can occur in some of these patients.

With this disease occurring in younger age, the socio-economic impact may be greater than cirrhosis. Further studies are warranted to help clarify these various issues.

OBJECTIVE 2

**{ TO EXPLORE PATHOGENIC MECHANISMS INVOLVED IN
NCIPH }**

OBJECTIVE 2

{TO EXPLORE PATHOGENIC MECHANISMS INVOLVED IN NCIPH}

INTRODUCTION :

Intra-hepatic micro-vascular thrombosis is a common feature in cirrhosis and may be an important cause of progression of disease. This was well studied by Wanless et al in a 61 explant livers. Intimal fibrosis, suggesting healed thrombosis, was detected in hepatic venous branches in 70% of these livers and in portal venous branches in 36% livers. Hepatic venous lesions were associated with focal parenchymal extinction and portal venous lesions, on the other hand, were associated with size variation of cirrhotic nodules and variceal bleeding¹⁷.

Unlike cirrhosis, where the disease initially affects the hepatocytes, followed by micro-vascular thrombosis in idiopathic non-cirrhotic intra-hepatic portal hypertension (NCIPH), the initial (and main) pathology is occlusion of small intra-hepatic portal vein radicles¹. Previously NCIPH was recognised as common in India¹², it still remains an important cause of portal hypertension^{13, 14}.

Endothelial/ platelet derived factors, which are important in primary haemostasis, may play an important role in the 'dynamic' component of portal hypertension. ADAMTS-13 (A disintegrin and metalloprotease with thrombospondin type 1 motif, member 13) is a von Willebrand factor (v-WF) cleaving protease. Deficiency of ADAMTS-13 causes platelet micro-thrombi in thrombotic thrombocytopenic purpura (thrombotic micro-angiopathy). Reduced ADAMTS-13 levels and elevated v-WF levels are reported in portal hypertension of varied causes¹⁰¹⁻¹⁰³. Recent reports from West have suggested ADAMTS-13 deficiency in

NCIPH patients¹⁰⁴. ADAMTS-13 levels tend to decline in advanced cirrhosis¹⁰³, the recent report suggested ADAMTS-13 deficiency in NCIPH patients despite preserved liver function. This suggests a role for deficient ADAMTS-13 in pathogenesis of NCIPH¹⁰⁴.

The aim of this study was to analyse ADAMTS-13/v-WF imbalance in portal hypertension patients with NCIPH (cases) and compare to cryptogenic ‘cirrhosis’ (disease controls) and healthy controls.

PATIENTS AND METHODS :

Current study was a case–control study to compare plasma ADAMTS-13 and v-WF levels in NCIPH patients (cases), cryptogenic ‘cirrhosis’ patients (disease controls) and hitherto healthy volunteers (healthy controls). All cases and disease controls had portal hypertension (had gastro-oesophageal varices on upper GI scopy). Informed consent was obtained prior to recruitment.

Case selection, demography and initial evaluation of cases (NCIPH patient) and controls (cryptogenic ‘cirrhosis’) :

29 NCIPH patients (22 males; age: 29 (13-58) years median (range)) and 22 cryptogenic ‘cirrhosis’ patients (15 males; age: 46 (18-74) years) were recruited. Seventeen healthy volunteers (14 males; age: 32 (27-45) years) were also enrolled.

NCIPH case definition was as per previously defined criteria³: presence of portal hypertension with patent portal and hepatic veins, absence of cirrhosis/ severe fibrosis on

liver biopsy and exclusion of conditions causing cirrhosis (e.g. alcohol liver disease and viral hepatitis B and C). Liver biopsy also excluded conditions that may cause portal lesions mimicking NCIPH, e.g. sarcoidosis, primary biliary cirrhosis or congenital hepatic fibrosis. All NCIPH cases included in this study thus had baseline liver biopsy. Post-liver transplant patient and patients having hepatic malignancy or predominant biopsy features of other disease process (in addition to portal venous insufficiency) were excluded from the study.

Diagnosis of study patients:

All NCIPH patients underwent liver biopsy (percutaneous:6; trans-jugular:17 and peroperative:6). In patients who underwent TJLB, 3 (2 – 5) median (range) of cores, 13 (5-16) mm length and having 10 (4-15) portal tracts, were obtained and were deemed as adequate for interpretation. Similarly, during per-cutaneous biopsy, 2 (1-3) cores, 12 (10-20) mm long and having 7 (6-15) portal tracts were adequately obtained. Wedge and tru-cut liver biopsies were obtained per-operatively. Liver histology showed portal fibrosis in 24 patients (mild-20, moderate- 4), ectasia of portal vein (16 patients), peri-sinusoidal/peri-venular fibrosis (11), portal vein thickening (4), hypoplasia of portal tract (2) and atresia of portal vein (1). Five of the 15 NCIPH patients (30%), who had undergone hepatic venous pressure measurements, had normal hepatic venous pressure gradient (HVPG) ≤ 5 mm Hg.

Cryptogenic ‘cirrhosis’ was defined as intra-hepatic portal hypertension with no identifiable cause. All patients had a negative workup for aetiology of portal hypertension (e.g. h/o of alcohol intake, serology for Hepatitis B & C, tests for autoimmune hepatitis, tests for iron and copper overload and other investigations as required on a case to case basis). Liver biopsy was done in 9 of the 22 patients with cryptogenic ‘cirrhosis’ (per-cutaneous:2; trans-jugular

biopsy:7). The histology revealed cirrhosis in 5 patients and significant bridging fibrosis in 3 patients.

Initial symptoms at presentation in patients with NCIPH were – haematemesis (13), splenomegaly and hypersplenism (7), asymptomatic incidental (4), anaemia (2) and pedal edema, ascites, and splenomegaly alone (1 each).

Initial symptoms at presentation in patients with cryptogenic ‘cirrhosis’ was – haematemesis (8 patients), ascites and pedal edema (5), hypersplenism (3), asymptomatic incidental (2), splenomegaly (2) and dyspnoea with fatigue (2).

Two of the 29 NCIPH patients had co-existent adult coeliac disease, which was diagnosed after the diagnosis of NCIPH. One was a male, 35 year old patient presented with combined iron/ vitamin B12 deficient anaemia and the other was a male, 32 year patient with iron deficiency.

In addition, one male, 31 year old NCIPH patient had bilateral avascular necrosis of hip (developed 2 years after diagnosis of NCIPH). This patient had no prior history of steroid intake and also did not suffer from other medical conditions predisposing him to avascular necrosis.

One 45 year old male West-Bengal patient had skin changes suggesting arsenicosis (melanosis+ keratosis of palms and soles) and increased nail arsenic levels 0.8 mg/kg (normal range: 0.02-0.5 mg/kg)¹⁰⁵.

Routine evaluation to ascertain aetiology and severity of liver disease was performed in all cases and disease controls. Besides this, plasma ADAMTS-13 and v-WF levels were assayed in all study subjects.

Plasma ADAMTS-13 and v-WF assays :

For ADAMTS-13 and v-WF assays were done on platelet poor plasma which was derived from citrated blood. Then plasma was divided in aliquots and stored at -80°C till processing.

ADAMTS-13 antigen assay was performed using Imubind® ADAMTS-13 ELISA kits (American Diagnostica Inc., Stamford, USA). To make comparison of activity and antigen values easier, the results of the antigen assay were converted to a percentage using a mean normal value.

ADAMTS-13 activity assays was performed by two in-house methods, first by measuring residual collagen binding activity of purified v-WF (Collagen binding assay-CBA) and second by FRET (fluorescence resonance transfer) assay with v-WF73 substrate. The normal values of these assays were: ADAMTS-13 antigen (64-136%), ADAMTS-13 activity by FRET assay (60–123%) and ADAMTS-13 activity by CBA (55–160%).¹⁰⁶.

v-WF antigen assay was performed in platelet poor citrated plasma by an automated coagulation analyser (immunoturbidimetric method). Normal values for vWF antigen were 50–150 IU/dl. Ratio of v-WF:ADAMTS-13 was calculated using plasma v-WF (IU/dl) antigen levels and plasma ADAMTS-13 antigen levels.

Classifying plasma ADAMTS-13 and v-WF levels according to severity of liver disease:

Correlation of plasma ADAMTS-13 /v-WF levels and v-WF:ADAMTS-13 ratio in cases as well as disease controls with markers of liver disease severity (e.g. model for end-stage liver disease score and Child's class/ score) and with measures of portal hypertension severity (e.g. hepatic venous pressure gradient (HVPG) and platelet counts) was performed.

Statistical methods :

Discrete variables were expressed as numbers (percentage) and continuous variables expressed as median (range). Non-parametric tests were used to compare two groups; i.e. Fisher's exact test, Mann Whitney U/ Kruskal Wallis tests for two or more unrelated samples, Wilcoxon signed ranks test for two related samples and Spearman's correlation coefficient (ρ) for continuous variables).

To facilitate analysis, any patient with plasma ADAMTS-13 activity of <5% was taken as having an activity of 5%. For classification, based on plasma ADAMTS-13 activity (as measured by CBA), patients were defined to have severe (<10% activity), moderate (10-25%) or mild (25-55%) The difference in ADAMTS-13 and v-WF levels in both cases and disease controls was compared to healthy controls and expressed as ratio of means with confidence interval calculated by bootstrapping (percentile method; 1000 re-samples) using R software. For the rest of the analysis, SPSS version 15 was used. P-value of <0.05 was considered as statistically significant. The study was a-priori approved by institutional research and ethics committee.

OBJECTIVE 2

{ TO EXPLORE PATHOGENIC MECHANISMS INVOLVED IN
NCIPH }

RESULTS

Table 6 depicts the demographics and baseline laboratory parameters of patients with NCIPH and cryptogenic ‘cirrhosis’.

Table 6: Demographic and baseline laboratory parameters in patients with idiopathic non-cirrhotic intra-hepatic portal hypertension (NCIPH) and cryptogenic ‘cirrhosis’

Patient characteristics*	NCIPH (n=29)	Cryptogenic cirrhosis (n=22)	p-value
MELD score	10 (6-13)	11.5 (6-23)	0.02
Child’s score	5 (5-8)	7 (5-13)	0.001
Child’s class (A/B/C)	23/6/0	9/9/4	0.007
Platelet count (X10 ⁵ /cmm)	0.53 (0.09-3.44)	0.33 (0.15-3.16)	0.038
Hepatic venous pressure gradient (mm Hg)	7 (1-12) n=15	13.5 (7-20) n=6	0.003

*Values are either numbers (discrete) or median and range (continuous)

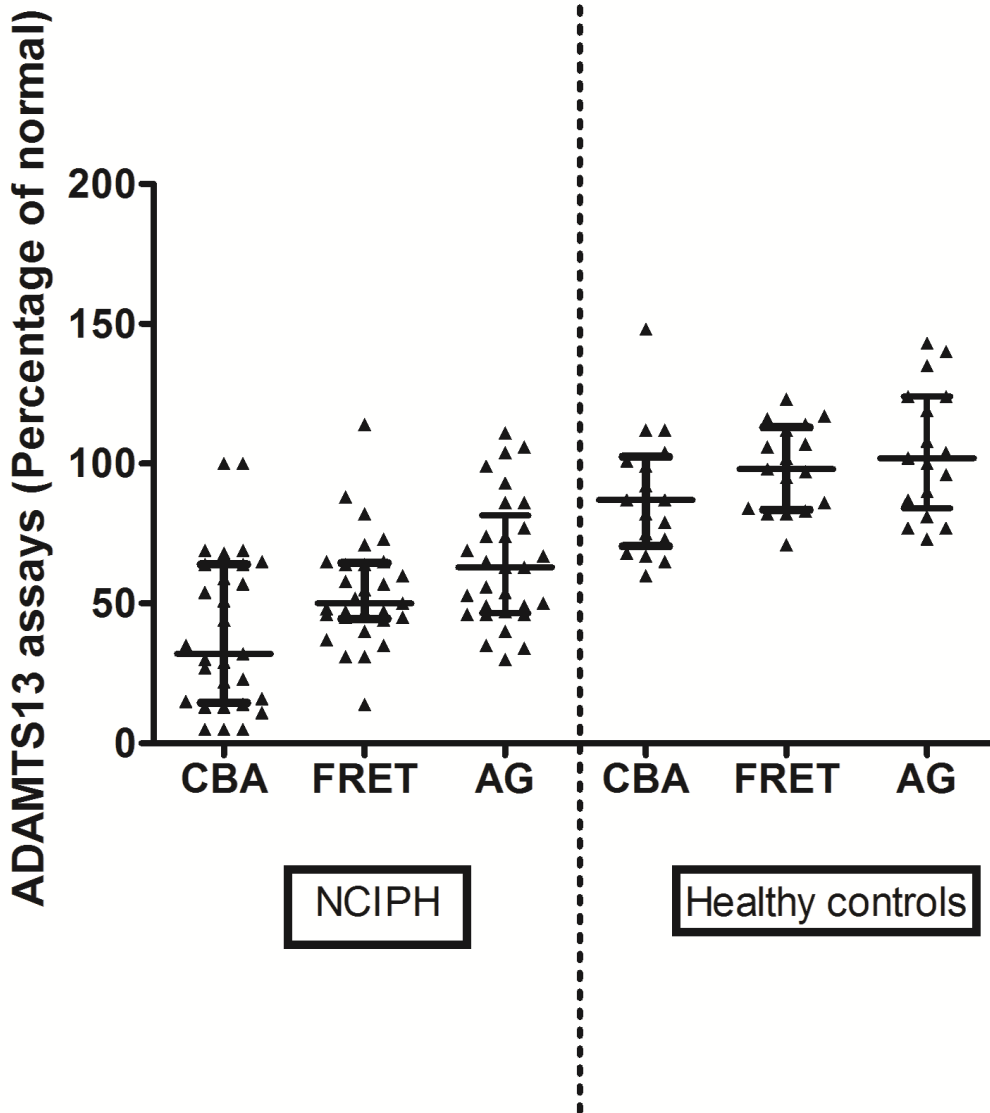
MELD : model for end-stage liver disease

Plasma ADAMTS-13 activity and plasma ADAMTS-13 antigen levels

Figure 10 depicts ADAMTS-13 activity as measured by CBA and FET and ADAMTS-13 antigen levels in the three study groups.

Test	Group	Value	P-value (against healthy controls)
ADAMTS-13 CBA	NCIPH	32%, 5-100%	<0.001
	Healthy	87%, 60-148%	-
	Disease controls	36%, 5-144%	<0.001
ADAMTS-13 FRET	NCIPH	50%, 14-114%	<0.001
	Healthy	98%, 71-123%	-
	Disease controls	49%, 5-125%	<0.001
ADAMTS-13 Ag	NCIPH	63%, 30%-111	<0.001
	Healthy	102%, 73-143%	-
	Disease controls	66.5%, 3%-228%	0.003

In NCIPH and cryptogenic ‘cirrhosis’ patients, ADAMTS-13 activity was significantly lower when measured by CBA assay as compared to FRET assay (p-value:0.001 and p-value:0.005 respectively). This was not so in healthy controls (p-value:0.14).



NCIPH: idiopathic non-cirrhotic intra-hepatic portal hypertension, ADAMTS-13: CBA: Collagen Binding assay; FRET : Fluorescence resonance transfer assay; AG: Antigen assay.

Figure 10 : Plasma ADAMTS-13 antigen and activity (expressed as % of normal) in 29 patients with NCIPH (*left panel*) and 17 healthy controls (*right panel*).

Plasma ADAMTS-13 activity classification:

Low ADAMTS-13 activity (by CBA) was noted in 19 (66%) NCIPH patients, as compared to none in healthy controls (p-value<0.001).

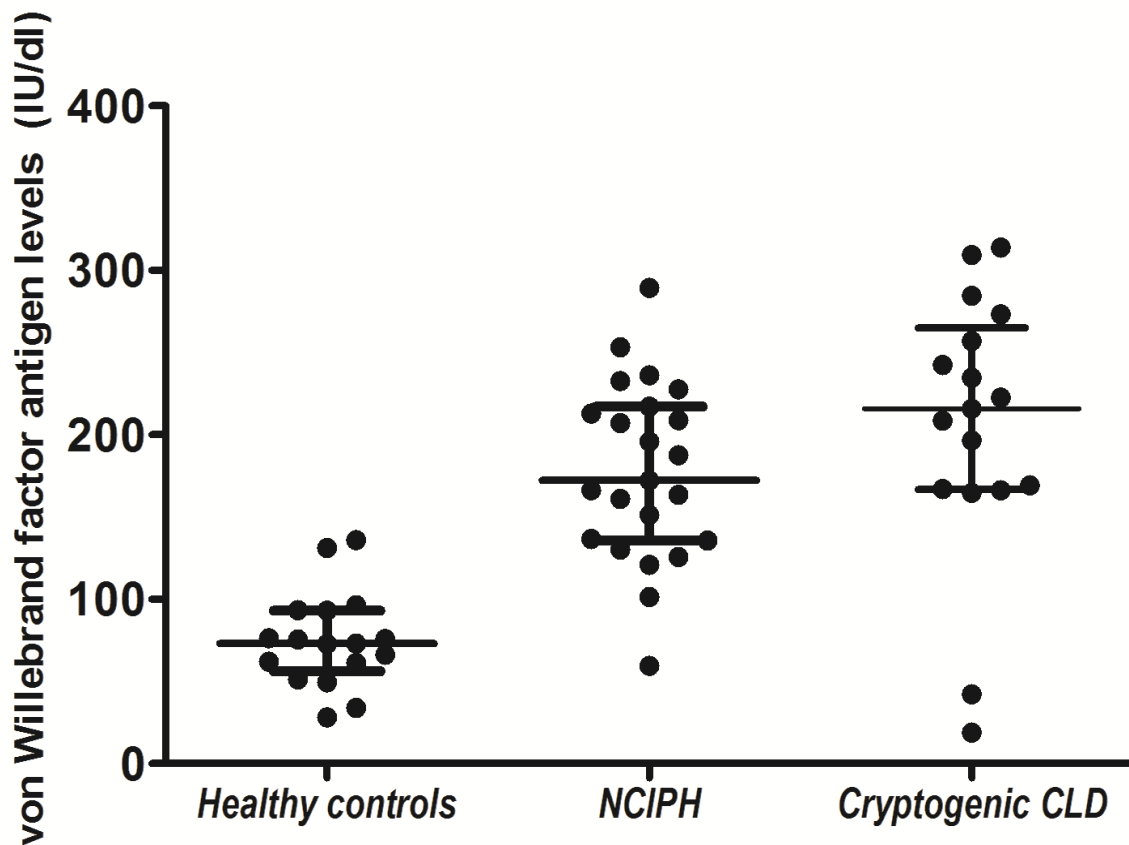
ADAMTS-13 deficiency	NCIPH	Healthy control	Disease control
Mild	8 (28%)	0	7 (32%)
Moderate	8 (28%)	0	2 (9%)
Severe	3 (10%)	0	6 (27%)
P-value (v/s healthy controls)	<0.001	-	<0.001

ADAMTS-13 specific activity (calculated as plasma ADAMYS-13 activity to antigen ratio for CBA (0.5, 0.07-1.89 v/s 0.81, 0.44-1.45; p-value:0.01) was lower in NCIPH patients than in healthy controls, which was not the case with FRET assay. Similarly, ADAMTS-13 activity to antigen ratio for CBA and FRET assay in patients with cryptogenic cirrhosis was similar to NCIPH patients.

v-WF antigen levels :

Figure 11 depicts the v-WF antigen levels in the three groups. 15 cryptogenic cirrhosis patients and 16 NCIPH patients had elevated plasma v-WF antigen levels (>150 IU/dl), as compared to none of the healthy volunteers

	NCIPH (23)	Healthy control (17)	Disease control (17)
v-WF antigen (IU/dl)	172.3 (59.4-289.4)	73.1 (38.2-135.9)	215.8 (18.9-313.8)
P-value (v/s healthy controls)	<0.001	-	<0.001

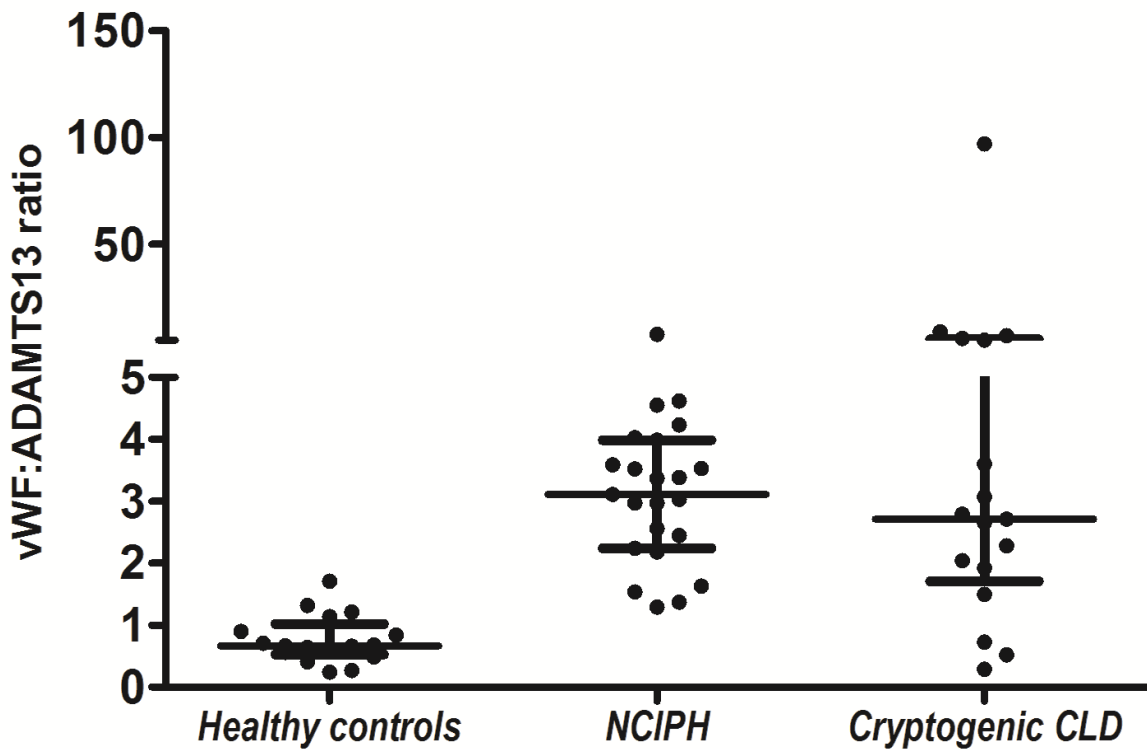


NCIPH : idiopathic non-cirrhotic intra-hepatic portal hypertension; CLD : Chronic liver disease

Figure 11 : Plasma von Willebrand factor antigen levels in patients with NCIPH (n=23) as compared to healthy controls (n=17) and patients with cryptogenic cirrhosis (n=17)

ADAMTS-13-v-WF imbalance in patients with portal hypertension:

v-WF:ADAMTS-13 ratio was higher in patients with NCIPH (3.1, 1.3-7.8; p-value<0.001) and also cryptogenic cirrhosis (2.7, 0.29-97; p-value<0.001) as compared to healthy controls (0.7, 0.2-1.7); Figure 12.

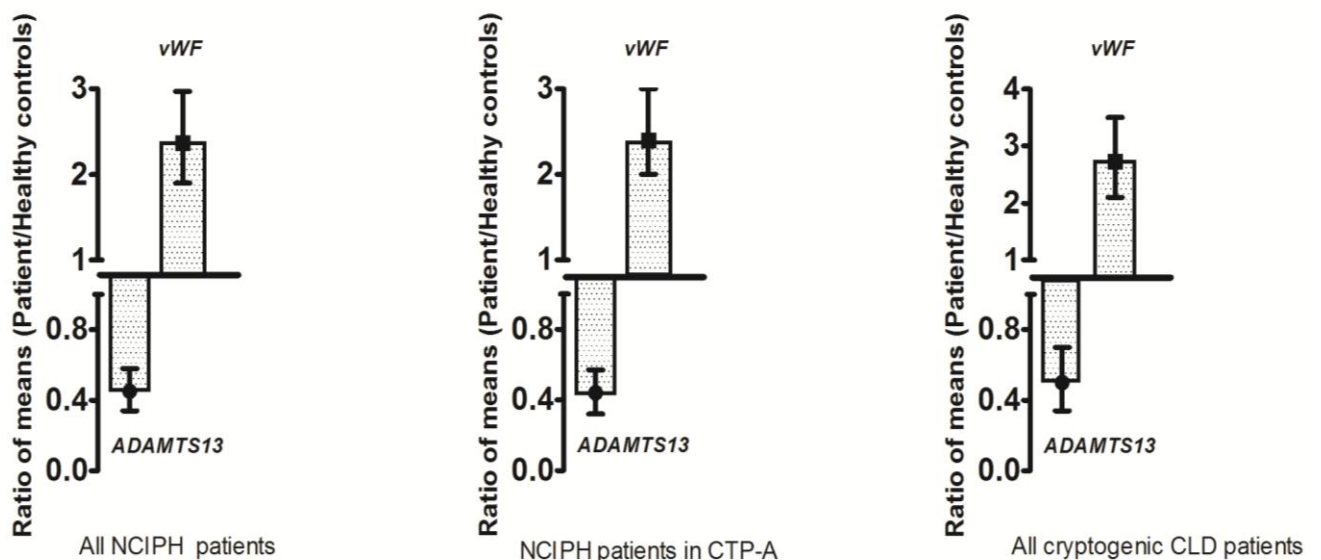


v-WF: von Willebrand Factor; ADAMTS-13: A disintegrin and metalloprotease with thrombospondin type 1 motif, member 13; NCIPH: idiopathic non-cirrhotic intra-hepatic portal hypertension; CLD: chronic liver disease

Figure 12 : Ratio of v-WF (IU/dl):ADAMTS-13 antigen in healthy controls (n=17), compared to patients with NCIPH (n=23) and cryptogenic cirrhosis (n=17)

ADAMTS-13 activity ratio :

Mean plasma ADAMTS-13 activity measured by CBA in NCIPH and cryptogenic cirrhosis was 45% (C.I: 34-58%) and 50% (C.I: 34-70%) respectively, of the healthy controls, Figure 13. In contrast, mean plasma v-WF antigen levels in NCIPH and cryptogenic cirrhosis, on comparison with healthy controls, was 237% (C.I: 190-297%) and 273% (C.I: 21-350%) respectively. Similar results were noted in Child's A NCIPH patients.



ADAMTS-13 : A disintegrin and metalloprotease with thrombospondin type 1 motif, member 13; v-WF : von Willebrand factor; NCIPH : idiopathic non-cirrhotic intra-hepatic portal hypertension; CLD : chronic liver disease; CTP-A: Child's Class A

Figure 13: Decreased plasma ADAMTS-13 activity and increased plasma v-WF antigen levels in NCIPH patients (*left panel*), cryptogenic cirrhosis (*right panel*) and NCIPH Child's class A patients (*middle panel*; n=23) as compared to healthy controls. The centre point represents the ratio of means and the horizontal bars depict 95% confidence interval

Plasma ADAMTS-13 activity (CBA) had a significant but moderate, negative correlation with plasma v-WF levels in patients with cryptogenic cirrhosis ($\rho=-0.5$; p value:0.05), but not in NCIPH patients ($\rho=-0.27$; p value:0.2).

Of all the portal hypertensive patients studied (NCIPH and cryptogenic cirrhosis), only 4 (3 NCIPH) had normal plasma ADAMTS-13 activity and normal plasma v-WF levels.

Plasma ADAMTS-13 levels as per severity of liver disease :

NCIPH patients with severe ADAMTS-13 deficiency (3) were in Child’s class A (MELD score : 8, 11, and 12). Most patients with cryptogenic cirrhosis having severe ADAMTS-13 deficiency were in Child’s class B/ C (p-value:0.05).

Severe ADAMTS-13 deficiency (9)	Child’s A	Child’s B/C	P-value
NCIPH	3	0	
Cryptogenic cirrhosis	1	5	0.05

Seven (88%) patients with NCIPH having moderate ADAMTS-13 deficiency and 6 (75%) with mild deficiency were in Child’s class A.

Plasma ADAMTS-13 activity (measured by CBA) did not show any correlation with MELD scores in both NCIPH patients ($\rho:-0.084$; p-value:0.7) and cryptogenic cirrhosis patients ($\rho:-0.3$; p-value:0.16).

There was no differences in MELD score in patients with NCIPH classified as per ADMATS-13 deficiency - severe deficiency (10.3; 8-12), moderate (10, 8-13), mild (7, 6-12) and normal activity (10.5, 6-13; p-value:0.12).

Plasma v-WF antigen levels as per severity of liver disease :

Both in NCIPH and cryptogenic cirrhosis patients, plasma vWF did not vary with Child’s grading.

Plasma v-WF antigen (IU/dl)	Child’s A	Child’s B	Child’s C	P-value
NCIPH	192 (59.4-253.2)	136 (101-289.4)	-	0.26
Cryptogenic cirrhosis	96 (42.2-309.4)	209 (18.9-313.8)	229 (197-284.5)	0.7

There was no correlation between plasma v-WF antigen levels and MELD score in either NCIPH patients ($\rho=0.35$; p value:0.13) and nor cryptogenic cirrhosis patients ($\rho=0.1$; p value:0.8).

v-WF:ADAMTS-13 ratio as per severity of liver disease :

Plasma v-WF:ADAMTS-13 ratio did not correlate with MELD score ($\rho=-0.01$, p value:1) or Child's score ($\rho=0.15$; p value:0.5) in patients with NCIPH. The ratio in patients with cryptogenic cirrhosis, though correlated with MELD score ($\rho=0.5$; p value:0.04) and Child's score ($\rho=0.56$; p value:0.02).

v-WF:

ADAMTS-13 ratio	Child's A	Child's B	Child's C	P-value
NCIPH	3.3 (1.3-7.8)	3 (1.4-4)	-	0.4
Cryptogenic cirrhosis	2 (0.3-5.2)	2.7 (0.5-7)	7.5 (3-97)	0.03

Plasma ADAMTS-13, v-WF antigen and v-WF:ADAMTS-13 ratio as per HVPG and blood platelet count :

HVPG was measured in 15 NCIPH patients and six cryptogenic cirrhosis patients.

Plasma ADAMTS-13 activity measured by CBA ($\rho=0.24$; pvalue:0.43), v-WF antigen ($\rho=0.28$; pvalue:0.32) and v-WF:ADAMTS-13 ratio ($\rho=-0.12$; pvalue:0.7) showed no correlation with HVPG in patients with NCIPH.

Similarly, there was no correlation noted between HVPG and ADAMTS-13 activity by CBA ($\rho=-0.35$; p value:0.5) in patients with cryptogenic cirrhosis.

Plasma ADAMTS-13 activity by CBA ($\rho=0.33$; pvalue:0.08), v-WF antigen ($\rho=-0.093$; pvalue:0.7) and v-WF:ADAMTS-13 ratio ($\rho=-0.36$; pvalue:0.09) showed no correlation to the platelet count in patients with NCIPH. This was also true for patients with cryptogenic cirrhosis.

OBJECTIVE 2

{TO EXPLORE PATHOGENIC MECHANISMS INVOLVED IN
NCIPH}

DISCUSSION

In this study, all patients with portal hypertension (both NCIPH and cryptogenic cirrhosis) had decrease in ADAMTS-13 activity (mean values : ~50% of that in healthy controls) and raised v-WF levels (mean values: ~ 250% of that in healthy controls). We also noted a significantly low ADAMTS-13 activity in patients with NCIPH. This ADAMTS-13 deficiency in NCIPH patients, despite preserved liver functions, is the most important observation of the current study. This is similar to what was reported in western cohort of NCIPH patients from the UK¹⁰⁴.

Of the 29 NCIPH patients studied, all 3 patients with severe ADAMTS-13 deficiency (i.e.: <10% activity when measured by CBA) belonged to Child's A and had low MELD scores (≤ 12). This is in contrast from a study by Uemura et al¹⁰³, where of the 109 patients studied with Hepatitis C cirrhosis, severe ADAMTS-13 deficiency (i.e.: $\leq 3\%$ of activity by v-WF multimer assay) was reported only in 5 patients, and all of these belonged to Child's class C (median Child's score: 13 (10 - 14)).

Uemura et al¹⁰³, in their study, noted severe ADAMTS-13 deficiency in 5 of 41 patients with Child's C cirrhosis with no patient belonging to Child's class A (35) or Child's class B (33)

cirrhosis had severe deficiency of ADAMTS-13. This suggests that, with advancing liver disease in cirrhosis, either there is gradual reduction in ADAMTS-13 secretion from the hepatic stellate cells^{107, 108}, or there is increased consumption.

Severe ADAMTS-13 deficiency in the three NCIPH patients in our current report, despite having preserved liver function (MELD score: ≤ 12), suggests that ADAMTS-13 deficiency as a primary event which plays a role in pathogenesis of NCIPH.

Mackie et al¹⁰⁴, in their study, performed a more detailed study of this phenomenon in NCIPH patients. In their study, ADAMTS-13 inhibitors and ADAMTS-13 antibodies did not contribute to the sustained ADAMTS-13 deficiency noted in NCIPH patients. ADAMTS-13 half life studies done in a single NCIPH patient (with severe ADAMTS-13 deficiency), after replacement in the form of fresh frozen plasma infusions, showed an increase in plasma levels of ADAMTS-13 activity and antigen for 72 hours⁹³. In another patient, deficient plasma ADAMTS-13 levels normalised post-liver transplant. All these findings put-together suggest that ADAMTS-13 deficiency in NCIPH may not be due to heightened consumption of ADAMTS-13. Thus, we propose that primary ADAMTS-13 deficiency, either congenital or acquired, may predispose an individual to developing NCIPH¹⁰⁴.

Elevated plasma v-WF level has recently been recognised as an important marker of prognosis in cirrhosis, which correlates with development of portal hypertension, decompensation and overall mortality^{101, 109}. In our current study, elevated plasma v-WF antigen levels did not correlate with liver disease severity. A possible explanation is lack of adequate number of patients with advanced liver disease (i.e. only 4 patients with Child's class C) included in the current study.

It is proposed that reduction in ADAMTS-13 activity when accompanied by an increase in substrate (i.e. ultra-large multimers of v-WF) in cirrhosis predisposes to platelet

microthrombi¹⁰³. In previous report on NCIPH patients, authors noted ultra-large v-WF multimers in four of the 11 (36%) NCIPH patients tested, compared to none in the controls¹⁰³. We propose that imbalance of ADAMTS-13 (decreased) and v-WF (increased) may be driving the portal venous obliteration noted in NCIPH, as this mechanism is also important in disease progression in patients with cirrhosis. This ADAMTS-13 / v-WF imbalance may have a role in pathogenesis of portopulmonary hypertension as well⁹³. Most (43/ 47 (92%)) of portal hypertension patients in our current study had this imbalance of ADAMTS-13–v-WF levels.

In our current study, in patients with cryptogenic cirrhosis, v-WF:ADAMTS-13 ratio showed an increase with worsening liver function (MELD and Child scores). This suggests an increased v-WF turnover and also ADAMTS-13 consumption with advancing disease. In NCIPH, although v-WF:ADAMTS-13 ratios were increased, they appeared unrelated to progression of liver disease. There was no correlation between v-WF and ADAMTS-13, suggesting that increased v-WF secretion does not account for the degree of ADAMTS-13 reduction.

In hypersplenism secondary to portal hypertension, sequestration of platelets is noted to happen onto the splenic endothelium¹¹⁰. We feel that in NCIPH, sequestration of platelets (possibly aggregating with v-WF), happen within the intra-hepatic small portal vein branches. This in turn may lead to the formation of platelet rich micro-thrombi, occluding these portal vein radicles. Such a process may occur in portal hypertension due to any cause and may be responsible for worsening of cirrhosis.

Liver stellate cells are the main source of ADAMTS-13 in the body¹⁰⁷. These stellate cells are located in the sub-endothelial space between hepatocytes and endothelial sinusoidal cells¹¹¹; i.e. at the level of the sinusoids. Hence, it is most likely that the lowest ADAMTS-13

concentration in the circulation will be at the pre-sinusoidal portal vein radicles in the liver. Selective portal vein radicles occlusion in NCIPH, suggests that important pathogenic factors may be operant in the gut-liver axis. In previous studies, over-representation of some intestinal disease (e.g. adult onset coeliac disease and ulcerative colitis) in a cohort of NCIPH patients, supports the above hypothesis³⁵. It has also been noted that, inflammatory cytokines stimulate ultra-large v-WF multimer release and also inhibit ADAMTS-13 synthesis^{112, 113}. These cytokines are elevated in the sera of patients with coeliac disease¹¹⁴. In our study, two NCIPH patients had adult new-onset coeliac disease, while one had skin arsenicosis (possibly secondary to arsenic contamination of ground water as has been reported from gangetic plains of India¹¹⁵) – both these factors have a potential to result in increase of v-WF levels^{112, 113, 116}, in the portal circulation.

Patients with cryptogenic cirrhosis served as disease controls in our study. These, by definition, are patients who do not have any evident cause for portal hypertension. Only 9 (of the 22) patients with cryptogenic cirrhosis underwent liver biopsy, this remains a limitation in our study. Cryptogenic cirrhosis remains a common mimic of NCIPH^{14, 15}, and any aetiology of cirrhosis can cause cryptogenic cirrhosis. In the current study, six patients with cryptogenic cirrhosis had severe ADAMTS-13 deficiency (Child's class A:1, Child's class B:2 and Child's class C:3).

At present, plasma ADAMTS-13 and v-WF assays lack adequate standardisation with lack of internationally recognised reference ranges^{106, 117}. In our current study, plasma ADAMTS-13 activity levels were more significantly decreased (in both NCIPH and cryptogenic cirrhosis) when assayed by collagen binding assay as compared to FRET assay. However, this inter-assay variability was not noted in healthy controls. This observation was also noted in a previous study on ADAMTS-13 levels in NCIPH patients from UK. This inter-assay

variability has also been observed in other group of patients (e.g. congenital thrombotic thrombocytopenic purpura and also other thrombotic micro-angiopathies)¹⁰⁶. The collagen binding assay (CBA) utilises full length of v-WF as a substrate, whereas the FRET assay utilises a 73 amino acid substrate containing ADAMTS-13 cleavage site (A2 domain of v-WF). Various structural changes, e.g. truncation of ADAMTS-13 protein, alterations in glycosylation, or binding of substances that obscure the attachment sites or alter the protein conformation; could lead to decrease in cleavage of the complete v-WF substrate but this is not detectable with the FRET substrate. The similarity of findings in the cryptogenic cirrhosis patients raises the possibility that there may be an overlap in pathogenesis with that of NCIPH, at least in India.

Deficiency of a metabolizing enzyme (ADAMTS-13); especially when accompanied by an increase in substrate (v-WF) can lead to exaggerated effects. This may lead to a highly exaggerated effect with platelet micro-thrombi formation and portal venular occlusion in patients with portal hypertension. ADAMTS-13 deficient individuals (congenital) may exist within the population who remain at increased risk of developing thrombotic micro-angiopathy. These individuals on being challenged by increased v-WF in the portal circulation, in response to gut-based stimuli (e.g. coeliac disease), may result in platelet micro-thrombi of the small portal venules. This can result in occlusion of these venules, thus manifesting as NCIPH.

We postulate that ADAMTS-13 – v-WF imbalance may also be equally important in patients with cirrhosis of any other aetiology. The sequence of events may be slightly different. Rising v-WF levels is noted in worsening cirrhosis patients and ADAMTS-13 deficiency also occurs late in the disease severity (Child's C)¹⁰³ - a consequence of decreased hepatic function, with advancing cirrhosis. Both decrease in ADAMTS-13 and increase in v-WF can predispose to

obstruction of intra-hepatic portal vein radicles in these patients with advanced cirrhosis. This is likely to profoundly and adversely affect the prognosis and natural history of the disease.

Future direction :

- Further larger studies exploring ADAMTS-13-v-WF imbalance in NCIPH and cirrhosis (and also other causes of portal hypertension) are needed.
- Role of this imbalance in natural history of portal hypertension disorders needs to be studied.
- Study the possible interventions to reverse ADAMTS-13-v-WF imbalance in portal hypertensive patients

OBJECTIVE 3

**{TO STUDY THE ASSOCIATED DISORDERS IN PATIENTS WITH
NCIPH}**

OBJECTIVE 3

**{TO STUDY THE ASSOCIATED DISORDERS IN PATIENTS WITH
NCIPH - STUDY OF GUT DISORDERS}**

INTRODUCTION

In western studies, coeliac disease is prevalent in 1% of the general population. In contrast, another Swedish study reported a 15 times higher prevalence in patients with cryptogenic cirrhosis¹¹⁸. ‘Cryptogenic’ chronic liver disease remains a common cause of portal hypertension in India¹⁴. In both prospective¹³ and retrospective¹⁵ studies from our center, we estimated that 39–48 % of patients with disease label of ‘cryptogenic cirrhosis’ after liver biopsy were diagnosed as idiopathic non cirrhotic intra-hepatic portal hypertension (NCIPH). NCIPH is a micro-angiopathy affecting the small intra-hepatic portal vein branches. Previously, in a study from UK, high prevalence of coeliac disease (16%) was documented in NCIPH patients awaiting liver transplant. Presence of coeliac disease was a prognostic indicator and determined liver transplant free survival in NCIPH patients¹¹⁹.

Recent studies have reported prevalence of coeliac disease in India of 0.3 to 1% in the general population¹²⁰. This study aims to ascertain prevalence of coeliac disease in portal hypertension patients with cryptogenic ‘cirrhosis’ and NCIPH.

PATIENTS AND METHODS

Ascertainment of cases and controls :

Patients with portal hypertension were prospectively and consecutively enrolled in the study after an informed consent. Patients with cryptogenic 'cirrhosis' served as cases and patients with hepatitis B/C related cirrhosis served as controls. Cirrhosis was presumptively diagnosed by clinical, biochemical and imaging features. Presence of portal hypertension was inferred with gastro-oesophageal varices and/or high gradient ascites.

Exclusion criteria :

- Hepatocellular carcinoma,
- Hepatic venous outflow tract obstruction
- Portal vein thrombosis at time of initial presentation
- Patients not providing informed consent
- Pregnant females/ Children

Before labelling as 'cryptogenic', all patients underwent a complete aetiological evaluation – H/O alcohol intake, documenting features of metabolic syndrome for presence of non-alcoholic fatty liver disease (e.g. body weight, body mass index, sugars and lipid profile), USG abdomen and doppler of portal venous inflow and hepatic venous outflow tract, serological markers for viral hepatitis (HBsAg and HCV antibody), auto-antibodies for autoimmune hepatitis (AMA, SLA, LKM, ANA etc.) and tests to rule out iron/ copper overload (serum ceruloplasmin and iron studies). Patients having cirrhosis and portal

hypertension, but a negative non-invasive aetiology evaluation for cause of liver disease, were diagnosed as cryptogenic 'cirrhosis'.

In patients with cryptogenic 'cirrhosis', liver biopsy (with hepatic venous pressure gradient (HVPG)) was obtained as and when feasible. Standard definition of idiopathic non-cirrhotic intra-hepatic portal hypertension (NCIPH) was used³:

1. Portal hypertension – evidenced by gastroesophageal varices on upper gastrointestinal endoscopy/ splenomegaly
2. Patent portal vein (inflow) and hepatic venous outflow tract on a Doppler scan of abdominal vessels
3. Absence of known aetiology of chronic liver disease – e.g. Hepatitis B/ C virus, alcohol intake etc.
4. Absence of cirrhosis or advanced fibrosis (bridging fibrosis) on liver biopsy
5. Absence of any aetiology known to cause portal venous lesions similar to NCIPH – e.g. sarcoidosis, congenital hepatic fibrosis, primary biliary cirrhosis, schistosomiasis

Patients with hepatitis B/ C related cirrhosis and portal hypertension served as controls for the study.

Investigation into coeliac disease :

- a. *Serology* : For the study, serum IgA tissue transglutaminase (tTG) antibody was done in all cases and controls. For this, we used a commercially available solid-phase enzyme immunoassay kit employing human recombinant antigen (AESKULISA Celichek, Germany). Based on the printed instructions the interpretation was made :
 - tTG antibody titres < 15 U/ml : negative,
 - tTG antibody titer between 15-20 U/ml : borderline positive

- tTG antibody titer >20 U/ml : positive.

For ease of analysis, in our study, we interpreted titres > 20 U/ml as positive for coeliac disease and \leq 20 U/ml as negative.

b. *Symptoms* : Symptom score by Kurppa et al¹²¹ was used for grading of symptoms pertaining to coeliac disease in patients who were tTG antibody positive :

- None
- Mild : occasional flatulence, abdominal pain, diarrhoea, tiredness, belching or joint pains
- Moderate : symptoms more persistent and disturbing normal life
- Severe : significant daily symptoms disturbing normal life or excessive weight loss.

c. *Duodenal histology* : Multiple duodenal biopsies from the 2nd part of duodenum (D20) were obtained depending on safety and feasibility. Duodenal mucosal histological changes were assessed by a single GI-pathologist, blinded to the clinical details.

Following features (of coeliac disease) were documented :

- Raised intra-epithelial lymphocytes,
- Crypt hyperplasia,
- Villous atrophy
- Lamina propria inflammation and
- Sub-epithelial fibrosis.

d. *Grading of duodenal histology* : Marsh-Oberhuber grading¹²² was used for grading duodenal mucosal histology in tTG antibody positive patients :

- Marsh 0: Normal
- Marsh I: raised intraepithelial lymphocytes (IEL)

- Marsh II: Crypt hyperplasia
- Marsh III: villous atrophy.
 - Marsh IIIA : mild villous atrophy
 - Marsh IIIB: moderate / subtotal villous atrophy
 - March IIIC: Severe villous atrophy

Presence of Coeliac disease was defined by tTG antibody positive and duodenal biopsy showing at-least raised IELs (Oslo definitions¹²³).

Gut permeability :

Lactulose-Mannitol (L/M) assay was used to assess intestinal permeability in a subset of the study patients.

The test assesses the relative % timed excretion of the ingested lactulose and mannitol in the urine :

$\text{L/M ratio} = \% \text{ Lactulose} / \% \text{ Mannitol}$

An L/M ratio of > 0.07 was interpreted as positive and designated as increased gut permeability.

Assay for cardiolipin antibody :

In a subset of study patients, serum cardiolipin antibodies (all IgM, IgG and IgA) were tested.

Enzyme immunoassay (Varelisa kit) was used for the purpose. Interpretation :

- Titres < 10 U/ml : Negative,
- Titres between 10 - 15 U/ml : Equivocal
- Titres > 15 U/ml : Positive.

Assessing severity of liver disease :

Child's score was used to grade severity of liver disease. Classification used was :

- Early chronic liver disease : Child's class A
- Late chronic liver disease : Child's classes B or C

Anti-tTG antibody by different commercial kits :

Stored serum samples from the study patients was subjected two other commercial tTG test kits - EUROIMMUN (EUROIMMUN AG, Germany; ≥ 20 relative units/ml as +ve) and INOVA QUANTA Lite™ (INOVA diagnostics, U.S.A; ≥ 20 units/ml as +ve).

Follow up evaluation after gluten free diet in patients with coeliac disease

All patients diagnosed with coeliac disease, were educated by a dietician and prescribed a gluten-free diet. These patients were then followed up till the end of this study. Various disease parameters were noted on follow up after being on gluten free diet :

- Symptom score,
- Titres of tTG antibody
- Change in duodenal histology
- Alteration in intestinal permeability and
- Severity of liver disease

Statistical analysis :

Continuous variables were expressed as median (range) and discrete variables as numbers (percentage). Unpaired and paired non-parametric tests were used as needed, to compare continuous variables in the study groups and demonstrate changes at follow up. Fisher's exact

test or chi squared test were used for comparing discrete variables across groups. P-value of ≤ 0.05 was considered as statistically significant. The study was a-priori approved by the Institutional review board and ethics committee.

OBJECTIVE 3

**{TO STUDY THE ASSOCIATED DISORDERS IN PATIENTS WITH
NCIPH - STUDY OF GUT DISORDERS }**

RESULTS

120 portal hypertensive patients enrolled into the study

- Cases (cryptogenic cirrhosis) : 61
 - NCIPH : 14

- Controls : 59
 - Hepatitis B : 39

 - Hepatitis C: 20

Twenty patients with cryptogenic ‘cirrhosis’ underwent liver biopsy. 14 (70%) of these patients were diagnosed as NCIPH and rest of the 6 had ‘true’ cryptogenic cirrhosis. The biopsies were adequate as per Hepato-pathologist. Various histological features noted in NCIPH were : portal vein ectasia /sinusoidal dilatation (11), minimal peri-portal fibrosis (4), peri-sinusoidal fibrosis (3) and peri-venular fibrosis (1).

Control patients did not undergo liver biopsy.

Table 7 depicts the demographics and baseline laboratory investigations in the study groups.

Table 7 : Demographics and baseline laboratory parameters in the study patients with comparison of cases and controls

Parameter		Cases (n=61)	Controls (n=59)	p-value
Age (years)		42(7-67)	46(21-67)	0.3
Sex (M:F)		46:15	53:6	0.05
Presentation	Jaundice	13	12	
	Ascites	28	31	
	Encephalopathy	7	6	
	Variceal bleed	22	20	
Serum total bilirubin (mg/dl)		1(0.4-30.8)	1.2(0.4-17.6)	0.85
Serum total protein (g/dl)		7.7(5.4-9.1)	7.6(5.2-10)	0.78
Serum albumin (g/dl)		3.6(1.8-5.2)	3.1(1.6-5.1)	0.04
International Normalised Ratio for Prothrombin time		1.2(0.9-2.9)	1.3(0.9-3.4)	0.01
Serum Creatinine (mg/dl)		0.9(0.5-1.6)	1(0.4-6.1)	0.002
Haemoglobin (g/dl)		10.6(5.2-15.1)	11.2(6.1-17.3)	0.26
Platelet count (X10 ⁹ /cmm)		0.68(0.2-2.6)	0.67(0.06-5.5)	0.5
Child's Class (A/B/C)		39/15/7	29/19/11	0.25
Child's score		5(5-12)	7(5-14)	0.01

Anti-tTG antibody in cases and controls :

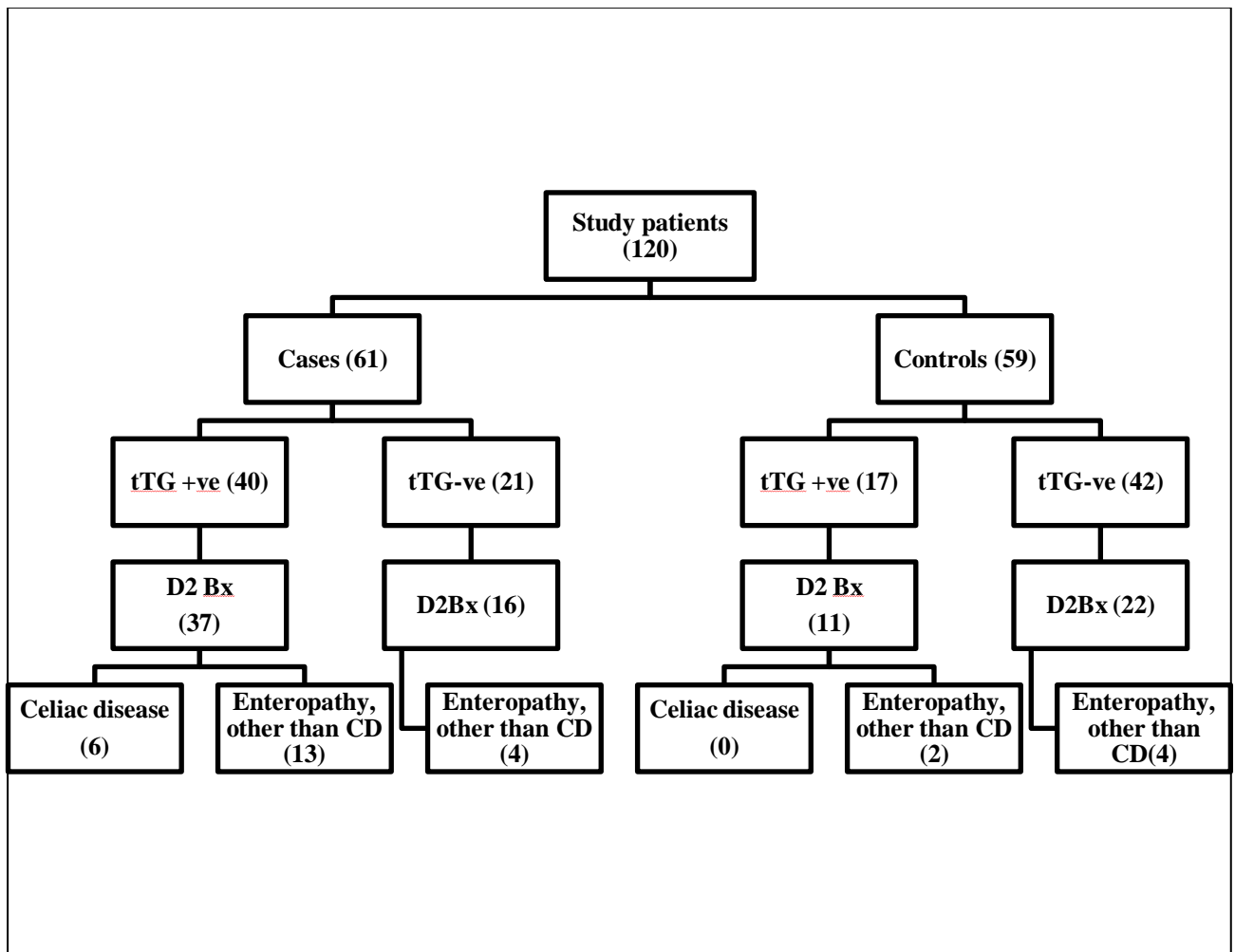
Prevalence of anti-tTG antibody positive result was significantly more in cases as compared to controls (66% v/s 29%; $p < 0.0001$). This difference in tTG antibody positivity was true in both early and late chronic liver disease.

tTG +ve result	Cases (61)	Controls (59)	P-value
Early chronic liver disease	22/ 39	7/ 29	0.02
Late chronic liver disease	19/ 22	10/ 30	<0.001

The anti-tTG antibody titres were also higher in cases (31, 0-300 U/ml) as compared to controls (7.5, 0-300 U/ml; p -value <0.001) and was also true irrespective of the severity of liver disease. Anti-tTG antibody titre of >100 U/ml was noted in six cases and in one control (p -value : 0.11).

Coeliac disease diagnosis in study patients (Figure 13) :

Based on anti-tTG antibody test and duodenal histology results, coeliac disease was diagnosed in 6 cases (Marsh IIIB : 1; Marsh IIIA: 3; March I: 2) as compared to none in controls.



tTG: tissue transglutaminase; D2 Bx : Biopsy from 2nd part of duodenum; CD : Coeliac disease

Figure 13 : Flow chart showing results of coeliac serology (anti-tissue transglutaminase antibody) and duodenal histology (D2 Bx) in study patients.

Coeliac disease patients :

Parameter	Coeliac disease (n=6)
Sex (M:F)	5:1
Age (years)	46 (34-57)
Residence (East/ West/South/North)	3/1/1/1
NCIPH	2
Severity of liver disease (Early/ Late)	5/1
Increase gut permeability	3
Classical symptoms present	1
Iron deficiency anaemia	5
Vitamin B12 deficiency	1

Follow up of coeliac disease patients :

Three patients were followed up for a median of 25 (12-58) months on gluten free diet. Anti-tTG antibody became negative (2) or showed a significant decrease in titer (1). The duodenal histology (IIIA → 0 and IIIA → 1) improved in patients in whom tTG became negative.

Improvement in intestinal permeability (repeat testing available in two patients) was noted in one patient. The severity of liver disease and platelet counts in these patients remained unchanged on follow up.

Non-specific enteropathy in study patients :

Baseline duodenal histology was available in 86 study patients (53 cases and 33 controls), Table 8.

Mucosal architecture alteration (villous atrophy with crypt hyperplasia) was significantly more common in cases as compared to controls. The same was true in early chronic liver disease sub-group as well. Non-specific lamina propria inflammation was also significantly more common in cases as compared to controls.

In a subset of late chronic liver disease patients, due to limited numbers, there was no significant difference in duodenal histology in cases and controls.

Table 8 : Duodenal mucosal biopsy in portal hypertensive subjects who had cryptogenic chronic liver disease (cases) or hepatitis B or C related cirrhosis (controls)

Variables	In all study patients who had duodenal biopsy			In Child's A patients who had duodenal biopsy		
	Cases (n=53)	Controls (n=33)	p-value	Cases (n=34)	Controls (n=20)	p-value
Crypt hyperplasia	19	6	0.09	13	2	0.03
Villous atrophy* (mild/moderate)	18/3	6/0	0.05	12/3	2/0	0.01
Raised IELs	6	1	0.17	5	1	0.4
Lamina propria inflammation*(mild/moderate)	34/13	22/1	0.04	20/12	12/0	0.003
Fibrosis	5	2	0.6	3	1	1

IEL : Intra-epithelial lymphocytes

*p-value assesses the probability of presence of these histology features

Enteropathy in NCIPH patients :

Coeliac disease was diagnosed in 2 of the 14 (14%) NCIPH patients. Table 9 summarises details pertaining to enteropathy in these 14 NCIPH patients.

Table 9 : Coeliac serology (anti-tTG antibody) and mucosal biopsy (from 2nd part of duodenum) patients with idiopathic non-cirrhotic intra-hepatic portal hypertension (NCIPH) and compared to hepatitis B/ C related cirrhosis (controls)

Parameters		NCIPH (n=14)	Controls (n=59)	p-value
Coeliac serology (anti-tissue transglutaminase antibody)	Anti-tTG positive; n (%)	6 (43%)	17 (29%)	0.35
	Anti-tTG titres (U/ml)	11 (0-300)	7.5 (0-300)	0.38
	Anti-tTG titre >100 U/ml (n)	1	1	0.36
Duodenal histology (NCIPH: 12; Controls : 33)	Crypt hyperplasia	4	6	0.4
	Villous atrophy	5	6	0.13
	Raised IELs	2	1	0.17
	Lamina propria inflammation	11	23	0.2
	Fibrosis	0	2	1

NCIPH : idiopathic non-cirrhotic intra-hepatic portal hypertension; tTG: tissue transglutaminase

Gut permeability in study patients :

Increase in gut permeability (i.e. L/M ratio > 0.07) was noted in nine of the 30 patients with cryptogenic 'cirrhosis' tested. Eight of these patients were anti-tTG antibody positive. Duodenal microscopy revealed mild villous atrophy in six patients, moderate villous atrophy in two patients and one patient with a normal histology.

Anti-Cardiolipin antibodies in study patients :

IgM, IgA and IgG anti-cardiolipin antibodies were tested in 28 cases and 32 controls. The results were not significantly different in the groups.

tTG antibody test by other commercial kits :

Stored sera samples (52 cases and 40 controls) were available for re-testing in a subset. Table 10 depicts the intense variability noted in the three commercial kits for anti-tTG antibody measurement.

Fifteen (25%) cases and 12 (20%) controls had anti-tTG antibody positivity by at least 2 of the 3 kits used.

Table10 : Results of anti-tTG antibody testing by various ELISA kits in chronic liver disease study patients.

	AESKULISA	EUROIMMUN (positive/negative)	INOVA (positive/negative)
Cases (n=52)	Positive (33)	13/20	11/22
	Negative (19)	3/16	1/18
Controls (n=40)	Positive (12)	9/3	6/6
	Negative (28)	6/22	2/26

AESKULISA : AESKULISA Celichek, Germany; ≥ 20 U/ml as positive

EUROIMMUN : EUROIMMUN AG, Germany; ≥ 20 relative units/ml as positive

INOVA : INOVA diagnostics, USA; ≥ 20 units/ml as positive

OBJECTIVE 3

{TO STUDY THE ASSOCIATED DISORDERS IN PATIENTS WITH
NCIPH - STUDY OF GUT DISORDERS }

DISCUSSION

In our present study, we note that coeliac disease is more prevalent in cryptogenic cirrhosis patients (10%) when compared to hepatitis B/C related cirrhosis (0/59). In NCIPH the prevalence of celiac disease was 14%. This association of NCIPH and cryptogenic chronic cirrhosis with coeliac disease has also been previously reported from India¹²⁴.

Coeliac disease patients showed improvement in both anti-tTG antibody titres and duodenal histology with the institution of gluten free diet. This improvement was not accompanied with any improvement in liver disease and portal hypertension severity on follow up. This may be secondary to inadequate time of follow up.

Besides higher prevalence of coeliac disease, cryptogenic cirrhosis patients had much higher prevalence of duodenal mucosal architectural changes and lamina propria inflammation as compared to Hepatitis B/C cirrhosis patients. Similar alterations noted even in early chronic liver disease, suggests the possible role of duodenal mucosal changes in the pathogenesis of these cryptogenic cirrhosis.

The exact cause of duodenal mucosal histological changes is unclear. These alterations can be occurring secondary to tropical sprue/ enteropathy, small intestinal bacterial overgrowth and/ or gluten sensitive enteropathy^{125, 126}. Portal hypertensive duodenopathy may also show similar histological alterations. This possibility remains to be excluded especially due to

absence of raised IELs in our patients¹²⁷. Antibiotic usage can influence duodenal histology and the same was not very adequately documented in the study. This remains a limitation.

Anti-tTG antibody testing by human IgA based testing is highly sensitive and specific and is the initial recommended test to diagnose coeliac disease. This can also be easily to standardised^{128, 129}. High inter-test variability and unusually high prevalence (48%) of positive tTG antibody in our patients suggests a possibility of high false positivity in this population. It has been previously noted that high prevalence of false positive anti-tTG antibody occurs with advancing liver disease¹³⁰. Anti-endomysial antibody may be helpful to clarify this, but was not performed in this study. This is a limitation.

NCIPH is termed as an Indian disease and is commonly described from India¹². One of the reasons of high prevalence in India could be the various enteropathies present in this part of the world. Present study shows that 5/ 14 NCIPH patients had enteropathy (2 had coeliac disease and 3 had enteropathy with unclear cause). Enteropathy may drive a pro-thrombotic milieu inside the liver by accentuating the imbalance of primary haemostatic mechanisms (ADAMTS-13 deficiency and increased v-WF levels). This in turn can lead to portal venous occlusion in NCIPH¹⁰⁴.

Cryptogenic ‘cirrhosis’ is a close mimic of NCIPH¹⁴. It requires liver biopsy to confirm the diagnosis of NCIPH. As biopsy is not always feasible, we recruited patients with cryptogenic ‘cirrhosis’ as cases for present study. In the present study, as was noted in our previous studies, large proportion (70%) of patients with cryptogenic ‘cirrhosis’ were diagnosed as NCIPH after a liver biopsy.

Coeliac disease is associated with portal hypertension of varied cause – cryptogenic (present study), autoimmune hepatitis, cholestatic cirrhosis, NCIPH (present study) or Budd Chiari

syndrome¹³¹. The present study demonstrates cryptogenic cirrhosis and NCIPH as the most common liver disease association with coeliac disease¹²⁴.

In conclusion :

- It is needed to investigate for latent/ symptomatic coeliac disease in all patients with cryptogenic portal hypertension
- Higher prevalence of enteropathy (celiac and non-specific) in patients with cryptogenic cirrhosis suggests a possible role in pathogenesis in these patients.
- Further studies evaluating the cause for this enteropathy needs to be done.
- Further studies are required to elucidate role of duodenal mucosal alteration in development/ progression of portal hypertension in NCIPH.

OBJECTIVE 3b

**{TO STUDY THE ASSOCIATED DISORDERS IN PATIENTS WITH
NCIPH - STUDY OF OTHER DISORDERS }**

OBJECTIVE 3b

{TO STUDY THE ASSOCIATED DISORDERS IN PATIENTS WITH
NCIPH - STUDY OF OTHER DISORDERS }

INTRODUCTION

Idiopathic non-cirrhotic intra-hepatic portal hypertension (NCIPH) is a common and important cause of portal hypertension in India¹⁴. It is also commonly known as non-cirrhotic portal fibrosis in India or idiopathic portal hypertension in Japan.

NCIPH is characterised by an isolated chronic micro-angiopathy affecting the small intra-hepatic portal vein radicles. This suggests the involvement of gut derived insults in driving this disease¹⁸. We have previously reported higher prevalence of gut disorders (celiac disease and ulcerative colitis) in NCIPH patients from UK and from India. In previous study, we have also noted low levels of plasma ADAMTS-13 {a disintegrin and metalloproteinase with thrombospondin type 1 motif, member 13; a von Willebrand factor (v-WF) cleaving protease}, in spite of well-compensated liver function. Alteration in ADAMTS-13 to v-WF balance can predispose to platelet-micro-thrombi formation in small portal venules in response to various gut derived insults. This provides a mechanistic explanation for the development of isolated intra-hepatic portal venous micro-angiopathy of NCIPH. Chronic ingestion of arsenic contaminated ground water is yet another example of gut derived insult¹³². Arsenic ingestion has been shown to predispose to NCIPH and this association has been reported from Eastern parts of India^{52, 54, 56}. Autopsy study revealed a higher hepatic arsenic content in patients with NCIPH as compared to those with cirrhosis⁵². Animal studies have shown chronic arsenic ingestion can lead to significant hepatic fibrosis⁵⁸. In the reports from the West, arsenicosis has been reported to be secondary to use of variety of arsenic preparation (e.g. oral Fowler's solution) especially to treat psoriasis^{133, 134}.

The aim of this study was to evaluate evidence of chronic arsenic toxicity in patients with NCIPH and also assess for groundwater arsenic contamination.

PATIENTS AND METHODS :

We employed a case-control study design to assess the association of arsenicosis with NCIPH. In the study, we compared NCIPH patients (cases) to hepatitis B/C related cirrhosis patients with portal hypertension (disease controls) and healthy controls. The study subjects were recruited only after obtaining informed consent for the study.

Recruitment of cases and controls

NCIPH was diagnosed as per published criteria, as follows:

1. Portal hypertension – evidenced by gastroesophageal varices on upper gastrointestinal endoscopy/ splenomegaly
2. Patent portal vein (inflow) and hepatic venous outflow tract on a Doppler scan of abdominal vessels
3. Absence of known aetiology of chronic liver disease – e.g. Hepatitis B/ C virus, alcohol intake etc.
4. Absence of cirrhosis or advanced fibrosis (bridging fibrosis) on liver biopsy
5. Absence of any aetiology known to cause portal venous lesions similar to NCIPH – e.g. sarcoidosis, congenital hepatic fibrosis, primary biliary cirrhosis, schistosomiasis

Twenty seven consecutive patients diagnosed with NCIPH were recruited for the study. All cases had liver biopsies performed - trans-jugular-18; percutaneous-6 and per-operative-3 (during splenorenal shunt surgery). The route was decided by a clinician.

The liver biopsies were termed as adequate by the Hepato-pathologist :

	Trans-jugular (18)	Percutaneous (6)
Number of cores	3 (2-9)	3 (2-3)
Size of biggest core (mm)	11 (4-19)	13 (8-13)
Number of portal tracts	8 (5-15)	10 (7-20)

The liver biopsy findings in 27 NCIPH patients were :

- Portal fibrosis: 19
 - Mild : 17
 - Moderate : 2
- Mild Peri-sinusoidal fibrosis : 2
- Incomplete septal cirrhosis : 2
- Mild sinusoidal dilatation : 13
- Portal vein ectasia with extension into parenchyma : 8
- Atretic portal venules : 2
- Nodular regenerative hyperplasia : 1

Disease controls comprised of prospectively and consecutively enrolled hepatitis B or C related cirrhosis patients (diagnosed as per endoscopy, radiology and laboratory findings).

Patients who were post liver transplant, had hepato-cellular malignancy or had an acute worsening were excluded. Healthy volunteers served as healthy controls. The disease and healthy controls were from similar locality as the cases.

All subjects underwent a clinical evaluation and relevant laboratory evaluation (done as per case to case basis). Liver disease severity was assessed by Child's score and liver fibrosis was assessed by

serum aspartate amino-transferase to platelet ratio index (APRI)¹³⁵. Serum vitamin B12 levels (Normal range: 200-950 pg/ml) were measured by electrochemiluminescence technique (Roche E170 modular system). Socioeconomic status of the study subjects was evaluated by modified Kuppuswamy score, utilising an Indian consumer price index of August 2011, i.e. 194^{136,137}.

Evaluation for arsenicosis

In all study subjects we measured nail arsenic level by a previously described methodology¹³⁸.

Methodology in brief :

Obtain clippings from finger + toe nails → store in labelled polyethylene bags at 4°C → remove the dirt manually → wash using an ultrasonic bath with distilled water → wash in acetone → dry overnight → digest by microwave → measure arsenic levels by inductively coupled mass spectrometry. Quantitation was done by using internal standards.

Normal levels of nail arsenic : 0.02-0.5 mg/kg of nail. Nail arsenic levels >1.5 mg/kg of nail were considered high and thought to indicate over-exposure to arsenic in the last 9 months¹⁰⁵.

All study cases and disease controls also underwent a thorough dermatological assessment looking for skin changes of arsenicosis. The dermatologist was unaware of the nail arsenic levels. Skin arsenicosis was defined as typical skin lesions

- Hyperpigmentation of the unexposed body parts
- Hypopigmentation of the unexposed body parts
- Keratosis of the palms/soles¹⁰⁵.

Evaluation for ADAMTS-13-v-WF imbalance in NCIPH patients with arsenicosis

We studied plasma activity of ADAMTS-13 and of v-WF in patients with NCIPH (cases only). As was previously described, ADAMTS-13 activity was estimated in citrated platelet-poor plasma by an in-house collagen binding assay¹³⁹. v-WF activity was also assessed by collagen binding assay in

citrated plasma by a commercially available ELISA (Hyphen- biomed #RK038A, France). Normal range : plasma ADAMTS-13 activity - 55-160% and plasma v-WF activity - 50-150%. Ratio of v-WF:ADAMTS-13 was calculated and value of ≥ 3 was considered as suggesting ADAMTS-13-v-WF imbalance.

Statistical analysis

All discrete variables were reported as numbers (percentage) and continuous variables as median (range). Non-parametric tests were used for comparison and a p-value of <0.05 was considered as significant. The study was approved by institutional review board and ethics committee.

OBJECTIVE 3b

{TO STUDY THE ASSOCIATED DISORDERS IN PATIENTS WITH
NCIPH - STUDY OF OTHER DISORDERS }

RESULTS

Consecutive patients from the out-patient liver clinic fulfilling the inclusion and exclusion criteria were recruited.

- NCIPH : 27

- Disease controls : 25
 - Hepatitis B : 21

 - Hepatitis C : 4

- Healthy controls : 25

Demographic data of the 3 groups is depicted in table 11.

Most subjects (in all the study groups) were from eastern parts of India and belonged to middle/ lower socioeconomic class. On personal interview, none of the study subjects resided next to a mining area (known to cause groundwater arsenic contamination) or were on long term complementary medications (known to arsenic contamination).

Table 11 : Demographic details of study patients

Parameter		NCIPH (n=27)	Hepatitis B/C cirrhosis (n=25)	Healthy controls (n=25)
Age (years)		35 (15-64)	36 (17-56)	40 (20-77)
Sex		19:8	23:2	17:8
States of residence	West Bengal / Bangladesh	7/3	7/13	13/1
	Bihar/Chhattisgarh/Jharkhand	7	2	3
	Other states of India	8	3	8
Socioeconomic class*	Upper	4 (16%)	1 (4%)	1 (8%)
	Middle	16 (64%)	19 (83%)	4 (31%)
	Lower	5 (20%)	3 (13%)	8 (61%)

NCIPH : Idiopathic non-cirrhotic intra-hepatic portal hypertension

*Socioeconomic class data available in 25 cases, 23 disease controls and 13 healthy controls.

Baseline liver disease status in cases and disease controls :

Table 12 depicts the laboratory parameters in cases and disease controls. Platelet counts in these groups were :

	NCIPH	Disease controls
Normal Platelet count	1	3
Mild-moderate thrombocytopenia ($>50000/\text{cmm}$)	12	13
Severe thrombocytopenia ($<50000/\text{cmm}$)	14	9

Liver disease, as evidenced by Child's score, was significantly more severe in disease controls as compared to cases.

Six NCIPH patients had altered v-WF:ADAMTS-13 ratio of >3 , suggesting imbalance favouring thrombosis. Low serum vitamin B12 level was noted in 5 (19%) NCIPH patients, compared to zero in disease controls.

Table 12 : Baseline laboratory assessment of liver disease in patients with portal hypertension (27 cases with NCIPH and 25 patients with hepatitis B/C related cirrhosis)

Parameters	NCIPH (n=27)	Hepatitis B/C cirrhosis (n=25)	p-value
Haemoglobin (g/dl)	12.3 (6.8-15.1)	12.7 (8.8-14.6)	0.4
Platelet count (x10 ⁵ /cmm)	0.49 (0.17-1.78)	0.65 (0.14-1.57)	0.9
Serum bilirubin (mg/dl)	1.3 (0.4-4)	1 (0.4-2.9)	0.3
Serum albumin (mg/dl)	3.9 (2.9-5.5)	3.5 (2.1-4.7)	0.07
International Normalised Ratio	1.2 (1-1.4)	1.2 (1-1.6)	0.005
Oesophageal Varices (small/large)	4/22*	8/17	-
Child's score	5 (5-6)	5 (5-9)	0.002
APRI	2 (0.6-4.7)	2.2 (0.5-11.4)	0.3
HVPG (mm Hg) [#]	7 (3-12)	-	
Serum vitamin B12 (pg/ml) [^]	414 (107-1128)	808 (278-1833)	0.001
ADAMTS-13 activity (%) ^{&}	55.5 (39-86)	-	-
v-WF activity (%) ^{&}	260 (135-484)	-	-
v-WF:ADAMTS-13 ratio ^{&}	4.1 (2.3-8.5)	-	-

NCIPH : Idiopathic non-cirrhotic intra-hepatic portal hypertension, APRI : Aspartate aminotransferase to Platelet ratio index, HVPG : Hepatic venous pressure gradient; ADAMTS-13: a disintegrin and metalloproteinase with thrombospondin type 1 motif, member 13; v-WF: von-Willebrand factor

* 1 patient had no varices, but had spleno-renal collaterals on ultrasonography

[#]HVPG was done in 13 NCIPH cases and none of the disease controls. HVPG was ≤5 mm Hg in 2 patients and was >5 mm Hg in 11 patients

[^]Serum vitamin B12 assay was available in 26 NCIPH patients and 12 patients with Hepatitis B/C cirrhosis

[&]ADAMTS-13 and v-WF activity was available in 8 NCIPH patients {Child's score of these 8 patients was 5 (in 7) and 6 (in 1 patient)} and none of the controls.

Arsenic levels in nails :

Arsenic levels in nail clippings were (Figure 14) :

	NCIPH	Disease controls	Healthy control
Nail arsenic level (mg/kg)	0.12 (0.023-2.24)	0.15 (0.01-0.64)	0.1 (0.02-0.39)
p-value	-	0.67	0.74

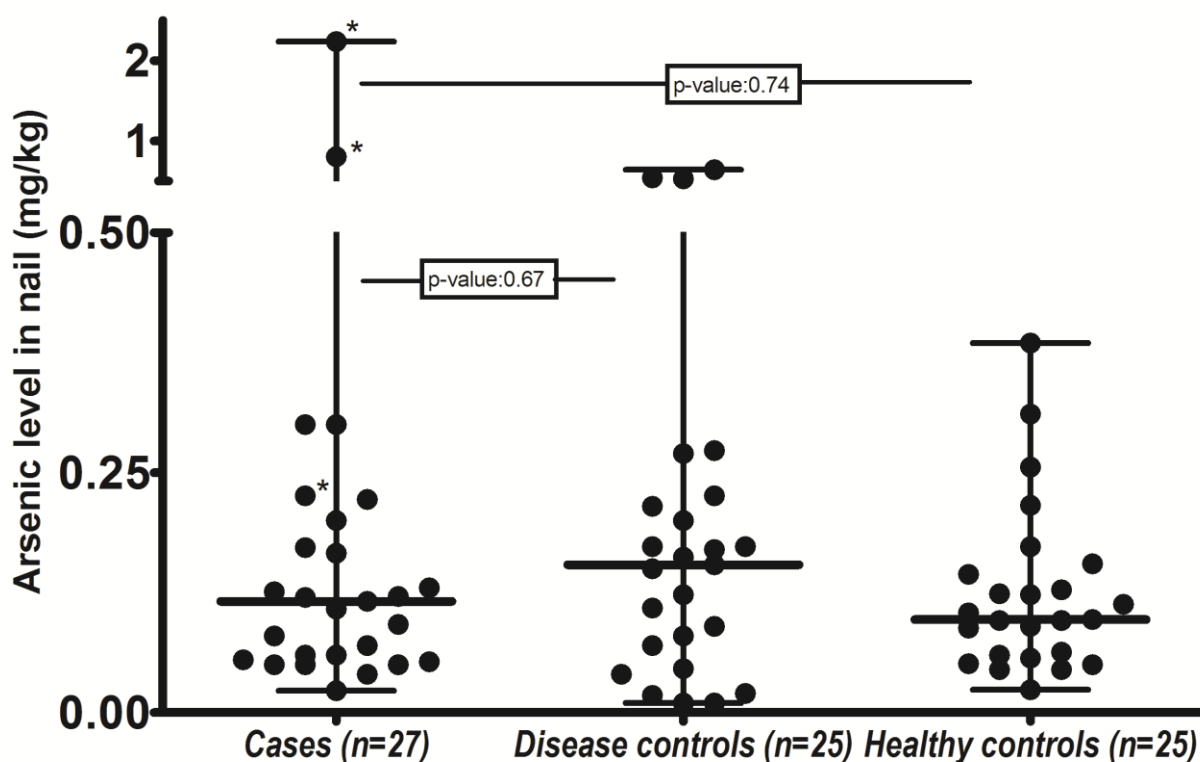


Figure 14 : Arsenic level, as measured by inductively coupled mass spectroscopy, in nail compared in the various study groups. The nail arsenic levels in three NCIPH patients with skin arsenicosis are marked with asterisk (*).

Nail arsenic levels showed no correlation to platelet count, APRI score, Child's score and HVPG in NCIPH or disease controls.

Two West-Bengal patients with NCIPH and three Bangladeshi patients (disease controls) had raised (i.e. > 0.5 mg/kg of nail) nail arsenic levels. None in the healthy control group had raised nail arsenic level.

Only one NCIPH patient, compared to none in both the control groups, had nail arsenic level of > 1.5 mg/kg.

Skin changes of arsenicosis :

Figure 15 shows skin changes of arsenicosis (palmar keratosis with hyperpigmentation). Three NCIPH patients showed similar skin changes which were highly suggestive of arsenicosis. None of the disease or healthy controls showed these changes (p-value : 0.2), Table 13.

The skin changes noted were :

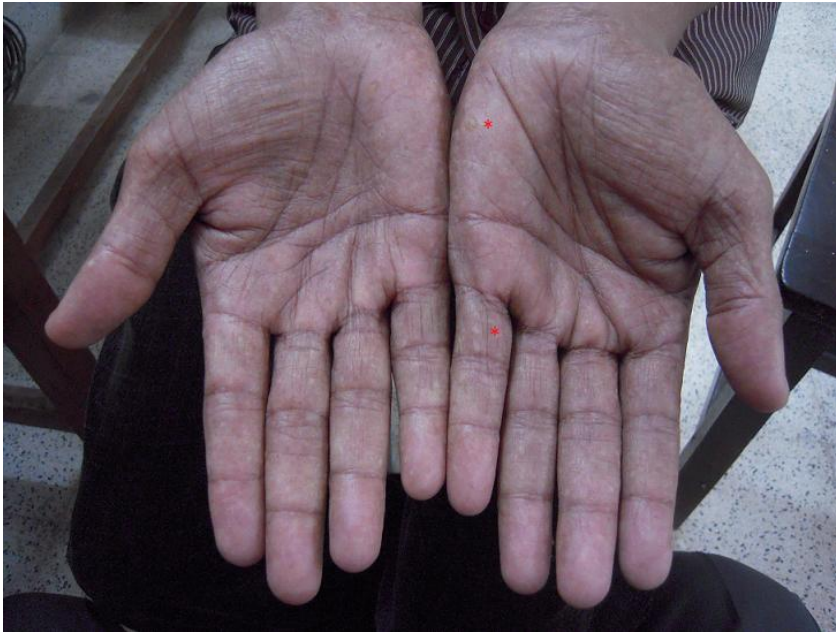- Predominant patchy hypo/ hyper pigmentation restricted to the trunk
- punctuate keratosis mainly involving the palms.
- Extensive keratosis involving the feet was seen in one patient.

Nail arsenic levels in these three NCIPH patients with arsenicosis involving the skin were - 0.23, 0.8 and 2.24 mg/kg of nail.

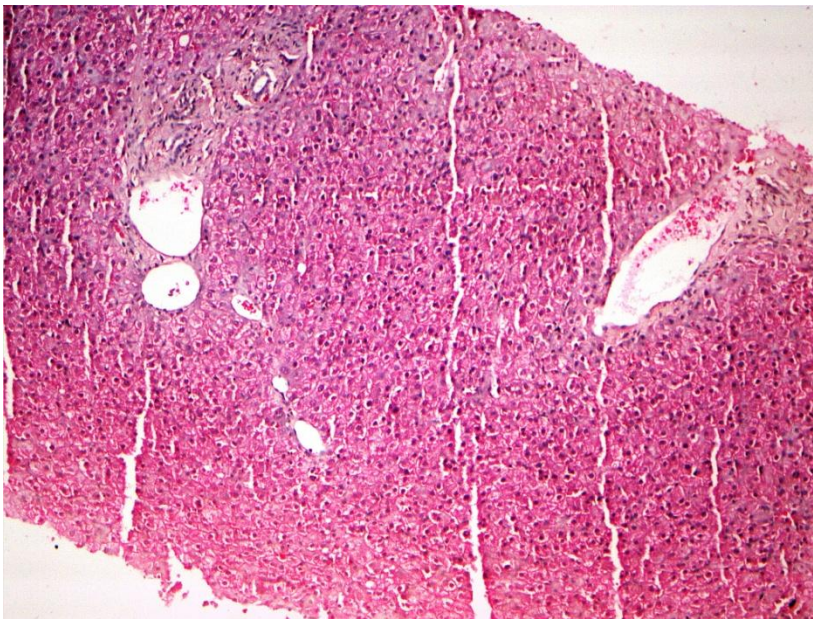
Table 13. Investigations into skin and nail arsenicosis in study patients

Skin changes of arsenicosis	Nail arsenic content (mg/kg)	NCIPH (n=27)	Hepatitis B / C cirrhosis (n=25)	Healthy controls (n=25)
Present	≤ 0.5	1 [*]	0	0
	0.5-1.5	1 [#]	0	0
	≥ 1.5	1 [#]	0	0
Absent	≤ 0.5	24	22	25
	0.5-1.5	0	3 [*]	0
	≥ 1.5	0	0	0

NCIPH : Idiopathic non-cirrhotic intra-hepatic portal hypertension; Patients from Bangladesh (*) and West Bengal (#).



Panel A



Panel B

Figure 15 : Typical skin changes of chronic arsenicosis (keratosis of the palms marked by red asterisk *) (Panel A) and liver biopsy depicting portal tracts with portal venule ectasia (Haematoxylin-Eosin10x; Panel B) in a 46 yr male with NCIPH.

Details of patients with skin arsenicosis :

Three NCIPH patients with skin arsenicosis belonged to Bangladesh (n=1) or West Bengal (n=2).

Parameters	NCIPH patient with skin arsenicosis (n=3)
Sex (M:F)	3:0
Age (years)	46 (40-54)
Residence (WB/ Bangladesh)	2/1
Presentation	Haematemesis : 1 Hypersplenism : 2
Duration of symptoms (months)	24 (12-36)
Child's class at presentation (A/B/C)	3/0/0
F/H/O liver disease (Y/N)	0/3
Liver biopsy findings	Mild portal fibrosis : 2 Sinusoidal dilation : 2 Portal venule ectasia : 1
Hepatic venous pressure gradient	7 mm Hg (n=1)

Comparison of NCIPH patients with/ without arsenicosis

Table 14 compares severity of various parameters including severity measures of liver disease/ portal hypertension in NCIPH patients with/ without arsenicosis.

The nail arsenic levels as expected, were significantly elevated in NCIPH patients with skin arsenicosis (Table 14).

Table 14 : Baseline details of NCIPH patients with or without skin arsenicosis

	NCIPH patients with skin arsenicosis (n=3)	NCIPH patients without skin arsenicosis (n=24)	p- value
Age (years)	46 (40-54)	33 (15-64)	0.016
Male : Female	3:0	16:8	0.5
From lower socioeconomic class[#]	2 (67%)	11(50%)	1
Residents of W. Bengal / Bangladesh	3	7	0.02
Presentation with haematemesis	1	13	0.6
Platelet counts (x10⁵/cmm)	0.6 (0.4-0.9)	0.49 (0.17-1.8)	0.9
Child's score	5 (5-6)	5 (5-6)	0.4
AST – Platelet Ratio Index	1.1 (0.9-2.6)	2.2 (0.6-4.7)	0.4
Moderate portal/peri- sinusoidal fibrosis on liver biopsy	0	6	0.5
Nail Arsenic level (µg/kg)	0.8 (0.2-2.2)	0.1 (0.02-0.3)	0.003
Hepatic venous pressure gradient (mm Hg)*	7	7 (3-12)	1

[#]Socioeconomic class data was not available in 2 NCIPH patients without skin arsenicosis

*Hepatic venous pressure gradient available in 1 NCIPH patient with skin arsenicosis and 12 NCIPH patients without skin arsenicosis.

Analysis of groundwater for arsenic contamination :

The water arsenic levels were measured in two NCIPH patients who brought groundwater samples from wells (used as drinking water) located near their local residence.

The acceptable arsenic level in drinking water as per WHO guidelines is < 10 µg/L and as per Indian standard is < 50 µg/L. In one patient from Bangladesh, water arsenic level was 79.5 µg/L (nail arsenic level: 0.23 mg/kg of nail), and in other patient from WB it was 0.9 µg/L (nail arsenic level: 0.8 mg/kg of nail).

Other associated disorders in patients with NCIPH :

The other associated disorders noted in patients with NCIPH were –coeliac disease (3), systemic lupus erythematosus (1), prior h/o pre-eclampsia during pregnancy (1) and glomerulonephritis after distal spleno-renal shunt surgery (1).

OBJECTIVE 3b

{TO STUDY THE ASSOCIATED DISORDERS IN PATIENTS WITH
NCIPH - STUDY OF OTHER DISORDERS }

DISCUSSION

In this study, skin arsenicosis was present in 11 % (3/27) of the NCIPH patients studied and increased nail arsenic levels was noted in 10% (5/ 52) portal hypertensive study patients (including two with NCIPH and three with hepatitis B related cirrhosis). All these patients were residents of West Bengal or Bangladesh (i.e. gangetic plains). Arsenic contamination of groundwater was noted in residential locality of one NCIPH Bangladeshi patient with arsenicosis. Thus, our report suggests that there is continued environmental contamination with arsenic, and this remains a possible cause of portal hypertension esp. NCIPH. This association was previously more commonly reported from the Indian subcontinent^{52, 54, 132, 140}.

According to our hypothesis in NCIPH, when a predisposed individual is challenged by chronic arsenic ingestion, it leads to occlusion of the small intra-hepatic portal venules²⁸. Various liver biopsy changes suggesting micro-angiopathy were noted in NCIPH patients from this study – e.g. sinusoidal dilatation, portal venule ectasia/ atresia and nodular regenerative hyperplasia.

In this report, v-WF-ADAMTS-13 imbalance associated with thrombocytopenia was noted in 6/ 8 NCIPH patients tested. This is similar to our previous studies in this area. We feel that low ADAMTS13 may be a predisposition and chronic arsenic ingestion may accentuate the

process of development of NCIPH (isolated micro-angiopathy affecting the small portal vein radicles)¹⁸. To further strengthen this hypothesis, in vitro experiments have shown that arsenic can activate endothelium and thus enhance v-WF antigen expression on endothelial cells¹¹⁶. Arsenic induced liver damage in mice, is thought to be indirect ((by endothelial stimulation) and may not be by direct cell damage¹⁴¹. No other pro-thrombotic disorders were tested for in this study. This is a limitation of our study.

Some of the previous studies have proven that arsenicosis can cause NCIPH⁵⁶. In this study, we have only demonstrated an association. We also note that majority (90%) of patients with NCIPH did not have arsenicosis. This indicates a multi-factorial causation for NCIPH. There was no difference in the phenotype of NCIPH patients with/ without arsenicosis.

Increased nail arsenic level were noted in both cases (NCIPH) and disease controls (Hepatitis B/C). The role of arsenicosis as a co-factor in pathogenesis of NCIPH and also for the worsening of portal hypertension in cirrhosis of other causes needs to be studied. As per study by Wanless et al¹⁷, intra-hepatic micro-venular occlusion may contribute to development/ progression of cirrhosis¹⁴².

For the study, we used WHO criteria, and defined arsenicosis as the typical skin manifestations¹⁰⁵. None of the study patients had any other non-dermatological manifestations of arsenicosis e.g. respiratory or neuropathy. Nail arsenic levels, although provides good reflection of the exposure to arsenic over previous 3-9 months (i.e. ongoing chronic exposure), it does not exclude chronic remote exposure only in the past¹⁰⁵. The liver arsenic levels were not measured in these patients.

We feel that chronic arsenic exposure, possibly by drinking contaminated groundwater, is the cause of skin arsenicosis in our patients. Analysis of groundwater for arsenic levels was

performed in only two NCIPH patients who had arsenicosis. This was not done in all the study patients. This remains a limitation of our study.

As there are various reports of increased metallic impurities (including arsenic), in complementary medicines¹⁴³, we excluded the possibility by ensuring record of long-term intake of these medications. None of our study patients were at risk of arsenic contamination from this source.

Groundwater arsenic contamination is well documented in Bangladesh and Eastern parts of India (basins of river Ganges, Brahmaputra). Similar contamination is also known to occur in Cambodia and Vietnam (Mekong delta) amongst others. Arsenic leaches out into the river from sediments in Himalayan Mountains. This then undergoes microbial reduction in anaerobic conditions. Various public health measures in place to combat this are :

- Identify and mark contaminated source
- Shift to safe water source
 - Treated surface water
 - Harvest rain water
 - Alternate source
 - Increase the depth of well
- Continuous education / participation of the community and
- Use of arsenic treatment plants and filters¹⁴⁴.

In our study, we note that people from the lower socioeconomic strata of society are still vulnerable to the effects of this arsenic contamination. This represents the need to need to

strengthen public health measures even further. 'Clean Ganges' project initiative may also help in this regard.

Why is NCIPH common in India ? This remains a relevant question with possible genetic and environmental factors responsible¹⁸. With better sanitation, some centres across India have reported a decreasing prevalence of NCIPH. Can arsenicosis be one of the factor to explain the high prevalence of NCIPH in India, needs to be further studied¹².

We have reported NCIPH as more common in lower socio-economic strata¹⁴. Majority of the study subjects in this study were from middle/ lower socio-economic status. Serum levels of vitamin B12 represent a non-invasive marker for diagnosis of NCIPH⁴⁸. In this study, 20% NCIPH patients had low levels of serum vitamin B12. Further studies to assess the role of vitamin B12 deficiency in causation of NCIPH are required.

In conclusion :

- NCIPH is associated with arsenicosis
- Arsenicosis is possibly secondary to contaminated groundwater
- Arsenic contamination of groundwater is an on-going problem in the Indian subcontinent
- NCIPH and arsenicosis effect the poor and lower socioeconomic strata.

OVERALL SUMMARY AND CONCLUSION

1. Non-cirrhotic intra-hepatic portal hypertension (NCIPH) remains a common cause of portal hypertension in 21st century India.
2. The overall prognosis in these patients remains good, but these patients are prone to decompensation, hepatocellular carcinoma and portal vein thrombosis.
3. Imbalance of von-Willebrand factor and its cleaving protease (ADAMTS-13), despite normal liver function, suggests a possibility of micro-angiopathy involving small portal venous radicles as the pathogenetic mechanism involved in NCIPH causation.
4. Over-representation of gut disorders, often non-specific inflammation which is clinically silent, suggests the important role of GI tract in the pathogenesis of NCIPH. This may also partly explain the increased prevalence of NCIPH in India, esp. in the lower socio-economic strata.
5. Continued ingestion of arsenic contaminated groundwater may be one of the pathogenic mechanisms in NCIPH, esp. in patients hailing from regions near Ganges.

IMPLICATIONS FOR FUTURE RESEARCH

1. Role of gastrointestinal tract has been postulated and this needs to be studied further.
Role of gut microbiome in pathogenesis and disease modification needs to be clarified.
2. Role of primary haemostasis has been hypothesised and needs to be further studied.
The genetic predisposition of Indians needs to be explored.

BIBLIOGRAPHY

1. Madhu K, Ramakrishna B, Zachariah U, Eapen CE, Kurian G. Non-cirrhotic intrahepatic portal hypertension. *Gut* 2008;57:1529.
2. Schouten JN, Garcia-Pagan JC, Valla DC, Janssen HL. Idiopathic noncirrhotic portal hypertension. *Hepatology* 2011;54:1071-81.
3. Hillaire S, Bonte E, Denninger MH, Casadevall N, Cadranet JF, Lebrec D, Valla D, Degott C. Idiopathic non-cirrhotic intrahepatic portal hypertension in the West: a re-evaluation in 28 patients. *Gut* 2002;51:275-80.
4. Tandon BN, Lakshminarayanan R, Bhargava S, Nayak NC, Sama SK. Ultrastructure of the liver in non-cirrhotic portal fibrosis with portal hypertension. *Gut* 1970;11:905-10.
5. Sama SK, Bhargava S, Nath NG, Talwar JR, Nayak NC, Tandon BN, Wig KL. Noncirrhotic portal fibrosis. *Am J Med* 1971;51:160-9.
6. Mallik KC, Sen Gupta KP, Basu AK, Biswas SK, Pal NC, Boyer J. Non-cirrhotic portal fibrosis with portal hypertension: a new syndrome. II. Histopathological studies. *Indian J Med Res* 1967;55:351-9.
7. Nayak NC, Ramalingaswami V. Obliterative portal venopathy of the liver. Associated with so-called idiopathic portal hypertension or tropical splenomegaly. *Arch Pathol* 1969;87:359-69.
8. Dhiman RK, Chawla Y, Vasishta RK, Kakkar N, Dilawari JB, Trehan MS, Puri P, Mitra SK, Suri S. Non-cirrhotic portal fibrosis (idiopathic portal hypertension): experience with 151 patients and a review of the literature. *J Gastroenterol Hepatol* 2002;17:6-16.
9. Dash SC, Bhuyan UN, Dinda AK, Saxena S, Agarwal SK, Tiwari SC, Nundy S. Increased incidence of glomerulonephritis following spleno-renal shunt surgery in non-cirrhotic portal fibrosis. *Kidney Int* 1997;52:482-5.
10. Sharma BC, Singh RP, Chawla YK, Narasimhan KL, Rao KL, Mitra SK, Dilawari JB. Effect of shunt surgery on spleen size, portal pressure and oesophageal varices in patients with non-cirrhotic portal hypertension. *J Gastroenterol Hepatol* 1997;12:582-4.

11. Poddar U, Thapa BR, Puri P, Girish CS, Vaiphei K, Vasishta RK, Singh K. Non-cirrhotic portal fibrosis in children. *Indian J Gastroenterol* 2000;19:12-3.
12. Okuda K. Non-cirrhotic portal hypertension: why is it so common in India? *J Gastroenterol Hepatol* 2002;17:1-5.
13. Goel A, Ramakrishna B, Madhu K, Zachariah U, Ramachandran J, Keshava SN, Elias E, Eapen CE. Idiopathic noncirrhotic intrahepatic portal hypertension is an ongoing problem in India. *Hepatology* 2011;54:2274; author reply 2274-5.
14. Goel A, Madhu K, Zachariah U, Sajith KG, Ramachandran J, Ramakrishna B, Gibikote S, Jude J, Chandy GM, Elias E, Eapen CE. A study of aetiology of portal hypertension in adults (including the elderly) at a tertiary centre in southern India. *Indian J Med Res* 2013;137:922-7.
15. Madhu K, Avinash B, Ramakrishna B, Eapen CE, Shyamkumar NK, Zachariah U, Chandy G, Kurian G. Idiopathic non-cirrhotic intrahepatic portal hypertension: common cause of cryptogenic intrahepatic portal hypertension in a Southern Indian tertiary hospital. *Indian J Gastroenterol* 2009;28:83-7.
16. Boyer JL, Hales MR, Klatskin G. "Idiopathic" portal hypertension due to occlusion of intrahepatic portal veins by organized thrombi. A study based on postmortem vinylite-injection corrosion and dissection of the intrahepatic vasculature in 4 cases. *Medicine (Baltimore)* 1974;53:77-91.
17. Wanless IR. Micronodular transformation (nodular regenerative hyperplasia) of the liver: a report of 64 cases among 2,500 autopsies and a new classification of benign hepatocellular nodules. *Hepatology* 1990;11:787-97.
18. Goel A, Elias JE, Eapen CE, Ramakrishna B, Elias E. Idiopathic Non-Cirrhotic Intrahepatic Portal Hypertension (NCIPH)-Newer Insights into Pathogenesis and Emerging Newer Treatment Options. *J Clin Exp Hepatol* 2014;4:247-56.
19. Nayak NC, Jain D, Saigal S, Soin AS. Non-cirrhotic portal fibrosis: one disease with many names? An analysis from morphological study of native explant livers with end stage chronic liver disease. *J Clin Pathol* 2011;64:592-8.
20. Basu AK, Boyer J, Bhattacharya R, Mallik KC, Sen Gupta KP. Non-cirrhotic portal fibrosis with portal hypertension: a new syndrome. I. Clinical and function studies and results of operations. *Indian J Med Res* 1967;55:336-50.
21. Ueda H, Kitani K, Kameda H, Takeda T, Yamada H. [Idiopathic (non-cirrhotic) portal hypertension. II. Hemodynamics of the liver and spleen]. *Naika* 1968;21:733-7.

22. Verheij J, Schouten JN, Komuta M, Nevens F, Hansen BE, Janssen HL, Roskams T. Histological features in western patients with idiopathic non-cirrhotic portal hypertension. *Histopathology* 2013;62:1083-91.
23. Rios FF, Rodrigues de Freitas LA, Codes L, Santos Junior GO, Schinoni MI, Parana R. Hepatoportal sclerosis related to the use of herbals and nutritional supplements. Causality or coincidence? *Ann Hepatol* 2016;15:932-938.
24. Cazals-Hatem D, Hillaire S, Rudler M, Plessier A, Paradis V, Condat B, Francoz C, Denninger MH, Durand F, Bedossa P, Valla DC. Obliterative portal venopathy: portal hypertension is not always present at diagnosis. *J Hepatol* 2011;54:455-61.
25. Chawla Y, Duseja A. Non-cirrhotic portal fibrosis (NCPF) is a vanishing disease in India. *Trop Gastroenterol* 2003;24:45-6.
26. Nayak NC, Jain D, Vasdev N, Gulwani H, Saigal S, Soin A. Etiologic types of end-stage chronic liver disease in adults: analysis of prevalence and their temporal changes from a study on native liver explants. *Eur J Gastroenterol Hepatol* 2012;24:1199-208.
27. Bhargava DK, Dasarathy S, Sundaram KR, Ahuja RK. Efficacy of endoscopic sclerotherapy on long-term management of oesophageal varices: a comparative study of results in patients with cirrhosis of the liver, non-cirrhotic portal fibrosis (NCPF) and extrahepatic portal venous obstruction (EHO). *J Gastroenterol Hepatol* 1991;6:471-5.
28. Simon EG, Joseph AJ, George B, Zachariah UG, Jeyamani R, Eapen CE, Chandy G, Ramakrishna BS, Kurian G, Chacko A. Aetiology of paediatric portal hypertension - experience of a tertiary care centre in South India. *Trop Doct* 2009;39:42-4.
29. Poddar U, Thapa BR, Rao KL, Singh K. Etiological spectrum of esophageal varices due to portal hypertension in Indian children: is it different from the West? *J Gastroenterol Hepatol* 2008;23:1354-7.
30. Sarin SK, Kumar A, Chawla YK, Bajjal SS, Dhiman RK, Jafri W, Lesmana LA, Guha Mazumder D, Omata M, Qureshi H, Raza RM, Sahni P, Sakhuja P, Salih M, Santra A, Sharma BC, Sharma P, Shiha G, Sollano J. Noncirrhotic portal fibrosis/idiopathic portal hypertension: APASL recommendations for diagnosis and treatment. *Hepatol Int* 2007;1:398-413.
31. Krasinskas AM, Egtesad B, Kamath PS, Demetris AJ, Abraham SC. Liver transplantation for severe intrahepatic noncirrhotic portal hypertension. *Liver Transpl* 2005;11:627-34; discussion 610-1.

32. Radomski JS, Chojnacki KA, Moritz MJ, Rubin R, Armenti VT, Wilson GA, Herrine S, Conn M. Results of liver transplantation for nodular regenerative hyperplasia. *Am Surg* 2000;66:1067-70.
33. Omanwar S, Rizvi MR, Kathayat R, Sharma BK, Pandey GK, Alam MA, Malhotra V, Sarin SK. A rabbit model of non-cirrhotic portal hypertension by repeated injections of E.coli through indwelling cannulation of the gastrosplenic vein. *Hepatobiliary Pancreat Dis Int* 2004;3:417-22.
34. Kathayat R, Pandey GK, Malhotra V, Omanwar S, Sharma BK, Sarin SK. Rabbit model of non-cirrhotic portal fibrosis with repeated immunosensitization by rabbit splenic extract. *J Gastroenterol Hepatol* 2002;17:1312-6.
35. Eapen CE, Nightingale P, Hubscher SG, Lane PJ, Plant T, Velissaris D, Elias E. Non-cirrhotic intrahepatic portal hypertension: associated gut diseases and prognostic factors. *Dig Dis Sci* 2011;56:227-35.
36. Austin A, Campbell E, Lane P, Elias E. Nodular regenerative hyperplasia of the liver and coeliac disease: potential role of IgA anticardiolipin antibody. *Gut* 2004;53:1032-4.
37. Daniels ME, Shrivastava A, Smith WA, Sahu P, Odagiri M, Misra PR, Panigrahi P, Suar M, Clasen T, Jenkins MW. Cryptosporidium and Giardia in Humans, Domestic Animals, and Village Water Sources in Rural India. *Am J Trop Med Hyg* 2015;93:596-600.
38. Kosek M, Guerrant RL, Kang G, Bhutta Z, Yori PP, Gratz J, Gottlieb M, Lang D, Lee G, Haque R, Mason CJ, Ahmed T, Lima A, Petri WA, Houtp E, Olortegui MP, Seidman JC, Mduma E, Samie A, Babji S. Assessment of environmental enteropathy in the MAL-ED cohort study: theoretical and analytic framework. *Clin Infect Dis* 2014;59 Suppl 4:S239-47.
39. Mathan M, Mathan VI, Baker SJ. An electron-microscopic study of jejunal mucosal morphology in control subjects and in patients with tropical sprue in southern India. *Gastroenterology* 1975;68:17-32.
40. Lindenbaum J, Gerson CD, Kent TH. Recovery of small-intestinal structure and function after residence in the tropics. I. Studies in Peace Corps volunteers. *Ann Intern Med* 1971;74:218-22.
41. Chacko CJ, Paulson KA, Mathan VI, Baker SJ. The villus architecture of the small intestine in the tropics: a necropsy study. *J Pathol* 1969;98:146-51.

42. Mackie I, Eapen CE, Neil D, Lawrie AS, Chitolie A, Shaw JC, Elias E. Idiopathic noncirrhotic intrahepatic portal hypertension is associated with sustained ADAMTS13 Deficiency. *Dig Dis Sci*;56:2456-65.
43. Eapen CE, Elias E, Goel A, Jacob JT. Hypothesis of mechanism of thrombocytopenia in severe dengue, providing clues to better therapy to save lives. *Current Science* 2014;108:168-9.
44. Ghoshal UC, Mehrotra M, Kumar S, Ghoshal U, Krishnani N, Misra A, Aggarwal R, Choudhuri G. Spectrum of malabsorption syndrome among adults & factors differentiating celiac disease & tropical malabsorption. *Indian J Med Res* 2012;136:451-9.
45. Gupta Bansal P, Singh Toteja G, Bhatia N, Kishore Vikram N, Siddhu A, Kumar Garg A, Kumar Roy A. Deficiencies of Serum Ferritin and Vitamin B12, but not Folate, are Common in Adolescent Girls Residing in a Slum in Delhi. *Int J Vitam Nutr Res* 2015;85:14-22.
46. Nongmaithem SS, Joglekar CV, Krishnaveni GV, Sahariah SA, Ahmad M, Ramachandran S, Gandhi M, Chopra H, Pandit A, Potdar RD, C HDF, Yajnik CS, Chandak GR. GWAS identifies population-specific new regulatory variants in FUT6 associated with plasma B12 concentrations in Indians. *Hum Mol Genet* 2017;26:2551-2564.
47. Sivaprasad M, Shalini T, Balakrishna N, Sudarshan M, Lopamudra P, Suryanarayana P, Arlappa N, Ravikumar BP, Radhika MS, Reddy GB. Status of Vitamin B12 and Folate among the Urban Adult Population in South India. *Ann Nutr Metab* 2016;68:94-102.
48. Goel A, Ramakrishna B, Muliylil J, Madhu K, Sajith KG, Zachariah U, Ramachandran J, Keshava SN, Selvakumar R, Chandy GM, Elias E, Eapen CE. Use of serum vitamin B12 level as a marker to differentiate idiopathic noncirrhotic intrahepatic portal hypertension from cryptogenic cirrhosis. *Dig Dis Sci* 2013;58:179-87.
49. Goel A, Ramakrishna B, Job V, Zachariah U, Eapen CE. Vitamin B12 Deficiency in Patients With Unexplained Portal Hypertension Indicates Absence of Severe Liver Fibrosis. *Journal of Clinical Gastroenterology*; Publish Ahead of Print.
50. Ahmad A, Afroz N, Gupta UD, Ahmad R. Vitamin B12 supplement alleviates N'-nitrosodimethylamine-induced hepatic fibrosis in rats. *Pharm Biol* 2014.
51. Mukherjee AK, Manna SK, Roy SK, Chakraborty M, Das S, Naskar JP. Plasma-aminothiols status and inverse correlation of total homocysteine with B-vitamins in

- arsenic exposed population of West Bengal, India. *J Environ Sci Health A Tox Hazard Subst Environ Eng* 2016;51:962-73.
52. Santra A, Das Gupta J, De BK, Roy B, Guha Mazumder DN. Hepatic manifestations in chronic arsenic toxicity. *Indian J Gastroenterol* 1999;18:152-5.
 53. Mazumder DN. Effect of chronic intake of arsenic-contaminated water on liver. *Toxicol Appl Pharmacol* 2005;206:169-75.
 54. Datta DV. Letter: Arsenic and non-cirrhotic portal hypertension. *Lancet* 1976;1:433.
 55. Mazumder DN, Das Gupta J, Santra A, Pal A, Ghose A, Sarkar S. Chronic arsenic toxicity in west Bengal--the worst calamity in the world. *J Indian Med Assoc* 1998;96:4-7, 18.
 56. Datta DV, Mitra SK, Chhuttani PN, Chakravarti RN. Chronic oral arsenic intoxication as a possible aetiological factor in idiopathic portal hypertension (non-cirrhotic portal fibrosis) in India. *Gut* 1979;20:378-84.
 57. Ghatak S, Biswas A, Dhali GK, Chowdhury A, Boyer JL, Santra A. Oxidative stress and hepatic stellate cell activation are key events in arsenic induced liver fibrosis in mice. *Toxicol Appl Pharmacol* 2011;251:59-69.
 58. Sarin SK, Sharma G, Banerjee S, Kathayat R, Malhotra V. Hepatic fibrogenesis using chronic arsenic ingestion: studies in a murine model. *Indian J Exp Biol* 1999;37:147-51.
 59. Khandpur S, Malhotra AK, Bhatia V, Gupta S, Sharma VK, Mishra R, Arora NK. Chronic arsenic toxicity from Ayurvedic medicines. *Int J Dermatol* 2008;47:618-21.
 60. Prasad HR, Malhotra AK, Hanna N, Kochupillai V, Atri SK, Ray R, Guglani B. Arsenicosis from homeopathic medicines: a growing concern. *Clin Exp Dermatol* 2006;31:497-8.
 61. Schouten JN, Van der Ende ME, Koeter T, Rossing HH, Komuta M, Verheij J, van der Valk M, Hansen BE, Janssen HL. Risk factors and outcome of HIV-associated idiopathic noncirrhotic portal hypertension. *Aliment Pharmacol Ther* 2012;36:875-85.
 62. Schouten JN, Nevens F, Hansen B, Laleman W, van den Born M, Komuta M, Roskams T, Verheij J, Janssen HL. Idiopathic noncirrhotic portal hypertension is associated with poor survival: results of a long-term cohort study. *Aliment Pharmacol Ther* 2012;35:1424-33.
 63. Harris M, Rash RM, Dymock IW. Nodular, non-cirrhotic liver associated with portal hypertension in a patient with rheumatoid arthritis. *J Clin Pathol* 1974;27:963-6.

64. Yilmaz G, Sari S, Egritas O, Dalgic B, Akyol G. Hepatoportal sclerosis in childhood: some presenting with cholestatic features (a re-evaluation of 12 children). *Pediatr Dev Pathol* 2012;15:107-13.
65. Albuquerque A, Cardoso H, Lopes J, Cipriano A, Carneiro F, Macedo G. Familial occurrence of nodular regenerative hyperplasia of the liver. *Am J Gastroenterol* 2013;108:150-1.
66. Barnett JL, Appelman HD, Moseley RH. A familial form of incomplete septal cirrhosis. *Gastroenterology* 1992;102:674-8.
67. Sarin SK, Mehra NK, Agarwal A, Malhotra V, Anand BS, Taneja V. Familial aggregation in noncirrhotic portal fibrosis: a report of four families. *Am J Gastroenterol* 1987;82:1130-3.
68. Dumortier J, Boillot O, Chevallier M, Berger F, Potier P, Valette PJ, Paliard P, Scoazec JY. Familial occurrence of nodular regenerative hyperplasia of the liver: a report on three families. *Gut* 1999;45:289-94.
69. Majumdar A, Delatycki MB, Crowley P, Lokan J, Tharian B, Angus PW, Gow P. An autosomal dominant form of non-cirrhotic portal hypertension. *J Hepatol* 2015;63:525-7.
70. Franchi-Abella S, Fabre M, Mselati E, De Marsillac ME, Bayari M, Pariente D, Jacquemin E, Bernard O. Obliterative portal venopathy: a study of 48 children. *J Pediatr* 2014;165:190-193 e2.
71. Witters P, Libbrecht L, Roskams T, Boeck KD, Dupont L, Proesmans M, Vermeulen F, Strandvik B, Lindblad A, Stephenne X, Sokal E, Gosseye S, Heye S, Maleux G, Aerts R, Monbaliu D, Pirenne J, Hoffman I, Nevens F, Cassiman D. Noncirrhotic presinusoidal portal hypertension is common in cystic fibrosis-associated liver disease. *Hepatology* 2011;53:1064-5.
72. Hwang S, Kim DY, Kim M, Chon YE, Lee HJ, Park YN, Park JY, Ahn SH, Han KH, Chon CY. [Deficiencies in proteins C and S in a patient with idiopathic portal hypertension accompanied by portal vein thrombosis]. *Korean J Hepatol* 2010;16:176-81.
73. Pulvirenti F, Pentassuglio I, Milito C, Valente M, De Santis A, Conti V, d'Amati G, Riggio O, Quinti I. Idiopathic non cirrhotic portal hypertension and spleno-portal axis abnormalities in patients with severe primary antibody deficiencies. *J Immunol Res* 2014;2014:672458.

74. Klenn PJ, Rubin R. Hepatic fibrosis associated with hereditary cystinosis: a novel form of noncirrhotic portal hypertension. *Mod Pathol* 1994;7:879-82.
75. McEntee MF, Wright KN, Wanless I, DeVovo R, Schneider JF, Shull R. Noncirrhotic portal hypertension and nodular regenerative hyperplasia of the liver in dogs with mucopolysaccharidosis type I. *Hepatology* 1998;28:385-90.
76. Feld JJ, Hussain N, Wright EC, Kleiner DE, Hoofnagle JH, Ahlawat S, Anderson V, Hilligoss D, Gallin JI, Liang TJ, Malech HL, Holland SM, Heller T. Hepatic involvement and portal hypertension predict mortality in chronic granulomatous disease. *Gastroenterology* 2008;134:1917-26.
77. Gorgy AI, Jonassaint NL, Stanley SE, Koteish A, DeZern AE, Walter JE, Sopha SC, Hamilton JP, Hoover-Fong J, Chen AR, Anders RA, Kamel IR, Armanios M. Hepatopulmonary syndrome is a frequent cause of dyspnea in the short telomere disorders. *Chest* 2015;148:1019-1026.
78. Girard M, Amiel J, Fabre M, Pariente D, Lyonnet S, Jacquemin E. Adams-Oliver syndrome and hepatoportal sclerosis: occasional association or common mechanism? *Am J Med Genet A* 2005;135:186-9.
79. Thevenot T, Dhote R, Tulliez M, Baverel F, Permal S, Rabineau D, Christoforov B. [Turner syndrome and nodular regenerative hyperplasia of the liver]. *Ann Med Interne (Paris)* 1998;149:295-6.
80. Vilarinho S, Sari S, Yilmaz G, Stiegler AL, Boggon TJ, Jain D, Akyol G, Dalgic B, Gunel M, Lifton RP. Recurrent recessive mutation in deoxyguanosine kinase causes idiopathic noncirrhotic portal hypertension. *Hepatology* 2016;63:1977-86.
81. Koot BG, Alders M, Verheij J, Beuers U, Cobben JM. A de novo mutation in KCNN3 associated with autosomal dominant idiopathic non-cirrhotic portal hypertension. *J Hepatol* 2016;64:974-7.
82. Vispo E, Cevik M, Rockstroh JK, Barreiro P, Nelson M, Scourfield A, Boesecke C, Wasmuth JC, Soriano V. Genetic determinants of idiopathic noncirrhotic portal hypertension in HIV-infected patients. *Clin Infect Dis* 2013;56:1117-22.
83. Blogowski W, Marlicz W, Smereczynski A, Lawniczak M, Lewosiuk A, Starzynska T. Nodular regenerative liver hyperplasia as a complication of azathioprine-containing immunosuppressive treatment for Crohn's disease. *Immunopharmacol Immunotoxicol* 2011;33:398-402.

84. Bayan K, Tuzun Y, Yilmaz S, Canoruc N, Dursun M. Analysis of inherited thrombophilic mutations and natural anticoagulant deficiency in patients with idiopathic portal hypertension. *J Thromb Thrombolysis* 2009;28:57-62.
85. Buchel O, Roskams T, Van Damme B, Nevens F, Pirenne J, Fevery J. Nodular regenerative hyperplasia, portal vein thrombosis, and avascular hip necrosis due to hyperhomocysteinaemia. *Gut* 2005;54:1021-3.
86. Ishii M, Katada Y. Idiopathic portal hypertension in a systemic sclerosis patient heterozygous for factor V Leiden mutation. *Rheumatol Int* 2003;23:44-6.
87. Taneja V, Mehra NK, Sarin SK, Sharma BK, Vaidya MC. Possible HLA influence in governing susceptibility to non-cirrhotic portal fibrosis. *Tissue Antigens* 1987;30:184-7.
88. Chakraborty D, Sunil HV, Mittal BR, Bhattacharya A, Singh B, Chawla Y. Role of Tc99m sulfur colloid scintigraphy in differentiating non-cirrhotic portal fibrosis from cirrhosis liver. *Indian J Nucl Med* 2010;25:139-42.
89. Scourfield A, Waters L, Holmes P, Panos G, Randell P, Jackson A, Mandalia S, Gazzard B, Nelson M. Non-cirrhotic portal hypertension in HIV-infected individuals. *Int J STD AIDS* 2011;22:324-8.
90. Arora A, Sarin SK. Multimodality imaging of obliterative portal venopathy: what every radiologist should know. *Br J Radiol* 2015;88:20140653.
91. Schouten JN, Garcia-Pagan JC, Valla DC, Janssen HL. Idiopathic noncirrhotic portal hypertension. *Hepatology*;54:1071-81.
92. Sarin SK, Sethi KK, Nanda R. Measurement and correlation of wedged hepatic, intrahepatic, intrasplenic and intravariceal pressures in patients with cirrhosis of liver and non-cirrhotic portal fibrosis. *Gut* 1987;28:260-6.
93. Elias JE, Mackie I, Eapen CE, Chu P, Shaw JC, Elias E. Porto-pulmonary hypertension exacerbated by platelet transfusion in a patient with ADAMTS13 deficiency. *J Hepatol* 2013;58:827-30.
94. Bernard PH, Le Bail B, Cransac M, Barcina MG, Carles J, Balabaud C, Bioulac-Sage P. Progression from idiopathic portal hypertension to incomplete septal cirrhosis with liver failure requiring liver transplantation. *J Hepatol* 1995;22:495-9.
95. Nzeako UC, Goodman ZD, Ishak KG. Hepatocellular carcinoma and nodular regenerative hyperplasia: possible pathogenetic relationship. *Am J Gastroenterol* 1996;91:879-84.

96. Sarin SK, Kumar A, Angus PW, Baijal SS, Baik SK, Bayraktar Y, Chawla YK, Choudhuri G, Chung JW, de Franchis R, de Silva HJ, Garg H, Garg PK, Helmy A, Hou MC, Jafri W, Jia JD, Lau GK, Li CZ, Lui HF, Maruyama H, Pandey CM, Puri AS, Rerknimitr R, Sahni P, Saraya A, Sharma BC, Sharma P, Shiha G, Sollano JD, Wu J, Xu RY, Yachha SK, Zhang C. Diagnosis and management of acute variceal bleeding: Asian Pacific Association for Study of the Liver recommendations. *Hepatology* 2011;5:607-24.
97. de Franchis R. Expanding consensus in portal hypertension: Report of the Baveno VI Consensus Workshop: Stratifying risk and individualizing care for portal hypertension. *J Hepatol* 2015;63:743-52.
98. Sarin SK, Gupta N, Jha SK, Agrawal A, Mishra SR, Sharma BC, Kumar A. Equal efficacy of endoscopic variceal ligation and propranolol in preventing variceal bleeding in patients with noncirrhotic portal hypertension. *Gastroenterology* 2010;139:1238-45.
99. Pal S, Radhakrishna P, Sahni P, Pande GK, Nundy S, Chattopadhyay TK. Prophylactic surgery in non-cirrhotic portal fibrosis: is it worthwhile? *Indian J Gastroenterol* 2005;24:239-42.
100. Sarin SK, Khanna R. Non-cirrhotic portal hypertension. *Clin Liver Dis* 2014;18:451-76.
101. Ferlitsch M, Reiberger T, Hoke M, Salzl P, Schwengerer B, Ulbrich G, Payer BA, Trauner M, Peck-Radosavljevic M, Ferlitsch A. von Willebrand factor as new noninvasive predictor of portal hypertension, decompensation and mortality in patients with liver cirrhosis. *Hepatology* 2012;56:1439-47.
102. Lisman T, Bongers TN, Adelmeijer J, Janssen HL, de Maat MP, de Groot PG, Leebeek FW. Elevated levels of von Willebrand Factor in cirrhosis support platelet adhesion despite reduced functional capacity. *Hepatology* 2006;44:53-61.
103. Uemura M, Fujimura Y, Matsumoto M, Ishizashi H, Kato S, Matsuyama T, Isonishi A, Ishikawa M, Yagita M, Morioka C, Yoshiji H, Tsujimoto T, Kurumatani N, Fukui H. Comprehensive analysis of ADAMTS13 in patients with liver cirrhosis. *Thromb Haemost* 2008;99:1019-29.
104. Mackie I, Eapen CE, Neil D, Lawrie AS, Chitolie A, Shaw JC, Elias E. Idiopathic noncirrhotic intrahepatic portal hypertension is associated with sustained ADAMTS13 Deficiency. *Dig Dis Sci* 2011;56:2456-65.

105. Das NK, Sengupta SR. Arsenicosis: diagnosis and treatment. *Indian J Dermatol Venereol Leprol* 2008;74:571-81.
106. Mackie I, Langley K, Chitolie A, Liesner R, Scully M, Machin S, Peyvandi F. Discrepancies between ADAMTS13 activity assays in patients with thrombotic microangiopathies. *Thromb Haemost* 2013;109:488-96.
107. Zhou W, Inada M, Lee TP, Benten D, Lyubsky S, Bouhassira EE, Gupta S, Tsai HM. ADAMTS13 is expressed in hepatic stellate cells. *Lab Invest* 2005;85:780-8.
108. Uemura M, Tatsumi K, Matsumoto M, Fujimoto M, Matsuyama T, Ishikawa M, Iwamoto TA, Mori T, Wanaka A, Fukui H, Fujimura Y. Localization of ADAMTS13 to the stellate cells of human liver. *Blood* 2005;106:922-4.
109. La Mura V, Reverter JC, Flores-Arroyo A, Raffa S, Reverter E, Seijo S, Abraldes JG, Bosch J, Garcia-Pagan JC. Von Willebrand factor levels predict clinical outcome in patients with cirrhosis and portal hypertension. *Gut* 2011;60:1133-8.
110. Poordad F. Review article: thrombocytopenia in chronic liver disease. *Aliment Pharmacol Ther* 2007;26 Suppl 1:5-11.
111. Friedman SL. Molecular regulation of hepatic fibrosis, an integrated cellular response to tissue injury. *J Biol Chem* 2000;275:2247-50.
112. Cao WJ, Niiya M, Zheng XW, Shang DZ, Zheng XL. Inflammatory cytokines inhibit ADAMTS13 synthesis in hepatic stellate cells and endothelial cells. *J Thromb Haemost* 2008;6:1233-5.
113. Bernardo A, Ball C, Nolasco L, Moake JF, Dong JF. Effects of inflammatory cytokines on the release and cleavage of the endothelial cell-derived ultralarge von Willebrand factor multimers under flow. *Blood* 2004;104:100-6.
114. Manavalan JS, Hernandez L, Shah JG, Konikkara J, Naiyer AJ, Lee AR, Ciaccio E, Minaya MT, Green PH, Bhagat G. Serum cytokine elevations in celiac disease: association with disease presentation. *Hum Immunol* 2010;71:50-7.
115. Kumar P, Kumar M, Ramanathan AL, Tsujimura M. Tracing the factors responsible for arsenic enrichment in groundwater of the middle Gangetic Plain, India: a source identification perspective. *Environ Geochem Health* 2010;32:129-46.
116. Kao YH, Yu CL, Chang LW, Yu HS. Low concentrations of arsenic induce vascular endothelial growth factor and nitric oxide release and stimulate angiogenesis in vitro. *Chem Res Toxicol* 2003;16:460-8.
117. Peyvandi F, Palla R, Lotta LA, Mackie I, Scully MA, Machin SJ. ADAMTS-13 assays in thrombotic thrombocytopenic purpura. *J Thromb Haemost* 2010;8:631-40.

118. Lindgren S, Sjoberg K, Eriksson S. Unsuspected coeliac disease in chronic 'cryptogenic' liver disease. *Scand J Gastroenterol* 1994;29:661-4.
119. Eapen CE, Nightingale P, Hubscher SG, Lane PJ, Plant T, Velissaris D, Elias E. Non-cirrhotic intrahepatic portal hypertension: associated gut diseases and prognostic factors. *Dig Dis Sci*;56:227-35.
120. Makharia G, Dhiman RK, Chawla YK, Vasistha RK. Non-cirrhotic portal fibrosis in a patient with rheumatoid arthritis. *Indian J Gastroenterol* 2001;20:197-8.
121. Kurppa K, Collin P, Viljamaa M, Haimila K, Saavalainen P, Partanen J, Laurila K, Huhtala H, Paasikivi K, Maki M, Kaukinen K. Diagnosing mild enteropathy celiac disease: a randomized, controlled clinical study. *Gastroenterology* 2009;136:816-23.
122. Marsh MN. Gluten, major histocompatibility complex, and the small intestine. A molecular and immunobiologic approach to the spectrum of gluten sensitivity ('celiac sprue'). *Gastroenterology* 1992;102:330-54.
123. Ludvigsson JF, Elfstrom P, Broome U, Ekbom A, Montgomery SM. Celiac disease and risk of liver disease: a general population-based study. *Clin Gastroenterol Hepatol* 2007;5:63-69 e1.
124. Sharma BC, Bhasin DK, Nada R. Association of celiac disease with non-cirrhotic portal fibrosis. *J Gastroenterol Hepatol* 2006;21:332-4.
125. Misra V, Misra SP, Dwivedi M, Gupta SC. Histomorphometric study of portal hypertensive enteropathy. *Am J Clin Pathol* 1997;108:652-7.
126. Barakat M, Mostafa M, Mahran Z, Soliman AG. Portal hypertensive duodenopathy: clinical, endoscopic, and histopathologic profiles. *Am J Gastroenterol* 2007;102:2793-802.
127. Nagral AS, Joshi AS, Bhatia SJ, Abraham P, Mistry FP, Vora IM. Congestive jejunopathy in portal hypertension. *Gut* 1993;34:694-7.
128. Tonutti E, Visentini D, Bizzaro N, Caradonna M, Cerni L, Villalta D, Tozzoli R. The role of antitissue transglutaminase assay for the diagnosis and monitoring of coeliac disease: a French-Italian multicentre study. *J Clin Pathol* 2003;56:389-93.
129. Leon F, Camarero C, R RP, Eiras P, Sanchez L, Baragano M, Lombardia M, Bootello A, Roy G. Anti-transglutaminase IgA ELISA: clinical potential and drawbacks in celiac disease diagnosis. *Scand J Gastroenterol* 2001;36:849-53.
130. Vecchi M, Folli C, Donato MF, Formenti S, Arosio E, de Franchis R. High rate of positive anti-tissue transglutaminase antibodies in chronic liver disease. Role of liver decompensation and of the antigen source. *Scand J Gastroenterol* 2003;38:50-4.

131. Kochhar R, Dutta U, Miglani A, Bhagat S, Poornachandra KS, Vaiphei K, Nain CK, Singh K. Celiac disease suspected at endoscopy in patients with chronic liver disease. *Indian J Gastroenterol*;30:166-9.
132. Das D, Chatterjee A, Mandal BK, Samanta G, Chakraborti D, Chanda B. Arsenic in ground water in six districts of West Bengal, India: the biggest arsenic calamity in the world. Part 2. Arsenic concentration in drinking water, hair, nails, urine, skin-scale and liver tissue (biopsy) of the affected people. *Analyst* 1995;120:917-24.
133. Nevens F, Fevery J, Van Steenberghe W, Sciote R, Desmet V, De Groote J. Arsenic and non-cirrhotic portal hypertension. A report of eight cases. *J Hepatol* 1990;11:80-5.
134. Morris JS, Schmid M, Newman S, Scheuer PJ, Sherlock S. Arsenic and noncirrhotic portal hypertension. *Gastroenterology* 1974;66:86-94.
135. Toniutto P, Fabris C, Bitetto D, Falletti E, Avellini C, Rossi E, Smirne C, Minisini R, Pirisi M. Role of AST to platelet ratio index in the detection of liver fibrosis in patients with recurrent hepatitis C after liver transplantation. *J Gastroenterol Hepatol* 2007;22:1904-8.
136. Patro BK, Jeyashree K, Gupta PK. Kuppaswamy's socioeconomic status scale 2010-the need for periodic revision. *Indian J Pediatr* 2012;79:395-6.
137. Labour Bureau Statistics: Labour Bureau, Government of India.
138. Samanta G, Sharma R, Roychowdhury T, Chakraborti D. Arsenic and other elements in hair, nails, and skin-scales of arsenic victims in West Bengal, India. *Sci Total Environ* 2004;326:33-47.
139. Gerritsen HE, Turecek PL, Schwarz HP, Lammle B, Furlan M. Assay of von Willebrand factor (vWF)-cleaving protease based on decreased collagen binding affinity of degraded vWF: a tool for the diagnosis of thrombotic thrombocytopenic purpura (TTP). *Thromb Haemost* 1999;82:1386-9.
140. Datta DV. Non-cirrhotic portal fibrosis ('idiopathic' portal hypertension in India). *J Assoc Physicians India* 1976;24:511-27.
141. Straub AC, Stolz DB, Ross MA, Hernandez-Zavala A, Soucy NV, Klei LR, Barchowsky A. Arsenic stimulates sinusoidal endothelial cell capillarization and vessel remodeling in mouse liver. *Hepatology* 2007;45:205-12.
142. Wanless IR, Wong F, Blendis LM, Greig P, Heathcote EJ, Levy G. Hepatic and portal vein thrombosis in cirrhosis: possible role in development of parenchymal extinction and portal hypertension. *Hepatology* 1995;21:1238-47.

143. Kumar G, Gupta YK. Monitoring of mercury, arsenic, cadmium and lead in Ayurvedic formulations marketed in Delhi by flame AAS and confirmation by ICP-MS. *Food Addit Contam Part B Surveill* 2012;5:140-4.
144. Ghosh P, Roy C, Das NK, Sengupta SR. Epidemiology and prevention of chronic arsenicosis: an Indian perspective. *Indian J Dermatol Venereol Leprol* 2008;74:582-93.

PUBLICATIONS (in the field of NCIPH)

1. **Goel A**, Ramakrishna B, Madhu K, Zachariah U, Ramachandran J, Keshava SN, Elias E, et al. Idiopathic noncirrhotic intrahepatic portal hypertension is an ongoing problem in India. *Hepatology* 2011;54:2275-2276.
2. **Goel A**, Ramakrishna B, Muliyl J, Madhu K, Sajith KG, Zachariah U, Ramachandran J, Keshava SN, Selvakumar R, Chandy GM, Elias E, Eapen CE. Use of serum vitamin B12 level as a marker to differentiate idiopathic noncirrhotic intrahepatic portal hypertension from cryptogenic cirrhosis. *Dig Dis Sci* 2013;58:179-87.
3. **Goel A**, Madhu K, Zachariah U, Sajith KG, Ramachandran J, Ramakrishna B, Gibikote S, Jude J, Chandy GM, Elias E, Eapen CE. A study of aetiology of portal hypertension in adults (including the elderly) at a tertiary centre in southern India. *Indian J Med Res* 2013;137:922-7
4. **Goel A**, Alagammai PL, Nair SC, Mackie I, Ramakrishna B, Muliyl J, Keshava SN, Eapen CE, Elias E. ADAMTS13 deficiency, despite well-compensated liver functions in patients with noncirrhotic portal hypertension. *Indian J Gastroenterol* 2014;33:355-63.
5. Maiwall R, **Goel A**, Pulimood AB, Babji S, Sophia J, Prasad C, Balasubramanian KA, Ramakrishna B, Kurian S, Fletcher GJ, Abraham P, Kang G, Ramakrishna BS, Elias E, Eapen CE. Investigation into celiac disease in Indian patients with portal hypertension. *Indian J Gastroenterol* 2014;33:517-23.
6. **Goel A**, Christudoss P, George R, Ramakrishna B, Amirtharaj GJ, Keshava SN, Ramachandran A, Balasubramanian KA, Mackie I, Fleming JJ, Elias E, Eapen CE. Arsenicosis, possibly from contaminated groundwater, associated with noncirrhotic intrahepatic portal hypertension. *Indian J Gastroenterol* 2016;35:207-15.

7. **Goel A**, Ramakrishna B, Job V, Zachariah U, Eapen CE. Vitamin B12 Deficiency in Patients With Unexplained Portal Hypertension Indicates Absence of Severe Liver Fibrosis. *Journal of Clinical Gastroenterology* 2017; Published [Ahead of Print].
8. **Goel A**, Raghupathy V, Amirtharaj GJ, Chapla A, Venkatraman A, Ramakrishna B, Ramachandran A, Thomas N, Balasubramanian KA, Mackie I, Elias E, Eapen CE. ADAMTS13 missense variants associated with defective activity and secretion of ADAMTS13 in a patient with non-cirrhotic portal hypertension. *Indian J Gastroenterol* 2017 (ahead of print).

PUBLICATIONS (from the thesis)

1. **Goel A**, Alagammai PL, Nair SC, Mackie I, Ramakrishna B, Muliyl J, Keshava SN, Eapen CE, Elias E. ADAMTS13 deficiency, despite well-compensated liver functions in patients with noncirrhotic portal hypertension. *Indian J Gastroenterol* 2014;33:355-63.
2. Maiwall R, **Goel A**, Pulimood AB, Babji S, Sophia J, Prasad C, Balasubramanian KA, Ramakrishna B, Kurian S, Fletcher GJ, Abraham P, Kang G, Ramakrishna BS, Elias E, Eapen CE. Investigation into celiac disease in Indian patients with portal hypertension. *Indian J Gastroenterol* 2014;33:517-23.
3. **Goel A**, Christudoss P, George R, Ramakrishna B, Amirtharaj GJ, Keshava SN, Ramachandran A, Balasubramanian KA, Mackie I, Fleming JJ, Elias E, Eapen CE. Arsenicosis, possibly from contaminated groundwater, associated with noncirrhotic intrahepatic portal hypertension. *Indian J Gastroenterol* 2016;35:207-15.

SELECTED ABSTRACTS (from the thesis)

1. Saravanan S, Bharadwaj T, **Goel A**, Balasubramanian AL, Ramachandran A, Jude J, Eapen CE. Analysis of Single Nucleotide Polymorphism at rs6677604 in Patients With Non-Cirrhotic Intrahepatic Portal Hypertension. *J Clin Exp Hepatol* 2015;5:S54.
2. **Goel A**, Ramakrishna B, Zachariah U, Sajith KG, Chandy G, Kurian G, Eapen CE. Prognosticating after variceal bleed in cryptogenic cirrhosis: non cirrhotic portal hypertension can be a confounder. *J Hepatol* 2016;64:S251-2
3. **Goel A**, Raghupathy V, Amirtharaj GJ, Chapla A, Ramachandran A, Sureshkumar S, Balasubramanian KA, Ramachandran A, Ramakrishna B, Thomas N, Mackie I, Eapen CE, Elias E. ADAMTS13 Mutations Associated with Defective ADAMTS13 Secretion in a Patient with Non-Cirrhotic Portal Hypertension. *J Clin Exp Hepatol* 2016;6:S88-S89.
4. Athiyarath R, **Goel A**, Chapla A, Thomas N, Balasubramanian KA, Eapen CE, Elias E. Identification of Potential Genetic Modifiers in Noncirrhotic Portal Hypertension (NCIPH). *Journal of Clinical and Experimental Hepatology* 2017;7:S104-105.