



# Medulloblastoma: Intraventricular Recurrences

*Hendy Setiawan<sup>1</sup>, Celia<sup>2</sup>, and Ridha Dharmajaya<sup>3</sup>*

<sup>1,2</sup>Resident, Department of Neurosurgery, Faculty of Medicine, Sumatera Utara University/RSUP. H. Adam Malik Medan

<sup>3</sup>Head of Departement, Department of Neurosurgery, Faculty of Medicine, Sumatera Utara University/RSUP. H. Adam Malik Medan

**Abstract:** Medulloblastoma is the most common malignant pediatric brain tumor. Incidence in adult population is less than 1 %. Medulloblastoma in adult usually between 20 and 40 years old, which is lateral hemispheric and not midline vermian. Survival rate in adult is 67% lower than adolescents is 69% and children is 72%. Location of recurrences most commonly presents at posterior fossa, spinal, supratentorial, and bone metastases. Recurrences of medulloblastoma in supratentorial ventricular is uncommon. The outcome for patients with recurrent medulloblastoma has historically been poor. 37 years old male who presented with severe headache gradually. Patient has history of headache 2 months ago and gait ataxia 1,5 months ago. Patient had surgery 2 years ago with result of hystopathology medulloblastoma. He had irradiation completely 22 months ago. Physical examination showed GCS 15 with gait ataxia. Head CT scan show multiple isodense lesion intraventricular. Before patient had surgery, Head CT scan showed hiperdense lesion at cerebellopontine angle. Seeding medulloblastoma to intraventricular is recurrences which have poor prognosis. Patient had poor condition in few days. Patient died before got reradiation

**Keyword:** Intraventricular, Medulloblastoma, Reirradiation, Recurrences, Seeding

Received [15 Jan 2019] | Revised [1 Feb 2019] | Accepted [20 Feb 2019]

## 1 Introduction

Medulloblastoma is the most common malignant pediatric brain tumor. Incidence in adult population is less than 1 %.[1] Medulloblastoma in adult usually between 20 and 40 years old, which is lateral hemispheric and not midline vermian.[2] Survival rate in adult is 67% lower than children is 72%. Location of recurrences most commonly presents at posterior fossa, spinal, supratentorial, and bone metastases.[3] Late recurrences of medulloblastoma in supratentorial ventricular is uncommon. Recurrent meduloblastoma has poor outcome, although gets radiotherapy and chemotherapy.[4] Recurrence of this tumor is well recognized and may require salvage therapy. Time to recurrence typically occurs within two years of initial diagnosis

---

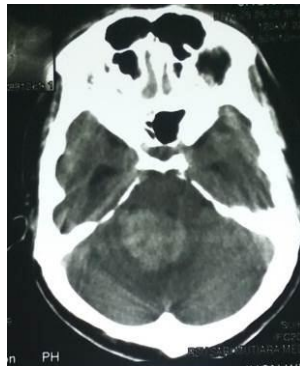
\*Corresponding author at: [hsns987@gmail.com](mailto:hsns987@gmail.com)

E-mail address: [hsns987@gmail.com](mailto:hsns987@gmail.com)

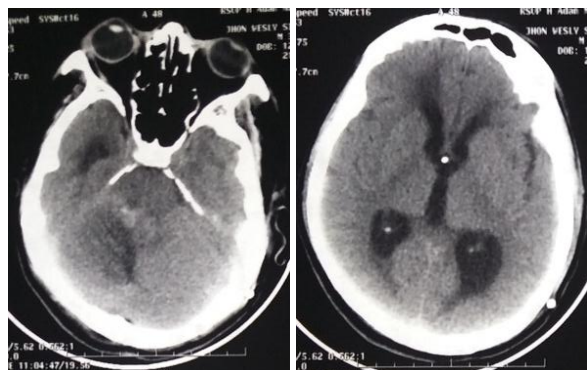
in the pediatric population. Tumors that follow Collin's Law (tumor free period of 9 months plus the age at diagnosis) are considered to be cured. However, late recurrence of medulloblastoma has been documented in the pediatric population.[5]

## 2 Case Report

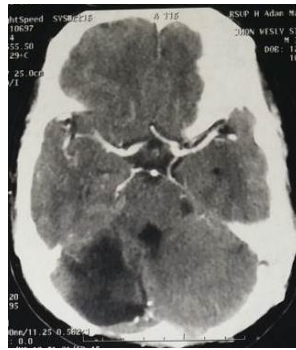
37 years old male patient who presented with severe headache gradually. Patient has history of headache 2 months ago and gait ataxia 1,5 months ago. Patient had been operated ventriculoperitoneal shunt (VP shunt) and resection tumor 2 years ago with result of histopathology desmoplastic medulloblastoma. He had cranio-spinal irradiation completely 22 months ago. He had not complaint after irradiation. Physical examination showed GCS 15 with gait ataxia. CT scan shows multiple isodense lesion intraventricular.



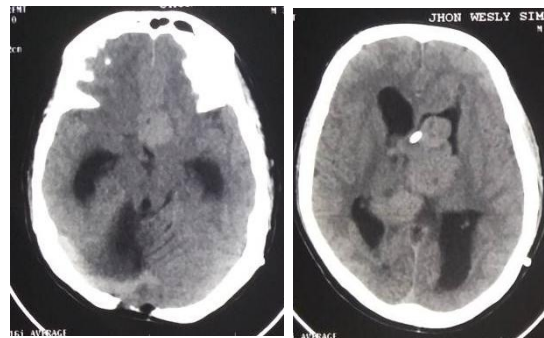
**Figure 1.** Non contrast CT Scan of brain before surgery shows right cerebellopontine angle lesion isodense



**Figure 2.** Non Contrast CT Scan of brain after he had been tumor removed and VP Shunt



**Figure 3.** Contrast CT Scan of brain after irradiation shows mixed density at right cerebellum



**Figure 4.** Non contrast CT Scan of brain 2 years later shows multiple isodense lesion intraventricular

### 3 Discussion

Medulloblastoma, a malignant tumor typically arising from the cerebellar vermis in young children and lobes in older children, represents 4–8% of all intracranial tumors, and is the most common malignant central nervous system tumor of childhood,<sup>5</sup> with approximately 80% occurring in patients under 15 years of age.<sup>6</sup> It accounts for 15–25% of all childhood brain tumors in comparison with only 1% of adult intracranial neoplasms, with a slight male predominance in both groups.[7]

Differences in childhood and adult tumors can also be observed in terms of histologic variant. Classical histologic presentation of medulloblastoma includes densely-packed primitive cells with hyperchromatic nuclei, scant cytoplasm, and nuclear molding.[8] This classical tumor histology is more common in children.<sup>7</sup> Homer-Wright rosettes may be seen.[9] Adults are more likely to have laterally-located tumors, which more often desmoplastic.[9] Both tumor types include markers of neuronal lineage, such as class III beta tubulin and MAP-2 neurofilaments, whereas more adult tumors will express GFAP.[10] The anaplastic/large cell variant is more frequently seen in older children and adults.

Medulloblastoma tends to seed the cerebrospinal fluid resulting in extensive leptomeningeal involvement, and treatment therefore requires surgical resection followed by neuro-axis radiotherapy and chemotherapy.[11] Recurrence in the pediatric population differs from that seen in adults. Age at diagnosis has been shown to be a significant predictor of time until relapse.[12] The majorities of pediatric recurrences are within two years of initial diagnosis, and are in the posterior fossa.[12] Those with tumor-free period equal to the age at diagnosis plus nine months may be considered cured (Collin's Law).[13] While a good predictor of many childhood tumors, there are known exceptions to Collins law for medulloblastoma. However, a recent review of 125 patients by Massimino et al., gender, age at diagnosis, metastases, and therapeutic protocol were shown to have no prognostic impact.[13]

In the event of recurrence, relapse at a single site and further out from initial time of diagnosis is considered a more favorable prognostic indicator.[14] Recurrences are most common in the posterior fossa, followed by spinal, supratentorial and bony metastases.[7] Supratentorial dissemination is often found in the subfrontal area and may be due to overly generous radiation protection of the orbital roof to prevent irradiation of the cribriform plate, allowing for a nidus of recurrence.[14] Late recurrence of medulloblastoma in the supratentorial ventricular compartment is uncommon. We present a case of late recurrent medulloblastoma 13 years after initial diagnosis, again validating the need for long term follow-up in the pediatric population following diagnosis of medulloblastoma

#### **4 Conclusion**

Seeding medulloblastoma to intraventricular is recurrences which have poor prognosis. Patient died before got reirradiation. Although he had not complaint after surgery and first irradiation.

#### **CONFLICT OF INTEREST**

The authors declare no conflict of interest regarding this manuscript.

#### **FUNDING**

The authors declare no financial interest in any of the materials discussed in this work.

#### **REFERENCES**

---

- [1] Goudihalli SR, Brar R, Mundi I. Reappraisal of Cerebellopontine angle medulloblastoma: Report of a fatal case and lessons learned. *Interdisciplinary Neurosurgery*. 2018; 12: 20-23.
- [2] Shih RY and Smirniotopolous JG. *Posterior Fossa Tumors in Adult Patients*. Adult Brain Tumor. Philadelphia: Elsevier. 2016. 1-18.
- [3] Iyamah KOA, Winslow N, Flouty O, and Kirby P. Isolated Supratentorial Intraventricular Recurrence of Medulloblastoma. *Journal Korean Neurosurgical Society*. 2015; 58 (6): 557-9.

- [4] Buglione M, Triggiani L, Grisanti S, etc.. Retreatment of recurrent adult medulloblastoma with radiotherapy: a case report and review the literature. *Journal of Medical Case Report*. 2013; 7: 64.
- [5] Roka YB, Bista P, Sharma GR, Adhikari D, Kumar P. Frontal recurrence of medulloblastoma five years after excision and craniospinal irradiation. *Indian J Pathol Microbiol*. 2009, 52 : 383-5.
- [6] Sarkar C, Pramanik P, Karak AK, Mukhopadhyay P, Sharma MC, Singh VP, et al. Are childhood and adult medulloblastomas different? A comparative study of clinicopathological features, proliferation index and apoptotic index. *J Neurooncol*. 2002, 59 : 49-61.
- [7] Sun LM, Yeh SA, Wang CJ, Huang EY, Chen HC, Hsu HC, et al. Postoperative radiation therapy for medulloblastoma--high recurrence rate in the subfrontal region. *J Neurooncol*. 2002, 58 : 77-85.
- [8] Allan R, Gill A, Spittaler P. Recurrent medulloblastoma--violation of Collin's law by 14 years. *J Clin Neurosci*. 2004, 11 : 756-7.
- [9] Sanders MA, Vitaz T, Rosenblum M, Plaga AR, Parker JC Jr, Parker JR. 46-year-old man with a spinal cord mass. *Brain Pathol*. 2011, 21 : 109-12.
- [10] Nigri F, Telles C, Acioly MA. Late obstruction of an endoscopic third ventriculostomy stoma by metastatic seeding of a recurrent medulloblastoma. *J Neurosurg Pediatr*. 2010, 5 : 641-4.
- [11] Tabori U, Sung L, Hukin J, Laperriere N, Crooks B, Carret AS, et al. Distinctive clinical course and pattern of relapse in adolescents with medulloblastoma. *Int J Radiat Oncol Biol Phys*. 2006, 64 : 402-7.
- [12] Massimino M, Antonelli M, Gandola L, Miceli R, Pollo B, Biassoni V, et al. Histological variants of medulloblastoma are the most powerful clinical prognostic indicators. *Pediatr Blood Cancer*. 2013, 60 : 210-6.
- [13] Massimino M, Casanova M, Polastri D, Biassoni V, Modena P, Pecori E, et al. Relapse in medulloblastoma : what can be done after abandoning high-dose chemotherapy? A mono-institutional experience. *Childs Nerv Syst*. 2013.
- [14] Miralbell R, Bleher A, Huguenin P, Ries G, Kann R, Mirimanoff RO, et al. Pediatric medulloblastoma : radiation treatment technique and patterns of failure. *Int J Radiat Oncol Biol Phys*. 1997, 37 : 523-9