

---

# ANALYSIS OF ROOT CANAL MORPHOLOGY OF INCISOR TEETH USING PERIAPICAL RADIOGRAPHY BISECTING TECHNIQUE AND CHANGE HORIZONTAL ANGULATION 30° IN SUB RACE PROTO AND DEUTRO MALAY

## ANALISIS MORFOLOGI SALURAN AKAR GIGI INSISIVUS MENGGUNAKAN RADIOGRAFI PERIAPIKAL TEKNIK BISEKTRIS DAN PERUBAHAN ANGULASI HORIZONTAL 30° PADA SUB RAS PROTO DAN DEUTRO – MELAYU

Dewi Kartika<sup>\*</sup>, Trelia Boel<sup>\*\*</sup>, Sondang Pintauli<sup>\*\*\*</sup>

<sup>\*</sup>Faculty of Dentistry, University of Sumatera Utara, Indonesia

<sup>\*\*</sup>Dental Radiology Unit, Faculty of Dentistry, University of Sumatera Utara, Indonesia

<sup>\*\*\*</sup>Department of Dental Health Society / Prevention, Faculty of Dentistry, University of Sumatera Utara, Indonesia

Address: Jalan Alumni No. 2 Kampus USU, Medan, Indonesia

Corresponding authors: [trelia.boel@usu.ac.id](mailto:trelia.boel@usu.ac.id)

---

### Abstract

The incisor has a variation of root canal morphology, which can be assessed using periapical radiography. Periapical radiography with standard angulation often makes complicated the assessment of the root canal morphology that is branched off in buccal and lingual directions because the radiograph result of the root canal will appear superimposed. Therefore, it is necessary to change horizontal angulation to mesial or distal to help assess the superimposed root canal. Root canal morphology may vary by population. The population in Indonesia consists mainly of the sub-races of Proto and Deutro-Malay. The purpose of this study was to determine the difference of root canal morphology between maxillary and mandibular incisors; between the sub-races of Proto and Deutro-Malay; and between the right and left regions, using twice the radiation projection. This study was an analytical study with cross-sectional method using 55 subjects who come from three previous generations of Proto and Deutro-Malay. On each tooth were performed twice radiations periapical radiography, using standard angulation and altering horizontal angulation toward distal 30°. The results showed that in Proto-Melayu, for maxillary central incisors maxillary teeth were obtained type I (99.1%) and III (0.9%) Vertucci, and maxillary lateral incisors were obtained type I Vertucci (100%). In mandibular central incisors were obtained type I (90%), II (3.6%), III (2.7%) Vertucci and IV Gulabivala (3.6%), and mandibular lateral incisors were obtained type I (87.3%), II (1.8%), III (7.3%) Vertucci and type IV Gulabivala (3.6%). In Deutro-Malay, maxillary central incisors were obtained 100% Vertucci type I and maxillary lateral incisors were obtained type I (99.1%) and II (0.9%). In mandibular central incisors were obtained type I (85.5%), III (11.8%) Vertucci, IV Gulabivala (1.8%), and other types 1-2-1-2-1 (0.9%), and mandibular lateral incisors were obtained by type I (81.8%) and III (18.2%) Vertucci. The result of chi-square analysis showed there were no significant differences of root canal morphology of maxillary incisors tooth between Proto and Deutro-Malay and between right and left region ( $p > 0,05$ ), but there were significant differences of root canal morphology between maxillary and mandibular incisors and root canal morphology of the mandibular incisor between Proto and Deutro-Malay ( $p < 0,05$ ). In conclusion, maxillary and mandibular incisors of Proto and Deutro-Malay sub-races have variations in root canal configuration and there were differences found in the mandibular incisors.

**Keywords:** root canal morphology, incisors, periapical radiography, horizontal angulation

### Abstract

Gigi insisivus memiliki variasi morfologi saluran akar. Morfologi saluran akar dapat dinilai dengan menggunakan radiografi periapikal. Radiografi periapikal dengan angulasi standar sering membuat dokter gigi kesulitan untuk menilai morfologi saluran akar yang bercabang ke arah bukal dan lingual karena pada hasil foto tersebut saluran akar akan terlihat berhimpit. Oleh sebab itu perlu dilakukan perubahan angulasi horizontal ke arah mesial atau distal untuk dapat membantu menilai saluran akar yang berhimpit. Morfologi saluran akar dapat bervariasi pada setiap populasi. Populasi di Indonesia sebagian besar terdiri dari sub ras Proto dan Deutro-Melayu. Tujuan penelitian ini adalah untuk mengetahui perbedaan morfologi saluran akar antara gigi insisivus maksila dan mandibula; antara sub ras Proto dan Deutro-Melayu; dan antara regio kanan dan kiri, menggunakan dua kali proyeksi penyinaran. Penelitian ini adalah penelitian analitik

dengan metode *cross-sectional* menggunakan 55 orang subjek yang berasal dari tiga keturunan sebelumnya keturunan dari Proto dan Deutro-Melayu. Pada setiap gigi dilakukan dua kali penyinaran yaitu foto ronsen periapikal dengan menggunakan angulasi standar dan mengubah angulasi horizontal ke arah distal 30°. Hasil penelitian menunjukkan bahwa pada Proto-Melayu, untuk gigi insisivus sentralis maksila diperoleh tipe I (99,1%) dan III (0,9%) Vertucci, dan insisivus lateralis maksila diperoleh tipe I Vertucci (100%). Pada Insisivus sentralis mandibula diperoleh tipe I (90%), II (3,6%), III (2,7%), Vertucci dan IV Gulabivala (3,6%), dan insisivus lateralis mandibula diperoleh tipe I (87,3%), II (1,8%), III (7,3%), Vertucci dan tipe IV Gulabivala (3,6%). Pada Deutro-Melayu, insisivus sentralis maksila diperoleh 100% tipe I Vertucci dan insisivus lateralis maksila tipe (99,1%) dan II (0,9%). Pada insisivus sentralis mandibula diperoleh tipe I (85,5%), III (11,8%) Vertucci, IV Gulabivala (1,8%), dan tipe lain 1-2-1-2-1 (0,9%), dan insisivus lateralis mandibula diperoleh tipe I (81,8%) dan III (18,2%) Vertucci. Hasil analisis *chi-square* diperoleh tidak dijumpai perbedaan signifikan morfologi saluran akar gigi insisivus maksila antara Proto dan Deutro-Melayu dan antara regio kanan dan kiri ( $p>0,05$ ), namun ada perbedaan signifikan morfologi saluran akar antara gigi insisivus maksila dan mandibula, dan morfologi saluran akar gigi insisivus mandibula antara Proto dan Deutro-Melayu ( $p<0,05$ ). Sebagai kesimpulan bahwa gigi insisivus maksila dan mandibula sub ras Proto dan Deutro-Melayu memiliki variasi konfigurasi saluran akar dan ada perbedaan dijumpai pada gigi insisivus mandibula.

**Kata Kunci:** morfologi saluran akar, gigi insisivus, radiografi periapikal, angulasi horizontal

## INTRODUCTION

The failure of endodontic treatment in permanent teeth is still common. It may cause pain in treated teeth which might be uncomfortable for the patient. According to Iqbal, 17.7% of undetectable root can cause endodontic treatment failure.<sup>1</sup>

The incisor is an anterior tooth that usually has one root and one root canal. The incisors have a variation of root canal morphology especially mandibular incisors. The often undetectable additional root in the incisor are usually located in the lingual area and are often the cause of treatment failure.<sup>2</sup>

Several studies have been done previously to identify root canal morphology in incisors. According to Scarlatescu et al., The mandibular central mandibular root canal configuration is based on the Vertucci classification of 65.6% type I, 25% type III, 6.3% type II, and 3.1% type VII.<sup>3</sup> In the Pakistan it consisted of 91 % type I, 3% V type, and 6% type III.<sup>4</sup> Research on the Palestinian population shows that all mandibular incisor teeth have 1 root consisted of 70.7% type I, 16.3% type II, 13% Vertucci III type.<sup>5</sup>

Radiographic projection can be used to detect root canal morphology of unextracted teeth.<sup>6</sup> However, periapical radiography is still the primary choice of radiographs by dentists in diagnosing and giving the treatments because it can show the state of the teeth and surrounding tissues well. The techniques used in periapical radiography are two bisector and parallel techniques. In the treatment of endodontics, both techniques can be used. Placement of film holder in parallel techniques is often difficult, especially in patients with limited mouth opening, therefore periapical radiography of bisector technique is still the preferred technique used in making x-ray photo-

graphs.<sup>7</sup> According to Moshfeghi et al., periapical radiography can help to identify root canals by making horizontal angle changes of up to 30° which can significantly improve root location accuracy.<sup>8</sup>

Most of the population in Indonesia belongs to the Malay race group. The Malay race consists of Proto-Melayu and Deutro-Melayu.<sup>9</sup> In Indonesia, the influence of race with ethnic and cultural diversity can also affect the occurrence of dental morphology variation. Study by Anggriani on first mandibular molars found Weine's four types of root canal configurations according to, whereas on maxillary teeth it has one type of configuration pattern.<sup>10</sup>

The researchers will conduct a study regarding the differences in root canal morphology between the maxillary and mandibular incisors between the Proto and Deutro-Malay sub-race, and between the left and right regions using periapical radiography of bisector techniques and horizontal angulation changes of 30° in the Proto and Deutro-Malay sub-race. This study is expected to provide additional scientific information about the root morphology in Indonesia, and improve dental health services for diagnosis and treatment of endodontic treatment.

## MATERIALS AND METHODS

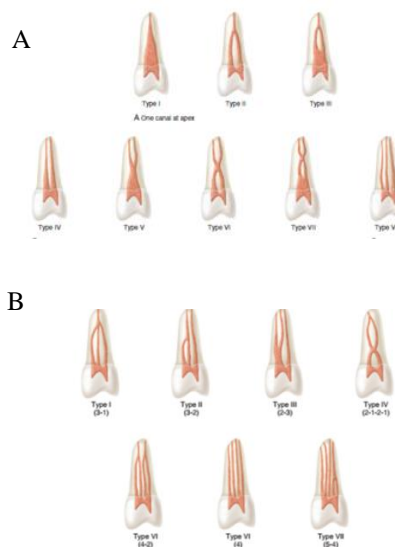
This research is an analytic research with cross-sectional design which is conducted from May to November 2017 at Radiology Installation of Dental and Oral Hospital of University of Sumatera Utara, Medan. This research has been approved by Health Research Ethics Commission, Faculty of Medicine, University of North Sumatra / RSUP H Adam Malik with No: 212 / TGL / KEPK FK USU-RSUP HAM

/ 2017. All subjects had approved and signed informed consent prior to the study.

The population of this study is all students who are the descendants and the third generations of Proto and Deutro-Malay sub-race residing in the University of North Sumatra. The sample should be in accordance with inclusion and exclusion criteria. The inclusion criterias of third generations of Proto and Deutro-Malay descent, are to have complete maxillary and mandibular incisors, deep caries (has not reached the pulp), no history of endodontic treatment, and lightly crowded. Exclusion criterias are: root canal with resorption and calcification, presence of root fracture, periapical lesion, and incomplete root formation. Sample selection method is done by purposive sampling technique.

Assessment of root canal morphology of the incisor is done by first conducting a field survey, i.e. the selection of respondents (samples) through interviews and filling out the questionnaire provided, intraoral examination. Then, if the respondents met the inclusion and exclusion criteria, they are required to complete the research approval sheet.

The next stage is to perform periapical photos with bisector technique and horizontal angulation with 30° changes to distal direction. First, radiation with standard angulation was performed on central maxillary incisors and maxillary lateral, after which a second photograph was made by altering horizontal angulation using the arc as a cone shift guide, so that the cone could be shifted to distal direction of 30°. Afterwards, radiation was performed with standard angulation on the teeth's central maxillary and maxillary lateral incisors, then a second photograph was taken by shifting the horizontal angulation to the distal direction of 30°. Afterwards, the radiation was performed on the central incisors and mandibular right lateral incisors, and the mandibular left central and lateral incisors using standard angulation. Then, distal changes of 30° in horizontal angulation were applied to the central incisors and the mandibular left lateral. After that, the similar changes were applied to the central incisors and the mandibular right lateral. Further film processing and interpretation of the root canal configuration type and periapical radiographs were carried out by viewer box. Types of root canal configurations are classified according to Vertucci and Gulabivala (Figures 1 and 2).



**Figure 1.** Configurations of root canal, A Vertucci, B. Gulabivala<sup>11</sup>

Chi-square statistical analysis was implemented to compare the differences in root canal morphology between maxillary and mandibular incisors, Proto and Deutro-Malay sub-races, and the right and left regions. Results will be labelled as significant when the value of  $p < 0.05$ .

## RESULTS

The sample of this research is University of North Sumatera students whose three previous generations are the original descendants of sub race of Proto and Deutro-Melayu, each of which amounted to 55 people. This study used periapical radiography of standard angulation bisector techniques and horizontal angulation changes of 30° to the distal direction. The obtained root canal configuration form was analyzed using a chi-square test and classified according to Vertucci and Gulabivala (Figs. 1 and 2).

Differences in root canal configuration between the maxillary and mandibular incisors in the Proto and Deutro-Malay sub-races are displayed in Table 1 and 2. The result is a significant difference in root canal configuration between maxillary and mandibular incisors ( $p < 0.05$ ).

**Table 1.** Differences in root canal configuration between the maxillary and mandibular incisors in the Proto-Malay sub-race

Teeth	Type of Root Canal Configuration n (%)										Chi-square Analysis Result	
	Vertucci								Gulabivala 2-1-2-1	Other types 1-2-1-2-1		
	I	II	III	IV	V	VI	VII	VIII				
Maxillary Central Incisors	109 (99,1)	-	1 (0,9)	-	-	-	-	-	-	-	-	0,000*
Lateral Incisors	110 (100)	-	-	-	-	-	-	-	-	-		
Mandibular Central Incisors	99 (90)	4 (3,6)	3 (2,7)	-	-	-	-	-	4 (3,6)	-		
Lateral Incisors	96 (87,3)	2 (1,8)	8 (7,3)	-	-	-	-	-	4 (3,6)	-		

\*Significant

**Table 2.** Differences in root canal configuration between the maxillary and mandibular incisors in the Deutro-Malay sub-race

Teeth	Type of Root Canal Configuration n (%)										Chi-square Analysis Result	
	Vertucci								Gulabivala 2-1-2-1	Other types 1-2-1-2-1		
	I	II	III	IV	V	VI	VII	VIII				
Maxillary Central Incisors	110 (100)	-	-	-	-	-	-	-	-	-	-	0,000
Lateral Incisors	109 (99,1)	1 (0,9)	-	-	-	-	-	-	-	-		
Mandibular Central Incisors	94 (85,5)	-	13 (11,8)	-	-	-	-	-	2 (1,8)	1 (0,9)		
Lateral Incisor	90 (81,8)	-	20 (18,2)	-	-	-	-	-	-	-		

\*Significant

Table 3 displays no significant difference in the type of root canal configuration in the central and maxillary lateral incisors between Proto and Deutro-Malay ( $p > 0.05$ ).

**Table 3.** Differences in root canal configuration of maxillary incisors between Proto and Deutro-Malay sub-races

Teeth	Sub-race	Type of Root Canal Configuration n (%)								chi-square Analysis Result
		I	II	III	IV	V	VI	VII	VIII	
Central Incisor	Proto-Malay	109 (99,1)	-	1 (0,9)	-	-	-	-	-	0,316
	Deutro-Malay	110 (100)	-	-	-	-	-	-		
Lateral Incisor	Proto-Malay	110 (100)	-	-	-	-	-	-	-	0,316
	Deutro-Malay	109 (99,1)	1 (0,9)	-	-	-	-	-	-	

Statistical analysis (Table 4) displayed significant differences in root canal configuration in mandibular central and mandibular incisors between Proto and Deutro-Malay with  $p = 0.017$  and  $p = 0.010$  ( $p < 0.05$ )

**Table 4.** Differences in mandibular root canal configuration between Proto and Deutro-Malay sub-races

Teeth	Sub-race	Type of Root Canal Configuration n (%)										chi-square Analysis Result	
		Vertucci								Gulabivala 2-1-2-1	Other types 1-2-1-2-1		
		I	II	III	IV	V	VI	VII	VIII				
Central Incisor	Proto-Malay	99 (90)	4 (3,6)	3 (2,7)	-	-	-	-	-	-	4 (3,6)	-	0,017*
	Deutro-Malay	94 (85,5)	-	13 (11,8)	-	-	-	-	-	-	2 (1,8)	-	
Lateral Incisor	Proto-Malay	96 (87,3)	2 (1,8)	8 (7,3)	-	-	-	-	-	-	4 (3,6)	-	0,010*
	Deutro-Malay	90 (81,8)	-	20 (18,2)	-	-	-	-	-	-	-	-	

\*Significant

Configuration of the maxillary and mandibular incisor ducts between the right and left regions of the Proto-Malay sub-race showed no significant difference of  $p > 0.05$  (Tables 5 and 6).

**Table 5.** Differences in root canal maxillary incisor configuration between the right and left regions of the Proto-Malay sub-race

Teeth	Region	Type of Root Canal Configuration n (%)								chi-square Analysis Result	
		I	II	III	IV	V	VI	VII	VIII		
Central Incisor	Right	54 (98,2)	-	1 (1,8)	-	-	-	-	-	-	0,315
	Left	55 (100)	-	-	-	-	-	-	-	-	
Lateral Incisor	Right	55 (100)	-	-	-	-	-	-	-	-	-
	Left	55 (100)	-	-	-	-	-	-	-	-	

**Table 6.** Differences in mandibular incisor root canal configuration between the right and left regions of the Proto-Malay sub-race

Teeth	Region	Type of Root Canal Configuration n (%)										chi-square Analysis Result	
		Vertucci								Gulabivala 2-1-2-1	Other types 1-2-1-2-1		
		I	II	III	IV	V	VI	VII	VIII				
Central Incisor	Right	50 (91)	1 (1,8)	2 (3,6)	-	-	-	-	-	-	2 (3,6)	-	0,719
	Left	49 (89,1)	3 (5,5)	1 (1,8)	-	-	-	-	-	-	2 (3,6)	-	
Lateral Incisor	Right	49 (89,1)	1 (1,8)	3 (5,5)	-	-	-	-	-	-	2 (3,6)	-	0,910
	Left	47 (85,5)	1 (1,8)	5 (9,1)	-	-	-	-	-	-	2 (3,6)	-	

Statistical analysis showed no significant difference in root canal configuration type on the maxillary and mandibular central and maxillary incisors between

the right and left regions with  $p > 0,05$  (Table 7 and 8).

**Table 7.** Differences in root canal maxillary incisor configuration between the right and left regions of the Deutro-Malay sub-race

Teeth	Region	Type of Root Canal Configuration n (%)								chi-square Analysis Result	
		I	II	III	IV	V	VI	VII	VIII		
Central Incisor	Right	55 (100)								-	
	Left	55 (100)									
Lateral Incisor	Right	54 (98,2)	1 (1,8)								0,315
	Left	55 (100)									

**Table 8.** Differences in mandibular incisor root canal configuration between the right and left regions of the Deutro-Malay sub-race

Teeth	Region	Type of Root Canal Configuration n (%)										chi-square Analysis Result		
		Vertucci								Gulabivala	Other types			
		I	II	III	IV	V	VI	VII	VIII					
Central Incisor	Right	46 (83,7)	-	7 (12,7)	-	-	-	-	-	-	1 (1,8)	1 (1,8)	0,772	
	Left	48 (87,3)	-	6 (10,9)	-	-	-	-	-	-	1 (1,80)	-		
Lateral Incisor	Right	46 (83,7)	-	9 (16,3)	-	-	-	-	-	-	-	-		0,621
	Left	44 (80)	-	11 (20)	-	-	-	-	-	-	-	-		

## DISCUSSION

Periapical radiography of bisector technique was applied by using standard angulation and horizontal distal angulation change toward 30°. The result showed that all maxillary and mandibular incisive teeth in Proto and Deutro-Malay have a root number of 1 (one). The root canal configuration of maxillary and mandibular incisors are shown in Table 1-4.

The root canal configuration of the maxillary incisors in Proto and Deutro-Malay is generally Vertucci I type. The result of this study is similar to previous research regarding the most commonly found canal configuration types in maxillary or mandibular incisors, namely type 1-1 or type I Vertucci.<sup>12</sup>

In this study, variations of root canal configuration types other than type I Vertucci were discovered.

This is due to the use of bisector periapical radiography technique with two first radiation projections with standard angulation, and second with horizontal angulation change of 30 ° or also called tube shift technique. The incisor is a three-dimensional object, whereas periapical radiography with standard angulation (the direction of rays from buccal to lingual / palatal) shows only two dimensional objects (images in distally mesial direction) making it difficult to determine the root canal configuration type. Usually the root canal are on the buccal and lingual side, resulting in the overlapping image. While in the second photo, the change in horizontal angulation can display objects in three dimensions because the direction of roent-gen rays through the teeth from distal to mesial (visible images in the direction of

buccal lingual), so that the root canal configuration forms in buccal and palatal are clearly visible and not overlapping.

Research by Uma et al., also states that radiographs must be taken in buccal and mesiodistal direction in order to view objects in a three-dimensional view. The mesiodistal direction radiograph is able to show the shape of root canal wider. Taking a second x-ray image in the mesiodistal direction allows for the separation of the root canal from one to two separate channels and it also allows the display of another root canal configuration.<sup>13</sup> In Klein et al's study, horizontal angle projection between 20°-30° is better in showing the root canal shape in mandibular teeth, whereas horizontal angle  $\pm 40^\circ$  in the mandibular incisors can make it difficult to detect the root canal due to overlapping of the adjacent teeth.<sup>14</sup>

In this study, there was a significant difference ( $p < 0.05$ ) between the maxillary and mandibular incisors root canal configuration variations in the Proto and Deutro-Malay subrace (Table 1 and 2). This is probably due to the position of the film and the direction of the rays when second x-ray photo is taken. When taking a roentgen photo with a bisector technique, the position of the film for the maxillary incisor will form a triangular plane of the photographed tooth while the film position for the mandibular incisor will form almost parallel to the photographed teeth even without the use of film holder due to the deeper floor of the mouth as compared to the palate.

The ray direction during the second x-ray shot can also affect the photo result. In the maxillary incisors, there were horizontal angulation changes in the distal direction. This results in the display of the apical portion of the maxillary central incisors which overlaps with the incisive foramen; and the lateral incisors overlapping with the lateral fossa. Therefore, according to Walton et al., the horizontal angulation change for the maxillary anterior teeth is a direct projection toward the facial, i.e. the direction of the straight ray passes through the patient's face. Due to the standard angulation in the x-ray photograph, the apical region of the maxillary incisors can overlap with the incisive foramen and the lateral fossa.<sup>15</sup>

Previous research has stated that root canal morphology is affected by race. Race may affect the size of either distal, mesial or buccolingual teeth. Previous studies have suggested that there is a correlation between the size of the dental crown and the incisive roots of the incisor root canals. According to Warren and Laws (cit. Nagas et al., 2011), the smaller the value of the MD / FL index, the greater the incidence of root canal branching. Nagas et al.'s study evaluated the association of bucco-

lingual size and mandibular incisor root morphology. The result of the research is that when the size of buccolingual is increasing, it is also possible for two root canals to branch at the base of the pulp chamber.<sup>16</sup>

Table 3 and 4 assess the differences in root canal configuration of maxillary incisors in the Proto and Deutro-Malay sub-races. The result of statistical analysis with chi-square test shows that there is no significant difference in maxillary incisors root configuration between Proto and Deutro-Malay sub-races (Table 3). Significant differences were found in the mandibular central and mandibular incisors between the Proto and Deutro-Malay sub-races ( $p < 0.05$ ) (Table 4). Previous research has been done to compare the tooth size of in Batak (sub-race Proto-Malay) and Malay (sub-race Deutro-Malay) (Mundiyah), there is no significant size difference between buccolingual maxillary and mandibular incisors in male from both Batak and Malay sub-races; and buccolingual maxillary incisors in female from both Batak and Malay sub-races. However, significant differences were found in the size of the buccolingual mandibular incisors between Batak and Malay women.<sup>17</sup>

The split of two or more root canals starting from the pulp chamber includes II, IV, VI, and VIII Vertucci types. In this study we found type II Vertucci in the sub-lateral maxillary incisor of Deutro-Malay, but the difference was not significant with the Proto-Malay sub-race. The results were similar to previous research (Mundiyah), which shows no significant difference in the buccolingual maxillary incisors teeth size. In the mandibular, type II Vertucci is found in the central and lateral incisors of Proto-Malay and the difference is significant when compared to the Deutro-Malay sub-race. The results of this study were similar to that of Mundiyah, which displays a significant difference in the size of the buccolingual mandibular incisor between the Batak (Proto-Melayu) and the Malay (Deutro-Melayu) female. The split of two or more root canals starting from the pulp chamber included in type II, IV, VI, and VIII Vertucci. In this study we found the type II Vertucci in the sub-lateral maxillary incisor of Deutro-Malay, but the difference was not significant with the Proto-Malay sub-race. The results were similar to that of Mundiyah that there was no significant difference in the buccolingual maxillary incisors size. In the mandible, type II Vertucci is found in the central and lateral incisors of Proto-Malay and the difference is significant when compared to the Deutro-Malay sub-race. The result of this research is similar to Mundiyah, that is, there is a significant difference of the size of the mandibular incisor

between the Batak (Proto-Melayu) and the Malay (Deutro-Melayu) female.

The split of two or more root canals can also be found in the centre or a one third of the roots. In this study, the root canal splits were encountered in type IV Gulabivala (2-1-2-1) and type 1-2-1-2-1. Tipe IV Gulabivala was found in centralis mandibular incisors of Proto and Deutro-Malay, and mandibular lateral incisors Proto-Malay and 1-2-1-2-1 types were found in Deutro-Malay central incisors.

Previous research has found type 2-1-2-1, which was first discovered by Gulabivala in mandibular molar of Thai and Burmese populations.<sup>18,19</sup> Han et al. on the study of root canal morphology in anterior mandibular teeth of Chinese populations using *cone beam computed tomography* method encountered type 2-1-2-1 for centralis mandibular incisor 0.39% and 0.08% for lateral mandibular lateral incisors.<sup>20</sup> Prita et al.'s study on the Indian population using *cone beam computed tomography* discovered the same type which accounted for 3% and 2% in the mandibular central and mandibular incisors.<sup>21</sup>

Prior research which might be influenced by racial and genetic factors found type 2-1-2-1 mandibular incisors in Proto and Deutro-Malay. Several studies have suggested that there are racial and genetic similarities of Mongoloid races in Indonesia to other Southeast Asian countries from Austronesian origin in Yunnan, Southern China.<sup>22</sup>

Type 1-2-1-2-1 has previously been discovered by in the Indian population in mandibular incisors of 3.6% of the population which was examined with clearing and dye penetration technique (Bhat et al.).<sup>23</sup> In this study, it was found only in mandibular

incisor of Deutro-Malay race, whereas it was not found in Proto-Melayu sub-race. This might be due to the possibility of the mixture between Deutro-Malay sub-race and migrants from India. In the year 500 AD, many Indian traders came to Indonesia including the West Indonesia. This is reinforced by the discovery of Indian pottery which was made during 200 BC to 200 AD in the area of Java and Bali.<sup>22</sup>

Research to assess the root canal configuration between the right and left regions has been done by Bulut et al. There was no significant difference in the number of root canals between the right and left regions in both men and women ( $p > 0.05$ ).<sup>24</sup> The results are similar to the results of this study. In Table 5-8 there is no significant difference in root canal configuration between the right and left mandibular and maxillary incisors of both the Proto and Deutro-Malay sub-races.

The shape of the root canal configuration is related to the width of the buccolingual / buccopalatal teeth. Previous studies conducted by Mundiayah, the size of buccolingual both on Batak (sub-race Proto-Malay) and Malay (sub races Deutro-Melayu) show bilateral symmetry. There was no significant difference between buccolingual / buccopalatal maxillary and mandibular incisors in Batak and Malay sub-race.<sup>17</sup> Therefore, the root canal configuration type may be the same between the right and left regions. In conclusion, the maxillary and mandibular incisors of Proto and Deutro-Malay sub-races varied in root canal configuration and there is a difference found in the mandibular incisors.

## REFERENCES

1. Iqbal A. The factors responsible for endodontic treatment failure in the permanent dentitions of the patients reported to the college of dentistry, the University of Aljouf, Kingdom of Saudi Arabia. *JCDR* 2016; 10(5): 146-8.
2. Aminsobhani M, Sadegh M, Meraji N, Razmi H, Kharazifard MJ. Evaluation of the Root and Canal Morphology of Mandibular Permanent Anterior Teeth in an Iranian Population by Cone-Beam Computed Tomography. *JDT-TUMS* 2013; 10(4): 358-66.
3. Scarlatescu S, Didilescu AC, Stratul S, Rusu D, Grigore M, Greabu M, Iliescu A. Root canal morphology of mandibular central incisors in a south-eastern Romanian population: endodontic and periodontal implications. *TMJ* 2010; 60(4): 280-3
4. Naz F, Sadozai SRK, Chatha R. Number and pattern of root canals in mandibular incisors. *PODJ* 2015; 35(4): 695-8.
5. Mukhaimer R, Jarbawi M. Radiographic study of the root canal system of mandibular incisors in Palestinian population. *OJST* 2013; 3: 452-6.
6. Kim SY, Lim SH, Gang SN, Kim HJ. Crown and root lengths of incisors, canines, and premolars measured by *cone-beam* computed tomography in patients with malocclusions. *Korean J Orthod* 2013; 43(6): 271-8.
7. Ibrahim MF, Azis MS, Maxood A, Ullah Khan W. Comparison of paralleling and bisecting angle techniques in endodontic working length radiography. *Pakistan Oral & Dental Journal* 2013; 33(1): 160-4.
8. Mosfeghi M, Jenab L, Sarikhani S, Nikneshan S. Experimental comparison of the diagnostic accuracy of conventional and digital radiography in detection of external root resorption 2013; 25(2): 130-33.
9. Rieuwpassa IE, Toppo S, Haerawati SD. Perbedaan ukuran dan bentuk lengkung gigi antara laki-laki dan



- perempuan suku Bugis, Makassar, dan Toraja. *Dentofasial* 2013; 11(3): 156-60.
10. Anggriani S. Jumlah dan bentuk akar serta konfigurasi saluran akar gigi molar satu rahang atas dan rahang bawah di Jawa Barat. Tesis. Jakarta: Program Pasca Sarjana FKG UI, 2012: 30-3.
  11. Hargreaves KM, Berman LH. *Cohen's: pathways of the pulp*. 11<sup>th</sup> edn, Elsevier: Missouri. 2016.
  12. Peiris R. Root and canal morphology of human permanent teeth in a Sri Lankan and Japanese population. *Anthropological Sci* 2008; 116(2): 123–33.
  13. Uma C, Ramachandran S, Indira R, Shankar P. Canal and isthmus morphology in mandibular incisors – an in vitro study. *Endodontology* 2004; 16: 7-11.
  14. Klein RMF, Blake SA, Nattress BR, Hirschmann PN. Evaluation of x-ray beam angulation for successful twin canal identification in mandibular incisors. *International Endodontic Journal* 1997; 30: 58-63.
  15. Walton R, Fouad AF. *Endodontics, principles and practice*. 5<sup>th</sup> edn. Elsevier: Missouri. 212-16.
  16. Nagas E, Gorduysus O, Gorduysus M. Relation between bucco-lingual dimension and root canal morphology in mandibular incisors: a morphometric study. *Cdr*. 2011; 35(2): 10-3.
  17. Mundiayah. Masalah gigi berjejal, suatu studi perbandingan morfologi, ukuran gigi, dan ukuran lengkung pada suku Batak dan suku Melayu di Sumatera Utara. Disertasi. Bandung: Pasca Sarjana Universitas Padjajaran 1982.
  18. Gulabivala K, Aung TH, Alavi A & Ng YL. Root and canal morphology of Burmese mandibular molars. *Int Endod J* 2001; 34: 359–70.
  19. Gulabivala K, Opasanon A, Ng YL, Alavi A. Root and canal morphology of Thai mandibular molars. *Int Endod J* 2002; 35: 52-62.
  20. Han T, Ma Y, Yang L, Chen X, Zhang X, Wang Y. A study of the root canal morphology of mandibular anterior teeth using cone-beam computed tomography in a Chinese subpopulation. *J Endod* 2014; 40(9): 1309-14.
  21. Prita D, Ajinkya MP, Prashant S, Kulvinder SB. An in-vitro cone-beam computed tomographic evaluation of root canal anatomy of permanent mandibular incisor teeth in an Indian population. *Clin Radiol Imaging J* 2017; 1(2): 1-8.
  22. Bellwood P, Fox JJ, Tryon D. *Austronesians historical and comparative perspectives*. ANU E Press, Australia, 2006.
  23. Bhat SP, Sheth R, Kumar P, Khilosiya A. Root canal morphology and assessment of incidence, type, and position of isthmus in permanent mandibular central incisor in North Indian population: An in vitro study. *Endodontology* 2017; 29(2): 107-14.
  24. Bulut DG, Kose E, Ozcan G, Sekerci AE, Canger EM, Sisman Y. Evaluation of root morphology and root canal configuration of premolars in the Turkish individuals using cone beam computed tomography. *Eur J Dent* 2015; 9: 551-7