

Xanthomatous meningioma: a case report with review of the literature.

著者	ISHIDA Mitsuaki, FUKAMI Tadateru, NITTA Naoki, IWAI Muneo, YOSHIDA Keiko, KAGOTANI Akiko, NOZAKI Kazuhiko, OKABE Hidetoshi
journal or publication title	International journal of clinical and experimental pathology
volume	6
number	10
page range	2242-2246
year	2013-09-15
URL	http://hdl.handle.net/10422/00012598

Case Report

Xanthomatous meningioma: a case report with review of the literature

Mitsuaki Ishida¹, Tadateru Fukami², Naoki Nitta², Muneo Iwai¹, Keiko Yoshida¹, Akiko Kagotani¹, Kazuhiko Nozaki², Hidetoshi Okabe¹

¹Department of Clinical Laboratory Medicine and Division of Diagnostic Pathology, ²Department of Neurosurgery, Shiga University of Medical Science, Shiga, Japan

Received August 13, 2013; Accepted August 27, 2013; Epub September 15, 2013; Published October 1, 2013

Abstract: Xanthomatous meningioma is an extremely rare variant of meningioma that is characterized histopathologically by the presence of tumor cells with lipid-filled vacuolated cytoplasm. In this report, we describe the fifth documented case of xanthomatous meningioma and review its clinicopathological features. A 76-year-old Japanese male presented with dizziness. Magnetic resonance imaging demonstrated a well-circumscribed tumor in the left parasagittal to frontal region with attachment of the dura mater. Histopathological examination of the resected specimen revealed proliferation of polygonal to spindle cells with eosinophilic cytoplasm and bland round to oval nuclei. Whorl formation and psammomas were scattered, and mitotic figures were rarely seen. A peculiar finding was the presence of extensive xanthomatous change continuing to the above-mentioned typical meningothelial meningioma. These tumor cells had clear vacuolated cytoplasm and bland round to oval nuclei. Immunohistochemically, xanthomatous cells were positive for epithelial membrane antigen. Accordingly, an ultimate diagnosis of xanthomatous meningioma was made. Our clinicopathological analysis revealed that xanthomatous meningioma affects children to young persons or the elderly, and four of five cases were located in the supratentorial region. Although the detailed mechanism underlying the xanthomatous change has not been clarified, this change is thought to result from a metabolic abnormality of the neoplastic meningothelial cells. Further, xanthomatous change has also been reported in atypical and anaplastic meningiomas. Therefore, it is important to recognize that xanthomatous change can occur in meningiomas, and to avoid misidentifying these cells as macrophages.

Keywords: Meningioma, metaplastic, xanthomatous, adipophilin

Introduction

Meningioma is a neoplasm derived from meningothelial cells that shows various histopathological features. A recent World Health Organization Classification divides grade I meningioma into 9 subtypes: meningothelial, fibrous, transitional, psammomatous, angiomatous, microcystic, secretory, lymphoplasmacyte-rich, and metaplastic [1]. Metaplastic meningioma is one of the rarest subtypes, and is defined as a tumor containing striking focal or widespread mesenchymal components including osseous, cartilaginous, lipomatous, myxoid, or xanthomatous tissue, singly or in combinations [1]. Xanthomatous change is characterized histopathologically by the presence of a significant number of tumor cells with vacuolated lipid-filled cytoplasm. Metaplastic meningioma with

extensive xanthomatous change, namely “xanthomatous” meningioma, has been extremely rarely reported [2-5]. Herein, we report the fifth documented case of xanthomatous meningioma and review its clinicopathological features.

Case report

A 76-year-old Japanese male presented with dizziness at an outpatient clinic. Magnetic resonance imaging demonstrated a well-circumscribed tumor in the left parasagittal to frontal region with attachment to the dura mater (**Figure 1**). He was referred to our hospital for operation of the tumor, and subsequently a total resection of the tumor was performed under a clinical diagnosis of meningioma.

Histopathological examination of the resected tumor revealed proliferation of polygonal to

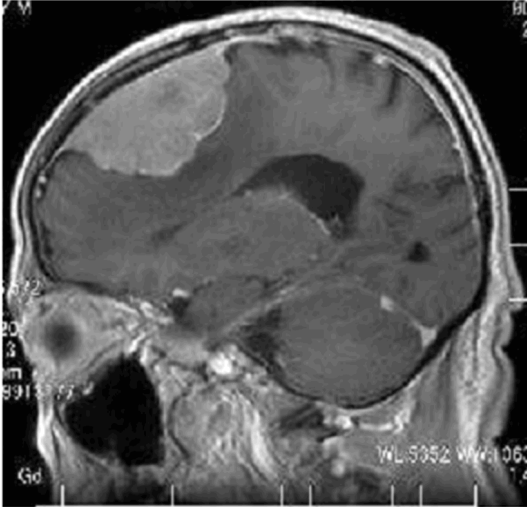


Figure 1. Magnetic resonance imaging showing a well-circumscribed tumor with attachment to the dura mater in the parasagittal to frontal region.

spindle cells with eosinophilic cytoplasm and bland round to oval nuclei containing small nucleoli (**Figure 2A-C**). Whorl formation and psammomas were scattered (**Figure 2A, 2C**). Mitotic figures were rarely seen (0-1/10 high-power fields). No geographic necrosis was present. A peculiar finding was the presence of extensive xanthomatous change within the tumor that comprised approximately 50% of the tumor, continuing to the above-mentioned typical meningothelial meningioma. The tumor cells had clear vacuolated cytoplasm and centrally located bland round to oval nuclei (**Figure 2A-C**). No mitotic figures were found in the xanthomatous area. A transition between the conventional meningioma and the xanthomatous area was present (**Figure 2A, 2C**). Moreover, infiltration of foamy macrophages and small lymphocytes was observed focally. Neither mature adipocytes nor osteocartilaginous tissue was present within the tumor. No invasion into the brain parenchyma or bone was noted.

Immunohistochemical studies were performed using an autostainer (Ventana) by the same method as previously reported [6-9]. Epithelial membrane antigen (EMA) was expressed in both the conventional meningioma and the xanthomatous component (**Figure 2A**). Vimentin was also expressed in both components. CD68, MAC387, and lysozyme were expressed only in the xanthomatous component. Interestingly, adipophilin was expressed in the xantho-

matous component as well as in the conventional meningioma (**Figure 3B**). The average Ki-67 labeling index was 2.1%, and there were a few areas of 4-5% within the tumor.

According to these findings, an ultimate diagnosis of xanthomatous meningioma was made.

Discussion

The term “xanthomatous” meningioma was first coined by Kepes in 1994 [2]. Since then, only three additional cases with detailed histopathological and immunohistochemical features have been reported and we describe here the fifth documented case of xanthomatous meningioma. **Table 1** summarizes the clinicopathological features of the four previously reported cases of xanthomatous meningioma as well as the present one. The distribution of the patients is interesting. This type of tumor affects children to young persons or the elderly (**Table 1**). Four of five cases were located in the supratentorial region, and one case was located in the posterior cranial fossa [3]. Ijiri *et al.* reported a case of radiation-associated xanthomatous meningioma in 10-year-old child, who had been treated for ependymoma at the age of 2 years following radiation therapy (total 55.5 Gy) [4].

The histopathological hallmark of xanthomatous meningioma is the presence of xanthomatous tumor cells [2-5]. These xanthomatous cells have been considered as neoplastic meningothelial cells, not macrophages because these cells were positive for EMA, as also seen in the present case although macrophage markers, such as CD68 and lysozyme, also were expressed [2-5].

This report is the first to examine the immunohistochemical analysis of adipophilin in xanthomatous meningioma. Adipophilin is an antibody that recognizes protein associated with lipid droplets, and is used as a useful immunohistochemical marker [10]. Interestingly, adipophilin was expressed in the xanthomatous area as well as in the conventional meningothelial meningioma component of the present case. This suggests that the conventional meningothelial meningioma component may have lipid droplet within the cytoplasm although xanthomatous differentiation was not observed by light microscopic examination.

Xanthomatous meningioma

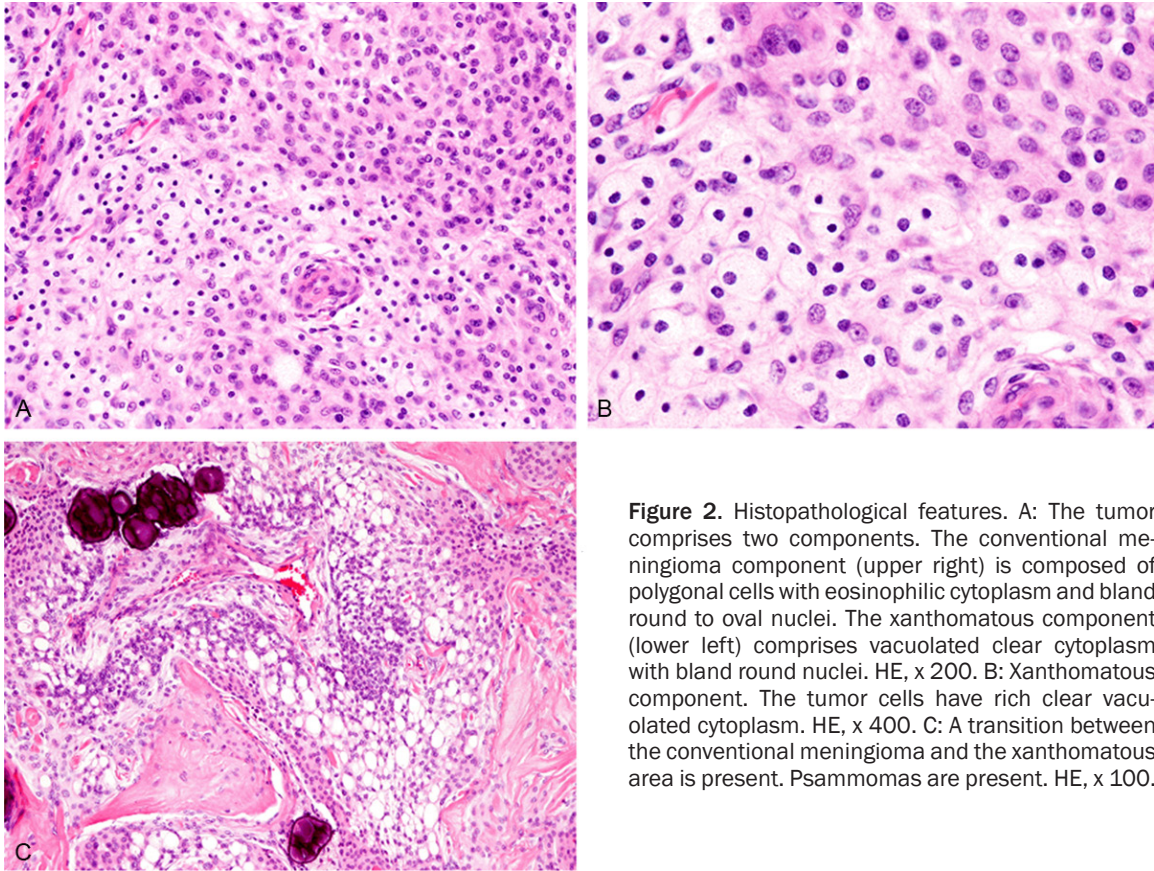


Figure 2. Histopathological features. A: The tumor comprises two components. The conventional meningioma component (upper right) is composed of polygonal cells with eosinophilic cytoplasm and bland round to oval nuclei. The xanthomatous component (lower left) comprises vacuolated clear cytoplasm with bland round nuclei. HE, x 200. B: Xanthomatous component. The tumor cells have rich clear vacuolated cytoplasm. HE, x 400. C: A transition between the conventional meningioma and the xanthomatous area is present. Psammomas are present. HE, x 100.

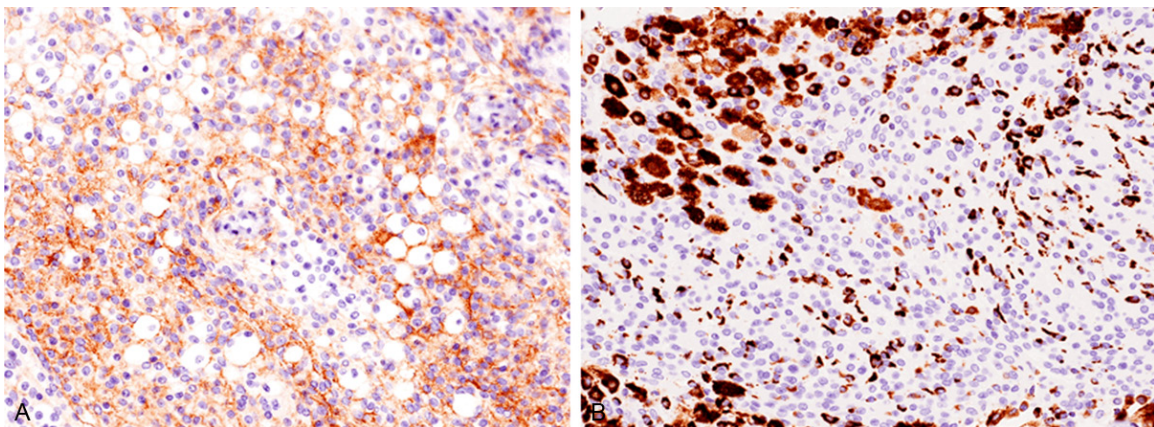


Figure 3. Immunohistochemical features. A: Epithelial membrane antigen is expressed in the xanthomatous area, x 200. B: Adipophilin is expressed in the xanthomatous area as well as in the conventional meningioma, x 200.

Lipomatous meningioma is also a rare histopathological subtype of meningioma that is characterized by the presence of adipocytes [12]. Roncaroli *et al.* reported the clinicopathological features of 18 cases of this type of tumor [11]. In their series, 6 cases had xanthomatous meningothelial cells admixed with adi-

pocyte-like cells, and a transition between the two components was evident in some cases [11]. Lipid deposition was observed in both of the two components, and these changes may appear to result from a metabolic abnormality of the neoplastic meningothelial cells, although the detailed mechanism underlying xanthoma-

Xanthomatous meningioma

Table 1. Clinicopathological features of xanthomatous meningioma

Case No.	Age/ Gender	Location	Transition between conventional meningioma and xanthomatous area	Immuohistochemistry	Reference
1	24/Male	Right parietal	+	CD68 (+)	[2]
2	2/Female	Posterior pyramid	Not available	EMA (+)	[3]
3	10/Male	Right frontal	+	CD68 (+)	[4]
4	61/Female	Right occipital to parietal	+	EMA (+), CD68 (+), Ki-67 LI 2.2%	[5]
Present case	76/Male	Left parasagittal to frontal	+	EMA (+), CD68 (+), adipophilin (+), Ki-67 LI 2.1%	

EMA, epithelial membrane antigen; Ki-67 LI, Ki-67 labeling index.

tous change has not been clarified [11]. Further, as mentioned above, conventional meningothe-
lial meningioma cells showed a positive immu-
noreactivity for adipophilin, therefore, a meta-
bolic abnormality may occur in these cells,
resulting in the obvious xanthomatous change.

Albeit extremely rare, the xanthomatous change
has also been observed in atypical and ana-
plastic meningiomas [12]. Taraszewska *et al.*
reported three cases of atypical meningioma
and two cases of anaplastic meningioma with
xanthomatous changes [12]. The xantha-
tomous change was extensive in all three atypical
meningiomas and focal in the two anaplastic
meningiomas [12]. This change can occur in
atypical and anaplastic meningiomas as well as
grade I meningioma.

In conclusion, we have described a case of xan-
thomatous meningioma. Xanthomatous change
may be caused by a metabolic change in the
neoplastic meningothe-
lial cells, and this
change can occur in atypical and anaplastic
meningiomas. It is important for pathologists to
recognize that xanthomatous change can occur
in meningiomas, and not to misidentify these
cells as macrophages.

Address correspondence to: Dr. Mitsuaki Ishida,
Department of Clinical Laboratory Medicine and
Division of Diagnostic Pathology, Shiga University of
Medical Science, Tsukinowa-cho, Seta, Otsu, Shiga,
520-2192, Japan. Tel: +81-77-548-2603; Fax: +81-
77-548-2407; E-mail: mitsuaki@belle.shiga-med.
ac.jp

References

[1] Perry A, Louis DN, Scheithauer BW, Budka H,
von Deimling A. Meningiomas. World Health
Organization Classification of Tumours of the

Central Nervous System. In: Louis DN, Ohgaki
H, Wiestler OD, Cavenee WK, eds. Lyon: IARC
Press, 2007. pp: 164-172.

- [2] Kepes JJ. Lipidized meningothe-
lial tumor cells in “xanthomatous” meningioma express ma-
crophage antigen. *J Neuropathol Exp Neurol*
1994; 53: 384-388.
- [3] Germano A, Galatioto S, La Rosa G, Caffo M,
Cardia E. Xanthomatous posterior pyramid me-
ningioma in a 2-year-old girl. *Childs Nerv Syst*
1997; 13: 406-411.
- [4] Ijiri R, Tanaka Y, Hara M, Sekido K. Radiation-
associated xanthomatous meningioma in a
child. *Childs Nerv Syst* 2000; 16: 304-308.
- [5] Ikota H, Nakazato Y. A case of metaplastic me-
ningioma with extensive xanthomatous chan-
ge. *Neuropathology* 2008; 28: 422-426.
- [6] Ishida M, Iwai M, Yoshida K, Kagotani A, Okabe
H. Sarcomatoid carcinoma with small cell car-
cinoma component of the urinary bladder: A
case report with review of the literature. *Int J
Clin Exp Pathol* 2013; 6: 1671-1676.
- [7] Ishida M, Mori T, Umeda T, Kawai Y, Kubota Y,
Abe H, Iwai M, Yoshida K, Kagotani A, Tani T,
Okabe H. Pleomorphic lobular carcinoma in a
male breast: case report with review of the lit-
erature. *Int J Clin Exp Pathol* 2013; 6: 1441-
1444.
- [8] Nakanishi R, Ishida M, Hodohara K, Yoshida T,
Yoshii M, Okuno H, Horinouchi A, Iwai M, Yo-
shida K, Kagotani A, Okabe H. Prominent ge-
latinous bone marrow transformation present-
ing prior to myelodysplastic syndrome: a case
report with review of the literature. *Int J Clin
Exp Pathol* 2013; 6: 1677-1682.
- [9] Ishida M, Mochizuki Y, Iwai M, Yoshida K, Kago-
tani A, Okabe H. Pigmented squamous intraep-
ithelial neoplasia of the esophagus. *Int J Clin
Exp Pathol* 2013; 6: 1890-1893.
- [10] Ishida M, Okabe H. Sebaceous carcinoma with
apocrine differentiation (seboapocrine carci-
noma). *Pathol Int* 2012; 62: 438-440.
- [11] Roncaroli F, Scheithauer BW, Laeng RH, Cenac-
chi G, Abell-Aleff P, Moschopoulos M. Lipoma-

Xanthomatous meningioma

tous meningioma. A clinicopathologic study of 18 cases with special reference to the issue of metaplasia. *Am J Surg Pathol* 2001; 25: 769-775.

[12] Taraszewska A, Matyja E, Bogucki J. Xanthomatous changes in atypical and anaplastic

meningiomas. Light and electron microscopic investigations. *Folia Neuropathol* 2000; 38: 125-134.