

Straight sinus thrombosis during neurosurgical operation.

著者	KAWANO Hiroto, NITTA Naoki, NOZAKI Kazuhiko
journal or publication title	Surgical neurology international
volume	7
page range	50
year	2016-05-05
URL	http://hdl.handle.net/10422/00012595

doi: 10.4103/2152-7806.181822(<https://doi.org/10.4103/2152-7806.181822>)

Case Report

Straight sinus thrombosis during neurosurgical operation

Hiroto Kawano, Naoki Nitta, Kazuhiko Nozaki

Department of Neurosurgery, Shiga University of Medical Science, Otsu, Shiga, Japan

E-mail: Hiroto Kawano - hkawano@belle.shiga-med.ac.jp; *Naoki Nitta - nnitta@belle.shiga-med.ac.jp; Kazuhiko Nozaki - noz@belle.shiga-med.ac.jp
*Corresponding author

Received: 05 January 16 Accepted: 24 March 16 Published: 05 May 16

Abstract**Background:** Perioperative straight sinus thrombosis is extremely rare.**Case Description:** A 59-year-old female was admitted to our department because of incidentally found small anterior cerebral artery (A1) aneurysm with microbleeding. After clipping the cerebral aneurysm, she had delayed emergence from anesthesia, total aphasia, and right hemiparesis. Fluid-attenuated inversion recovery (FLAIR) magnetic resonance imaging (MRI) of the head showed hyperintensity in the bilateral caudate nuclei, putamina, and thalami, and computed tomography of the head showed a hyperdense straight sinus, suggesting straight sinus thrombosis. Her neurologic symptoms improved gradually, and she achieved a full clinical recovery, with radiological evidence of recanalization of the straight sinus at follow-up.**Conclusion:** The possibility of straight sinus thrombosis should be considered in postoperative patients with unexplained postoperative deficits when MRI demonstrates hyperintensity in the bilateral basal ganglia and thalami on FLAIR signal images.**Key Words:** Basal ganglia, bilateral, postoperative, straight sinus thrombosis, thalamus

Access this article online

Website:

www.surgicalneurologyint.com

DOI:

10.4103/2152-7806.181822

Quick Response Code:

**INTRODUCTION**

Cerebral venous sinus thrombosis (CVST) is an infrequent form of stroke with several risk factors such as oral contraceptive, postpartum state, infection, and malignancies. CVST has been reported to be extraordinary rare after an intracranial surgery.^[5] Here, we report a case of a 59-year-old woman with suspected temporary straight sinus thrombosis following clipping of an A1 aneurysm.

CASE REPORT

A 59-year-old woman was admitted in our Neurosurgical Department because of a small left A1 aneurysm suspected of microbleeding. The patient had a history of Graves' disease and hypothyroidism. She underwent clipping of the aneurysm using pterional approach. There were no intraoperative complications; no cerebral

contusion, premature rupture, or brain swelling. After the operation, she had delayed emergence from anesthesia, total aphasia, and right hemiparesis (the Medical Research Council scale; upper and lower limbs: 1/5). Glasgow coma scale scored 7 (E: 2; V: 1; M: 4). A plane computed tomographic (CT) scan of the head, obtained immediately after the operation, showed no intracerebral hemorrhage. Fluid-attenuated inversion recovery (FLAIR) magnetic resonance imaging (MRI) of the head after the CT scan showed moderate

This is an open access article distributed under the terms of the Creative Commons Attribution-NonCommercial-ShareAlike 3.0 License, which allows others to remix, tweak, and build upon the work non-commercially, as long as the author is credited and the new creations are licensed under the identical terms.

For reprints contact: reprints@medknow.com**How to cite this article:** Kawano H, Nitta N, Nozaki K. Straight sinus thrombosis during neurosurgical operation. *Surg Neurol Int* 2016;7:50.
<http://surgicalneurologyint.com/Straight-sinus-thrombosis-during-neurosurgical-operation/>

hyperintensity in the bilateral caudate nuclei, putamina, and thalami [Figure 1a]. We first suspected that she might be suffering from a metabolic disorder such as an acid-base imbalance, a glucose metabolism disorder, and so on. She was transferred to Intensive Care Unit and underwent laboratory tests, but all results were normal. Next, we suspected ischemic stroke caused by occlusion of perforators from the left A1 or M1; however, diffusion-weighted images (DWIs) of the head showed no apparent ischemic injury, other than a small focus of mildly increased signal in the left putamen. We also suspected that generalized epilepsy might cause the neurologic deterioration, and she was treated with phenytoin. Since the MR angiography showed no apparent occlusion and she was in the postoperative course, we treated her with low molecular weight dextran as a plasma volume expander and to decrease platelet aggregation, and with hydrocortisone for possible adrenal insufficiency.

Although we suspected straight sinus thrombosis after reviewing the postoperative CT and MRI images, a repeat MRI scan the day after surgery showed normal enhancement of the straight sinus on postcontrast T1-weighted images (TIWIs), which looked the same as the straight sinus shown by preoperative digital subtraction angiography (DSA). DWI showed hyperintense basal ganglia, and we treated her with a thromboxane A₂ inhibitor. Results of hematologic test; tests of coagulation, renal function, and liver function; electrolyte levels; complement levels, C3, and C4; levels of thyroid-stimulating hormone, free T₃ and free T₄; anti-DNA antibodies; levels of protein S and protein C; levels of anticardiolipin antibodies; and level of rheumatoid factor were normal. At 5 days after the operation, FLAIR showed decreased hyperintensity in the basal ganglia and thalami, DWI no new lesion, and postcontrast TIWI no CVST [Figure 1b]. Physical examination showed improved neurological symptoms, and we stopped administering thromboxane A₂ inhibitor.

At 6 days after the operation, postcontrast CT of the abdomen showed a thrombus in the right femoral vein, we started administration of heparin and then warfarin.

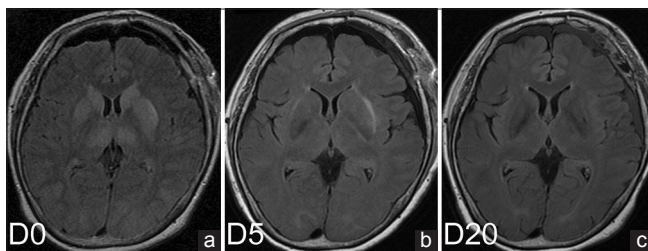


Figure 1: Postoperative fluid-attenuated inversion recovery immediately after the operation (a), at 5 days after the operation (b) and at 20 days after the operation (c). Note that hyperintensity in the bilateral basal ganglia and thalami improved with time

We continued the administration of warfarin, and the prothrombin time-international normalized ratio was between 1.5 and 2.5. At 20 days after the operation, FLAIR showed no hyperintensity in the basal ganglia or thalami [Figure 1c]. She was discharged without any neurologic symptoms at 41 days after the operation.

We reviewed postoperative sagittal plane CT images, and we found that the CT immediately after the operation revealed transient hyperdensity in the straight sinus, which hyperdensity was not observed on CT at 1 month after the operation [Figure 2a and b]. Although we could not find any fine image of thrombus in the straight sinus on the emergent MRI after the CT, FLAIR showed hyperintense in the bilateral basal ganglia and thalami, which is a characteristic of straight sinus thrombosis. The CT and MRI findings suggested that she suffered from transient straight sinus thrombosis during the operation, and it resolved before the next day's postcontrast TIWI.

DISCUSSION

The present report describes a case of straight sinus thrombosis after an intracranial surgery. Although we did not recognize the patient's condition at the onset or treat her with any anticoagulants or endovascular intervention, the straight sinus appears to have rapidly recanalized leading to the resolution of symptoms.

The patient had no major risk factors such as pregnancy, puerperium, oral contraceptive use, infection, malignancy, or trauma.^[3] The trigger of CVST in the present case was neurosurgery, which has been reported to be a risk factor only in 0.6% of CVST patients.^[5] In view of the fact that the incidence of CVST was reported to be 1.32/100,000/year, CVST after neurosurgery is considered to be very rare. Other risk factor for the present case was thyroid disease, which was reported to account for only 1.7% of all patients.^[5]

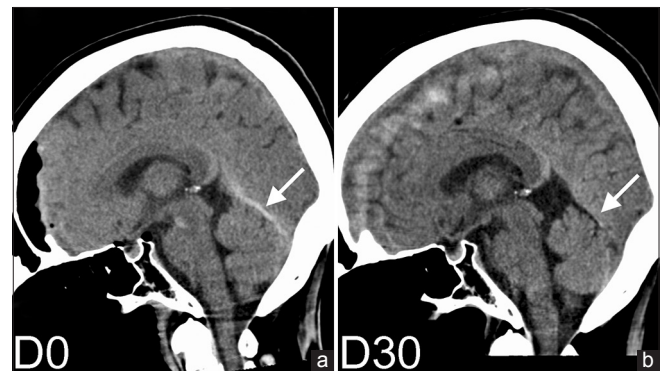


Figure 2: Sagittal plane computed tomography images immediately after the operation (a) and at 1 month after the operation (b). Arrows indicate the straight sinus. Hyperdensity in the straight sinus resolved spontaneously

Why did neurosurgery trigger CVST in the present case? Almost all CVST after brain surgery followed procedures performed in the vicinity of the sinuses.^[9,10] Laceration, compression, or drying of the sinus during operation can cause intra- or post-operative CVST.^[10] However, the straight sinus was distal to the area of the surgical corridor in the present case. Only two distant CVST cases have previously been reported, in which the thrombosed sinuses were not directly manipulated during operation.^[8,11] Another possible etiology for CVST is intracranial hypotension. Lumbar puncture has been reported as a minor risk factor of CVST.^[5] Canhão *et al.* reported that the lumbar puncture induces an average 47% reduction of mean blood flow velocities of the straight sinus and suggested that decrease of venous blood flow is a possible mechanism contributing to the occurrence of CVST.^[2] In the present case, the arachnoid cisterns were opened, and cerebrospinal fluid was removed during the operation, which probably resulted in intracranial hypotension. We speculate that intracranial hypotension during the operation might have decreased venous flow and contributed to straight sinus thrombosis.

Although we could not initially consider straight sinus thrombosis in this case; fortunately, it resolved spontaneously. In the previous two cases of perioperative straight sinus thrombosis, the patients also had sagittal sinus thrombosis and died on the 2nd and 9th postoperative days, respectively.^[8,11] In general, patients with straight sinus thrombosis present with acute headache, nausea, vomiting, seizures, altered mental status, focal neurologic deficits, coma, and/or death because of venous infarction of the bilateral thalami and basal ganglia.^[6] Typical MRI findings are high signal intensity and swelling of the bilateral thalami, internal capsules, and basal ganglia on T2WI and FLAIR.^[1,4,6] The relationship between the MRI findings of bilateral thalami and the straight sinus thrombosis is as follows. The straight sinus drains blood from the internal cerebral veins and basal veins on both the left and right via the great cerebral vein. Thus, thrombosis of the straight sinus can result in bilateral venous hypertension of the region drained by the internal cerebral veins and basal veins, namely, the thalami and basal ganglia, without cerebral lobar.^[12] At neuroimaging, venous hypertension and cerebral edema caused by straight sinus thrombosis typically result in high signal intensity in the bilateral thalami and basal ganglia.^[1,6] In the present case, FLAIR showed characteristic hyperintensity in the bilateral basal ganglia and thalami as mentioned above. Furthermore, the initial CT scan after the operation showed a hyperdense straight sinus, which has also been reported in cases of straight sinus thrombosis.^[7,13] When nonenhanced CT shows a hyperdense straight sinus and/or MRI shows FLAIR

signal changes in the bilateral basal ganglia and thalami, we should consider the possibility of straight sinus thrombosis and perform CT venography, MR venography, or DSA.

CONCLUSION

We report a case of a 59-year-old woman with straight sinus thrombosis after a neurosurgical operation. If sagittal plane CT image shows a hyperdense straight sinus or FLAIR shows hyperintensity in the bilateral basal ganglia and/or thalami, we should consider the possibility of straight sinus thrombosis.

Acknowledgment

We are grateful to Toshihiro Yokoi and Hiroki Matsui for fruitful discussions and helpful comments.

Financial support and sponsorship

Nil.

Conflicts of interest

There are no conflicts of interest.

REFERENCES

1. Ben-Dov M, Inbar E, Steiner I. Cerebral straight sinus thrombosis: An unusual cause of confusion. *JAMA Neurol* 2015;72:1527.
2. Canhão P, Batista P, Falcão F. Lumbar puncture and dural sinus thrombosis – A causal or casual association? *Cerebrovasc Dis* 2005;19:53-6.
3. Coutinho JM, Zuurbier SM, Stam J. Declining mortality in cerebral venous thrombosis: A systematic review. *Stroke* 2014;45:1338-41.
4. Ferro JM, Canhão P, Bousser MG, Stam J, Barinagarrementeria F, Stolz E; ISCVT Investigators. Cerebral venous thrombosis with nonhemorrhagic lesions: Clinical correlates and prognosis. *Cerebrovasc Dis* 2010;29:440-5.
5. Ferro JM, Canhão P, Stam J, Bousser MG, Barinagarrementeria F; ISCVT Investigators. Prognosis of cerebral vein and dural sinus thrombosis: Results of the International Study on Cerebral Vein and Dural Sinus Thrombosis (ISCVT). *Stroke* 2004;35:664-70.
6. Hegde AN, Mohan S, Lath N, Lim CC. Differential diagnosis for bilateral abnormalities of the basal ganglia and thalamus. *Radiographics* 2011;31:5-30.
7. Iwashita T, Kitazawa K, Koyama J, Nagashima H, Koyama T, Tanaka Y, *et al.* Subtle computed tomography abnormalities in cerebral deep sinus thrombosis. *J Clin Neurosci* 2007;14:68-71.
8. Kozasa Y, Takaseya H, Koga Y, Hiraki T, Mishima Y, Niiyama S, *et al.* A case of delayed emergence from anesthesia caused by postoperative brain edema associated with unexpected cerebral venous sinus thrombosis. *J Anesth* 2013;27:764-7.
9. Lega BC, Yoshor D. Postoperative dural sinus thrombosis in a patient in a hypercoagulable state. Case report. *J Neurosurg* 2006;105:772-4.
10. Ohata K, Haque M, Morino M, Nagai K, Nishio A, Nishijima Y, *et al.* Occlusion of the sigmoid sinus after surgery via the presigmoidal-transpetrosal approach. *J Neurosurg* 1998;89:575-84.
11. Redhu S, Mohd Abdul M, Pandey P, Devaragudi TS. Distant cerebral venous sinus thrombosis in meningioma surgery: A rare complication. *Neurol India* 2013;61:180-1.
12. Schuenke M, Schulte E, Schumacher U, Rude J. *Atlas of Anatomy; Head and Neuroanatomy.* Stuttgart: Thieme; 2007.
13. Sidhu M, Footitt D, Donaldson I, Hughes S, Wuppapapati S, Emsley HC. Intact neurological outcome after neurointerventional treatment for intracranial venous thrombosis with straight sinus involvement. *BMJ Case Rep* 2013;2013. pii: Bcr2013010242.