

Available online at www.sciencedirect.com

ScienceDirect

journal homepage: www.elsevier.com/locate/radcr

Case Report

99m-Tc galactosyl human serum albumin scanning to evaluate liver function after stereotactic body radiotherapy for hepatocellular carcinoma: A case report

Osamu Tanaka, MD^{a,*}, Kazutaka Miki, RT^a, Takuya Taniguchi, MP^a, Takao Kojima, MD^b, Akihiro Ohbora, MD^b, Chiyoko Makita, MD^c, Masayuki Matsuo, MD^d

^a Asahi University Hospital, Department of Radiation Oncology, 3-23 Hashimoto-cho, Gifu, Gifu 500-8523, Japan

^b Asahi University Hospital, Department of Gastroenterology, Gifu, Japan

^c Gifu Prefectural General Medical Center, Department of Radiation Oncology, Gifu, Japan

^d Gifu University Hospital, Department of Radiation Oncology, Gifu, Japan

ARTICLE INFO

Article history:

Received 9 May 2019

Revised 27 August 2019

Accepted 2 September 2019

Keywords:

Radiotherapy

Liver function

99m-Tc GSA-SPECT/CT

ABSTRACT

The primary choice among treatment options for liver malignancies is surgery. However, if surgery cannot be performed, Stereotactic body radiotherapy (SBRT) may be effective. 99m-technetium galactosyl human serum albumin (GSA) single-photon emission computed tomography (SPECT) imaging is useful for the assessment of liver function before surgery. We report the case of a 77-year-old man who had undergone SBRT for hepatocellular carcinoma of the left lobe of the liver 2 years previously. Follow-up revealed a 15-mm hepatocellular carcinoma at the edge of the right lobe of the liver. 99m-technetium GSA SPECT was performed before SBRT to confirm that there was no accumulation in the left lobe and to ensure that there was good function of the right lobe. Three months after SBRT, the tumor had responded, and decreases in GSA accumulation were observed in line with the radiation beam. Because hepatocellular carcinoma often relapses, it is important to assess the anatomic site of liver dysfunction before and after radiation. This case demonstrates that 99m-technetium GSA SPECT is useful for this purpose.

© 2019 The Authors. Published by Elsevier Inc. on behalf of University of Washington.

This is an open access article under the CC BY-NC-ND license.

(<http://creativecommons.org/licenses/by-nc-nd/4.0/>)

Declaration of Competing Interest: None.

Funding support: None.

National clinical study registered number UMIN000035026 (UMIN-CTR, Japan).

* Corresponding author.

E-mail address: c.bluered@gmail.com (O. Tanaka).

<https://doi.org/10.1016/j.radcr.2019.09.002>

1930-0433/© 2019 The Authors. Published by Elsevier Inc. on behalf of University of Washington. This is an open access article under the CC BY-NC-ND license. (<http://creativecommons.org/licenses/by-nc-nd/4.0/>)

Introduction

Malignant liver tumors can be treated with hepatectomy, radiofrequency ablation, or transarterial chemoembolization.

Hepatectomy is associated with the best outcomes [1–4]. However, patients requiring extensive resection or who have liver disease with compromised hepatocellular function are at high risk of developing postoperative liver failure.

Stereotactic body radiotherapy (SBRT) is increasingly available and is another option for treatment of localized liver tumors. However, just as with surgery, it is important to predict hepatic reserve before and after treatment. An accurate assessment of liver reserve is intended to reduce the risk of liver failure after irradiation.

One way to measure liver function rapidly and noninvasively is by measuring the clearance of indocyanine green (ICG) [4]. ICG elimination, expressed as the ICG plasma disappearance rate or the retention rate at 15 minutes (ICG-R15), assesses relative ICG concentration changes. Another technique uses 99m-technetium galactosyl human serum albumin (GSA)-single-photon emission computed tomography (SPECT). Although this has been used primarily for preoperative evaluation of hepatocellular carcinoma (HCC) to be treated surgically, it could also be used for patients who will undergo targeted SBRT [5–10]. We report a case in which GSA was used to assess functional liver reserve both before and after SBRT, comparing it with the results of ICG clearance testing.

Case report

A 77-year-old man had been diagnosed with chronic hepatitis C about 20 years previously. In 2016, he was treated with

transarterial chemoembolization and SBRT (40 Gy in 10 fractions) for HCC in the left lobe of his liver (Fig. 1A). No recurrence was seen over the next 2 years. There was no accumulation of GSA in images of the left hepatic lobe (Fig. 1B), and contrast-enhanced CT showed no tumor (Fig. 1C).

In 2018, a 15-mm HCC was seen in the right hepatic lobe. Laboratory data were as follows: Hemoglobin, White blood cells, platelet, alanine aminotransferase (ALT), aspartate aminotransferase (AST), alkaline phosphatase and bilirubin, albumin, bilirubin, and prothrombin time were within normal limits before and after SBRT. Tumor marker α -fetoprotein (AFP) was maintained below 10 ng/mL; however, the amount of protein induced by vitamin K absence or antagonist-2 (PIVKA-2) was increasing (395 AU/mL), and thus, SBRT was planned.

Because the tumor was close to the kidney, radiofrequency ablation was considered too dangerous, and radiotherapy was therefore scheduled (Fig. 2). The pretreatment ICG-R15 value was 14%. We treated the right hepatic HCC with SBRT (42 Gy in 4 fractions) (Fig. 3A). Three months later, the ICG-R15 value had slightly deteriorated to 18%. Irradiated tumor disappeared (Fig. 3B). GSA imaging at that time showed decreased accumulation along the beam path (Fig. 3C,D).

With a cutoff value of counts of 150 in the pre- and post-treatment GSA images, the volume of accumulation in the liver showed a 40-cc drop from 1280 to 1240 cc. The volume of the liver overall did not otherwise change (1333 and 1322 cc.) The tumor marker PIVKA-2 was decreased (54 AU/mL).

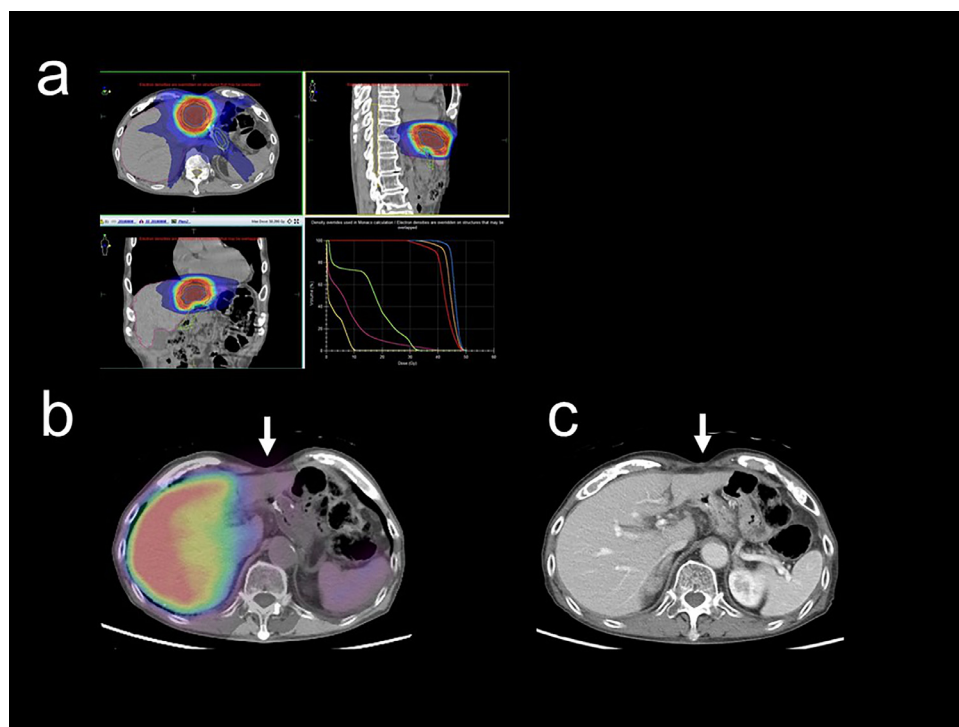


Fig. 1 – Initial radiotherapy for left lobe of the liver. (A) Radiotherapy planning to treat HCC in the left lobe using 40 Gy/10 fractions in 2016. Dose volume histogram; left lower image. Red line: planning target volume. Green line: stomach wall. Purple line: whole liver. (B) 99m-Tc GSA-SPECT/CT image after SBRT showing no accumulation in the left lobe of the liver where (arrow) the tumor had been treated. (C) No evidence of recurrence is seen on contrast-enhanced CT (arrow). GSA, galactosyl human serum albumin.

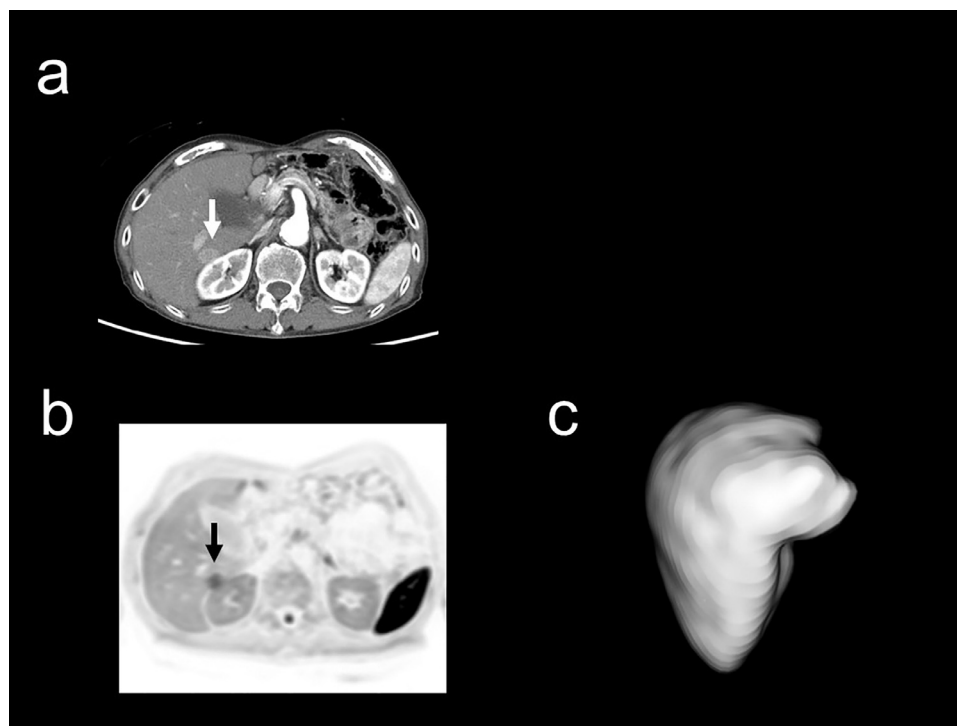


Fig. 2 – Two years after initial radiotherapy for left lobe of the liver. (A) Contrast-enhanced CT showing a 15-mm tumor at the edge of the right lobe of the liver (arrow). (B) Diffusion-weighted MR image shows a tumor with a reduced apparent diffusion coefficient at the edge of the right lobe (arrow). (C) There is no abnormality around the tumor in a 99m-Tc GSA-SPECT/CT Image before SBRT. GSA, galactosyl human serum albumin.

Discussion

CT is the modality commonly used in the planning of hepatectomy. Although quantitative evaluation using GSA as a nuclear medicine technique has been used, it was thought insufficient as a simulation before surgery [4]. However, the use of SPECT/CT has allowed prehepatectomy evaluation that gives both functional and spatial information, providing a more useful assessment than CT alone [5–8]. What is of particular interest in our case is the use of 99m-Tc GSA-SPECT/CT before SBRT, not surgical resection.

Evaluation of liver function by contrast-enhanced CT

Contrast-enhanced CT is widely used in prehepatectomy simulations because it provides anatomical information necessary for planning lines of separation such as along veins and portal veins. Generally, in the simulation by contrast-enhanced CT, measurements include the total liver volume and the volume of the area to be resected. The ratio of the volume of the resected area to the total liver volume (volume resection rate) is then calculated. However, the volume assessment alone cannot reflect impairment of liver function at the histologic level. The distribution of abnormal function may be uneven in the presence of chronic hepatitis or when tumors involve vessels. Similarly, when planning ablation with SBRT, the volume ablation rate may be under- or overestimated by CT imaging alone. Therefore, in cases of likely functional

heterogeneity, pre-SBRT simulation requires the addition of functional assessment.

Utility of 99m-Tc GSA scintigraphy

GSA is a synthetic glycoprotein that exhibits the same *in vivo* behavior as the asialoglycoprotein expressed on the sinusoidal surface of normal hepatocytes. GSA specifically binds to the asialoglycoprotein receptor. Therefore, GSA can reflect the number and function of normal hepatocytes. In terms of quantitative evaluation by scintigraphy alone, the HH15 (clearance index) and LHL15 (receptor index), calculated from dynamic study by planar image, are generally used. HH15 and LHL15 are simple and reproducible indicators useful for evaluating the reserve capacity of the entire liver. However, the planar image lacks anatomical information. Also, it is not possible to correct for the influence of the attenuation of accumulation due to the distance from the body surface. Therefore, liver function may be over- or underestimated.

The introduction of SPECT has partially addressed this problem. The use of SPECT images gives more anatomical information than planar images [5,8,10]. However, because SPECT still does not provide adequate anatomical information, particularly about blood vessels, only a rough estimate can be made for planning resection lines.

The Chang method has been used to correct for attenuation in order to improve the quantitative results of SPECT images. However, the liver is not uniform, and its relationship with surrounding organs and bones is more complicated

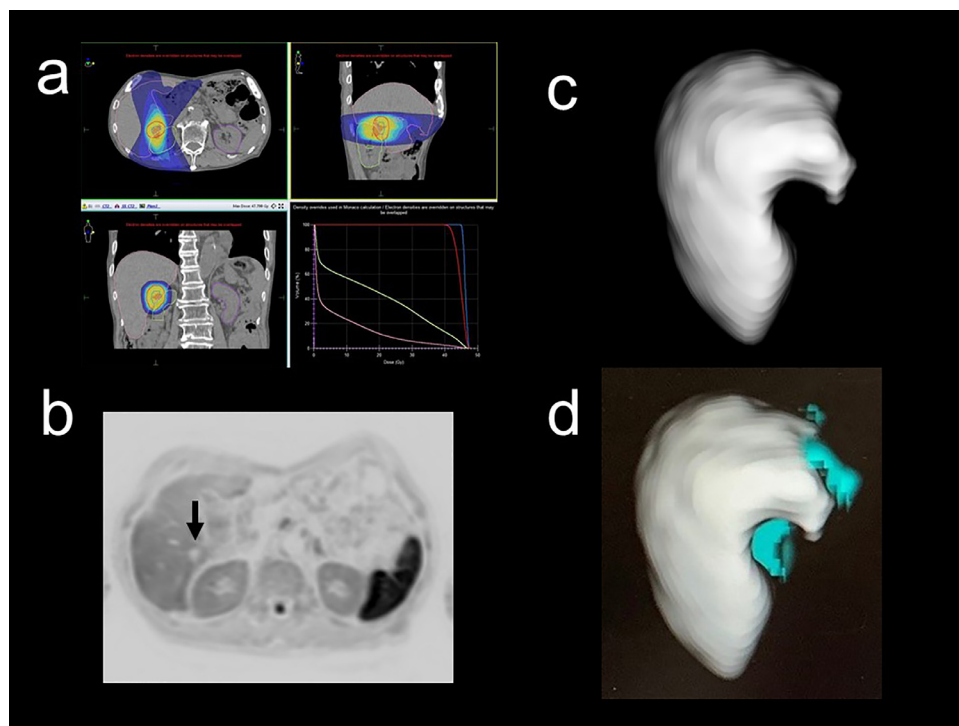


Fig. 3 – Three month after treatment of recurrence in right lobe of the liver. (A) SBRT beam planning. Red line defines the planning target volume. Yellow indicates 95% coverage of the prescribed dose (42 Gy/4 fractions). Dose volume histogram. Red line: planning target volume. Green line: right kidney. Pink line: whole liver. (B) Diffusion-weighted MR image. There is no abnormal intensity in the whole liver and irradiated tumor was disappeared (arrow). (C) A defect in accumulation in line with the radiation beam is observed in the 99m-Tc GSA-SPECT/CT Image. (D) Image obtained by subtracting GSA accumulation after radiation treatment from GSA before radiotherapy. The subtracted area is shown in blue. GSA, galactosyl human serum albumin.

than that of other structures such as the brain. Therefore, the Chang method is not sufficient for attenuation correction in 99m-Tc GSA-SPECT images.

Method for using 99m-Tc GSA-SPECT for functional image prior to liver SBRT

There are a few reports of scintigraphy used for evaluation of liver reserve before radiotherapy. Fukugawa et al reported that gadolinium ethoxybenzyl diethylenetriamine pentaacetic acid (Gadolinium-EOB-DTPA)-enhanced MRI was useful for predicting hepatic function in cases where 3-dimensional radiotherapy was used. The percentage of the whole liver volume receiving a dose of more than 30–40 Gy is a potential candidate optimal DVH parameter for this fractionation schedule [6]. They concluded that in patients with HCC who undergo 3D-CRT in 15 fractions, the threshold dose for focal liver reaction is nearly 35 Gy. In contrast, we did not perform MRI. One reason is that the value of PIVKA-2 decreased in blood tests. No decrease was observed in liver function in the ICG test. In our hospital, screening is performed by echo after 6 months of treatment or when signs of recurrence appear. Contrast-enhanced MRI or contrast-enhanced CT is performed when a tumorous lesion is found in the echo.

Fukugawa et al evaluated using 3-dimensional RT; in contrast, we performed SBRT, and the relationship between MRI

and GSA might be different from that evaluated by Fukugawa et al. In the case of SBRT, because the high dose was irradiated, the liver function was locally abolished only at the site from where the beam passed, as shown in Figure 3. The same phenomenon occurred as when the left lobe of the liver was irradiated 2 years ago (Fig. 1). In our hospital, a session is currently being conducted to evaluate the relationship between MRI and GSA.

Son et al reported on factors predicting a reduction in liver function after helical tomotherapy [7]. An increase of at least 2 points in the Child-Pugh class score is a radiation dose-limiting factor, and the nontarget normal liver receiving a dose more than 15 Gy (V15 Gy) should be <43.2% to reduce the risk of the deterioration of hepatic function. In a retrospective analysis of 12 patients Toya et al reported that previous treatments significantly influenced the parametric discrepancy between dose-function histogram and DVH. The use of dose-function histogram may facilitate the detection of dosimetric parameters for the precise prediction of radiation-induced liver toxicity [8]. Dyk et al reported on the effect of high-dose SBRT on liver function. Approximately one-quarter of patients experience a decline in Child-Pugh class after high-dose liver SBRT [9]. The V25 may be an important dosimetric parameter predicting decline in liver function after treatment. A V25 > 32% was associated with a 42% incidence of Child-Pugh class decline compared with 9% for V25 ≤ 32 (P = .029). For primary

liver malignancies, a $V25 > 36\%$ was associated with a 4-fold increase in the incidence of Child–Pugh class decline (60% vs 15%, $P = 0.021$).

We subtracted the GSA count value after treatment from the value before treatment and evaluated the region in which treatment diminished liver function in a 3-dimensional image (Fig. 3). We think that creating this 3-dimensional image is useful for beam planning with noncoplanar imaging. Specifically, treatment can be planned to avoid as much as possible passing the beam through the normal liver. Rather, the aim is to pass it through a portion that is already nonfunctioning.

The challenge is deciding the cutoff of the count value. We are planning to accumulate more cases to develop a quantitative method based not only on the liver structure but also the body type and subcutaneous fat. The correlation between the results of ICG tests and those of GSA imaging need to be examined in more detail.

In our patient, GSA was useful to assess the distribution of hepatic reserve before and after SBRT. Additionally, the decrease in the GSA count value was similar to the decrease in liver function indicated by the ICG test. Because HCC often recurs, repeat treatment with irradiation may be necessary. Functional imaging with GSA is a useful option for evaluating liver reserve and for radiotherapy beam planning.

Acknowledgments

None

Supplementary materials

Supplementary material associated with this article can be found, in the online version, at doi:[10.1016/j.radcr.2019.09.002](https://doi.org/10.1016/j.radcr.2019.09.002).

REFERENCES

- [1] Klein J, Dawson LA. Hepatocellular carcinoma radiation therapy: review of evidence and future opportunities. *Int J Radiat Oncol Biol Phys* 2013;87:22–32.
- [2] Liang SX, Huang XB, Zhu XD, Zhang WD, Cai L, Huang HZ, et al. Dosimetric predictor identification for radiation-induced liver disease after hypofractionated conformal radiotherapy for primary liver carcinoma patients with Child–Pugh Grade A cirrhosis. *Radiother Oncol* 2011;98:265–9.
- [3] Sanuki N, Takeda A, Oku Y, Mizuno T, Yosuke A, Eriguchi T, et al. Stereotactic body radiotherapy for small hepatocellular carcinoma: a retrospective outcome analysis in 185 patients. *Acta Oncol* 2014;53:399–404.
- [4] Gasperi A, Mazza E, Prosperi M. Indocyanine green kinetics to assess liver function: ready for a clinical dynamic assessment in major liver surgery? *World J Hepatol* 2016;8:355–67.
- [5] Tsuruga Y, Kamiyama T, Kamachi H, Shimada S, Wakayama K, Orimo T, et al. Significance of functional hepatic resection rate calculated using 3D CT/(99m)Tcgalactosyl human serum albumin single-photon emission computed tomography fusion imaging. *World J Gastroenterol* 2016;22:4373–9.
- [6] Fukugawa Y, Namimoto T, Toya R, Saito T, Yuki H, Matsuyama T, et al. Radiation-induced liver injury after 3D-conformal radiotherapy for hepatocellular carcinoma: quantitative assessment using Gd-EOB-DTPA enhanced MRI. *Acta Med Okayama* 2017;71:25–9.
- [7] Son SH, Kay CS, Song JH, Lee SW, Choi BO, Kang YN, et al. Dosimetric parameter predicting the deterioration of hepatic function after helical tomotherapy in patients with unresectable locally advanced hepatocellular carcinoma. *Radiat Oncol* 2013;8:11.
- [8] Toya R, Saito T, Shiraishi S, Kai Y, Murakami R, Matsuyama T, et al. Dose-function histogram evaluation using 99mTc-GSA SPECT/CT images for stereotactic body radiation therapy planning for hepatocellular carcinoma patients: a dosimetric parameter comparison. *Anticancer Res* 2018;38:1511–16.
- [9] Dyk P, Weiner A, Badiyan S, Myerson R, Parikh P, Olsen J. Effect of high-dose stereotactic body radiation therapy on liver function in the treatment of primary and metastatic liver malignancies using the Child–Pugh score classification system. *Pract Radiat Oncol* 2015;5:176–82.
- [10] Shen S, Jacob R, Bender LW, Duan J, Spencer SA. A technique using 99mTc-mebrofenin SPECT for radiotherapy treatment planning for liver cancers or metastases. *Med Dosim* 2014;39:7–11.