

# Tuberculosis of the Ankle: A Case Report

Drew Newhoff MD<sup>†</sup> and Richard Miller MD<sup>†</sup>

<sup>†</sup>UNM Department of Orthopaedics and Rehabilitation

## Introduction

Tuberculosis was one of the leading causes of death in the United States during the late 19th and early 20th centuries.<sup>1</sup> New Mexico has an interesting history with regard to tuberculosis since many people migrated to this region during that time period seeking treatment in the warm, dry climate.<sup>2</sup> Today, public health efforts and antibiotics have greatly decreased the incidence and mortality of tuberculosis in this country. In spite of these measures, TB has not been eradicated. In 2013, 50 active cases were diagnosed in New Mexico.<sup>3</sup> Immune-compromised state, poverty, and immigration contribute to its persistence.

We present the case of a 60 year old female who complained of chronic ankle pain which was ultimately diagnosed as *Mycobacterium tuberculosis*. Her risk factors included origin in the Philippines and immune-compromised state from medications she receives as a kidney transplant recipient. This is the first case of foot or ankle TB the senior author has ever encountered during 28 years as a physician at the University of New Mexico.

## Case History

ET is a 60 year old Philippine female with end-stage renal disease secondary to polycystic kidney disease with post cadaveric renal transplant on 1/31/12. She immigrated to the United States as a child. Post-transplant, she was managed on tacrolimus and prednisone to prevent rejection. The patient presented to rheumatology on 10/17/12 with a several week history of left ankle pain. Plain radiographs demonstrated an effusion without osseous abnormality. (Figure 1) Laboratory workup at that time demonstrated WBC 10.5, ESR 85, and CRP 10.2. These values were consistent with her post-transplant laboratories. Aspiration of the left ankle was performed in the rheumatology clinic. Total nucleated cell count was 1200 with no crystals. Aerobic and anaerobic cultures were negative. Intra-articular corticosteroid injections were performed for pain relief on 10/24/12 and 12/5/12. These did provide some pain relief for the patient.

The patient initially presented to the orthopedic service after acute worsening of her symptoms. She sought care in the emergency department on 12/27/12 after four days of severe left ankle pain with inability to ambulate. Examination at that time demonstrated a joint effusion with tenderness to palpation around the ankle joint. She had limited range of motion secondary to pain and an intact neurovascular exam. WBC count was 6.6, ESR 84, and CRP 12.2. Radiographs were unchanged. A repeat aspiration was performed. Total nucleated cell count was 2400 with 96% neutrophils and no crystals. An MRI was obtained which demonstrated nonspecific talar body edema with synovitis and a small joint effusion (Figure 2). Initial cultures were negative, and the patient was discharged home with pain medications. Positive acid-fast bacillus cultures resulted 15 days later and demonstrated growth of multi-drug resistant *Mycobacterium tuberculosis*. She was taken to the operating room on 1/17/13 for arthroscopic irrigation and debridement of the left ankle and had significant

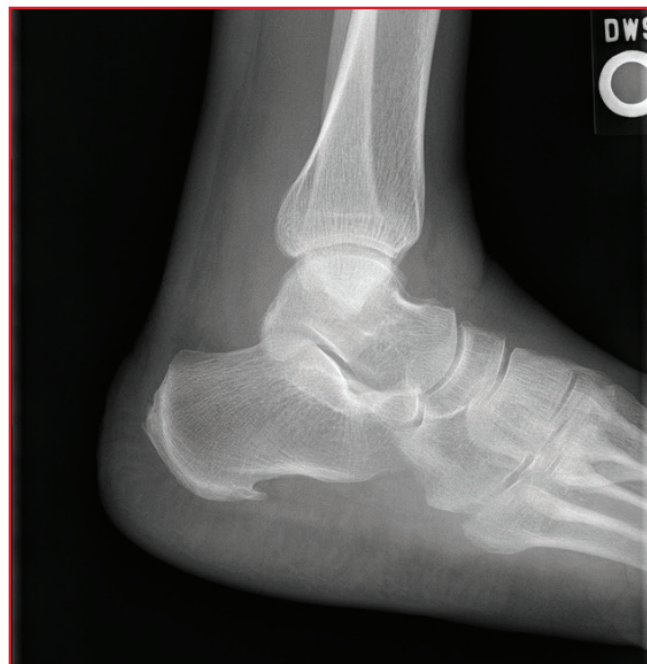

Figure 1: Lateral ankle radiograph of the patient on presentation demonstrating a small joint effusion.

intra-articular purulent material. The infectious disease specialists were consulted who started the patient on an appropriate antibiotic regimen with a 24-month duration of therapy. CT of the chest demonstrated no pulmonary lesions and AFB sputum sample was negative. The patient reported no fevers, night sweats, or weight loss. She had no history of immunization or treatment for tuberculosis. Repeat irrigation and debridement was performed 1/21/13 due to the significant purulence noted on her initial surgery. The patient was discharged from the hospital on 2/11/13. Her surgical incisions healed without complication. At her most recent follow up (7/19/13), the patient had some residual intermittent pain in her left ankle that was improving. She was able to ambulate with intermittent need of a walker, and was discharged from clinic on that date.

## Discussion

Tuberculosis is caused by infection with the bacteria *Mycobacterium tuberculosis*. This is an aerobic bacillus which demonstrates acid fast properties on gram stain.<sup>4</sup> The majority of people who carry the bacteria are asymptomatic and noninfectious though they may convert to develop acute illness. When patients become ill with acute tuberculosis, the lungs are most commonly affected with symptoms of chronic cough, fever, night sweats, and weight loss. Extrapulmonary tuberculosis occurs in 15-20 % of active cases and is more common in immunosuppressed people.<sup>5</sup>

Extrapulmonary tuberculosis involving the ankle joint is rare and the diagnosis is often delayed.<sup>6,7</sup> As with this patient,

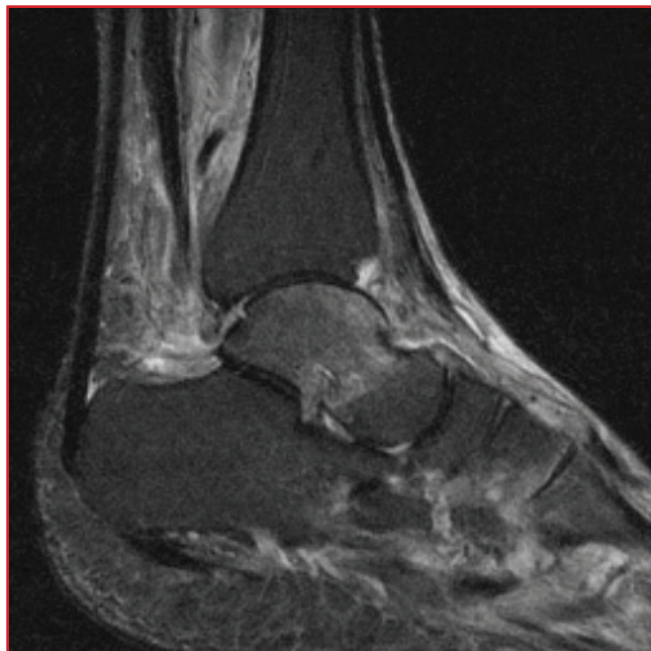


Figure 2: T2-weighted MRI image of the patient on presentation. Note edema of the talus and synovitis of the ankle joint and joint effusion.

symptoms, labs, joint fluid analysis, and radiographic evaluation can be nonspecific. The differential diagnosis includes other infectious, traumatic, neoplastic, and inflammatory conditions along with avascular necrosis of the talus.<sup>8</sup> Synovial fluid cultures require a long incubation period and are frequently negative.<sup>9</sup> Surgical biopsy may be required for diagnosis.<sup>6</sup> Antituberculosis medication is the main treatment for tuberculosis of the ankle. Surgical debridement may be required for significant synovitis or purulence, and arthrodesis is indicated for painful joint destruction.<sup>9</sup>

The patient presented was originally from the Philippines where tuberculosis is common. The World Health Organization ranks the Philippines as one of the highest TB burdened countries in the world.<sup>10</sup> The Philippines is the second most frequent country of origin for non-US born TB patients in the United States.<sup>11</sup> Patients with renal transplants on immunosuppressive medication to prevent rejection are also at increased risk of developing tuberculosis.<sup>12,13,14</sup> This patient was on tacrolimus to help prevent rejection of a renal transplant she received approximately eleven months prior to being evaluated for ankle pain and swelling. She also had no pulmonary lesions which has previously been reported following infection with foot and ankle tuberculosis.<sup>15,16</sup>

In the United States, where the presentation of skeletal tuberculosis is exceedingly rare, considering it in the differential diagnosis of a patient with similar clinical features as the one presented here may result in an earlier diagnosis and treatment.

## References

1. Jones DS, Podolsky SH, Greene JA. The burden of disease and the changing task of medicine. *New England Journal of Medicine*. 2012;366(25):2333-8.
2. Lewis NO. Chasing the cure in New Mexico: The lungers and their legacy. *El Palacio*. 2008;113(4):40-7.
3. Infectious disease in New Mexico: 2013 annual report. New Mexico Department of Health Web site. [nmhealth.org](http://nmhealth.org). Accessed March 26, 2014.
4. Basic TB facts. Centers for Disease Control and Prevention Web site. [cdc.gov](http://cdc.gov). Accessed March 26, 2014.
5. Golden MP, Holenarasipur RV. Extrapulmonary tuberculosis: An overview. *American Family Physician*. 2005;72(9):1761-8.
6. Inoue S, Matsumoto S, Iwamatsu Y, Satomura M. Ankle tuberculosis: A report of four cases in a Japanese hospital. *Journal of Orthopaedic Science*. 2004;9(4):392-8.
7. Dhillon MS, Nagi ON. Tuberculosis of the foot and ankle. *Clinical Orthopaedics and Related Research*. 2002;398:107-13.

8. Choi WJ, Han SH, Joo JH, Kim BS, Lee JW. Diagnostic dilemma of tuberculosis in the foot and ankle. *Foot & Ankle International*. 2008;29(7):711-5.
9. Chen SH, Lee CH, Wong T, Feng HS. Long-term retrospective analysis of surgical treatment for irretrievable tuberculosis of the ankle. *Foot & Ankle International*. 2013;34(3):372-9.
10. Ong WT. Tuberculosis in the Philippines: 10 things you should know. Philippine Star Web site. philter.com. Updated January 3, 2012. Accessed March 26, 2014.
11. DTBE in Philippines. Centers for Disease Control and Prevention Web site. cdc.gov. Accessed March 26, 2014.
12. Ha YE, Joo EJ, Park SY, Wi YM, Kang CI, Chung DR, Joh JW, Lee SK, Song JH, Peck KR. Tacrolimus as a risk factor for tuberculosis and outcome of treatment with rifampicin in solid organ transplant recipients. *Transplant Infectious Disease*. 2012;14(6):626-34.
13. Ganong WF. *Review of medical physiology*. 22nd ed. Lange Medical Books. 530.
14. Regmi A, Singh P, Harford A. A case of multidrug-resistant monoarticular joint tuberculosis in a renal transplant recipient. *Transplant Proceedings*. 2014;46(1):274-7.
15. Aparicio G, Viudez I, Perez JL, Delgado F. Extrapulmonary and extraspinal presentation of osteoarticular tuberculosis. *Acta Ortopedica Mexicana*. 2012;26(1):15-20.
16. Prechtl NV, Marcoux JT. Tuberculosis osteomyelitis of the mid foot in the absence of a pulmonary lesion: A case report. *Journal of Foot and Ankle Surgery*. 2008;14(4):225-8.