

# Midterm Results of an Anatomical Radial Head Arthroplasty for Treating Fractures and Degenerative Joint Diseases of the Radial Head

Gabriel Pertierra, BA; Lauren L. Vernon, PhD; Francisco Rubio, MD

The Miami Hand and Upper Extremity Institute, Miami, Florida

**Corresponding Author** Lauren L. Vernon. The Hand Institute. 8905 SW 87th Avenue, Miami, Florida 33176 (email: lvernon@thehandinstitute.us).

**Funding** The authors received no financial support for the research, authorship, and publication of this article.

**Conflicts of Interest** Gabriel Pertierra and Lauren Vernon report employment by Skeletal Dynamics, LLC. Francisco Rubio reports consulting fees from Skeletal Dynamics, LLC.

## ABSTRACT

**Background:** Radial head arthroplasty (RHA) is typically performed to restore elbow stability or function in patients with fractures or degenerative joint diseases. The procedure requires a specific operating technique to avoid complications such as overstuffing, capitellar erosion, stiffness, instability, micro motion, and loosening. It is difficult to restore native radial head function reliably.

**Methods:** We reviewed the medical records of 45 patients who underwent radial head arthroplasty using the ALIGN radial head implant (ALIGN Radial Head System, Skeletal Dynamics, Miami, FL) at our institution. A total of 15 patients met inclusion criteria and were contacted to complete a QuickDASH questionnaire, with additional questions on range of motion, strength, stability, pain, and satisfaction. The monoblock ALIGN implant has a long, press-fit stem coated in titanium plasma spray (TPS), is comprised of cobalt chrome, and is anatomically aligned by the provided alignment jig.

**Results:** Of the 15 patients, one reported severe loss of motion. No patient reported severe loss of strength, loss of stability, or pain. The average QuickDASH score was 12.62 (SD, 18.06) of 100, and the average patient satisfaction score was 8.80 (SD, 2.18) of 10.

**Conclusions:** Radial head arthroplasty may result in suboptimal performance. Functional outcomes after using this implant with monoblock design have been favorable. The design may accurately replicate the anatomical function of the native radial head, and the long, TPS-coated press-fit stem may provide more stability and osseous integration than other implants. The results of this study indicated satisfactory midterm results after use of the ALIGN implant in radial head arthroplasty.

**Keywords:** Radial Head Arthroplasty, Axis of Forearm Rotation, Radial Head

## INTRODUCTION

The radial head is a key component of the proximal radioulnar joint and an important element in force distribution across the elbow. Dysfunction of the radial head produces notable disability. No radial head implant has been able to restore native radial head function reliably.<sup>1</sup>

Fractures of the radial head constitute 33% of all elbow injuries and up to 5% of all adult fractures.<sup>2</sup> Most radial head fractures (85%) occur in young active adults, typically during a fall in which impact is braced by the hand, the forearm is supinated, and the elbow is in extension.<sup>3</sup> The radial head is a primary stabilizer to axial forearm loads and a secondary stabilizer to varus-valgus stress.<sup>3,4</sup> When injury results in ligamentous damage, the radial head becomes the primary stabilizer to varus-valgus.<sup>3</sup>

Active stability of the elbow is mostly dependent on joint compressive forces, which result from muscle action and articular congruency. The lateral and medial collateral ligament complexes and the anterior capsule maintain passive stability of the elbow. Joint forces in voluntary movement involve compression of the radial head and coronoid process against the humerus. The radial head alone can handle a load of up to three times the subject's body weight during valgus loading, when tension is high across the medial collateral ligament. The initiation of flexion about the elbow generates the greatest amount of force onto the radial head and coronoid. The elbow is most stable at 90° of flexion. In extension, most of the load (60%) is transmitted through the radial head and the remaining load is carried by the ulnohumeral joint (coronoid). Overall, the radioulnar joint allows an average of 75° of pronation and 80° of supination.<sup>5</sup>

Advanced degenerative joint disease may be treated surgically by osteotomy, resection, or radial head arthroplasty (RHA). Surgical treatment of radial head fractures may include open reduction and internal fixation (ORIF), resection of the radial head, or RHA. Indications for operative treatment include articular

displacement, irregular motion, severe pain, and instability associated with soft-tissue damage.<sup>2</sup>

Although ORIF is the preferred treatment for less comminuted radial head fractures, this technique has a high failure rate when the fracture is highly comminuted and unstable.<sup>6</sup> Resection greatly alters joint kinematics and may lead to complications such as long-term instability, displacement, positive cubital variance, and premature osteoarthritis. The interosseous ligament transfers axial loading to the ulna when the radial head is removed, leaving only the medial ligament to prevent a valgus deformity.<sup>5</sup> Resection is more effective in cases of isolated fracture without ligament injury owing to these biomechanical changes.<sup>2,7</sup> Fracture of greater than 50% of the coronoid process, comminution into three or more pieces, disruption of the collateral ligaments, or acute longitudinal radioulnar dissociation (Essex-Lopresti) lead to elbow instability and indicate the need for RHA.<sup>8,9</sup> RHA is also suggested for severe degenerative joint disease, failed ORIF, non-union, osteonecrosis, and posttraumatic sequelae.<sup>4,8</sup>

RHA requires precise surgical technique to avoid complications. Implant sizing is crucial because oversized implants, known as joint overstuffing, can decrease range of motion and lead to capitellar erosion. This is commonly the result of excessive radial head length.<sup>7</sup> An overly proximal bone cut or overestimation of the bone gap when the lateral collateral ligament is compromised can lead to overstuffing.<sup>6,7</sup> Lengthening of 2.5 mm or more alters joint kinematics and leads to excessive radiocapitellar load,<sup>10</sup> whereas an undersized implant will fail to stabilize the elbow properly.<sup>7</sup> Micro motion and loosening are more likely with larger radial neck resections and smaller implant stem lengths.<sup>11</sup>

Although some implants spin inside the radius with loose-fitting stems, other implants are seated (using a press-fit stem or bone cement) to restore native function. Press-fit stems are typically coated with a textured surface, such as titanium plasma spray (TPS), to promote osseous in-growth and stability. The objective of this study was to assess and report midterm follow-up results on patients who underwent RHA using a cobalt chrome, press-fit implant (ALIGN Radial Head System, Skeletal Dynamics, Miami, FL).

## METHODS

After receiving approval from our facility's medical director (we emailed the approval letter to the publication staff), we retrospectively reviewed all patients who underwent RHA from January 2011 to December 2015 (n = 45). Inclusion criteria were patients with a radial head fracture or severe elbow arthritis, treatment primarily with RHA, that were skeletally mature (18 years of age) at the time of the procedure. Exclusion criteria were patients who did not have a working phone number or did not wish to participate in the study, work-related injuries, and simultaneous ipsilateral upper-extremity injuries. Studies have

shown that workers' compensation claims strongly affect patient outcomes after an orthopaedic surgical procedure.<sup>12-14</sup> Of the 45 patients, a total of 15 met the inclusion criteria (5 men, 10 women).

Fifteen patients were contacted to complete a telephone survey (Figure 1). Our survey started with an overall patient satisfaction question (reported on a 0-10 continuous rating scale) and proceeded to questions regarding motion, strength, stability, and

**Questionnaire:**

1. On a scale from 0 to 10, with 0 being completely dissatisfied, and 10 being completely satisfied, how satisfied are you with the outcome of your elbow surgery? \_\_\_\_\_
2. How would you rate your elbow range of motion now?
  - a) Normal
  - b) Mild loss (80% of the other side)
  - c) Moderate loss (50% of the other side)
  - d) Severe loss (disabling)
3. How would you rate your elbow strength?
  - a) Normal
  - b) Mild loss (80% of the other side)
  - c) Moderate loss (50% of the other side)
  - d) Severe loss (disabling)
4. How would you rate your elbow stability?
  - a) Normal
  - b) Mild loss (perceived by patient, no limitation)
  - c) Moderate loss (limits some activity)
  - d) Severe loss (limits everyday tasks)
5. How do you rate your elbow pain?
  - a) No pain
  - b) Mild pain (with activity, no medication required)
  - c) Moderate loss (with or after activity)
  - d) Severe loss (at rest, constant medication, disabling)
6. Following your surgery, did you experience any complications or require any additional elbow surgery? Yes/ No
  - a. If no, proceed to next question
  - b. If yes, what were the complications?
  - c. If yes, did you require a second surgery?
    - i. If yes, Was that procedure also carried out by Dr. \_\_\_\_\_ (the original doctor)?

**Figure 1.** The survey on range of motion, strength, stability, pain, and patient satisfaction, conducted over the phone to 15 patients

pain. These questions were taken from the Broberg and Morrey<sup>15</sup> elbow rating system that defines the limits for mild, moderate, and severe loss. Finally, we included a question on complications. If the patient reported complications, additional follow-up questions were provided. The patients were also asked to complete a QuickDASH questionnaire to assess disability.<sup>16</sup>

We modified one question from the elbow rating system, regarding range of motion. The original scoring system used range-of-motion measurements to calculate the motion score. Because our survey was conducted over the phone, these measurements were not available. Instead, the question was changed to mirror the mild, moderate, and severe scale used for the strength score (reported as a percentage of the contralateral elbow).

The ALIGN radial head implant (Figure 2) is a cobalt chrome, side-loading, monoblock implant designed to be anatomically aligned to the patient's axis of forearm rotation by means of an alignment jig (Figure 3). A long stem provides three-point, press-fit fixation and has a TPS coating. The implant is installed in a modular fashion, until a lock screw secures the head to the stem,



**Figure 2.** The ALIGN implant (ALIGN Radial Head System, Skeletal Dynamics, Miami, FL).

transforming it into a monoblock system. RHA was performed as described by the manufacturer of the ALIGN implant.<sup>17</sup> Two orthopaedic surgeons with upper-extremity subspecialty training performed all surgical procedures.

## RESULTS

The mean age of the 15 patients was 60.87 years (SD, 16.39) at the time of the surgical procedure (range, 26-83 years). Table 1 shows demographic data. RHA was performed on eight right and seven left hands. Patients were contacted to complete the survey at an average of 44.58 months (SD, 18.03) postoperatively. Figures 4A and 4B shows a representative radiograph of a patient at final follow-up.

The results of the patient questionnaire are shown in Table 2. With respect to motion, eight patients (53.3%) reported normal range of motion, three (20.0%) had

**Table 1.** Demographic information on 15 patients with radial head fractures treated using the ALIGN Radial Head System implant<sup>a</sup>

Patient number	Age, y <sup>b</sup>	Sex <sup>c</sup>	Left or right hand treated <sup>d</sup>	Postoperative follow-up, mos <sup>e</sup>
1	83	Female	Right	70.39
2	66	Female	Left	64.77
3	62	Male	Right	64.21
4	26	Male	Left	62.73
5	68	Female	Left	59.05
6	58	Female	Left	51.45
7	56	Male	Right	48.82
8	81	Female	Left	45.30
9	70	Female	Right	45.14
10	66	Female	Left	36.36
11	81	Female	Right	35.64
12	34	Male	Right	31.33
13	45	Male	Left	21.21
14	54	Female	Right	16.83
15	63	Female	Right	15.45

<sup>a</sup>Skeletal Dynamics, Miami, FL.

<sup>b</sup>Average age of all patients was 60.87 years (SD, 16.39).

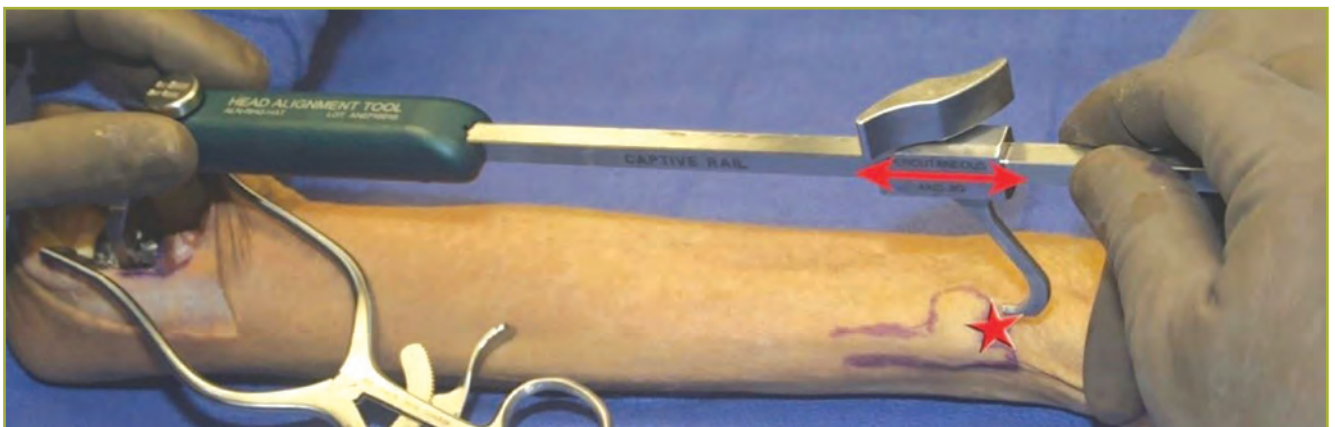
<sup>c</sup>In total, ten patients were women and five were men.

<sup>d</sup>In total, eight right and seven left hands were treated.

<sup>e</sup>Patients were contacted to complete the survey at an average of 44.58 months (SD, 18.03) postoperatively.

mild loss of motion, three (20.0%) had moderate loss of motion, and one (6.7%) had severe loss of motion. Regarding strength, nine patients (60.0%) had normal elbow strength, four (26.7%) had mild loss of strength, and two (13.3%) had moderate loss of strength.

Concerning stability, eleven patients (73.3%) reported normal elbow stability, three (20.0%) had mild loss of stability, and one (6.7%) had moderate loss of stability. With respect to pain, ten patients (66.7%) reported no elbow pain, three (20.0%) had mild elbow pain, and two (13.3%) had moderate pain.



**Figure 3.** The ALIGN implant (ALIGN Radial Head System, Skeletal Dynamics, Miami, FL) alignment jig used to anatomically align the implant to the patient's axis of forearm rotation.

**Table 2.** Results of the follow-up survey given to 15 patients who underwent surgical treatment of radial head fractures using the ALIGN Radial Head System implant<sup>a</sup>

Patient Number	ROM	Strength	Stability	Pain	QuickDASH Score <sup>b</sup>	Complications	Satisfaction Score <sup>c</sup>
1 <sup>d</sup>	normal	normal	normal	none	4.55	no	10
2	moderate loss	normal	normal	mild	4.55	no	9
3 <sup>d</sup>	severe loss	moderate loss	moderate loss	moderate	50.00	no	5
4	mild loss	mild loss	mild loss	none	9.09	no	10
5	normal	normal	normal	none	0.00	no	10
6 <sup>e</sup>	moderate loss	moderate loss	normal	moderate	40.00	yes	4
7	mild loss	normal	normal	mild	6.82	no	10
8 <sup>f</sup>	moderate loss	mild loss	mild loss	none	50.00	no	5
9	normal	normal	normal	none	2.27	no	10
10 <sup>d</sup>	normal	normal	normal	none	0.00	no	10
11 <sup>f</sup>	normal	mild loss	mild loss	none	10.71	no	10
12	normal	normal	normal	mild	0.00	no	10
13	normal	normal	normal	none	0.00	no	10
14	mild loss	normal	normal	none	4.55	no	10
15	normal	mild loss	normal	none	6.82	no	9

ROM, range of motion.

<sup>a</sup>Skeletal Dynamics, Miami, FL.

<sup>b</sup>The average QuickDASH score was 12.62 (SD, 18.06). Patient scores ranged from 0 to 50 of 100 (QuickDASH maximum score), with a score of < 20 indicating a positive outcome.

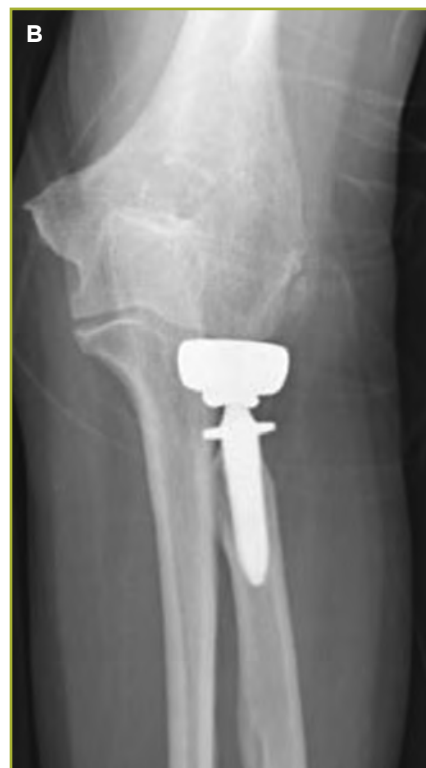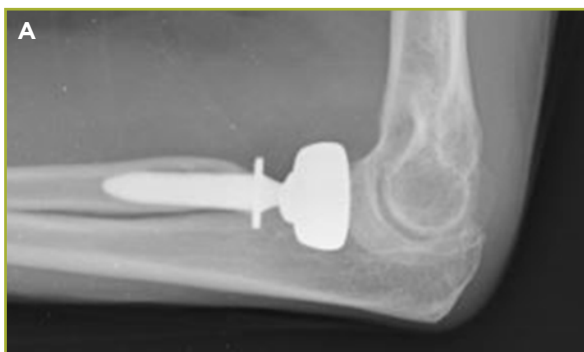<sup>c</sup>The average satisfaction score was 8.80 (SD, 2.18). Scores ranged from 0 to 10, with a score of 10 indicating the most satisfied.

<sup>d</sup>Patients had history of elbow pain and instability before treatment.

<sup>e</sup>Patient reported “golfer’s elbow” (ie, medial epicondylitis) and underwent an additional procedure on the same elbow.

<sup>f</sup>Patients had a severe cognitive impairment, and responses were given by a family member or caregiver.

The average QuickDASH score was 12.62 (SD, 18.06; Table 2). The average patient satisfaction score was 8.80 (SD, 2.18) of 10. One patient (6.7%) reported a complication of “golfer’s elbow,” or medial epicondylitis, requiring additional surgical treatment of the same elbow (patient #6). Another patient had a 15-year history of elbow pain and instability before treatment, multiple operative procedures, and a ligament reconstruction (patient #3). One patient had lived with instability for more than 50 years before surgical treatment (patient #10). Of the 15 patients included in the study, none underwent surgical revision or removal of the ALIGN implant.



**Figure 4.** Representative radiographs of a patient at 3-year follow-up. A) Anteroposterior view of the elbow. B) Lateral view of the elbow.

## DISCUSSION

RHA is a common orthopaedic treatment that may result in suboptimal results, revision procedures, and postoperative complications.<sup>1,9,18</sup> The treatment is intended to improve stability after injury, particularly when ligamentous and bony injury are combined, or to relieve pain in advanced degenerative joint disease of the radial head. Restoration of the radial head buttress restores elbow stability.

Even after ligament healing stabilizes the joint, radial head implants can produce long-term problems such as painful capitellar wear and prosthetic loosening. A study done by Wretenberg et al<sup>19</sup> found that up to 27% of radial head implants are removed or revised soon after implantation owing to similar issues, with an average follow-up of 3.4 years. There is no consensus for the optimal design of radial head implants thus far. Three controversies stand out: monoblock versus bipolar, loose-fitting stem versus fixed-stem implants, and anatomical versus non-anatomical designs.

Monoblock designs attempt to replace the native radial head with a rigid implant that replicates its biomechanical function. Their rigidity provides lateral support to control posterolateral instability, despite some degree of elbow subluxation. Because of the wide range of anatomic variation, it is difficult to restore the original alignment when using monoblock radial heads. These implants may produce edge loading and wear on the capitellum. Bipolar radial heads have a ball and socket articulation immediately distal to the radial head that attempts to minimize capitellar wear by alignment with the capitellum.<sup>7</sup> Therefore, the bipolar radial head avoids capitellar edge loading seen with monoblock implant malalignment.

A bipolar design may cause localized high stresses on the capitellum when subjected to a lateral force because the radial head transmits axial and transverse loads.<sup>1</sup> In cadaveric models, bipolar heads provide less stability than monoblock implants because they fail to restore lateral support in the face of slight subluxation.<sup>9</sup> However, recent studies have not shown enough significant clinical evidence in favor of one specific type of implant.<sup>8</sup>

Radial head implants with a loose-fitting stem are designed to be a simple spacer between the capitellum and the radial stump. They present a smooth, metallic, intramedullary stem introduced into the radial neck, with the intention of allowing rotational motion. Loose-fitting stems cannot transmit joint forces, especially transverse forces, in a physiological manner. They are prone to complications such as osteolysis and migration.<sup>20</sup>

Fixed-stem implants, on the other hand, transmit loads in a physiologic manner.<sup>21</sup> Fixation methods used have included press-fit, cement, and bone-ingrowth surfaces. Stably-fixed implants have some disadvantages, however. Anatomical implant alignment

has been difficult to obtain and malalignment can cause capitellar wear.<sup>8</sup> If fixation is not successfully achieved, the textured surfaces of press-fit implant stems may cause erosion and osteolysis.<sup>21</sup> With uncemented implants, immediate postoperative stability is needed for bony integration and to prevent micromotion. Implant stability depends on stem length and proper resection of the radial head and neck.<sup>11</sup> Findings of a study done by Kodde et al<sup>1</sup> suggests that press-fit fixation with successful osseous integration results in long-term fixation and stability. Cemented implants, on the other hand, have been shown to loosen at the cement-bone interface in up to 10% of cases.<sup>18</sup>

Anatomically accurate radial head implants more evenly distribute and reduce contact stresses on the capitellum as compared to their non-anatomically designed counterparts.<sup>5</sup> Anatomically designed radial heads are difficult to insert in the original anatomical position.<sup>8</sup> Their designs are based on averages of a wide range of anatomical variations of the elbow and therefore do not conform well to individual patients. Non-anatomical radial head implants cannot be aligned properly because their stem is perpendicular to the radial neck, where fixation is typically obtained. Because the average radial head is angulated 6° from the axis of the radial neck, a wobbling motion during forearm rotation and edge loading on the capitellum can result.

The ALIGN implant has a unique long and press-fit stem design with a radial head that is custom aligned to the patient's axis of forearm rotation. This provides the bipolar-like protection of the capitellar surface and the stability of a monoblock implant. This design also permits the use of a long stem to achieve more reliable fixation while avoiding the difficulties of inserting a traditional anatomical monoblock implant.

Overall, patients reported high scores of satisfaction (average score, 8.8), with 10 patients reporting complete satisfaction (10 of 10). Similarly, five patients reported no pain, normal range of motion, normal strength, and normal stability. However, not all patients were completely satisfied. Three patients (#3, #6, and #8) reported satisfaction scores of less than 7. Interestingly, these patients had high QuickDASH scores (> 20) and reported moderate to severe loss of range of motion. In the Broberg and Morrey<sup>15</sup> rating system (that our survey was modeled after), range of motion is the most heavily weighted category (40% of the final score), suggesting that these patients would likely have received a fair or poor Broberg and Morrey<sup>15</sup> classification score.

Three patients (#1, #3, and #10), had a history of elbow instability prior to treatment. Two of these patients (#1 and #10) had promising treatment outcomes. However, patient #3 (who had a poor outcome) had full range of motion at 4 weeks postoperatively but described poor function. This may

have been due to his multiple medical comorbidities that affected his ability to perform tasks. Three patients (#3, #10, and #14) underwent RHA to treat degenerative joint disease. Twelve patients (with high satisfaction and low QuickDASH scores) reported favorable outcomes across the categories (range of motion, strength, stability, and pain), indicating an excellent or good score of the Broberg and Morrey<sup>15</sup> classification.

Our study has several limitations. We had a limited sample size of patients. Of the 45 patients treated with RHA, only 15 patients met inclusion criteria. Of the 30 patients who did not participate, twenty-one were unable to be contacted or declined to participate, five were involved workers' compensation claims, one was below the age of 18 years at the time of procedure, and three had severe ipsilateral injuries. Furthermore, the study was conducted using the phone, which limited the data collected to patient-reported outcomes and did not allow for objective measurements (specifically for the range of motion question) or radiographic analysis. The phone survey was therefore written to closely mirror the Broberg and Morrey<sup>15</sup> questionnaire, which is a validated method for assessing treatment outcomes of elbows.

In the current study, our patients exhibited favorable results after RHA for the relevant indications listed. Our findings may indicate that use of the ALIGN implant provides promising midterm clinical results, with few complications, and minimizes the need for revision procedure or implant removal.

## REFERENCES

1. Kodde IF, Heijink A, Kaas L, Mulder PG, van Dijk CN, Eygendaal D. Press-fit bipolar radial head arthroplasty, midterm results. *J Shoulder Elbow Surg.* 2016;25(8):1235-1242. doi: 10.1016/j.jse.2016.02.007.
2. Moghaddam A, Raven TF, Dremel E, Studier-Fischer S, Grutzner PA, Biglari B. Outcome of radial head arthroplasty in comminuted radial head fractures: short and midterm results. *Trauma Mon.* 2016;21(1):e20201. doi: 10.5812/traumamon.20201.
3. Van Hoecke E, Van De Vijver A, Van Glabbeek F, Gielen J. Long term results after bipolar radial head arthroplasty. *Acta Orthop Belg.* 2016;82(2):382-388.
4. Gauci MO, Winter M, Dumontier C, Bronsard N, Allieu Y. Clinical and radiologic outcomes of pyrocarbon radial head prosthesis: midterm results. *J Shoulder Elbow Surg.* 2016;25(1):98-104. doi: 10.1016/j.jse.2015.08.033.
5. Shahid, MK, Fletcher M, Robati S, Pemmaraju G. The biomechanical forces that act on the elbow. *EC Orthopaedics.* 2015;1(1):1-11.
6. Yoon A, Athwal GS, Faber KJ, King JWG. Radial head fractures. *JHS.* 2012;37(A):2626-2634.
7. Kang SH, Kim DY, Park H, Song HS. Anthropometric study of the proximal radius: does radial head implant fit in all cases? *Int Orthop.* 2015;39(8):1553-1561. doi: 10.1007/s00264-015-2773-z.
8. Giannicola G, Sacchetti FM, Antonietti G, Piccioli A, Postacchini R, Cinotti G. Radial head, radiocapitellar and total elbow arthroplasties: a review of recent literature. *Injury.* 2014;45(2):428-436. doi: 10.1016/j.injury.2013.09.019.
9. Heijink A, Kodde IF, Mulder PGH, Van Dijk CN, Eygendaal D. Cemented bipolar radial head arthroplasty: midterm follow-up results. *J Shoulder Elbow Surg.* 2016;25(11):1829-1838. doi: 10.1016/j.jse.2016.05.017.
10. Van Glabbeek F, van Riet RP, Baumfeld JA, et al. The kinematic importance of radial neck length in radial head replacement. *Med Eng Phys.* 2005;27(4):336-342.
11. Shukla DR, Fitzsimmons JS, An KN, O'Driscoll SW. Effect of stem length on prosthetic radial head micromotion. *J Shoulder Elbow Surg.* 2012;21(11):1559-1564. doi: 10.1016/j.jse.2011.11.025.
12. de Moraes VY, Godin K, Tamaoki MJ, Faloppa F, Bhandari M, Belloti JC. Workers' compensation status: does it affect orthopaedic surgery outcomes? A meta-analysis [published erratum in: *PLoS One.* 2013;8(8)]. *PLoS One.* 2012;7(12):e50251. doi: 10.1371/journal.pone.0050251.
13. Cowan J, Makanji H, Mudgal C, Jupiter J, Ring D. Determinants of return to work after carpal tunnel release. *J Hand Surg Am.* 2012;37(1):18-27. doi: 10.1016/j.jhsa.2011.10.033.
14. Hou WH, Tsao JY, Lin CH, Liang HW, Du CL. Worker's compensation and return-to-work following orthopaedic injury to extremities. *J Rehabil Med.* 2008;40(6):440-445. doi: 10.2340/16501977-0194.
15. Broberg MA, Morrey BF. Results of delayed excision of the radial head after fracture. *J Bone Joint Surg.* 1986;68-A(5):669-674.
16. Hudak PL, Amadio PC, Bombardier C. Development of an upper extremity outcome measure: the DASH (disabilities of the arm, shoulder and hand): the Upper Extremity Collaborative Group (UECG) [published erratum in: *Am J Ind Med* 1996;30(3):372]. *Am J Ind Med.* 1996;29(6):602-608
17. Skeletal Dynamics, LLC. Surgical Technique Guide: ALIGN® radial head system. <http://skeletalynamics.com/products/align/overview>. Accessed April 12, 2018.
18. Popovic N, Lemaire R, Georis P, Gillet P. Midterm results with a bipolar radial head prosthesis: radiographic evidence of loosening at the bone-cement interface. *J Bone Joint Surg Am.* 2007;89(11):2469-2476.
19. Wretenberg P, Ericson A, Stark A. Radial head prosthesis after fracture of radial head with associated elbow instability. *Arch Orthop Trauma Surg.* 2006;126(3):145-149.
20. Marsh, J., Grewal, R., Faber, K. J., Drosdowech, D. S., Athwal, G. S., & King, G. J. Radial Head Fractures Treated with Modular Metallic Radial Head Replacement. *J Bone Joint Surg Am.* 2016;98:527-535.
21. Levy JC, Formaini NT, Kurowicki J. Outcomes and radiographic findings of anatomic press-fit radial head arthroplasty. *J Shoulder Elbow Surg.* 2016;25(5):802-809. doi: 10.1016/j.jse.2015.11.014.