

Case Report



A case of subacute thyroiditis associated with complete occlusion of right coronary artery

Abstract

Case presentation: A case is a 72-year-old male, and developed fever, sore throat and immigrating neck pain, without shortness of breath (SOB). He showed pulse 96/min, Temp 38.8C, BP 146/90mmHg, respiration and SpO₂ normal. Physicals were slight tenderness in thyroid, and laboratory data revealed free T₃/T₄ 10.7pg/mL/5.4ng/dL. He was diagnosed as subacute thyroiditis. ECG showed incomplete right bundle block branch (RBBB) and Holter ECG showed pulse rate 70-144/min and the average was 95.8/min for 24 hours. HbA_{1c} increased from 6.4% to 7.4% for 6 weeks. For the treatment, prednisolone 20mg/day was started and reduced gradually, and thyroid function was normalized. Consecutively, he developed chest discomfort and oppression with unremarkable ECG changes and chest CT showed only the calcification of coronary arteries. Coronary angiography showed occlusion of the right proximal coronary artery (RCA, #2:100%), left anterior descending (LAD, #6:75%, #7:90%). Coronary angioplasty was operated immediately. By placing a drug-eluting stent, RCA was re-opened successfully. His symptoms disappeared, and clinical course was improved.

Discussion: Subacute thyroiditis may bring hyperthyroidism and tachycardia, increased metabolism for circulatory system. Then, subacute thyroiditis would give burden and stress for coronary heart function. It is suggested that hyperthyroidism would aggravate the coronary stenosis. We have to consider such complex pathophysiology for the diseased states in the clinical medical practice.

Keywords: subacute thyroiditis, de quevain's thyroiditis, coronary artery disease, coronary angioplasty

Volume 6 Issue 3 - 2019

Akinori Nakanishi MD,¹ Jouji Shunto MD,²
 Reiko Shunto MD,² Masataka Sata MD,³
 Hiroshi Bando MD⁴

¹Clinic Shara, Matsushige, Tokushima, Japan

²Shunto Clinic, Matsushige, Tokushima, Japan

³Department of Cardiovascular Medicine, Tokushima University Graduate School of Biomedical Sciences, Tokushima, Japan

⁴Tokushima University/Medical Research, Tokushima, Japan

Correspondence: Hiroshi Bando MD, Tokushima University/ Medical Research, Nakashowa 1-61, Tokushima, 770-0943, Japan, Tel +81 90 3187 2485, Email pianamed@bronze.ocn.ne.jp

Received: July 02, 2019 | **Published:** July 30, 2019

Abbreviations: LAD, left anterior descending coronary artery; LCX, left circumflex coronary artery; RCA, right coronary artery; CAD, coronary artery disease; ACC/AHA, American College of Cardiology/American Heart Association; CABG, coronary artery bypass graft surgery; NSAIDs, non-steroidal anti-inflammatory drugs

Introduction

Subacute thyroiditis has been known as a self-limiting and inflammatory disease of the thyroid which seems to be caused by a systemic viral infection.^{1,2} It was formerly called De Quevain's thyroiditis with long history.^{3,4} Subacute thyroiditis has been usually occurs in the area of thyroid gland associated with pain, fever, tenderness and general malaise.^{5,6} In the acute period of subacute thyroiditis, the tissue of thyroid gland is destroyed and large amount of thyroid hormone is released into the blood.⁶ Consequently, it can bring hyperthyroidism such tachycardia, increased metabolism for circulatory system. Then, subacute thyroiditis would give burden and stress for coronary heart function.⁷

Authors have continued medical practice for many patients with a variety of diseases. Among them, we have experienced a meaningful case of subacute thyroiditis associated with coronary heart diseases.⁸ This study describes a 72-year-old man having several medical problems and discusses characteristic points.

Case presentation

The case is a 72-year-old male. His chief complaint was fever and sore throat. As to past history, he did not have cardiovascular disease (CVD), or not feel related symptom concerning CVD. From

mid-January 2019, he developed fever, sore throat and immigrating neck pain. These symptoms were persisted for a few days, without strong occipital headaches, chest pain, chest oppression, nausea, vomiting, visual changes, rash, or others. He did not perceive chest pain, shortness of breath (SOB), or other remarkable cardiovascular symptoms. Further, he did not feel apparent symptom of irritability, increased sweating, eye discomfort, abdominal pain or diarrhea.

His vitals were as follows: pulse rate 96 per minute, body temperature 38.8 C, blood pressure 146/90, respiration and SpO₂ normal. Physical examination revealed slight tenderness in thyroid, and lung, heart, abdomen and neurological findings unremarkable. His thyroid function revealed elevated levels of free T₃ and free T₄, which was 10.7pg/mL, and 5.4ng/dL, respectively. He was thought to be probable subacute thyroiditis.^{1,5} As a result of thyroid echocardiography, the right lobe of the thyroid gland was predominantly enlarged, and multiple hypoechoic regions were present inside. Further, no abscess was found in the bilateral thyroid lobe, suggesting subacute thyroiditis or acute exacerbation of Hashimoto's disease. From the above laboratory and echogenic findings with clinical situations, he was diagnosed as subacute thyroiditis.

Blood examination was held at the diagnosis of subacute thyroiditis, and the results were shown in Table 1. Among them, elevated free T₃ and free T₄, low TSH, elevated CRP and white blood cells, elevated LDL, TG, total-cholesterol, blood glucose, and low CPK were observed. Thyroid autoantibodies were as follows: Thyroglobulin (TG) antibodies 626IU/mL (< 27.9), Thyroid peroxidase (TPO) antibody 11.2IU/mL (<15.9). These remarkable values are considered to be consistent with the pathology of subacute thyroiditis. In the

electrocardiogram (ECG), persisting tachycardia was observed in Figure 1. The detail findings of ECG were that ordinary sinus rhythm, pulse rate 114/min, R-R interval 0.526sec, P-R interval 0.144sec, QRS interval 0.131 sec., QTc=0.467 and incomplete right bundle

block branch (RBBB). As a result of investigating for 24 hours by Holter electrocardiogram, the pulse rate was distributed at 70 to 144/min and the average pulse rate was 95.8/min.

Table I Results of blood tests

Thyroid		Biochemistry	
free T3	10.7 pg/mL	CPK	39 U/L
free T4	5.4 ng/dL	Uric Acid	3.0 mg/dL
TSH	<0.005μU/mL	BUN	18 mg/dL
CBC		Cre	0.7 mg/dL
WBC	10900/μL	Na	140 mEq/L
RBC	4.05 x 10 ⁶ /μL	K	4.0 mEq/L
Hb	11.8 g/dL	Cl	105 mEq/L
Ht	34.9 %	Ca	8.7 mg/dL
Platelet	19.4 x 10 ⁴ /μL	P	3.3 mg/dL
Biochemistry		Mg	2.2 mg/dL
CRP	10.7 mg/dL	LDL-C	73 mg/dL
CRP	4+	HDL-C	35 mg/dL
T.P.	5.8 g/dL	TG	188 mg/dL
Alb	2.6 g/dL	LDL-C	170 mg/dL
T-Bil	0.6 mg/dL	HDL-C	39 mg/dL
AST	26 U/L	Total-C	122 mg/dL
ALT	52 U/L	TG	72 mg/dL
ALP	254 U/L	LDL/HDL	2.2
LDH	135 U/L	amylase	51 U/L
r-GTP	25 U/L	glucose	150 mg/dL

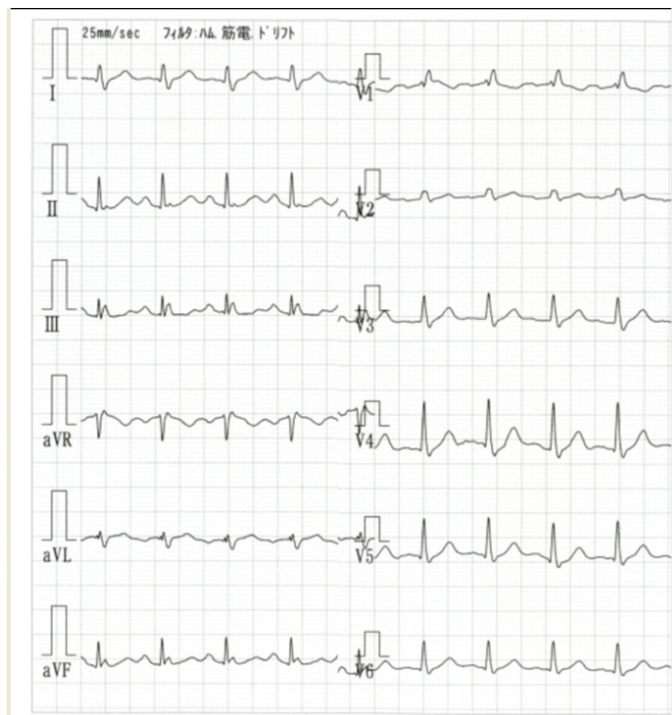


Figure 1 ECG finding on the diagnosis as subacute thyroiditis. It shows tachycardia (pulse 114/min).

As a treatment for subacute thyroiditis, steroid was administered by gradually decreasing from 20 mg/day of prednisolone. Therapeutic effect was found, and thyroid function was lowered in about 3 weeks by steroid administration. Changes in Free T3, free T4, TSH, and HbA1c levels of the process for the treatment are shown in Figure 2. The thyroid function could be sufficiently lowered, and thereafter, thyroid function could be maintained within the normal range by adjusting the dose of levothyroxine (Thyradin S) 50–100μg/day. HbA1c increased from 6.4% to 7.4% for 6 weeks, and decreased. After that, his condition had been stable without remarkable clinical symptoms. He developed chest discomfort and oppression from early February, 2019. Furthermore, he did not perceive apparent chest pain or shortness of breath. There were no significant changes in ECG and echocardiography as basic examinations for cardiovascular evaluation. Chest CT showed only the calcification of coronary arteries.

Subsequently, coronary angiography was performed. As a result, it showed total occlusion of the right proximal coronary artery (# 2) (Figure 3a). The left anterior descending coronary artery (LAD) has occlusion of 75% at # 6 and 90% at # 7, and the left circumflex coronary artery (LCX) has 90% occlusion at #15, and total occlusion at # 2 in the right coronary artery (RCA). Furthermore, there was the existence of collateral vessel between LAD and RCA. For these diseased states, coronary angioplasty was operated immediately.⁹ As the treatment for right coronary artery, passage of the wire of the lesion, thrombus aspiration and balloon dilation were performed. By placing a drug-eluting stent (Ultimaster 3.0 mm x 18 mm), the right coronary artery was re-opened successfully (Figure 3b).

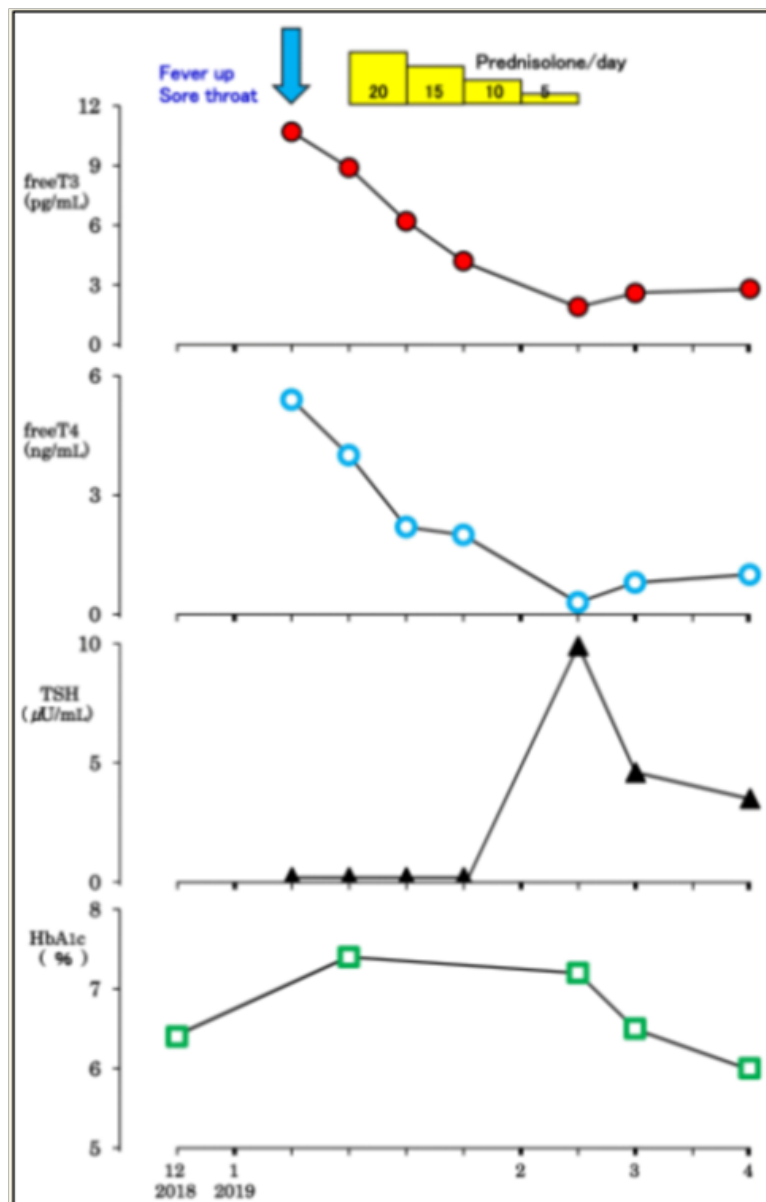


Figure 2 Clinical changes in thyroid.

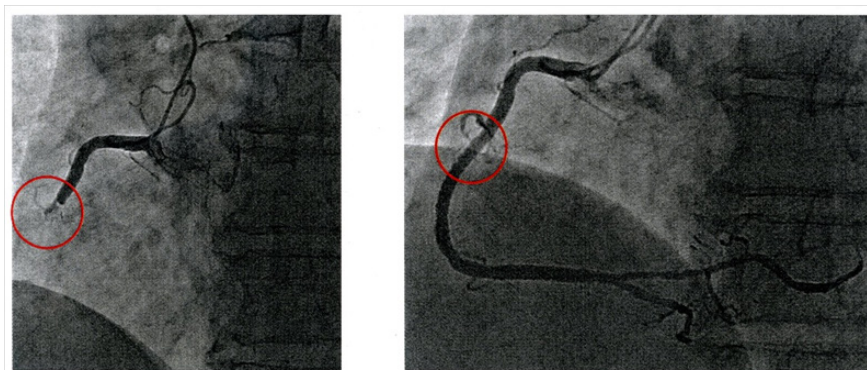


Figure 3 Findings of coronary angiography.

3a: Right coronary artery (RCA) showed total occlusion before angioplasty.

3b: After angioplasty, RCA has become re-opened.

His symptoms disappeared after the operation, and the clinical course was improved. He was discharged in early March, 2019. For the continuing treatment, he was given two meds of hyperlipidemia, and two meds of anti-coagulant agents. These four meds were Bayaspirin® 100mg (Aspirin, 2-Acetoxybenzoic acid), Efient® 3.75mg (Prasugrel Hydrochloride), Rosuvastatin® 2.5mg (Rosuvastatin Calcium) and Zetia® 10mg (Ezetimibe). On early April, he was re-admitted for the catheter therapy, in which the lesion on the left anterior descending branch was successfully treated.

Discussion

The patient had showed fever and sore throat and was diagnosed as subacute thyroiditis.² At that time, there were important points in the diagnosis of this clinical disorder. It was the inquiry to the patient whether there was mobility and immigrating pain in the neck or not. Therefore, thyroid hormone concentration could be examined, and then the diagnosis became possible in early stage.¹

The findings of the data were consistent with subacute thyroiditis, such as leukocytosis, elevated CRP, decreased CPK, decreased level of total cholesterol and others.³ In the hyperthyroid state, there are some influences on the cardiovascular system. In this case, there were no coronary artery diseases before, or no findings suggesting angina pectoris or acute myocardial infarction such as shortness of breath or chest pain. In addition, ECG was examined when hyperthyroidism was observed, and the pulse was a tachycardia of 114/min. On the Holter ECG, the total pulse rate for 24 hours reached 138,000, the average pulse was 95.8/min, and the pulse rate was distributed from 70 to 144. At rest at bedtime, the pulse rate was 70/min, and during daytime with usual activity the pulse rate increased to 144/min. In detail, Af and AF were not detected, APC and VPC were rare, and ST-T changes were not observed. Thus, the situation of hyperthyroidism gives oxidative stress for cardiovascular system.⁸

There was a study of peripheral blood leukocyte classification at the onset and diagnosis of subacute thyroiditis.¹⁰ Neutrophil-to-lymphocyte ratio (NLR), a novel marker of inflammation, was studied in 75 cases of subacute thyroiditis and 75 cases of normal control. As a result, NLR was 3.56 ± 2.64 in subacute thyroiditis, while it was 1.41 ± 0.9 in healthy subjects. In our case, laboratory data showed leukocytosis, in which $\text{WBC} = 10900$ with $\text{neutrophil/lymphocyte} = 80.0/11.8 = 7.0$. After 7 days, the blood thyroid hormone decreased due to the treatment, where $\text{WBC} = 5600$ with $\text{neutrophil/lymphocyte} = 59.6/31.0 = 1.9$. These data in our case appear to be consistent with the reports of Kilinc et al.¹⁰

Pain and tenderness in the anterior neck has been the most common in subacute thyroiditis, which is often associated with clinical signs and symptoms from hyperthyroidism.⁵ Its diagnosis has been performed by mainly laboratory findings of thyrotoxicosis and iodine uptake scan with reduced uptake.¹¹ As for the treatment of subacute thyroiditis, non-steroidal anti-inflammatory drugs (NSAIDs) and/or steroids have been the main agents for the therapy. After the period of thyrotoxicosis phase, approximately one fourth of the cases would become hypothyroidism situation with the necessity of levothyroxine administration after that.^{5,11} Cases with subacute thyroiditis have been often treated by NSAIDs or corticosteroids. The former group seems to be rather lighter, and the latter group seems to be rather heavier clinical course.¹² Probably due to this tendency, latter group with steroid therapy seems to show higher incidence of hypothyroidism after the treatment. Further evaluation would be necessary to be discussed concerning these two treatments and prognoses.¹³

As for the steroid treatment for subacute thyroiditis, an adequate guideline has not been established. From lots of reports, 40mg of prednisolone would be the usual dose of starting according to the severity of the symptoms.¹²⁻¹⁴ Further, lower doses of 10 mg/day would be used in other reports with relieving the symptoms of the cases.^{15,16} Because we can recently get the results of thyroid function immediately due to the laboratory development, the management for subacute thyroiditis would be safer and easier with less doses of steroid administration.^{15,16} After the relieving condition of subacute thyroiditis, the patients seem to reveal overt or subclinical hypothyroidism in about 20 – 30% of the cases.^{2,5} Those thyroid function may vary in the cases with a variety of latency period. Then, following up the thyroid function is necessary in the course of subacute thyroiditis.¹¹ The ratio of hypothyroidism after subacute thyroiditis would be 34% in 6-12 months, and 15% after 1 year.¹² Consequently, thyroid function in those cases would be necessary to be followed up. They are usually treated with levothyroxine supplementation with ordinary stable clinical course.^{12,13}

During the entire course of the cardiovascular health problems, no apparent chest symptoms were noted in the medical history. As a laboratory finding, no abnormality was found in the electrocardiogram. One of the important findings would be the calcification of the coronary artery by chest CT scan. Chest CT was also done 2 years ago, which was beneficial for the patient. The reason was that coronary artery radiography was strongly recommended because calcification progressed for the comparison. Consequently, the case can be detected to have serious changes of two coronary arteries, leading to saving the life of the patient. From previous reports, patients of total occlusion of the left anterior descending coronary artery (LAD) or right coronary artery (RCA) have been found.^{17,18} Those patients showed beneficial collateral vessels, which play important roles depending on the situations. In this case, there has been a crucial collateral vessel between LAD and RCA. RCA was supposed to be occluded totally after developing subacute thyroiditis. The case had formerly showed no evidence of cardiovascular disease, no apparent related symptoms such as chest pain, shortness of breath, or no remarkable changes in the electrocardiogram. After he developed subacute hyperthyroidism, he came to perceive cardiac symptoms and showed tachycardia and increased metabolism for the body. It may also give a burden on the circulatory system. Consequently, it can be thought that coronary heart disease may be aggravated such as angina and acute myocardial infarct.⁸

This case showed the presence of type 2 diabetes mellitus (T2DM) and multi-vessel coronary artery disease (CAD). Patients with T2DM have been said to have rather multi-vessel CAD. As for such patients, there has been a standard guideline, which was established by American College of Cardiology/American Heart Association (ACC/AHA). Its comment was that such patients with DM and multi-vessel CAD would be treated with coronary artery bypass graft surgery (CABG).¹⁹ Furthermore, LDL-C level has been known as one of the risk factor for cardiovascular disease. The case had showed somewhat elevated LDL-C level, then it may influence the progress of coronary artery disease. There is a recent report of a novel risk score which investigated patients in the CABG strata randomized to intensive medical therapy (IMT) in the Bypass Angioplasty.²⁰ As a result, the new score can defer CABG treatment for the patients with low-risk and stable situation.

In summary, there might be some degree of occlusion of the right coronary artery, but no angina-like symptoms were observed. After

that, various stress for cardiovascular function has increased, partly due to the occurrence of subacute thyroiditis, tachycardia and hyper-metabolic state. As a result, occlusion of the right coronary artery has progressed and chest compression symptoms may be occurred. The treatment was successful with coronary angiography and angioplasty.

As mentioned above, this report would become one of the useful and reference cases with thyroid and cardiovascular diseases. We have to pay attention to such clinical cases with such combined medical problems, which have to be considered from general points of view.

Ethical consent

None.

Acknowledgments

None.

Conflicts of interest

Author declares there is no conflict of interest.

References

1. Czerwonka L. Thyroiditis. In: Docimo Jr S, Pauli E, Editors. *Clinical Algorithms in General Surgery*. Springer. 2019.
2. Raj R, Yada S, Jacob A, et al. Fever of Unknown Origin as a Sole Presentation of Subacute Thyroiditis in an Elderly Patient: A Case Report with Literature Review. *Case Reports in Endocrinology*. 2018;1–8.
3. Ranganath R, Shaha MA, Xu B, et al. de Quervain's thyroiditis: a review of experience with surgery. *Am J Otolaryngol*. 2016;37(6):534–537.
4. Olah R, Hajos P, Soos Z, et al. De Quervain thyroiditis. Corner points of the diagnosis. *Orv Hetil*. 2014;155(17):676–680.
5. Alfadda AA, Sallam RM, Elawad GE, et al. Subacute thyroiditis: Clinical presentation and long term outcome. *Int J Endocrinol*. 2014;2014:794943.
6. Cappelli C, Pirola I, Gandossi E, et al. Ultrasound findings of subacute thyroiditis: A single institution retrospective review. *Acta Radiol*. 2014;55(4):429–433.
7. Liu R, Xu B, Luo H, et al. A case report of subacute thyroiditis and myocardial damage. *Int J Clin Exp Med*. 2018;11(9):10161–10165.
8. Dağdeviren M, Koca AO, Akkan T, et al. Evaluation of oxidative stress parameters in subacute thyroiditis patients. *Endocrine Abstracts*. 2019;63:773.
9. Singh SK, Bajpai M, Tiwari S, et al. Effect of age on cardiac output after coronary angioplasty in patients of acute myocardial infarction. *Natl J Physiol Pharm Pharmacol*. 2018;8(8):1235–1239.
10. Kilinc F, Ergun Y, Pekkolay Z, et al. Elevated neutrophil-to-lymphocyte ratio in the diagnosis of subacute thyroiditis. *Progress in Nutrition*. 2018;20(3):510–515.
11. Nishihara E, Ohye H, Amino N, et al. Clinical characteristics of 852 patients with subacute thyroiditis before treatment. *Intern Med*. 2008;47(8):725–729.
12. Fatourechi V, Aniszewski JP, Fatourechi GZE, et al. Clinical features and outcome of subacute thyroiditis in an incidence cohort: Olmsted County, Minnesota, study. *J Clin Endocrinol Metab*. 2003;88(5):2100–2105.
13. Benbassat CA, Olchovsky D, Tsvetov G, et al. Subacute thyroiditis: Clinical characteristics and treatment outcome in fifty-six consecutive patients diagnosed between 1999 and 2005. *J Endocrinol Invest*. 2007;30(8):631–635.
14. Kim JH, Bae KH, Choi YK, et al. Case of Subacute Thyroiditis Presenting as the Cause of Fever of Unknown Origin. *Korean J Med*. 2013;84(5):733–736.
15. Muqtadir F, Ahmed A, Gufran K, et al. Case of subacute thyroiditis presenting as the cause of pyrexia of unknown origin. *J Evolution Med Dental Sci*. 2015;4(88):15373–15375.
16. Dalugama C. Asymptomatic thyroiditis presenting as pyrexia of unknown origin: a case report. *Journal of Medical Case Reports*. 2018;12:1–3.
17. Hasegawa K, Yamamoto W, Otsuji S, et al. TCTAP C-075 Effective Utilization of a Separate Conus-septal Branch for the Treatment of the Chronic Total Occlusion in the Right Coronary Artery. *J Am College Cardiol*. 2018;71(16suppl):143–144.
18. Mizuguchi Y, Hashimoto S, Shibutani H, et al. Successful treatment of a nonagenarian patient with acute coronary syndrome complicated with chronic total occlusion of the left main coronary artery. *Cardiovasc Revasc Med*. 2017;18(4) 276–280.
19. Fihn SD, Blankenship JC, Alexander KP, et al. 2014 ACC/AHA/AATS/PCNA/SCAI/STS focused update of the guideline for the diagnosis and management of patients with stable ischemic heart disease: a report of the American College of Cardiology/American Heart Association Task Force on Practice Guidelines, and the American Association for Thoracic Surgery, Preventive Cardiovascular Nurses Association, Society for Cardiovascular Angiography and Interventions, and Society of Thoracic Surgeons. *J Am Coll Cardiol*. 2014;64(18):1929–1949.
20. Perry A, Chung MJ, Novak E, et al. Development of a risk score to identify patients with type 2 diabetes mellitus and multivessel coronary artery disease who can defer bypass surgery. *Diagnostic and Prognostic Research*. 2019;3:1–9.