

# Review Articles

## Adrenal Myelolipoma: Diagnosis and Management

Siamak Daneshmand,<sup>1\*</sup> Marcus L Quek<sup>2</sup>

<sup>1</sup>*Section of Urologic Oncology, Division of Urology and Renal Transplantation, Oregon Health and Science University, Portland, USA*

<sup>2</sup>*Department of Urology, Loyola University Stritch School of Medicine, Maywood, Illinois, USA*

### ABSTRACT

**Introduction:** Adrenal myelolipomas are benign lesions that contain hematopoietic and fatty elements. They are usually hormonally inactive and asymptomatic until they reach large sizes. With the routine use of cross-sectional imaging, these lesions are now being discovered with increasing frequency.

**Materials and Methods:** We performed a comprehensive review of the literature using the PubMed database containing the key word *adrenal myelolipoma*.

**Results:** We identified 492 articles written from 1956 to 2006 and reviewed 93 in detail including the authors' own experience. In this review, we highlighted the salient diagnostic features of adrenal myelolipomas and offered a guide for management of these benign lesions.

**Conclusion:** Adrenal myelolipomas may grow over time, but they can usually be followed without surgical excision. In some cases, very large myelolipomas can present with pain and can be confused with necrotic adrenal carcinomas, thus necessitating their surgical removal.

**KEY WORDS:** adrenal gland neoplasm, myelolipoma, diagnosis, adrenal imaging

### Introduction

Adrenal myelolipomas are rare benign tumors composed of mature adipose and hematopoietic tissue. In 1905, Gierke first described the occurrence of a mass lesion in the adrenal glands composed of mature fat and mixed myeloid and erythroid cells.<sup>(1)</sup> They were subsequently termed *formations myelolipomatoses* by Oberling in 1929.<sup>(2)</sup> Thought to arise from metaplasia of undifferentiated stromal cells, these tumors used to be discovered primarily at autopsy; however, today they are typically incidental findings due to the widespread use of ultrasonography, computerized tomography (CT), and magnetic

resonance imaging (MRI). Although the true incidence of these tumors is unknown, less than 100 cases have been described in the literature and the incidence is estimated at 0.08% to 0.25%.<sup>(3,4)</sup> Myelolipomas account for approximately 3 to 5% of all primary adrenal tumors. They are usually noted in late adult life with a mean age at presentation of 62 years in one of the larger series.<sup>(5)</sup> Men and women appear to be equally affected.

These lesions are usually unilateral and asymptomatic, although a number of bilateral tumors have been described in the literature.<sup>(6)</sup> Myelolipomas are often less than 4 cm in diameter when discovered; however, they can attain very large sizes.<sup>(7)</sup> The largest adrenal myelolipoma reported in the literature weighed 5900 g.<sup>(8)</sup> After excision, they generally do not recur, with recurrence-free survival rates of up to

\*Corresponding author: Section of Urologic Oncology, Division of Urology & Renal Transplantation, Oregon Health & Science University, 3181 SW Sam Jackson Park Rd, L588, Portland, OR 97229, USA.  
Tel: +1 503 494 1342, Fax: +1 503 494 8671  
E-mail: siadaneshmand@yahoo.com

12 years being reported.<sup>(5)</sup> These tumors are generally hormonally-inactive, although there are case reports of their association with overproduction of adrenal hormones. Myelolipomas have been associated with overproduction of dehydroepiandrosterone-sulphate (DHEAS), congenital adrenal hyperplasia caused by 21-hydroxylase deficiency, congenital adrenal 17  $\alpha$ -hydroxylase deficiency, Cushing disease, Conn syndrome, adrenal insufficiency, and pheochromocytoma.<sup>(9,10)</sup> Some of these tumors coexist with adrenal adenomas which may in part account for the hormonal activity. Among them, congenital adrenal hyperplasia and Cushing syndrome appear to be the two most common endocrine disorders described. Overall, more than 25 cases of endocrine dysfunction associated with myelolipoma have been reported in the English and Japanese literature.<sup>(11)</sup>

### Diagnosis

**Imaging.** Most adrenal myelolipomas are asymptomatic. Symptoms associated with large myelolipomas are typically vague and include back or abdominal pain. Ultrasonography, CT, and MRI are effective in diagnosing adrenal myelolipomas in more than 90% of cases, with CT being the most sensitive diagnostic imaging modality.<sup>(12,13)</sup> Myelolipomas appear as well-delineated heterogeneous masses with low-density mature fat (less than -30 Hounsfield Units [HU]) interspersed with more dense myeloid tissue (Figure 1).<sup>(14)</sup> A fatty adrenal mass is virtually diagnostic of myelolipoma, although other less

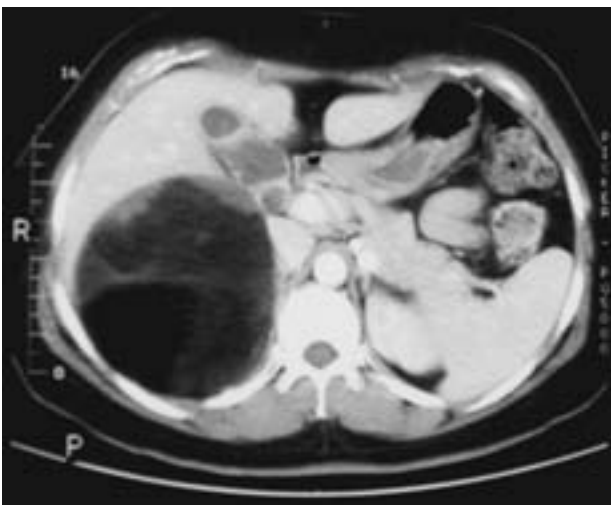

FIG. 1. Abdominal CT scan in a 37-year-old woman who presented to our department with vague right abdominal discomfort of 4 weeks' duration. The large adrenal mass is composed mostly of fat with well-defined borders.

common adrenal tumors containing fat such as teratoma, lipoma, and liposarcoma should be considered. The differential diagnosis should also include angiomyolipoma, although it is much more common in the kidneys. Although adrenal adenomas may appear as low-density lesions (with attenuation values less than 18 HU), they are more dense and homogeneous than myelolipomas. Myelolipomas often have a discrete capsule, and the soft tissue component is enhanced after the administration of intravenous contrast, whereas liposarcomas generally exhibit an infiltrative pattern with attenuation coefficients up to +30 HU.<sup>(15)</sup> On ultrasonography, myelolipomas appear as a well-defined tumor with varying degrees of hyperechoic areas (fatty tissue) and hypoechoic areas (myeloid tissue).<sup>(12)</sup> Magnetic resonance imaging does not add significantly to the tissue characterization of these tumors; however, it can help in distinguishing the origin of the tumor and assessing tissues planes for surgical planning. Magnetic resonance imaging shows that this tumor has a signal intensity equal to subcutaneous and retroperitoneal fat on all spin echo pulse sequences.<sup>(16)</sup> The tumors are generally large when they are discovered in part due to the fact that they are asymptomatic until they begin to cause compression of adjacent structures. Calcification can be seen in up to 27% of adrenal myelolipomas and is also a feature of other benign lipomatous tumors of the adrenal glands on imaging.<sup>(5)</sup>

**Fine-Needle Aspiration.** If the diagnosis of adrenal myelolipoma cannot be made with confidence using noninvasive imaging, fine-needle aspiration (FNA) biopsy should be considered.<sup>(17-19)</sup> Also in cases where expectant management is being considered, FNA can definitively rule out malignancy. The presence of mature adipocytes and hematopoietic elements is diagnostic of myelolipoma.<sup>(18,20)</sup> Approximately 15 case reports have described cytological findings of this tumor obtained by FNA.<sup>(21)</sup>

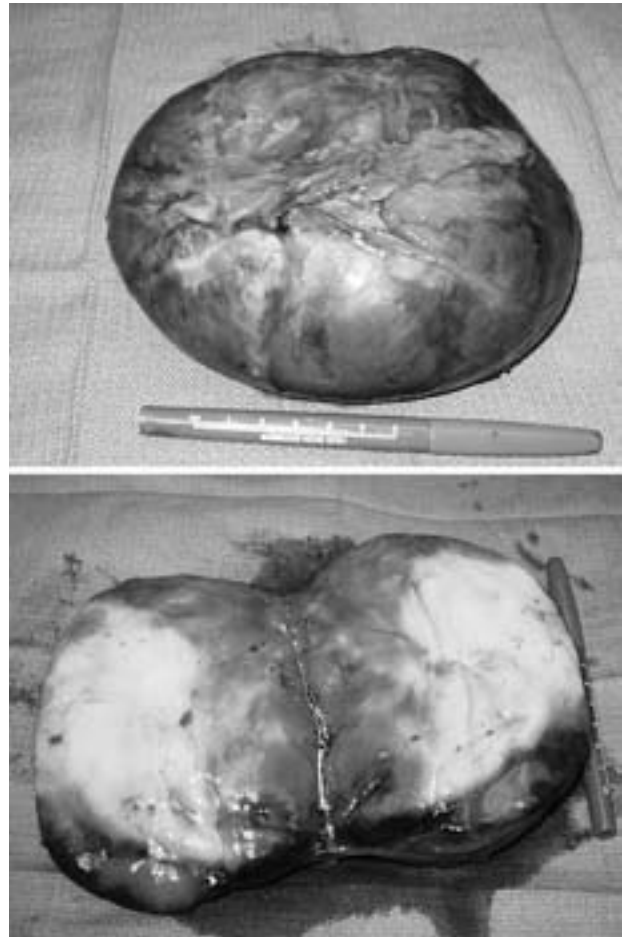
### Management

The increasing number of incidentally discovered adrenal myelolipomas raises the question of appropriate treatment modalities which include watchful waiting and surgical removal. Small asymptomatic tumors less than 4 cm can be monitored expectantly since they pose little risk of spontaneous rupture or bleeding. We

suggest that symptomatic tumors or myelolipomas larger than 7 cm should be removed since the risk of spontaneous rupture with retroperitoneal hemorrhage is increased. In addition, we believe bilateral myelolipomas should be treated similarly to bilateral angiomyolipomas of the kidney with removal of the larger, more symptomatic mass and expectant management of the smaller mass in order to avoid lifelong steroid substitution.

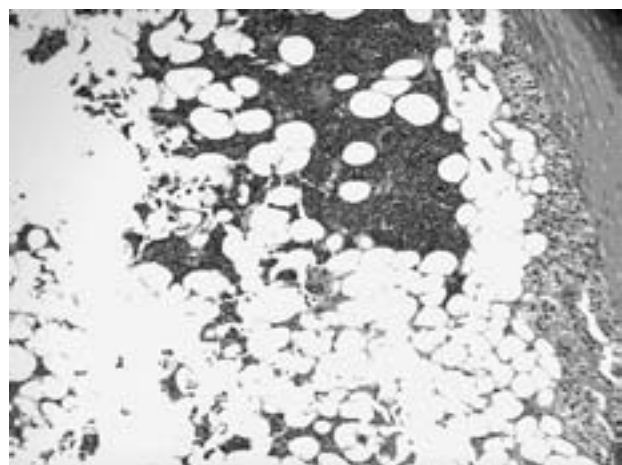
**Observation.** Most lesions found incidentally that are homogenous on imaging and do not have any malignant characteristics can be safely followed with annual imaging. Han and colleagues reported on 16 adrenal myelolipomas followed without surgical intervention for an average of 3.2 years (range 0.3 to 10.8 years). Thirteen patients remained asymptomatic and 2 experienced persistent vague abdominal discomfort. A total of 13 tumors from 12 patients were serially imaged, with tumor size increasing in 6, decreasing in 2, and remaining unchanged in 5.<sup>(22)</sup> These data suggest that at least half of adrenal myelolipomas can be treated conservatively. However, there are several situations in which surgical removal of the tumor may be warranted. Symptomatic masses should be removed since observation is doubtful to relieve pain or discomfort associated with the mass. Additionally, myelolipomas have been reported to grow significantly during observation and there are a number of case reports of spontaneous hemorrhage or bleeding with minor trauma.<sup>(23-28)</sup>

**Surgical Treatment.** Although myelolipomas are benign, their size and propensity to grow often warrant surgical removal. Rare hormonally-active tumors should also be excised. Smaller tumors are amenable to laparoscopic resection; however, large symptomatic tumors often warrant wide operative exposure via a Chevron or thoracoabdominal incision. In some experienced centers, even large tumors have been successfully removed laparoscopically.<sup>(29)</sup> Gaining adequate exposure is crucial in avoiding injury to the vena cava on the right or the aorta on the left. Myelolipomas are generally encapsulated and peel off of surrounding structures. Gross anatomical section typically shows sharply defined yellow adipose tissue with varying amounts of red-brown hematopoietic elements (Figure 2).<sup>(14)</sup> Microscopic examination reveals scattered islands of fat cells intermixed with hematopoietic stem



**FIG. 2.** The patient subsequently underwent a right thoracoabdominal adrenalectomy. Gross anatomical section showed an encapsulated tumor with sharply defined yellow adipose tissue with varying amounts of red-brown hematopoietic elements.

cells (Figure 3).<sup>(14)</sup> Although rare, areas of hemorrhage and necrosis may be observed. A difficult dissection should warn the surgeon of the possibility of a malignancy such as a liposarcoma, and frozen sections should be



**FIG. 3.** Histological examination showed a typical myelolipoma composed of a mixture of mature adipocytes and hematopoietic elements (hematoxylin-eosin,  $\times 200$ ).

obtained in order to ascertain whether adequate margins are obtained.

### Conclusion

Most myelolipomas are benign and clinically silent tumors which can be definitively diagnosed with cross-sectional imaging. There is an increasing number of cases reporting the association of myelolipoma with various endocrine disorders which emphasizes the importance of a thorough pre-operative workup. Smaller, asymptomatic myelolipomas can be observed expectantly with surgical resection reserved for large or symptomatic tumors.

### References

- Gierke E. Uber Knochenmarksgewebe in der Nebenniere. *Zeiglers Beitr Path Anat.* 1905;suppl 7:311-24.
- Oberling C. Les formations myelolipomateuses. *Bull Ass Fr Etude Cancer.* 1929;18:234-46.
- Olsson CA, Krane RJ, Klugo RC, Selikowitz SM. Adrenal myelolipoma. *Surgery.* 1973;73:665-70.
- McDonnell WV. Myelolipoma of adrenal. *AMA Arch Pathol.* 1956;61:416-9.
- Lam KY, Lo CY. Adrenal lipomatous tumours: a 30 year clinicopathological experience at a single institution. *J Clin Pathol.* 2001;54:707-12.
- Bishoff JT, Waguespack RL, Lynch SC, May DA, Poremba JA, Hall CR. Bilateral symptomatic adrenal myelolipoma. *J Urol.* 1997;158:1517-8.
- Vierna J, Laforga JB. Giant adrenal myelolipoma. Report of a case and review of the literature. *Scand J Urol Nephrol.* 1994;28:301-4.
- Boudreaux D, Waisman J, Skinner DG, Low R. Giant adrenal myelolipoma and testicular interstitial cell tumor in a man with congenital 21-hydroxylase deficiency. *Am J Surg Pathol.* 1979;3:109-23.
- Wagnerova H, Lazurova I, Bober J, Sokol L, Zachar M. Adrenal myelolipoma. 6 cases and a review of the literature. *Neoplasma.* 2004;51:300-5.
- Umpierrez MB, Fackler S, Umpierrez GE, Rubin J. Adrenal myelolipoma associated with endocrine dysfunction: review of the literature. *Am J Med Sci.* 1997;314:338-41.
- Hisamatsu H, Sakai H, Tsuda S, Shigematsu K, Kanetake H. Combined adrenal adenoma and myelolipoma in a patient with Cushing's syndrome: case report and review of the literature. *Int J Urol.* 2004;11:416-8.
- Vick CW, Zeman RK, Mannes E, Cronan JJ, Walsh JW. Adrenal myelolipoma: CT and ultrasound findings. *Urol Radiol.* 1984;6:7-13.
- Musante F, Derchi LE, Zappasodi F, et al. Myelolipoma of the adrenal gland: sonographic and CT features. *AJR Am J Roentgenol.* 1988;151:961-4.
- Quek ML, Daneshmand S. Urology photo quiz: adrenal myelolipoma. *Resid Staff Physician.* 2003;50:19.
- Szolar DH, Schmidt-Kloiber C, Preidler KW. Computed tomography evaluation of adrenal masses. *Curr Opin Urol.* 1999;9:143-51.
- Musante F, Derchi LE, Bazzocchi M, Avataneo T, Gandini G, Pozzi-Mucelli RS. MR imaging of adrenal myelolipomas. *J Comput Assist Tomogr.* 1991;15:111-4.
- deBlois GG, DeMay RM. Adrenal myelolipoma diagnosis by computed-tomography-guided fine-needle aspiration. A case report. *Cancer.* 1985;55:848-50.
- Gaboardi F, Carbone M, Bozzola A, Galli L. Adrenal incidentalomas: what is the role of fine needle biopsy? *Int Urol Nephrol.* 1991;23:197-207.
- Galli L, Gaboardi F. Adrenal myelolipoma: report of diagnosis by fine needle aspiration. *J Urol.* 1986;136:655-7.
- Wadih GE, Nance KV, Silverman JF. Fine-needle aspiration cytology of the adrenal gland. Fifty biopsies in 48 patients. *Arch Pathol Lab Med.* 1992;116:841-6.
- Settakorn J, Sirivanichai C, Rangdaeng S, Chaiwun B. Fine-needle aspiration cytology of adrenal myelolipoma: case report and review of the literature. *Diagn Cytopathol.* 1999;21:409-12.
- Han M, Burnett AL, Fishman EK, Marshall FF. The natural history and treatment of adrenal myelolipoma. *J Urol.* 1997;157:1213-6.
- Albala DM, Chung CJ, Sueoka BL, Memoli VA, Heaney JA. Hemorrhagic myelolipoma of adrenal gland after blunt trauma. *Urology.* 1991;38:559-62.
- Hoeffel C. Rupture and growth of adrenal myelolipoma in two patients. *Br J Radiol.* 1998;71:693.
- Wong KW, Lee IP, Sun WH. Case report: rupture and growth of adrenal myelolipoma in two patients. *Br J Radiol.* 1996;69:873-5.
- Goldman HB, Howard RC, Patterson AL. Spontaneous retroperitoneal hemorrhage from a giant adrenal myelolipoma. *J Urol.* 1996;155:639.
- Catalano O. Retroperitoneal hemorrhage due to a ruptured adrenal myelolipoma. A case report. *Acta Radiol.* 1996;37:688-90.
- Russell C, Goodacre BW, vanSonnenberg E, Orihuela E. Spontaneous rupture of adrenal myelolipoma: spiral CT appearance. *Abdom Imaging.* 2000;25:431-4.
- Schaeffer EM, Kavoussi LR. Adrenal myelolipoma. *J Urol.* 2005;173:1760.