

Rowan University

Rowan Digital Works

Stratford Campus Research Day

23rd Annual Research Day

May 2nd, 12:00 AM

Something has Fallen: Pelvic Organ Prolapse or Vaginal Cuff Dehiscence and Evisceration? A Case Report.

Alexandra Nutaitis
Rowan University

Laurie Kane M.D.
Southern Ocean Medical Center, Manahawkin, NJ

Follow this and additional works at: https://rdw.rowan.edu/stratford_research_day



Part of the [Female Urogenital Diseases and Pregnancy Complications Commons](#), [Obstetrics and Gynecology Commons](#), [Surgery Commons](#), and the [Urogenital System Commons](#)

Let us know how access to this document benefits you - share your thoughts on our [feedback form](#).


Nutaitis, Alexandra and Kane, Laurie M.D., "Something has Fallen: Pelvic Organ Prolapse or Vaginal Cuff Dehiscence and Evisceration? A Case Report." (2019). *Stratford Campus Research Day*. 44.
https://rdw.rowan.edu/stratford_research_day/2019/may2/44

This Poster is brought to you for free and open access by the Conferences, Events, and Symposia at Rowan Digital Works. It has been accepted for inclusion in Stratford Campus Research Day by an authorized administrator of Rowan Digital Works. For more information, please contact brush@rowan.edu.

Something has Fallen: Pelvic Organ Prolapse or Vaginal Cuff Dehiscence and Evisceration? A Case Report

Alexandra Nutaitis, BS, Laurie Kane, MD, FACOG

Department of Urogynecology, Southern Ocean Medical Center, Manahawkin, NJ



Hackensack
Meridian Health

LEARNING OBJECTIVES

1. Recognize a late presenting complication of hysterectomy
2. Include vaginal cuff dehiscence with evisceration (VCDE) in the differential diagnosis of acute pelvic organ prolapse
3. Appreciate the relative rarity of VCDE in younger women

CASE PRESENTATION

- 36 year old G0P0 Caucasian female presented to the ED with a chief complaint of sudden onset excruciating epigastric pain, followed by diarrhea and visible vaginal bulge.
- Her complaints also included nausea, vomiting, and vaginal pressure.
- Pertinent PMH: Stage IIIC breast cancer diagnosed 15 months prior s/p bilateral mastectomy, radiation, chemotherapy; hypertension; cardiomyopathy; GERD
- Pertinent surgical history: robotic-assisted prophylactic hysterectomy and BSO six months prior
- Social history: smokes up to 1 cigarette/wk, first postoperative coitus 2 days prior
- Home medications: carvedilol, anastrozole, citalopram, neratinib, omeprazole
- Diagnosed with pelvic organ prolapse in the ED, which was reduced, leading to a reduction in her pain.

UROGYNECOLOGY PHYSICAL EXAM

- ED VS : BP 142/77, HR 73, RR 20, temp 98 ° F, Wt 86.2 kg
- Abdominal exam: tenderness to palpation, no rebound, no guarding
- Speculum exam: no pelvic organ prolapse, bowel was visible at the vaginal cuff with clear yellow fluid pooling in the vaginal vault
- Indigo carmine dye was used to fill the bladder via urethral catheter and gauze was placed into the vagina
- Vesicovaginal fistula was ruled out. VCDE was suspected.

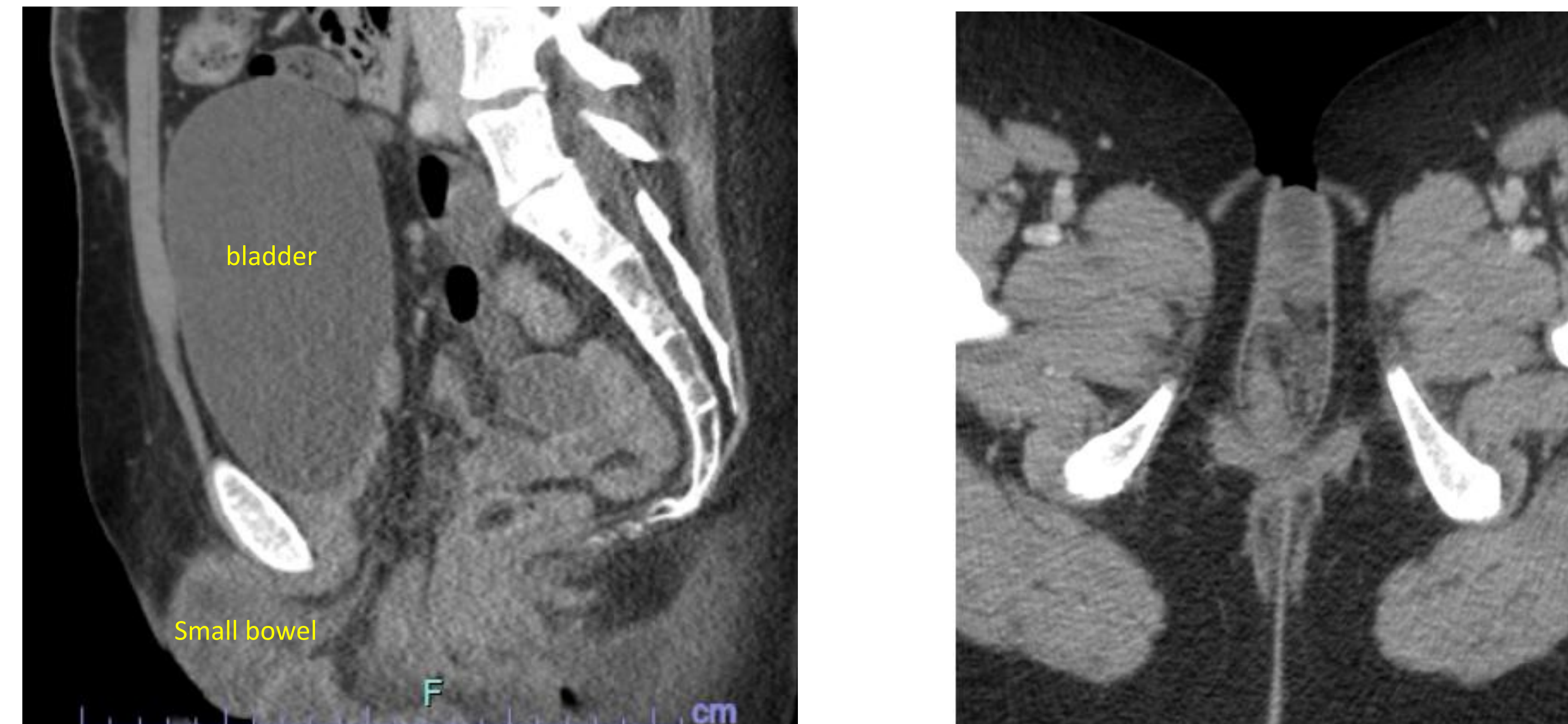
LABORATORY DATA

Lab (normal range)	Day 0 *	Day 1 **	POD 1
WBC (4.5-11 K/uL)	6.0	10.3 ↑	9.9
Neutrophil % (50-70%)	51.4	78.8 (H) ↑	70.6
BUN (5-25 mg/dL)	19	11	7
Creatinine (0.44-1.0 mg/dL)	0.62	0.58	0.54
Hemoglobin (12-16 gm/dL)	10.5 (L)	9.9 (L)	9.6 (L)
Bilirubin (0.2-1.3 mg/dL)	0.3	0.9	0.5

* day of admission,

** operative day

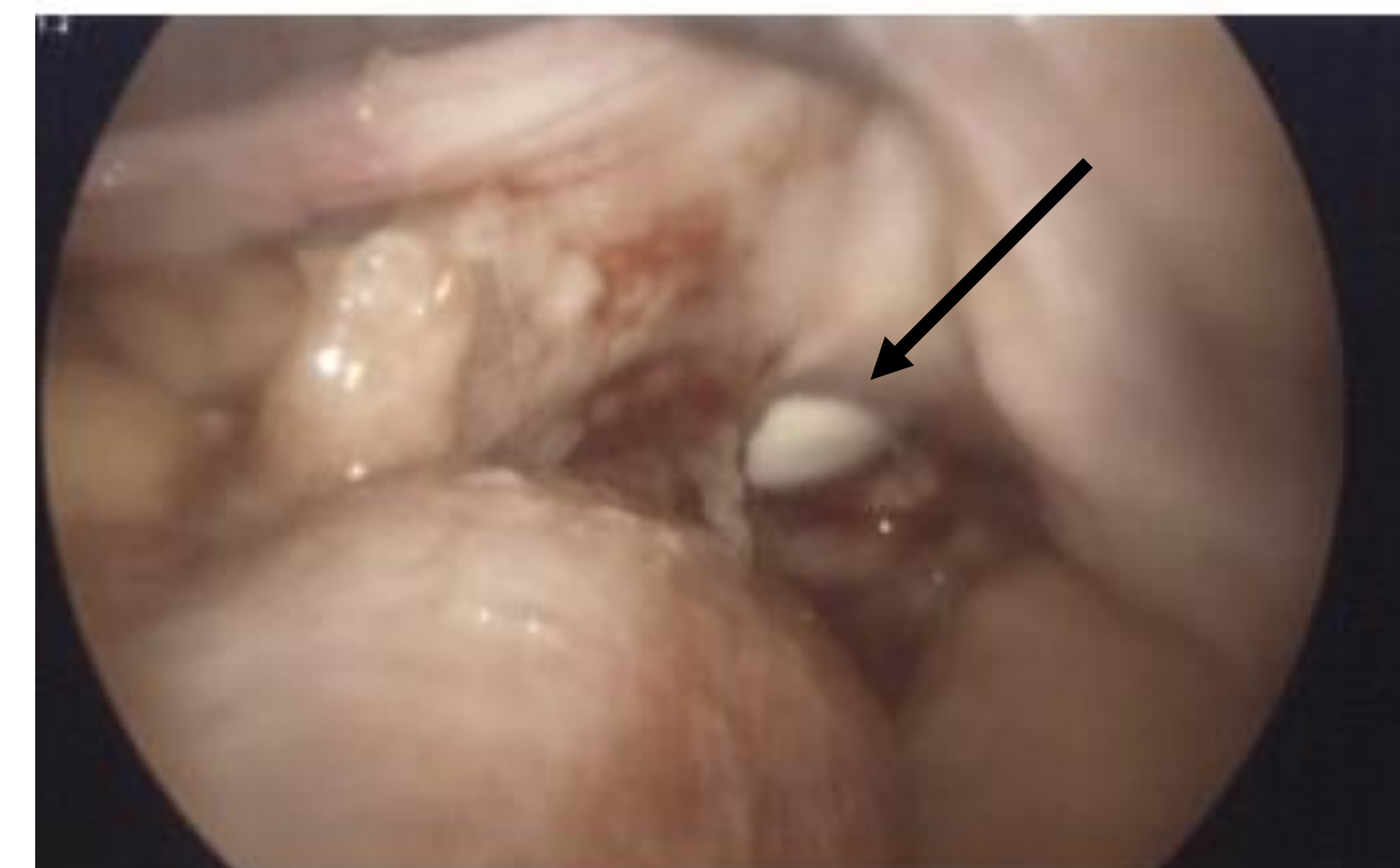RADIOGRAPHIC IMAGING



CT abdomen/pelvis with IV contrast: Microscopic pneumoperitoneum. Prolapse of bowel loops into the vaginal vault, localized small bowel obstruction, "pelvic floor prolapse with large enterocele identified"

INTRAOPERATIVE IMAGING

A sterile glove with gauze pad was placed in the vagina in order to maintain pneumoperitoneum during procedure. A 4 cm vaginal cuff defect was visualized.



SURGICAL MANAGEMENT and OUTCOME

- Exploratory laparoscopy with lysis of adhesions and transvaginal cuff closure was performed
- A sterile glove with gauze pad was placed in the vagina in order to maintain pneumoperitoneum during procedure
- An extensive amount of adhesions that were severely adherent to the pelvis, bladder, and loops of bowel were removed.
- A 4 cm vaginal cuff defect was identified and the entire length of the bowel and mesentery was inspected.
- VCDE was confirmed.
- No bowel perforation was identified.
- Patient was treated for peritonitis with IV antibiotics
- Post-operative course was uncomplicated and she was discharged on POD #2

CONCLUSIONS and SUMMARY

- VCDE refers to the separation of the anterior and posterior edges of the vaginal cuff followed by expulsion of intraperitoneal contents through the separated incision.
- Vaginal cuff dehiscence (VCD) post hysterectomy occurs at a rate of 0.14-4.1%^{1,3} and VCDE at a rate of 0.032-1.2%.^{2,3}
- The small bowel (distal ileum) is the most commonly prolapsed organ. Complications include bowel necrosis resulting in a bowel resection rate of up to 20%.⁴
- An elevated WBC count, acute onset vaginal protrusion, and severe abdominal pain may help delineate VCDE from pelvic organ prolapse.
- Primary risk factors for VCD include mode of incision and cuff closure, tissue quality, obesity, and increased strain on healing vaginal cuff.²
- In premenopausal women, VCDE risk is low but most frequently is associated with vaginal trauma associated with early resumption of coitus, gynecological instrumentation, or a foreign body.⁵
- Although there is currently no evidence based recommendation on the appropriate time to resume coitus post hysterectomy, most episodes of intercourse-precipitated VCD occur within 4 postoperative months.^{1,2}
- This patient presents as an unusual case as she is a young, surgically postmenopausal woman, who waited what would be considered an appropriate length of time to resume coitus.
- Her risk factors for VCDE included: possible reduced tissue quality secondary to chemotherapy, tobacco use, and obesity.
- Delay in diagnosis can lead to cuff inflammation, adhesions, and distortion of tissue planes complicating dissection of the surrounding bowel and bladder and repair of the cuff.⁶
- Clinicians, including emergency room physicians, general surgeons, and OB/GYNS must be cognizant of the possibility of VCDE, as prompt recognition and management is critical for organ preservation and will result in best patient outcomes.

REFERENCES

1. Hur HC, Guido RS, Mansuria SM, Hacker MR, Sanfilippo JS, Lee TT. Incidence and patient characteristics of vaginal cuff dehiscence after different modes of hysterectomies. J Minim Invasive Gynecol 2007;14:311-7
2. Nezhat C, Kennedy Burns M, Wood M, Nezhat C, Nezhat A, Nezhat F. Vaginal cuff dehiscence and evisceration. Obstet Gynecol. 2018;132(4):972-985.
3. Kho RM, Akl MN, Cornella JL, Magtibay PM, Wechter ME, Magrina JF. Incidence and characteristics of patients with vaginal cuff dehiscence after robotic procedures. Obstet Gynecol 2009;114:231-5.
4. Ramirez PT, Klemer DP. Vaginal evisceration after hysterectomy: a literature review. Obstet Gynecol Surv 2002;57:462-7.
5. Cardosi RJ, Hoffman MS, Roberts WS, Spellacy WN. Vaginal evisceration after hysterectomy in premenopausal women. Obstet Gynecol 1999;94:859
6. Hur HC, Lightfoot M, McMillin MG, Kho KA. Vaginal cuff dehiscence and evisceration: a review of the literature. Curr Opin Obstet Gynecol 2016;28:297-303.