

2019

Cavernous sinus thrombosis complicated by carotid artery occlusion: A case report

Faisal Taleb, Seraj S. Ajaj, Abdussalam Abograra, and Ali Eldeeb

Author Affiliations

Faisal Taleb (*Tripoli University Hospital, Tripoli, Libya*)

Seraj S. Ajaj (*Tripoli University Hospital, Tripoli, Libya*)

Abdussalam Abograra (*Tripoli University Hospital, Tripoli, Libya*)

Ali Deeb (*Tripoli University Hospital, Tripoli, Libya*)

Corresponding Author

Faisal Taleb FRCS, MD

Tripoli University Hospital

Tripoli, Libya

Email: Talebfaisal@gmail.com

Follow this and additional works at: <https://mds.marshall.edu/mjm>

 Part of the [Medicine and Health Sciences Commons](#)



This work is licensed under a [Creative Commons Attribution 4.0 License](#).

Recommended Citation

Taleb, Faisal; Ajaj, Seraj S.; Abograra, Abdussalam; and Eldeeb, Ali (2019) "Cavernous sinus thrombosis complicated by carotid artery occlusion: A case report," *Marshall Journal of Medicine*: Vol. 5: Iss. 4, Article 7.

DOI: [10.33470/2379-9536.1221](https://doi.org/10.33470/2379-9536.1221)

Available at: <https://mds.marshall.edu/mjm/vol5/iss4/7>

DOI: [10.33470/2379-9536.1221](https://doi.org/10.33470/2379-9536.1221)

Author Footnote: The parents have provided consent for the case report and use of photographs. The authors wish to thank the cooperating family members for the necessary medical data and photographs for Publication.

Open Access |

Cavernous sinus thrombosis complicated by carotid artery occlusion: a case report

Abstract

Cavernous sinus thrombosis (CST) is a fatal phenomenon that requires clinical suspicion and emergent imaging for correct diagnosis. However, only a few authors reported severe involvement of the internal carotid artery (ICA). Here we report an 11-year-old girl diagnosed with cavernous sinus thrombosis complicated by left internal carotid artery occlusion.

Keywords

Cavernous sinus thrombosis, Magnetic resonance imaging, Computer Tomography, Magnetic resonance angiography, Lemierre syndrome

Introduction

Cavernous sinus thrombosis (CST) was first described by Debase in 1778.¹ The primary source of CST may be a distant focus, with septicemia preceding thrombosis of the cavernous sinus. However, the infection may spread from the facial regions, via the facial venous plexus or from the sphenoid sinus, directly to the cavernous sinus.² The cavernous sinus, which is anatomically placed in the posterior portion of the optic canal and superior to the orbital fissure, is a vital structure as a pathway for the internal carotid artery and cranial nerves III, IV, V, and VI. Thus, any infection through the valve-less system of sinuses and veins allows for the potential spread of bacteria or thrombosis. This could be followed by clinical manifestations including ptosis, ophthalmoplegia, diplopia and paresthesia around the orbital cavity due to involvement of the eye motor nerves and impairment in the ophthalmic and maxillary branches of cranial nerve V.¹ We present a case of carotid artery occlusion secondary to cavernous sinus thrombosis which is not frequently reported in the literature.

Case report

An 11-year-old girl presented to the emergency room with a headache and left eye swelling for seven days. The patient was afebrile; examination revealed proptosis, eyelid edema, weakness of downgaze of the left eye and a dilated poorly reactive left pupil. Motor and sensory exam were unremarkable except for poor light response in the left eye. An orbit CT scan with angiography was performed and shows left superior ophthalmic vein and preseptal region thickening (Fig1). Because of the nonspecific orbit CT finding, brain magnetic resonance imaging was performed (Fig 2). After the MRI revealed the left carotid artery thrombosis, angiography study was obtained.

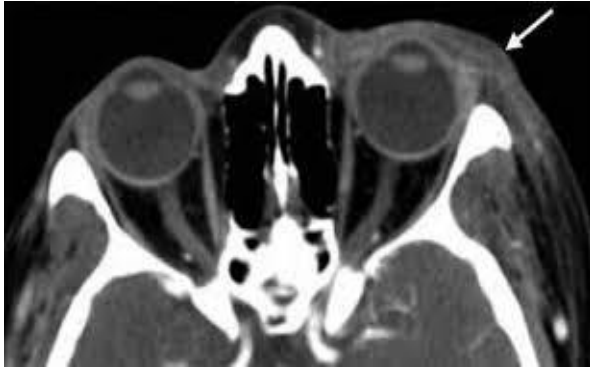


Fig 1. Periorbital. Axial contrast enhanced CT image show's swelling around the left eye.

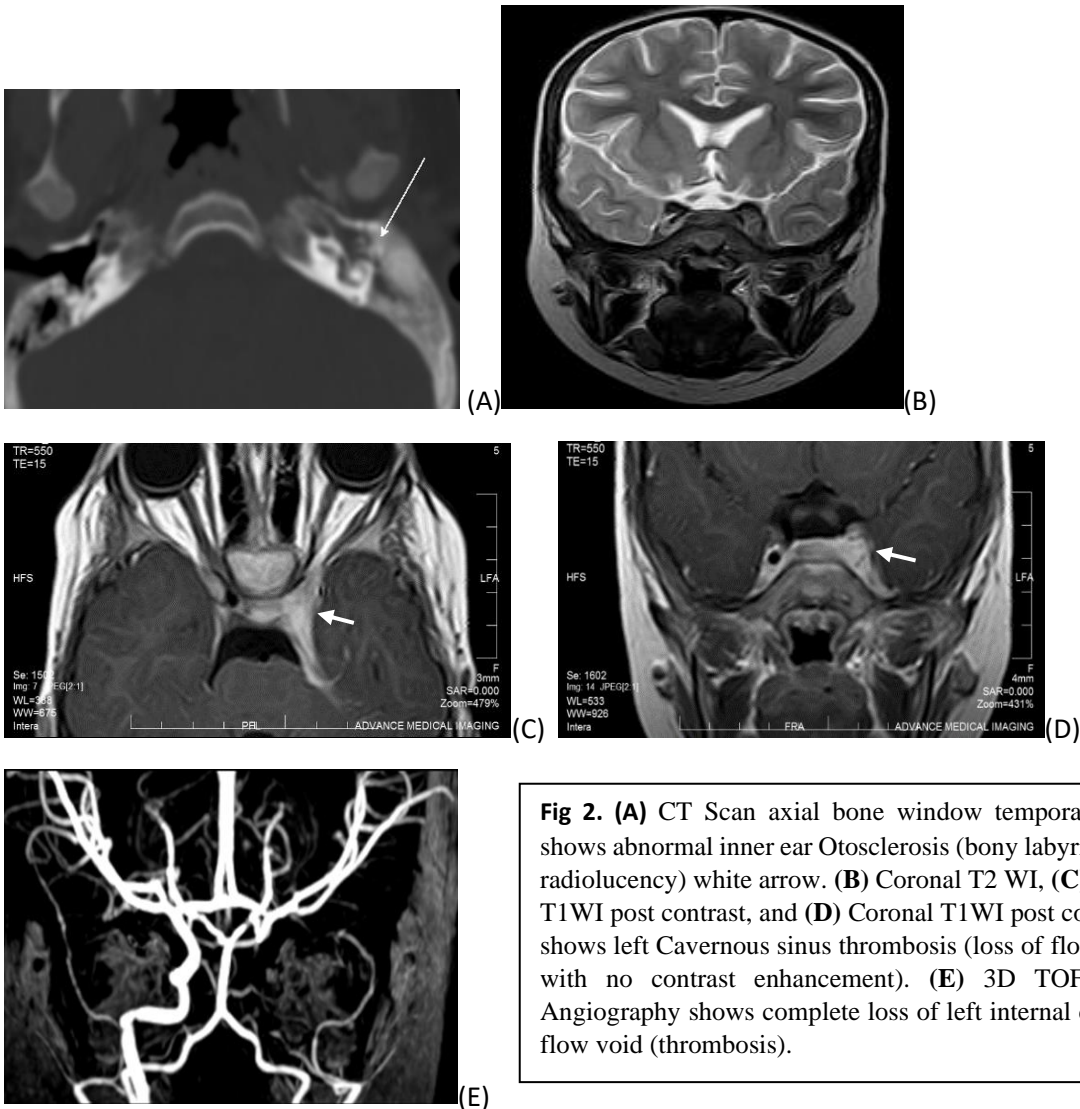


Fig 2. (A) CT Scan axial bone window temporal bone shows abnormal inner ear Otosclerosis (bony labyrinthine radiolucency) white arrow. (B) Coronal T2 WI, (C) Axial T1WI post contrast, and (D) Coronal T1WI post contrast: shows left Cavernous sinus thrombosis (loss of flow void with no contrast enhancement). (E) 3D TOF MRI Angiography shows complete loss of left internal carotid flow void (thrombosis).

Discussion

Cavernous sinus thrombosis is usually a late sequence of an infectious cause. The organisms that most frequently cause infection in the cavernous sinus are *Staphylococcus aureus* (35%), *Streptococcus pneumoniae* and other streptococci species, gram-negative bacilli, and anaerobes.³⁻⁵ The diagnosis is established through clinical symptoms and radiological findings. In our case, the symptoms included involvement of the left third cranial nerve, ocular pain, and headache. Currently, computed tomography (CT) scan or magnetic resonance imaging (MRI) with contrast is the modality of choice to confirm the diagnosis of CST. MRI with MR venogram (MRV) is preferred as the MRV will show the absence of venous flow in the affected cavernous sinus and carotid angiography can demonstrate narrowing or obstruction of the inter-cavernous segment of the internal carotid artery.⁶

The occlusion of the carotid artery due to cavernous sinus thrombosis is rare and few authors reported the condition in literature. Lemierre syndrome is defined as a case of septic thrombosis of the jugular vein with septic emboli caused by an oropharyngeal infection produced by *F. necrophorum* and firstly described in 1936.⁷ However, compared to other reported cases in literature similar to our report, our case was described as a variant of Lemierre syndrome in which there is internal carotid artery occlusion but no jugular involvement.⁸ From our review of the literature we found variability of signs, symptoms and clinical course of CST complicated by carotid occlusion; those signs and symptoms may include headache, cranial nerves palsy, hemiplegia, and loss of consciousness.⁹ In fact, the internal carotid artery thrombosis in children is rare and the sequel of this event is hard to predict and can be presented with hemiplegia and loss of consciousness.⁹ Surprisingly, our patient did not have a stroke which was proved by no ischemic changes on brain MRI. The sequence of carotid artery thrombosis in our case was after the event of CST and was accidentally discovered by follow-up imaging studies. The treatment course in our case was established with antibiotics and anticoagulation and the patient followed-up at neurosurgical and radiology departments with no neurological deficit. In conclusion, although internal carotid artery involvement in cavernous sinus thrombosis is a rare condition, it is vital to be familiar with it to obtain an early diagnosis and emergent therapeutic response.

References

1. Cho JY, Kim HM, Ryu JY. Cavernous sinus thrombosis progression from trismus. *J Korean Assoc Oral Maxillofac Surg.* 2015;41(1):43-7.
2. Lai PF, Cusimano MD. The spectrum of cavernous sinus and orbital venous thrombosis: a case and a review. *Skull Base Surg.* 1996;6(1):53-59.
3. Cannon ML, Antonio BL, McCloskey JJ, Hines MH, Tobin JR, Shetty AK. Cavernous sinus thrombosis complicating sinusitis. *PediatrCrit Care Med.* 2004;5(1):86-88.
4. Ebright JR, Pace MT, Niazi AF. Septic thrombosis of the cavernous sinuses. *Arch Intern Med.* 2001;161:2671-2676.
5. Southwick FS, Richardson EP Jr, Swartz MD. Septic thrombosis of the dural venous sinuses. *Medicine.* 1986;65:82-106.
6. Tang Y, Booth T, Steward M, Solbach T, Wilhelm T. The imaging of conditions affecting the cavernous sinus. *ClinRadiol.* 2010;65(11):937-45.
7. Goyal MK, Kumar G, Burger R. Necrobacillosis resulting in isolated carotid thrombosis and massive stroke: a unique Lemierre variant? *J Neurol Sci.* 2009;287:108-110.
8. Karkos PD, Asrani S, Karkos CD, Leong SC, Theochari EG, Alexopoulou TD, et al. Lemierre's syndrome: a systematic review. *Laryngoscope.* 2009;119:1552-1559.
9. Mellick SA Phelan PD. Internal carotid artery occlusion in a child. *Archives of disease in childhood.* 1965;40(210):224-246.