

2019

## Acute Diagnosis of Wilson's Disease in a Teenage Patient

Sarah Irvin and Ryan McCarthy

### Author Affiliations

Sarah Irvin (*West Virginia University School of Medicine, Morgantown, West Virginia*)

Ryan McCarthy (*West Virginia University School of Medicine, Morgantown, West Virginia*)

### Corresponding Author


Sarah Irvin

West Virginia University School of Medicine

Morgantown, West Virginia

Email: sarah.irvin2@gmail.com

Follow this and additional works at: <https://mds.marshall.edu/mjm>

 Part of the [Digestive System Diseases Commons](#), [Genetic Phenomena Commons](#), [Hepatology Commons](#), [Medical Genetics Commons](#), [Medical Pathology Commons](#), [Nervous System Diseases Commons](#), [Neurology Commons](#), [Other Mental and Social Health Commons](#), and the [Psychiatry Commons](#)



This work is licensed under a [Creative Commons Attribution 4.0 License](#).

---

## Recommended Citation

Irvin, Sarah and McCarthy, Ryan (2019) "Acute Diagnosis of Wilson's Disease in a Teenage Patient," *Marshall Journal of Medicine*: Vol. 5: Iss. 4, Article 3.

DOI: [10.33470/2379-9536.1242](https://doi.org/10.33470/2379-9536.1242)

Available at: <https://mds.marshall.edu/mjm/vol5/iss4/3>

DOI: [10.33470/2379-9536.1242](https://doi.org/10.33470/2379-9536.1242)

Open Access | 

## Acute diagnosis of Wilson's disease in a teenage patient

### Abstract

Wilson's disease, a rare autosomal recessive genetic disease, is caused by a mutation in the ATP7B enzyme gene. Without this enzyme, copper builds up in the brain, liver, and cornea, causing a multitude of symptoms. It is important to consider Wilson's disease because the prognosis is dependent on timely diagnosis. This is an interesting case of a 19-year-old male who presented with suicidal thoughts and rapid weight loss. After many months and an extensive workup, Wilson's disease was diagnosed. Due to his rapid decline, he was transferred to a larger university healthcare center where he is currently enrolled in a clinical trial for WTX101.

### Keywords

Wilson's disease, depression, suicidal ideation, neurogenetics, copper metabolism, neurologic Wilson's disease, hepatic, tremor in teenager

### Introduction

Copper (Cu), an important mineral, is primarily stored in the liver and brain.<sup>1</sup> Vegetables, grains, meats, and fish are dietary sources of copper. Absorbed by the gastric mucosa and small intestine, copper is metabolized by ATP7A, an enzyme which secretes copper into the portal circulation where it binds to albumin and is carried to the liver.<sup>1</sup> ATP7B is an enzyme within the liver that is responsible for the synthesis of ceruloplasmin.<sup>1</sup> This is what binds 93% of copper in plasma and also aids in copper secretion in bile.<sup>1</sup>

Wilson's disease is a rare, autosomal recessive disease caused by a mutation in the ATP7B enzyme gene (chromosome 13).<sup>2</sup> This mutation leads to a toxic build-up of copper in the liver, cornea, and brain.

Wilson's disease has two major manifestations, hepatic and neurologic, though symptoms can overlap. Hepatic findings include fatigue, jaundice, hepatomegaly, and fulminant liver failure. Neurologic symptoms are often mild but can include dystonia, bradykinesia, tremor, ataxia, depression, and mood swings.

Hepatic symptoms often present in young children while neurological ones tend to occur after the age of eighteen.<sup>2</sup> Copper build-up in the cornea produces a yellowish-gold finding, the famous Kayser-Fleischer Ring (Figure 1). Wilson's disease is diagnosed by decreased ceruloplasmin (< 20 mg/dL), increased 24-hour urinary Cu (> 100  $\mu$ mol/24 hr), Kayser-Fleischer Ring, and neuropsychiatric symptoms.<sup>2</sup>

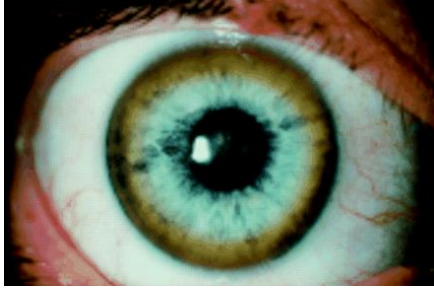

Figure 1: Kayser-Fleischer ring due to copper build-up in the human cornea (from Sullivan, 2002)

If Kayser-Fleischer Rings are absent but there is a high suspicion for Wilson's disease, a liver biopsy can be performed. Chelation therapies (penicillamine and trientine), zinc salts, and a low copper diet are mainstays of treatment. A liver transplant is the sole curative treatment for patients with hepatic disease.<sup>2</sup> This is reserved for cirrhotic patients and those with fulminant liver failure.<sup>4</sup>

The prognosis of Wilson's disease is highly dependent on the timeliness of diagnosis. Without proper treatment, patients with liver failure have a life expectancy of days to weeks. Those suffering from the neurologic disease may live upwards of 5 years.<sup>6</sup>

## Case

A 19-year-old recent high school graduate enjoyed life and worked part-time at Taco Bell. Respectable and dependable, he had never been involved with drugs or alcohol. College was around the corner for this bright, young man.

Over several months, he developed rapid weight loss and a dramatic increase in anxiety. Some startling personality changes followed. After expressing thoughts of suicide, his grandmother took him to the emergency department (ED).

In the ED, he had a mental illness evaluation. Computed tomography (CT) scan of the brain, chest X-ray, complete blood count (CBC), and complete metabolic count (CMP) were all normal. A urine drug screen was negative. No ethanol was detected. The patient was calm and oriented to person, place, and time. He denied psychosis or hallucinations. Because of persistent suicidal thoughts, he was admitted to inpatient psychiatric care.

On discharge, the patient was on mirtazapine, melatonin, and scheduled for weekly psychiatrist visits. During follow-up with his primary care physician, the patient continued to have a very distant, flat affect. The physical exam was otherwise unremarkable. Over the next few weeks, the patient declined further in surprising ways: dysphagia, drooling, mild tremors, and strange psychological regression (acting like a small child).

A second psychiatrist prescribed a different antidepressant. Symptoms worsened. A neurologist was consulted about possible concussion symptoms and a brain MRI was done. The MRI showed midbrain copper deposits, the so-called "panda face" which is classic for Wilson's disease (Figure 2). An ophthalmologist immediately diagnosed Kayser-Fleischer rings.

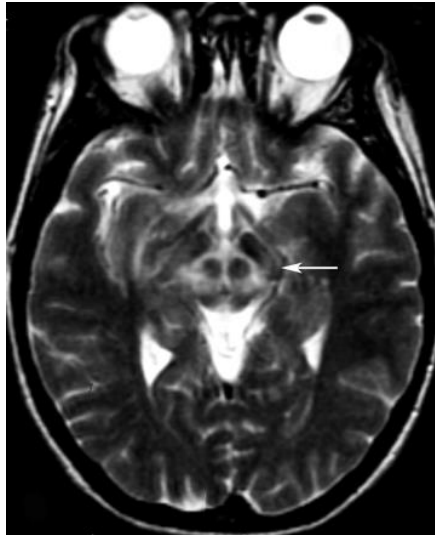

Figure 2: Panda face on MRI - classic for a patient with Wilson's disease and copper deposits in the brain (from Jacobs, 2003)

Ceruloplasmin level measured 7.9 mg/dL (normal: 20-35 mg/dL). A 24-hour urinalysis showed a copper level of 247  $\mu\text{g}$  (normal: 20-50  $\mu\text{g}$  per 24 hours), which completed the work-up. This teenager was officially diagnosed with Wilson's disease. Penicillamine, which works by chelation and increasing urinary copper excretion, was started.

Within a month, the patient had worsened to the point of uncontrolled drooling and inability to eat. He was transported to a higher care facility to participate in a clinical trial for WTX101, an experimental therapy. A gastric feeding tube was placed. Today, his neurologic symptoms continue to slowly improve. No hepatic symptoms from the disease have presented.

## Discussion

This patient's presentation is classic for the dramatic onset of neurologic Wilson's disease. He met all diagnostic criteria: Kayser-Fleischer rings, low plasma ceruloplasmin, and high cupuresis. Neurologic signs typically present between ages 17-21.<sup>3</sup> Psychological symptoms are present in 30-50% of neurologic Wilson's disease.<sup>3</sup> These symptoms (personality changes, irritability, and depression) are vague and sometimes misleading, often delaying diagnosis.<sup>3</sup>

Dysarthria is the most common symptom found in neurologic Wilson's disease – found in more than 85% of patients. A *risus sardonicus*, an uncontrollable and exaggerated smile, is common. Essential tremor of the upper extremities is the most common movement disorder.<sup>3</sup>

This patient is now in a clinical trial for WTX101, which works by directly removing copper from hepatocytes. It forms a tripartite bond with copper and albumin to initiate biliary excretion of copper.<sup>4</sup> A phase II clinical trial showed that 24 weeks of WTX101 therapy lowered non-ceruloplasmin bound copper and improved neurologic symptoms.<sup>4</sup> Our patient is currently enrolled in phase III of the clinical trial.

This case is noteworthy because of the rarity of Wilson's disease -- a prevalence of only 17 per 1 million people.<sup>3</sup> It is estimated that only 50% of patients with Wilson's disease are actually diagnosed and this is typically after twelve months of symptoms.<sup>1</sup>

Although rare, it is important to consider Wilson's disease for young patients with neurologic or psychiatric symptoms. This is because the prognosis is dependent on the prompt initiation of therapy. Some studies have shown complete resolution of brain lesions if therapy is started within twenty-four months of initial symptoms.<sup>5</sup>

If therapy is not started quickly, brain lesions can be permanent.<sup>5</sup> In one study, 37% of patients who started therapy within one month of symptom onset became completely free of neurologic symptoms.<sup>3</sup> Without medication, this disease is fatal. Patients with neurologic Wilson's disease have a mean survival time of five years if untreated, and those with liver failure have a 95% acute mortality risk.<sup>6,7</sup>

Early detection of Wilson's disease can drastically change the survival of patients. It is important to have family members screened. Some studies show that heterozygote carriers can be clinically differentiated from non-carriers by identifying prolonged biological copper metabolism, decreased biliary excretion of copper, renal abnormalities, and hypercupriuresis after penicillamine loading.<sup>1</sup>

## References

- Mason K. A conspectus of research on copper metabolism and requirements of man. *The Journal of Nutrition*. 1979;109(11):1979-2066.
- Huster D. Wilson disease. *Best practice & research clinical gastroenterology*. 2010;24(5):531-539.
- Lorincz M. Neurologic Wilson's disease. *The New York Academy of Sciences*. 2010;1184(1):173-187.
- Weiss K, Czlonkowska A, Hedera P, Ferenci P. WTX101 – an investigational drug for the treatment of Wilson disease. *Expert opinion on investigational drugs*. 2018;27(6):561-567.
- Huang CC, Chu NS. Wilson's disease: resolution of MRI lesions following long-term oral zinc therapy. *Acta Neurol Scand*. 1996;93(2-3):215-218.
- Dening TR, Berrios GE, Walsh JM. Wilson's disease and epilepsy. *Brain*. 1988;111(Pt 5):1139-1155.
- Hepato J. EASL Clinical Practice Guidelines: Wilson's disease. *European Association for Study of Liver*. 2012;56(3):671-685.
- Sullivan CA, Chopdar A, Shun-Shun GA. Dense Kayser-Fleischer ring in an asymptomatic Wilson's disease (hepatolenticular degeneration). *British Journal of Ophthalmology*. 2002;86(1):114.
- Jacobs DA, Markowitz CE, Liebeskind DS, Galetta SL. The "double panda sign" in Wilson's disease. *American Academy of Neurology*. 2003;61(7):969.