



## Advances in optical coherence tomography in dermatology - a review

Olsen, Jonas; Holmes, Jon; Jemec, Gregor B. E.

*Published in:*  
Journal of Biomedical Optics

*DOI:*  
[10.1117/1.JBO.23.4.040901](https://doi.org/10.1117/1.JBO.23.4.040901)

*Publication date:*  
2018

*Document version*  
Publisher's PDF, also known as Version of record

*Citation for published version (APA):*  
Olsen, J., Holmes, J., & Jemec, G. B. E. (2018). Advances in optical coherence tomography in dermatology - a review. *Journal of Biomedical Optics*, 23(4). <https://doi.org/10.1117/1.JBO.23.4.040901>

# Journal of Biomedical Optics

BiomedicalOptics.SPIEDigitalLibrary.org

## Advances in optical coherence tomography in dermatology—a review

Jonas Olsen  
Jon Holmes  
Gregor B. E. Jemec

**SPIE.**

Jonas Olsen, Jon Holmes, Gregor B. E. Jemec, "Advances in optical coherence tomography in dermatology—a review," *J. Biomed. Opt.* **23**(4), 040901 (2018), doi: 10.1117/1.JBO.23.4.040901.

# Advances in optical coherence tomography in dermatology—a review

Jonas Olsen,<sup>a,\*</sup> Jon Holmes,<sup>b</sup> and Gregor B. E. Jemec<sup>a</sup>

<sup>a</sup>University of Copenhagen, Zealand University Hospital, Department of Dermatology, Health Sciences Faculty, Roskilde, Denmark

<sup>b</sup>Michelson Diagnostics, Maidstone, United Kingdom

**Abstract.** Optical coherence tomography (OCT) was introduced as an imaging system, but like ultrasonography, other measures, such as blood perfusion and polarization of light, have enabled the technology to approach clinical utility. This review aims at providing an overview of the advances in clinical research based on the improving technical aspects. OCT provides cross-sectional and *en face* images down to skin depths of 0.4 to 2.00 mm with optical resolution of 3 to 15  $\mu\text{m}$ . Dynamic optical coherence tomography (D-OCT) enables the visualization of cutaneous microvasculature via detection of rapid changes in the interferometric signal of blood flow. Nonmelanoma skin cancer (NMSC) is the most comprehensively investigated topic, resulting in improved descriptions of morphological features and diagnostic criteria. A refined scoring system for diagnosing NMSC, taking findings from conventional and D-OCT into account, is warranted. OCT diagnosis of melanoma is hampered by the resolution and the optical properties of melanin. D-OCT may be of value in diseases characterized with dynamic changes in the vasculature of the skin and the addition of functional measures is strongly encouraged. In conclusion, OCT in dermatology is still an emerging technology that has great potential for improving further in the future. © 2018 Society of Photo-Optical Instrumentation Engineers (SPIE) [DOI: 10.1117/1.JBO.23.4.040901]

Keywords: optical coherence tomography; interferometry; medicine; dermatology; imaging.

Paper 170593VRR received Sep. 12, 2017; accepted for publication Mar. 26, 2018; published online Apr. 26, 2018.

## 1 Introduction

Imaging may seem superfluous in the skin as most of it is easily visible to the naked eye. Nevertheless, recording of images through technology may contribute significantly to our ability both to see the actual structures of the skin and visualize their functioning. Imaging therefore has a long tradition within dermatology, originating in drawings that convey the artist's impression of skin changes either clinically or as drawings of histopathology.

Simple imaging has traditionally been done using a magnifying lens, and more recently, the use of the dermoscope has penetrated into routine clinical work. This simple operator-dependent technique involves the use of a magnifying lens with a contact-pane obliterating surface reflections. It is particularly well suited for diagnosis of pigmented lesions and provides important morphological insights into a range of other skin pathologies.

More detailed imaging can, however, also be done *in vivo* using reflectance confocal microscopy (RCM), optical coherence tomography (OCT), and ultrasonography. These methods are at various stages of implementation into clinical routine. Additional methods, e.g., photoacoustic imaging, are available in an experimental setting.

It is customary for imaging methods to start off as pure imaging, but the competitive advantage of a traditional holistic clinical approach has meant that the penetration of new imaging methods into routine clinical assessment of the skin is still low. Simple clinical photography and dermoscopy show the highest penetration into clinical work, as these methods are entirely

operator dependent and only act as adjunct clinical examinations. By contrast, e.g., magnetic resonance imaging has become widely used, not least due to the method's possibility to furnish the clinicians with objective and functional data about the tissue under study. A similar evolution may be taking place in dermatology. The older imaging technology of high frequency ultrasound has gained considerable penetration into specialties, such as gynecology, in recent years. It may be speculated that this is due to the method's ability to provide functional data on the tissue. This is also possible in skin<sup>1</sup> and in spite of the limited resolution of the images provided, ultrasound is increasingly popular.

The use of OCT in skin appears to be following a similar path. It started out as a pure imaging system, providing clinicians with micrometer resolution images of skin. These images were more accurate than existing ultrasonography, and less so than, e.g., RCM. In spite of the fact that greater volumes of skin could be imaged than in RCM, the overall image quality of OCT did not compare favorably with that of RCM. Measures to weigh up for the small field-of-view in RCM have been made by enabling the acquisition of several scans in a larger field of up to 8 mm  $\times$  8 mm. On the other hand, the introduction of more functional measures, such as perfusion, in OCT means that the method is now approaching clinical utility much more rapidly. It is highly suited for this as the images clearly provide more detail than simple magnifying glasses while, at the same time, promising to show functional aspects of the skin.

## 2 Technology and Technological Advances

### 2.1 Summary of Optical Coherence Tomography

OCT is a technique for imaging turbid media, such as living tissue, and was applied to imaging skin in 1997 by Welzel et al.<sup>2</sup>

\*Address all correspondence to: Jonas Olsen, E-mail: [jonao@regionsjaelland.dk](mailto:jonao@regionsjaelland.dk)

As an imaging modality, it occupies a space between acoustic imaging and confocal microscopy in terms of its resolution and imaging depth, typically imaging to a depth of 0.4 to 2.00 mm with optical resolution of 3 to 15  $\mu\text{m}$ . OCT utilizes the property of coherence of laser light to detect scattered light from target tissue at depths, which are inaccessible to conventional microscopy. A focused laser beam is scanned across the sample, and backscattered light from the subsurface tissue is collected and made to interfere with a reference beam also derived from the laser. Only backscattered photons that have retained their coherence by not being multiply scattered within the tissue will constructively interfere and generate a large signal response at the detector. Furthermore, the interferometer provides the depth information at which these photons were backscattered, thus enabling a 2-D image of the scattering centers within the tissue to be constructed.

## 2.2 Optical Coherence Tomography Imaging of Skin

Skin, as a particularly easy organ to access, was one of the first parts of the body to be scanned with OCT. It was quickly discovered by early researchers that it was necessary to use the 1300-nm waveband in the water absorption spectral window to obtain satisfactory image depth penetration in skin. Normal skin comprises an epidermis of 50 to 100  $\mu\text{m}$  above a dermis of up to 2000  $\mu\text{m}$  or more thickness. For clinically useful OCT images, it is important for imaging to penetrate at least 500  $\mu\text{m}$  into the dermis and, unfortunately, the visible wavelengths commonly applied in ophthalmic imaging are scattered too highly by skin to achieve acceptable depth penetration. Other wavelengths have been studied, notably 1050 nm,<sup>3</sup> but all commercial skin imaging OCT devices use the 1300-nm waveband (see Fig. 1 for examples of OCT scans from currently available commercial devices).

## 2.3 Advances in Optical Coherence Tomography Technology

The driver for advances in OCT technology for imaging skin has been a clinical interest in imaging skin cancer, in particular, nonmelanoma skin cancer (NMSC). This disease manifests as the tumor “nests” initially in the upper 500  $\mu\text{m}$ , which grow and penetrate to 1000  $\mu\text{m}$  and deeper. There are numerous other features that can be mistaken for tumors in OCT images, such as hair follicles, cysts, and benign growths, and so, high image resolution to successfully distinguish between these over the full imaging depth of 1000  $\mu\text{m}$  is desired. Initial studies using time-domain OCT systems quickly established that probes providing lateral resolution of 15 to 25  $\mu\text{m}$  provided

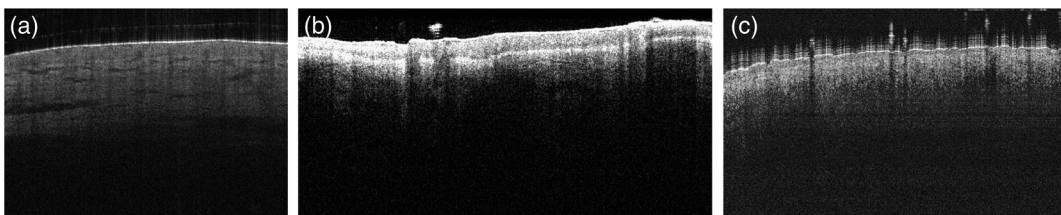
images of insufficient detail to achieve really useful sensitivity and specificity for NMSC diagnosis; for example, in 2007, Mogensen et al.<sup>4</sup> reported diagnostic sensitivity of 50% to 96% and specificity of 79% to 94% in a study of 100 patients. Nevertheless, these studies showed that clinically useful image features were being glimpsed and further improvements in resolution would likely yield useful results, encouraging further development of higher resolution probes with resolution  $<10 \mu\text{m}$ .

The early studies with utilizing time-domain OCT highlighted another challenge in terms of the scan rate. Skin lesions can be quite large—1 cm diameter is not uncommon—and early systems with an imaging time of 1 to 2 s per OCT image frame were too slow to be practical for routine clinical use.

The first commercially available device was the ISIS Optronics SkinDex, and this had a 2-s frame capture time for a 1-mm width image frame. The impressively high optical resolution of  $\sim 3 \mu\text{m}$  of this device was unfortunately compromised by the slow scan rate and unwieldy probe, and it was not clinically adopted.

However, the development of Fourier-domain OCT<sup>5</sup> coupled with rapid advances in computer processing power enabled real-time scan rates, and then by the addition of a second scan mirror, i.e., the rapid capture of three-dimensional datasets. In 2010, Michelson Diagnostics launched VivoSight, the first practical commercial dermatology OCT system that has been adopted into routine clinical practice. This device combined a swept-source Fourier-domain OCT engine with multibeam optical configuration, combining four OCT devices each focused at a different depth into one probe, to achieve lateral resolution of 7.5  $\mu\text{m}$  over a full desired focal depth of 1000  $\mu\text{m}$  and 3-D scanned area of 6 mm  $\times$  6 mm.<sup>6</sup> The fiber-based hand-held probe was small enough to easily manipulate and scan most parts of the face and body. These practical advances in image resolution, scan rate, and probe ergonomics encouraged clinical studies and then adoption into routine practice.<sup>7</sup> In 2014, the utility of the VivoSight probe was further improved with the addition of a color microcamera providing the user with the facility to see the lesion being scanned and the exact location of the scan plane on the lesion.

In 2010, Agfa launched the SkinTell<sup>®</sup> (Agfa, Mortsel, Belgium) dermatological OCT system with so-called high-definition OCT (HD-OCT). This device addressed the image resolution problem by using time-domain OCT engine with *en-face* OCT imaging mode, high NA objective lens, and tracking the focus during the scan. The resolution of 3  $\mu\text{m}$  of HD-OCT was higher than VivoSight but at the expense of a less ergonomic probe, lower scan area of 1.8 mm  $\times$  1.5 mm, and image penetration of 570  $\mu\text{m}$ . Clinical studies with this device showed



**Fig. 1** Examples of normal skin from three different OCT devices. (a) Vivosight<sup>®</sup> (Michelson Diagnostics Ltd., Maidstone, United Kingdom), (b) Callisto<sup>®</sup> (Thorlabs AG, Lubeck, Germany), and (c) NITID<sup>®</sup> (DermaLumics, Madrid, Spain).

promising results,<sup>8</sup> but the device was withdrawn from the market by the manufacturer at the end of 2015.

More recently, in 2015, Dermalumics launched the NITID OCT device. This very compact and highly portable dermatological OCT system has a probe equipped with dermatoscope and clinical camera so that all three imaging modalities are available to the clinical user. Its image resolution is  $12\ \mu\text{m}$ <sup>9</sup> and, currently, clinical studies using the device are lacking.

#### 2.4 Advances in Optical Coherence Tomography Modalities

Besides the key advances in image resolution, scan rate, depth penetration, and probe ergonomics, advances have also been made in the functional OCT imaging of skin. These include polarization-sensitive OCT and angiographic or “dynamic OCT (D-OCT).”

An important constituent of skin tissue is collagen, which is highly birefringent. The collagen fibers themselves are very small and difficult to resolve optically unless very high NA optics is used. Polarization-sensitive OCT has been studied for possible use in managing burns,<sup>10</sup> because heat denatures the collagen and destroys its birefringence. A difficulty is that the images are quite difficult to interpret visually, and the higher cost of polarization-maintaining optical components is also problematic preventing the development of a practical PS-OCT device.

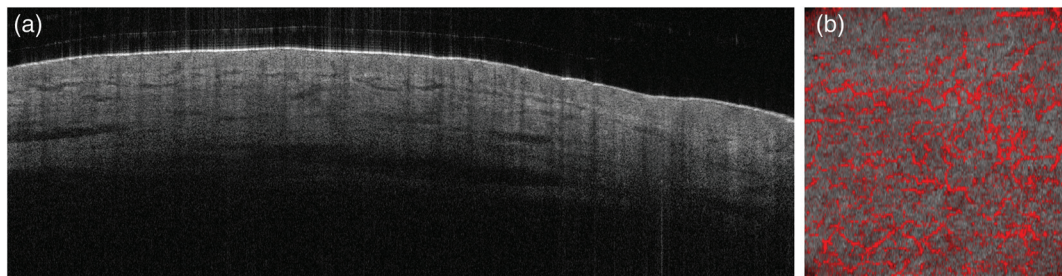
Early developments of OCT included studies of Doppler OCT to detect blood flow.<sup>11</sup> The limited sensitivity of these

devices stifled application in dermatology, but since 2015, there has been great interest in angiographic OCT based on so-called speckle-variance techniques pioneered by Mariampillai et al.<sup>12</sup> Speckle variance and its close cousins decorrelation mapping<sup>13</sup> and OMAG<sup>14</sup> work on the principle of detecting rapid changes in OCT signal intensity that are produced by the effects of blood flow producing changes to the OCT interferometric signal; by mapping the image pixels where these rapid changes are detected, blood vessels in the upper dermis can be readily imaged and are best visualized in the *en-face* imaging plane (see Figs. 2–5).

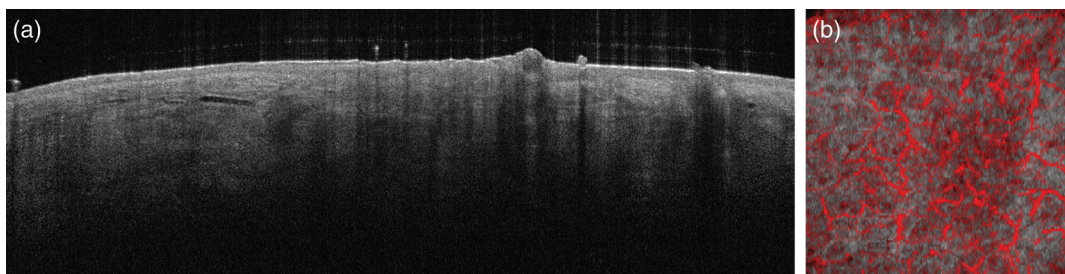
D-OCT has already been studied for potential applications in skin cancer diagnosis, scleroderma, psoriasis, wound healing, and many other areas, and it shows promise for the future.

### 3 Applications in Dermatology

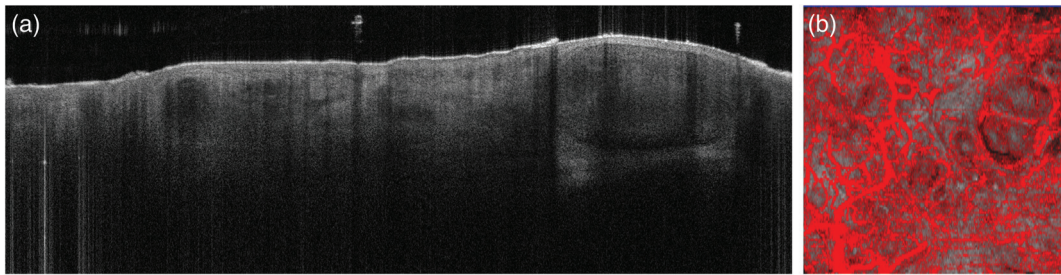
The clinical applicability of OCT is high in ophthalmology, where OCT is routinely used and considered a key tool in diagnosing various diseases of the retina.<sup>15</sup> In dermatology, OCT studies on various skin diseases have been conducted, though the technology has yet to be implemented as a standard procedure in clinical practice. In this section, we focus on comparing studies conducted from 2015 to 2017 with former studies to bring forth an overview of the advances in clinical research. One obvious limitation for imaging depth in OCT and other laser-based imaging technologies is the optical properties of chromophores in human tissue. Molecules, such as melanin and water,



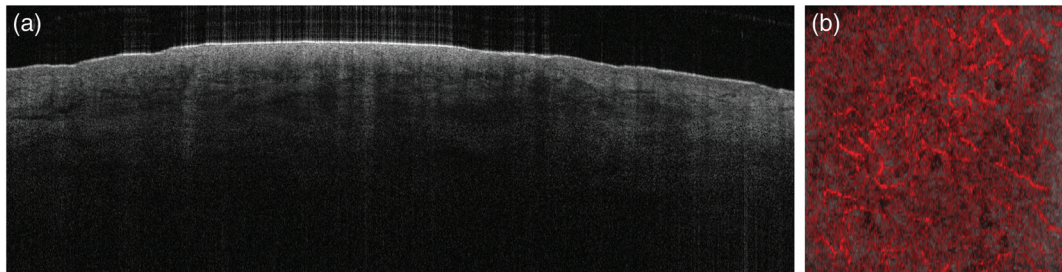
**Fig. 2** Healthy skin of the back of the hand from a 59-year-old man. (a)  $6 \times 2$  mm cross-sectional OCT-scan showing a narrow bright band, i.e., the entry signal, a homogenous narrow epidermis, an intact DEJ and a brighter and more heterogeneous dermis. (b)  $6 \times 6$  mm *en face* D-OCT image at  $300\ \mu\text{m}$  showing a high degree of dots and small caliber serpiginous vessels in a mottle-pattern and regular distribution. The research project for which the OCT images were initially acquired was approved by the local ethics committee, project id: SJ-509.



**Fig. 3** AK in the right temporal of a 68-year-old woman. (a)  $6 \times 2$  mm cross-sectional OCT-scan showing thickening of the epidermis with a disrupted DEJ and a poor penetration depth beneath. (b)  $6 \times 6$  mm *en face* D-OCT image at  $300\ \mu\text{m}$  showing a moderate degree of curves and serpiginous vessels with alternating calibers and branching pattern in an irregular distribution.



**Fig. 4** BCC from the right temple of an 84-year-old woman. (a)  $6 \times 2$  mm cross-sectional OCT-scan showing thickening of the epidermis with ovoid structures with dark palisading border underneath protruding into the dermis and with a disruption of the DEJ. (b)  $6 \times 6$  mm *en face* D-OCT image at  $300 \mu\text{m}$  showing serpiginous, curved and dilated telangiectasias and vessels in an arborizing pattern.



**Fig. 5** Malignant melanoma on the left forearm of a 48-year-old woman. (a)  $6 \times 2$  mm cross-sectional OCT-scan showing thickening and increased signal intensity in the epidermis, disruption of the DEJ and a steep fall in signal intensity in the dermis. (b)  $6 \times 6$  mm *en face* D-OCT image at  $300 \mu\text{m}$  showing a high degree of curves and dots and a moderate degree of lines in a mottled pattern with an irregular distribution.

have an effect on the OCT-image quality due to the absorption of light at wavelengths used in OCT, increasing the amount of light absorption and scattering and therefore reducing the imaging depth in tissue rich on said molecules.<sup>16</sup>

### 3.1 Skin Cancer

#### 3.1.1 Nonmelanoma skin cancer

As a disease originating from the epidermis and the most prevalent type of skin cancer,<sup>17</sup> NMSC is the most studied field of research in OCT.<sup>18–40</sup> In recent years, studies on NMSC have focused on diagnostic accuracy;<sup>41–43</sup> scoring systems or algorithms for diagnosing and differentiating basal cell carcinoma (BCC) and actinic keratosis (AK);<sup>44–48</sup> treatment monitoring<sup>49–51</sup> and D-OCT morphology of NMSC.<sup>52,53</sup> Earlier studies on NMSC have also been aimed at determining diagnostic accuracy<sup>38</sup> and applied OCT as a treatment monitoring tool,<sup>18,21,22,37,40</sup> though D-OCT had yet to be introduced.

Validation of any emerging imaging technique is the correlation with existing methods and since the first pilot study in 2004, a series of studies have shown good morphological correlation between OCT and histology in BCC.<sup>23,26,29–32</sup> The most distinct features in B-scans were used in creating the Berlin score in an attempt to set a range of objective criteria and to quantify the diagnostic accuracy using these criteria<sup>48</sup> (see section below regarding diagnostic algorithms). Tumor thickness in BCC is another interesting feature, which has been studied with OCT and correlated with histology. Studies have shown that OCT has a good correlation with histology in determining

epidermal thickness (ET).<sup>36</sup> The method is superior to high frequency ultrasonography, showing better agreement with histology, though both methods overestimated thickness.<sup>35</sup> Another study found a median insignificant difference of 0.12 mm between histology and OCT compared to a significant median difference of 0.3 mm between histology and ultrasonography.<sup>34</sup> AK has not been studied as comprehensively, leaving only a single pilot study comparing OCT and histology, also showing a good correlation.<sup>20</sup>

The diagnostic accuracy in NMSC has been studied on cross-sectional OCT images only, without any clinical information. An overall sensitivity of 76% and 90% and specificity of 68% and 90% for AK and BCC, respectively, among observers experienced in OCT image interpretation was found.<sup>41</sup> A former study on observer blinded diagnostic accuracy in distinguishing NMSC and malignant melanoma from healthy skin has shown a sensitivity and specificity of 79% to 94% and 85% to 96%, respectively, whereas the error rate in discriminating between AK and BCC was only 50% to 52%.<sup>38</sup> In newer studies of OCT as a supplement to clinical assessment of BCC, one study has shown OCT to improve the sensitivity in diagnosing BCC from 90% to 95.7% and specificity from 28.6% to 75.3%, the latter showing statistical significance ( $p < 0.001$ )<sup>42</sup> while another study has shown a significant improvement in both sensitivity and specificity ( $p < 0.01$ ) from 63% to 93% and 49% to 80%, respectively, when applying OCT as a supplement to clinical diagnostics.<sup>43</sup> Polarization-sensitive OCT (PS-OCT) has been used in a pilot study for identifying tumor margins in aggressive BCC, showing a loss of birefringence in tumor islands and a shift to a more uniform birefringence in unaffected

skin. This method was, however, unable to identify the deeper tumor margins.<sup>33</sup> A recent study from 2016 investigated the automated detection of BCC with PS-OCT in *ex vivo* human skin using machine learning algorithms. They achieved 95.4% sensitivity and specificity.<sup>54</sup> A former murine study with similar methods shows the usability of PS-OCT in automated tumor detection. They found a sensitivity and specificity of 94.4% and 92.5%, respectively, when taking both signal intensity and birefringence into account compared to 78.2% and 82.2% when only looking at intensity and 85.5% and 87.9% with birefringence alone.<sup>24</sup>

The use of OCT in presurgical tumor margin assessment of NMSC has been tested in a practical approach, conducting the scans perpendicular to the clinically assessed tumor margins. The OCT-defined margins always fell within the clinically assessed borders and correctly indicated complete removal of tumor tissue in 84% of cases. Lateral margin definition before Mohs micrographic surgery of BCC has been investigated in a recent study from 2018, showing a reduction in the number of surgical stages during Mohs surgery. The method enabled the complete removal of tumor tissue in a single stage in 8/10 cases, and tumor margins were enlarged after OCT in 4/10 cases.<sup>55</sup>

Diagnostic algorithms for BCC and AK have been suggested and validated in recent years. For BCC, the Berlin score has been developed using an expert panel and afterward applied for these criteria: dark border underneath tumor, hyporeflexive nests, ovoid structures, disruption of the dermoepidermal junction (DEJ) and cysts, resulting in a sensitivity and specificity among experts 96.6% and 75.2%, respectively.<sup>48</sup> Another algorithm for discriminating BCC subtypes and imitators using HD-OCT has developed, suggesting the presence of lobular structure as a hallmark for BCC and other features, such as connection to hair follicles and nests in the epidermis, may imply BCC imitators while the subtyping of BCC is based on vascular patterns.<sup>45</sup> An algorithm for differentiating AK, squamous cell carcinoma (SCC), and normal skin using HD-OCT has also been developed and validated, suggesting the presence of an outlined DEJ in cross-sections to be the main discriminator between SCC and AK or normal skin and the presence of an atypical honey comb pattern (*en face*) and alternating hyperkeratosis/parakeratosis (cross-section) to be an identifier for AK in discriminating it from normal skin.<sup>44,47</sup> The validation of this algorithm resulted in a sensitivity of 81.6% and 93.8% and specificity of 92.6% and 98.9% in diagnosing AK and SCC, respectively, among experienced observers.<sup>47</sup>

Changes in quantitative measures such as attenuation and signal intensity in NMSC have been investigated in few studies. A study on the signal intensity and attenuation of BCC has shown significant differences in signal density and attenuation between BCC and healthy skin,<sup>56</sup> whereas another study found that distinction between AK and BCC can be made on a drop in signal intensity in the dermis and a thicker epidermis for AK.<sup>57</sup> A study in HD-OCT demonstrated that subdifferentiation of BCC can be made with a higher accuracy when applying optical properties compared to morphology analysis alone.<sup>58</sup>

The monitoring of therapeutic response to treatment is another field of OCT research that has developed recently. A higher accuracy of identifying residual BCC lesions and confirmation of complete response after photodynamic therapy compared to clinical evaluation has been shown in Ref. 51.

This correlates well with former studies performed suggesting that OCT is able to identify residual lesions after treatment with a higher precision than clinical examination alone.<sup>18,59</sup> A study on the effect of systemic hedgehog inhibitors on BCC monitored with RCM and HD-OCT has revealed that pseudocysts may be a marker of tumor regression, though the small sample size of five patients suggests the study and the phenomenon comprehensively.<sup>37</sup>

D-OCT enables the study of *in vivo* blood flow and has been clinically validated against other vascular imaging techniques and is able to image and identify physiological changes in the blood flow of the skin<sup>60</sup> as well as morphological changes in vessel morphology.<sup>61</sup> The microvascular structural morphology of AK, Bowen's disease, and SCC was studied with D-OCT applying an observer blinded analysis. Several morphological characteristics of blood vessels have been identified and the presence of "blobs" at 300  $\mu\text{m}$  was characteristic in Bowen's disease and "curves" were present in AK lesions, though no significant difference was found in quantitative measures between precancer and cancer lesions.<sup>52</sup> Examples of D-OCT images of NMSC and the nomenclature for describing the vessels in the horizontal *en face* images and morphology of the cross-sectional images are shown in Figs. 2–5. The depth of blood vessels in various types of NMSC was studied, showing significantly more superficial vessels in AK, BCC, and SCC, respectively, compared to healthy skin but also in BCC compared to AK and SCC.<sup>53</sup>

As a natural field of interest, the first pilot study on OCT of melanocytic lesions was published in 2005. There was a low degree of correlation between OCT and histological features, and it was not possible to visualize individual cells. It was concluded that the technology was still far from the possibility of being brought into practical use in the dermatological oncology sector.<sup>62</sup> The distinction between malignant melanoma and melanocytic naevi is of the highest relevance in the field of dermatology, and though OCT may be somewhat limited in diagnosing pigmented lesions due to light scattering and absorption of the melanin<sup>16</sup> and less resolution than RCM, the technology may have its uses in tumor thickness estimation. Like in BCC, a study has shown that OCT has a higher degree of agreement with histology in determining tumor thickness in melanocytic lesions.<sup>63</sup> On the other hand, the wavelength of the OCT-device influences the penetration depth, and studies have shown that high frequency ultrasound is superior to OCT-scans at 930 nm in determining tumor thickness.<sup>64</sup> A recent study has shown OCT at 1300 nm to be slightly more accurate in assessing tumor thickness, though both technologies tend to overestimate thin tumors (<0.2 mm) and underestimate thick tumors (>0.7 mm) compared to histology.<sup>65</sup> In a descriptive study using HD-OCT in pigmented lesions, melanomas have, compared to benign lesions, a higher frequency of fusion of rete ridge, pagetoid cells, and junctional and/or dermal nests with atypical cells. HD-OCT is suggested to have a higher diagnostic value in pigmented lesions compared to conventional OCT while being inferior to RCM.<sup>66</sup> Older studies suggest a higher degree of architectural disarray and fused and elongated rete ridges and to be a marker of malignancy in pigmented lesions,<sup>67</sup> and HD-OCT is able to visualize similar features as RCM with a good correlation with histological findings.<sup>68</sup> A multicenter study of HD-OCT in the differentiation of cutaneous melanoma and melanocytic naevi with 66 naevi and 27 melanoma patients has demonstrated a sensitivity of 74.1%, specificity

of 92.4%, positive predictive value of 80%, and negative predictive value of 89.7% in diagnosing melanoma.<sup>69</sup> Another HD-OCT-study of pigmented lesions has suggested the possibility to raise sensitivity and specificity to 93.3% and 93.7%, respectively, while taking optical properties such as attenuation into account.<sup>70</sup>

## 3.2 Other Applications

### 3.2.1 Inflammatory diseases

The introduction of D-OCT to dermatological research has meant an obvious improvement compared to earlier studies in the ability to evaluate the microvascular morphology of inflammatory skin. The earliest OCT study on inflammatory skin diseases is a descriptive study of dermatitis and psoriasis from 2003. The study describes a thickening of the epidermis in psoriasis and irritant dermatitis, and the light scattering ability of the dermis was lower than regular skin due to less tightly packed collagen fibers in the edematous and inflamed dermis.<sup>71</sup> In recent years, a range of inflammatory skin disorders, including acne, dermatitis, and nail psoriasis, has been studied with OCT.<sup>72–74</sup> D-OCT of acne vulgaris has revealed characteristic morphological features including interrupted entrance signal, increased ET, vertical hypodense structures, and granular hyper echogenic material inside comedos. The vascular characteristics include focal absence of vascular signals, hypervascular spikes, and increased vascular networks. The study has also shown a correlation between oral antibiotic treatment and normalization of the above mentioned features.<sup>72</sup> Differentiation of allergic and irritant dermatitis in patch test scoring has been assessed with HD-OCT and a good correlation between certain features in HD-OCT and clinical severity scores was shown, though no significant improvement over visual patch test scoring could be demonstrated.<sup>73</sup> Allergic patch test scoring was also evaluated with OCT in a pilot study from 2005, showing clearly demarcated signal-free cavities within the epidermis. This finding correlated well with the grading of the clinical patch test scoring.<sup>75</sup> OCT has also been applied as an assessment tool of outcomes in clinical trials for dermatitis and psoriasis. The atrophogenic potential of hydrocortisone 1% and pimecrolimus in the skin of patients with atopic dermatitis was investigated in which dermal thickness and ET were evaluated using OCT. It was demonstrated that hydrocortisone but not pimecrolimus induced a significant decrease in ET, which normalized 4 weeks past ended treatment.<sup>76</sup> Almost the same study design was applied in a study of plaque psoriasis comparing tacrolimus and methylprednisolone aceponate ointment, in which OCT and ultrasonography were applied for confirming the clinically scored outcomes.<sup>77</sup> The disease severity in psoriasis has been evaluated with histology and psoriasis area and severity index (PASI) score and ET being evaluated by OCT. The ET showed a good correlation with histology rated disease severity but not with the PASI score.<sup>78</sup> A study of nail psoriasis has shown a significantly increased blood flow and greater nail thickness in the proximal nail fold, and morphological features of psoriatic nail blood vessels differed from controls with dilated and disorganized blood vessels in the superficial proximal nail fold.<sup>74</sup> A systematic approach in studying inflammatory skin diseases with OCT has been suggested prior to the introduction of D-OCT by Boone et al.<sup>79</sup> for HD-OCT, suggesting a terminology resembling that of RCM.

### 3.2.2 Physiological studies

OCT has been applied as an assistance for planning and controlling various treatments, such as follicular unit extraction, laser-assisted drug delivery through nails and skin, and for semiautomated localization of the DEJ.<sup>80–86</sup> OCT is able to visualize the nail plate, nail bed, and nail matrix,<sup>87</sup> and the method has been used for assessing effectiveness of transnail drug delivery using ablative fractional laser with OCT, suggesting the technology to be an effective tool for monitoring both depth of laser penetration and drug delivery efficacy in nails.<sup>80,81</sup> Measurement of nail thickness with OCT has been applied, showing lower degrees of variation compared to ultrasonography,<sup>87</sup> though lacking the ability to visualize single cellular structures compared to confocal laser scanning microscopy.<sup>88</sup> A “demonstration of principle” study to assist the planning of follicular unit extraction with OCT has been made in order to easily evaluate the angles of hair follicles during hair transplants. This evaluation was performed in order to minimize hair follicle transection and the authors suggest that the principle may be applied for automated follicle unit extraction devices.<sup>83</sup> The epidermis is the easiest part of the skin to visualize with OCT and several studies on the ET were conducted.<sup>89–95</sup> Different methods for measuring ET with OCT were tested using A-scan based analysis, shapelet-based analysis, and manual observer-based analysis, the latter two being most precise.<sup>93</sup> A-scan analysis with histological comparison has revealed no correlation between methods, suggesting the method to be unviable in determining ET.<sup>89,91</sup> Even though a recent study on a software-based semiautomated method for assessing the ET using A-scan data has shown a strong correlation with histology and manual assessment, a poor numerical agreement was found. This suggests that different methods may not be used interchangeably.<sup>95</sup> Manual measurement of ET on B-scans OCT has been shown to be reproducible with a low degree of variation and has been used in determining variations due to age and gender, skin type, and anatomical location.<sup>90,92</sup> Atrophic thinning of the epidermis is a common side effect of glucocorticosteroids, and OCT has been used for the evaluation of ET in a double-blind placebo controlled trial on healthy volunteers, showing OCT to be superior to ultrasound in detecting early signs of epidermal thinning.<sup>96</sup> Hair straws are known to cause artifacts in OCT scans due to their light scattering ability, and this can be exploited in examining hair thickness with B-scans, providing highly reproducible *in vivo* measurements of hair shaft thickness, whereas other methods are more time-consuming and requiring removal of hairs.<sup>97</sup> When evaluating hair removal, OCT is able to provide cross-sectional views of the hair shaft and follicle, whereas other methods only provide images *en face*.<sup>98</sup>

### 3.2.3 Other diseases

OCT has been used in the investigation of various diseases of interest in dermatology. Vascular diseases of the skin have been investigated prior to the introduction of D-OCT. Blood vessels were identified as hyporeflexive structures in the reticular dermis of hemangiomas, hemolymphangiomas, and telangiectasia, showing good correlation with histology.<sup>99,100</sup>

Burns and scars after burns were studied with OCT. The assessment of vasculature is an important aspect of monitoring healing of burn injuries, and with the introduction of D-OCT, it is possible to track the vascular progression during wound



healing.<sup>101</sup> The treatment planning of laser therapy to burn scars is normally based on the physician's estimate on thickness of the scar tissue, and therefore, OCT has been employed for setting a more standardized and precise estimate of the scar thickness, revealing physicians to underestimate the scar thickness in the dermis.<sup>102</sup> Deep and superficial burns have been compared with PS-OCT, in which both vasculature and connective tissue birefringence of the reticular dermis were diminished in the deep burns.<sup>10</sup> Blood vessels in hypertrophic burn scar tissue have a higher density compared to normal skin with proliferation of larger vessels compared to both normal skin and regular scar tissue, which found in an OCT study using speckle decorrelation to delineate blood vessels.<sup>103</sup>

The bullous diseases: pemphigus, bullous pemphigoid, burn blisters, subcorneal pustular dermatosis, Darier's disease, staphylococcal scalded skin syndrome (SSSS), and toxic epidermal necrolysis (TEN) have been studied while depicting bullae as dark ovoid well-demarcated structures in the epidermis.<sup>104,105</sup> OCT is able to differentiate bullous pemphigoid from burn blisters and pemphigus due to the different levels of epidermal splitting but lacks the ability to assess tissue damage in the dermis in burns.<sup>105</sup> The same phenomenon can be observed in differentiating SSSS and TEN, where a SSSS demonstrates a split higher in the epidermis, and TEN shows a split at the DEJ.<sup>104</sup> Parasitic infestations of the skin with scabies mites and larva migrans and the naturally occurring demodex mites have been demonstrated with OCT.<sup>106–108</sup> Both larva migrans and scabies mites created subcorneal burrows, though only the scabies mite was visualized with OCT.<sup>106,107</sup> Demodex mites are situated corresponding to hair follicles and their degree of presence can be demonstrated with HD-OCT enabling treatment monitoring in demodex-related diseases.<sup>108</sup> As mentioned earlier, the nail plate, nail fold, and nail matrix are visualizable with OCT, and various nail involving diseases have been investigated with OCT.<sup>109–111</sup> Onychomycosis can be seen as highly scattering elongated structures in the nail plate,<sup>110</sup> though showing a high rate of false positives compared to polymerase chain reaction, fungal cultures, and confocal scanning laser microscopy.<sup>109</sup> Psoriasis nail involvement can be visualized with OCT as light narrow bands with shadowing underneath. The overall agreement between clinical assessment and OCT by the authors suggests OCT being useable in objectively assessing treatment response.<sup>111</sup>

## 4 Discussion

The development of OCT in dermatology has been going on for 30 years, and during this time, several aspects of the technology have been improved substantially. The diagnostic accuracy, especially regarding NMSC, has reached a point in which diagnostic biopsies may be avoided in one out of three cases of BCC,<sup>43</sup> and the sensitivity has improved from 42% to 90% in differentiating AK from BCC for skilled observers,<sup>38,41</sup> which may be due to increased image quality as well as improved understanding of key diagnostic features of BCC.<sup>48</sup> The "Berlin score" for BCC showed a good diagnostic accuracy with a sensitivity of 96.6% and specificity of 75.2% when used by an expert group. Since this study was conducted, vascular features in differentiating different types of NMSC with D-OCT have been suggested,<sup>52</sup> possibly enabling a refinement of a score for diagnosing NMSC in future studies. Even though great advances in terms of diagnostic accuracy and planning and monitoring of various treatments are being made, the technology

remains more experimental and lacks some obvious key features associated with other technologies, such as reflectance confocal microscopy in the diagnosis of melanoma.<sup>112</sup>

D-OCT adds functional aspects to OCT by allowing *in vivo* assessment of microvasculature and may have applications beyond improving diagnostic accuracy in NMSC. As a part of the acute inflammatory response, the increase in blood flow in the most superficial vessels of the skin may be assessed and quantified using D-OCT,<sup>61</sup> which has already been applied for assessing treatment response in clinical trials,<sup>49–51</sup> and D-OCT may prove to be a further useful monitoring tool in clinical trials studying inflammatory and neoplastic diseases of the skin, though a problem may arise in case of edema of the epidermis due to water's ability to absorb and scatter infrared light.<sup>16</sup> The possible addition of new functional measures of tissue composition or metabolism is to be strongly encouraged in order to harvest the full potential of this interesting technique in dermatology. Even though the information gathered from the scanned tissue has increased with the introduction of D-OCT, other methods for gathering supplementary data have been reduced. PS-OCT has been studied on a broad scale, adding information about the connective tissue birefringence, though most studies have been published more than 5 years ago.<sup>10,33,38,87,92</sup> Though recent studies on automated identification and classification of BCC using a noncommercial PS-OCT setup have been conducted,<sup>24,54</sup> suggesting that the down prioritizing of PS-OCT in commercial devices may affect the amount of research being conducted.

In conclusion, OCT in dermatology currently remains an emerging technology for which the potential has yet to be described fully. With the advancement in processing speed of computers, the decline in laser prices and the increased demand for quick, precise, and noninvasive diagnostic tests, the technology has a great potential for improving its obvious utility further in the future.

## Disclosures

J.O. received a PhD grant from the LEO foundation. J.H. is an employee and shareholder of Michelson Diagnostics, a developer and manufacturer of OCT devices for dermatology applications. G.B.E.J. honoraria from AbbVie, Inflarx, Leo pharma, Pierre-Fabre, Novartis and UCB for participation on advisory boards. Grants from Abbvie, Novartis, Regeneron, Leo Pharma, Sanofi and UCB for participation as an investigator. Research grants from Abbvie, Leo Pharma, and Novartis.

## Acknowledgments

We would like to thank Dr. Sandra Schuh and Prof. Julia Welzel (Klinikum Augsburg, Germany) for providing OCT images from Callisto<sup>®</sup> and NITID<sup>®</sup>.

## References

1. X. C. Wortsman et al., "Real-time spatial compound ultrasound imaging of skin," *Skin Res. Technol.* **10**(1), 23–31 (2004).
2. J. Welzel et al., "Optical coherence tomography of the human skin," *J. Am. Acad. Dermatol.* **37**(6), 958–963 (1997).
3. A. Alex et al., "Multispectral *in vivo* three-dimensional optical coherence tomography of human skin," *J. Biomed. Opt.* **15**(2), 026025 (2010).
4. M. Mogensen et al., "Diagnostic potential of optical coherence tomography in non-melanoma skin cancer—a clinical study," in *European Conf. on Biomedical Optics*, Optical Society of America (2007).
5. A. F. Fercher et al., "Measurement of optical distances by optical spectrum modulation," *Proc. SPIE* **2083**, 263–267 (1994).

6. J. Holmes et al., "Multi-channel Fourier domain OCT system with superior lateral resolution for biomedical applications," *Proc. SPIE* **6847**, 68470O (2008).
7. L. Schmitz et al., "Optical coherence tomography: its role in daily dermatological practice," *J. Dtsch. Dermatol. Ges.* **11**(6), 499–507 (2013).
8. G. T. Li et al., "High-definition optical coherence tomography in the diagnosis of basal cell carcinoma evaluated by an experienced versus inexperienced investigator," *J. Clin. Exp. Dermatol.* **5**(4), (2014).
9. L. G. Gomez et al., "Optical coherence tomography: applications in dermatology," *Dermalumics* (2015), <http://www.dermalumics.com/wp-content/uploads/2015/09/Poster-reuni%C3%B3n-nacional.pdf>
10. K. H. Kim et al., "In vivo imaging of human burn injuries with polarization-sensitive optical coherence tomography," *J. Biomed. Opt.* **17**(6), 066012 (2012).
11. Z. Ding et al., "Real-time phase-resolved optical coherence tomography and optical Doppler tomography," *Opt. Express* **10**(5), 236–245 (2002).
12. A. Mariampillai et al., "Speckle variance detection of microvasculature using swept-source optical coherence tomography," *Opt. Lett.* **33**(13), 1530–1532 (2008).
13. E. Jonathan, J. Enfield, and M. J. Leahy, "Correlation mapping method for generating microcirculation morphology from optical coherence tomography (OCT) intensity images," *J. Biophotonics* **4**(9), 583–587 (2011).
14. R. K. Wang, "Optical microangiography: a label-free 3-D imaging technology to visualize and quantify blood circulations within tissue beds in vivo," *IEEE J. Sel. Top. Quantum Electron.* **16**(3), 545–554 (2010).
15. A. H. Kashani et al., "Optical coherence tomography angiography: a comprehensive review of current methods and clinical applications," *Prog. Retin. Eye Res.* **60**, 66–100 (2017).
16. S. L. Jacques, "Optical properties of biological tissues: a review," *Phys. Med. Biol.* **58**(11), R37–R61 (2013).
17. A. Lomas, J. Leonardi-Bee, and F. Bath-Hextall, "A systematic review of worldwide incidence of nonmelanoma skin cancer," *Br. J. Dermatol.* **166**(5), 1069–1080 (2012).
18. L. Themstrup et al., "Optical coherence tomography imaging of non-melanoma skin cancer undergoing photodynamic therapy reveals subclinical residual lesions," *Photodiagn. Photodyn. Ther.* **11**(1), 7–12 (2014).
19. T. Maier et al., "Actinic keratosis in the en-face and slice imaging mode of high-definition optical coherence tomography and comparison with histology," *Br. J. Dermatol.* **168**(1), 120–128 (2013).
20. M. A. Boone et al., "Imaging actinic keratosis by high-definition optical coherence tomography. Histomorphologic correlation: a pilot study," *Exp. Dermatol.* **22**(2), 93–97 (2013).
21. L. Themstrup et al., "Cryosurgery treatment of actinic keratoses monitored by optical coherence tomography: a pilot study," *Dermatology* **225**(3), 242–247 (2012).
22. N. Scola et al., "A randomized, half-side comparative study of aminolaevulinate photodynamic therapy vs. CO(2) laser ablation in immunocompetent patients with multiple actinic keratoses," *Br. J. Dermatol.* **167**(6), 1366–1373 (2012).
23. F. G. Bechara et al., "Histomorphologic correlation with routine histology and optical coherence tomography," *Skin Res. Technol.* **10**(3), 169–173 (2004).
24. L. Duan et al., "Automated identification of basal cell carcinoma by polarization-sensitive optical coherence tomography," *Biomed. Opt. Express* **5**(10), 3717–3729 (2014).
25. D. Cunha et al., "Comparison of ex vivo optical coherence tomography with conventional frozen-section histology for visualizing basal cell carcinoma during Mohs micrographic surgery," *Br. J. Dermatol.* **165**(3), 576–580 (2011).
26. T. Gambichler et al., "Histopathological correlates of basal cell carcinoma in the slice and en face imaging modes of high-definition optical coherence tomography," *Br. J. Dermatol.* **170**(6), 1358–1361 (2014).
27. T. Maier et al., "Ex vivo high-definition optical coherence tomography of basal cell carcinoma compared to frozen-section histology in micrographic surgery: a pilot study," *J. Eur. Acad. Dermatol. Venereol.* **28**(1), 80–85 (2014).
28. T. Maier et al., "Morphology of basal cell carcinoma in high definition optical coherence tomography: en-face and slice imaging mode, and comparison with histology," *J. Eur. Acad. Dermatol. Venereol.* **27**(1), e97–e104 (2013).
29. M. Mogensen et al., "How histological features of basal cell carcinomas influence image quality in optical coherence tomography," *J. Biophotonics* **4**(7–8), 544–551 (2011).
30. M. A. Boone et al., "Imaging of basal cell carcinoma by high-definition optical coherence tomography: histomorphological correlation: a pilot study," *Br. J. Dermatol.* **167**(4), 856–864 (2012).
31. T. Gambichler et al., "In vivo optical coherence tomography of basal cell carcinoma," *J. Dermatol. Sci.* **45**(3), 167–173 (2007).
32. J. M. Olmedo et al., "Optical coherence tomography for the characterization of basal cell carcinoma in vivo: a pilot study," *J. Am. Acad. Dermatol.* **55**(3), 408–412 (2006).
33. J. Strasswimmer et al., "Polarization-sensitive optical coherence tomography of invasive basal cell carcinoma," *J. Biomed. Opt.* **9**(2), 292–298 (2004).
34. T. Hinz et al., "Preoperative characterization of basal cell carcinoma comparing tumour thickness measurement by optical coherence tomography, 20-MHz ultrasound and histopathology," *Acta Derm.-Venereol.* **92**(2), 132–137 (2012).
35. M. Mogensen et al., "In vivo thickness measurement of basal cell carcinoma and actinic keratosis with optical coherence tomography and 20-MHz ultrasound," *Br. J. Dermatol.* **160**(5), 1026–1033 (2009).
36. J. M. Olmedo et al., "Correlation of thickness of basal cell carcinoma by optical coherence tomography in vivo and routine histologic findings: a pilot study," *Dermatol. Surg.* **33**(4), 421–426; discussion 5–6 (2007).
37. T. Maier et al., "Noninvasive monitoring of basal cell carcinomas treated with systemic hedgehog inhibitors: pseudocysts as a sign of tumor regression," *J. Am. Acad. Dermatol.* **71**(4), 725–730 (2014).
38. M. Mogensen et al., "Assessment of optical coherence tomography imaging in the diagnosis of non-melanoma skin cancer and benign lesions versus normal skin: observer-blinded evaluation by dermatologists and pathologists," *Dermatol. Surg.* **35**(6), 965–972 (2009).
39. S. A. Alawi et al., "Optical coherence tomography for presurgical margin assessment of non-melanoma skin cancer—a practical approach," *Exp. Dermatol.* **22**(8), 547–551 (2013).
40. C. A. Banzhaf et al., "Optical coherence tomography imaging of non-melanoma skin cancer undergoing imiquimod therapy," *Skin Res. Technol.* **20**(2), 170–176 (2014).
41. J. Olsen et al., "Diagnostic accuracy of optical coherence tomography in actinic keratosis and basal cell carcinoma," *Photodiagn. Photodyn. Ther.* **16**, 44–49 (2016).
42. M. Ulrich et al., "The sensitivity and specificity of optical coherence tomography for the assisted diagnosis of nonpigmented basal cell carcinoma: an observational study," *Br. J. Dermatol.* **173**(2), 428–435 (2015).
43. O. Markowitz et al., "Evaluation of optical coherence tomography as a means of identifying earlier stage basal cell carcinomas while reducing the use of diagnostic biopsy," *J. Clin. Aesthetic Dermatol.* **8**(10), 14–20 (2015).
44. M. A. Boone et al., "High-definition optical coherence tomography algorithm for the discrimination of actinic keratosis from normal skin and from squamous cell carcinoma," *J. Eur. Acad. Dermatol. Venereol.* **29**(8), 1606–1615 (2015).
45. M. A. Boone et al., "High-definition optical coherence tomography algorithm for discrimination of basal cell carcinoma from clinical BCC imitators and differentiation between common subtypes," *J. Eur. Acad. Dermatol. Venereol.* **29**(9), 1771–1780 (2015).
46. M. A. Boone et al., "A new algorithm for the discrimination of actinic keratosis from normal skin and squamous cell carcinoma based on in vivo analysis of optical properties by high-definition optical coherence tomography," *J. Eur. Acad. Dermatol. Venereol.* **30**(10), 1714–1725 (2016).
47. A. Marneffe et al., "Validation of a diagnostic algorithm for the discrimination of actinic keratosis from normal skin and squamous cell carcinoma by means of high-definition optical coherence tomography," *Exp. Dermatol.* **25**(9), 684–687 (2016).
48. C. Wahrlich et al., "Assessment of a scoring system for basal cell carcinoma with multi-beam optical coherence tomography," *J. Eur. Acad. Dermatol. Venereol.* **29**(8), 1562–1569 (2015).

49. T. Maier et al., "Treatment monitoring of topical ingenol mebutate in actinic keratoses with the combination of optical coherence tomography and reflectance confocal microscopy: a case series," *Br. J. Dermatol.* **172**(3), 816–818 (2015).
50. J. Malvey et al., "Treatment monitoring of 0.5% 5-fluorouracil and 10% salicylic acid in clinical and subclinical actinic keratoses with the combination of optical coherence tomography and reflectance confocal microscopy," *J. Eur. Acad. Dermatol. Venereol.* **30**(2), 258–265 (2016).
51. L. Niculescu et al., "Optical coherence tomography imaging of basal cell carcinoma undergoing photodynamic therapy: a pilot study," *Photodiagn. Photodyn. Ther.* **18**, 133–137 (2017).
52. L. Themstrup et al., "In vivo microvascular imaging of cutaneous actinic keratosis, Bowen's disease and squamous cell carcinoma using dynamic optical coherence tomography," *J. Eur. Acad. Dermatol. Venereol.* **31**(10), 1655–1662 (2017).
53. V. Sigsgaard et al., "In vivo measurements of blood vessels' distribution in non-melanoma skin cancer by dynamic optical coherence tomography—a new quantitative measure?" *Skin Res. Technol.* **24**(1), 123–128 (2018).
54. T. Marvdashti et al., "Classification of basal cell carcinoma in human skin using machine learning and quantitative features captured by polarization sensitive optical coherence tomography," *Biomed. Opt. Express* **7**(9), 3721–3735 (2016).
55. N. De Carvalho et al., "Optical coherence tomography for margin definition of basal cell carcinoma before micrographic surgery—recommendations regarding the marking and scanning technique," *Skin Res. Technol.* **24**(1), 145–151 (2018).
56. D. Yucel et al., "Optical coherence tomography of basal cell carcinoma: density and signal attenuation," *Skin Res. Technol.* **22**(4), 497–504 (2016).
57. S. Schuh et al., "Optical coherence tomography of actinic keratoses and basal cell carcinomas - differentiation by quantification of signal intensity and layer thickness," *J. Eur. Acad. Dermatol. Venereol.* **30**(8), 1321–1326 (2016).
58. M. Boone et al., "In vivo assessment of optical properties of basal cell carcinoma and differentiation of BCC subtypes by high-definition optical coherence tomography," *Biomed. Opt. Express* **7**(6), 2269–2284 (2016).
59. A. A. Hussain et al., "Adjunct use of optical coherence tomography increases the detection of recurrent basal cell carcinoma over clinical and dermoscopic examination alone," *Photodiagn. Photodyn. Ther.* **14**, 178–184 (2016).
60. L. Themstrup et al., "Validation of dynamic optical coherence tomography for non-invasive, in vivo microcirculation imaging of the skin," *Microvasc. Res.* **107**, 97–105 (2016).
61. L. Themstrup et al., "In vivo, micro-morphological vascular changes induced by topical brimonidine studied by dynamic optical coherence tomography," *J. Eur. Acad. Dermatol. Venereol.* **30**(6), 974–979 (2016).
62. V. de Giorgi et al., "Possible histopathologic correlates of dermoscopic features in pigmented melanocytic lesions identified by means of optical coherence tomography," *Exp. Dermatol.* **14**(1), 56–59 (2005).
63. T. Hinz et al., "Assessment of tumor thickness in melanocytic skin lesions: comparison of optical coherence tomography, 20-MHz ultrasound and histopathology," *Dermatology* **223**(2), 161–168 (2011).
64. N. Meyer et al., "High-frequency ultrasonography but not 930-nm optical coherence tomography reliably evaluates melanoma thickness in vivo: a prospective validation study," *Br. J. Dermatol.* **171**(4), 799–805 (2014).
65. A. Varkentin et al., "Comparative study of presurgical skin infiltration depth measurements of melanocytic lesions with OCT and high frequency ultrasound," *J. Biophotonics* **10**(6–7), 854–861 (2017).
66. T. Gambichler et al., "High-definition optical coherence tomography of melanocytic skin lesions," *J. Biophotonics* **8**(8), 681–686 (2015).
67. T. Gambichler et al., "Characterization of benign and malignant melanocytic skin lesions using optical coherence tomography in vivo," *J. Am. Acad. Dermatol.* **57**(4), 629–637 (2007).
68. M. A. Boone et al., "High-definition optical coherence tomography imaging of melanocytic lesions: a pilot study," *Arch. Dermatol. Res.* **306**(1), 11–26 (2014).
69. T. Gambichler et al., "A multicentre pilot study investigating high-definition optical coherence tomography in the differentiation of cutaneous melanoma and melanocytic naevi," *J. Eur. Acad. Dermatol. Venereol.* **29**(3), 537–541 (2015).
70. M. A. Boone et al., "In vivo assessment of optical properties of melanocytic skin lesions and differentiation of melanoma from non-malignant lesions by high-definition optical coherence tomography," *Arch. Dermatol. Res.* **308**(1), 7–20 (2016).
71. J. Welzel, M. Bruhns, and H. H. Wolff, "Optical coherence tomography in contact dermatitis and psoriasis," *Arch. Dermatol. Res.* **295**(2), 50–55 (2003).
72. M. Manfredini et al., "Acne: morphologic and vascular study of lesions and surrounding skin by means of optical coherence tomography," *J. Eur. Acad. Dermatol. Venereol.* **31**(9), 1541–1546 (2017).
73. M. A. Boone, G. B. Jemec, and V. Del Marmol, "Differentiating allergic and irritant contact dermatitis by high-definition optical coherence tomography: a pilot study," *Arch. Dermatol. Res.* **307**(1), 11–22 (2015).
74. A. S. Aldahan et al., "Vascular features of nail psoriasis using dynamic optical coherence tomography," *Skin Appendage Disord.* **2**(3–4), 102–108 (2017).
75. T. Gambichler et al., "Correlation between clinical scoring of allergic patch test reactions and optical coherence tomography," *J. Biomed. Opt.* **10**(6), 064030 (2005).
76. R. Aschoff et al., "Evaluation of the atrophogenic potential of hydrocortisone 1% cream and pimecrolimus 1% cream in uninvolved forehead skin of patients with atopic dermatitis using optical coherence tomography," *Exp. Dermatol.* **20**(10), 832–836 (2011).
77. K. Buder, P. Knuschke, and G. Wozel, "Evaluation of methylprednisolone aceponate, tacrolimus and combination thereof in the psoriasis plaque test using sum score, 20-MHz-ultrasonography and optical coherence tomography," *Int. J. Clin. Pharmacol. Ther.* **48**(12), 814–820 (2010).
78. H. Morsy et al., "Optical coherence tomography imaging of psoriasis vulgaris: correlation with histology and disease severity," *Arch. Dermatol. Res.* **302**(2), 105–111 (2010).
79. M. Boone et al., "High-definition optical coherence tomography: adapted algorithmic method for pattern analysis of inflammatory skin diseases: a pilot study," *Arch. Dermatol. Res.* **305**(4), 283–297 (2013).
80. C. H. Yang et al., "Feasibility of ablative fractional laser-assisted drug delivery with optical coherence tomography," *Biomed. Opt. Express* **5**(11), 3949–3959 (2014).
81. M. T. Tsai et al., "Evaluation of laser-assisted trans-nail drug delivery with optical coherence tomography," *Sensors* **16**(12), 2111 (2016).
82. A. Taghavikhalilbad et al., "Semi-automated localization of dermal epidermal junction in optical coherence tomography images of skin," *Appl. Opt.* **56**(11), 3116–3121 (2017).
83. K. Schicho et al., "Optical coherence tomography for planning of follicular unit extraction," *Dermatol. Surg.* **41**(3), 358–363 (2015).
84. U. H. Olesen, M. Mogensen, and M. Haedersdal, "Vehicle type affects filling of fractional laser-ablated channels imaged by optical coherence tomography," *Lasers Med. Sci.* **32**(3), 679–684 (2017).
85. C. A. Banzhaf et al., "Spatiotemporal closure of fractional laser-ablated channels imaged by optical coherence tomography and reflectance confocal microscopy," *Lasers Surg. Med.* **48**(2), 157–165 (2016).
86. C. A. Banzhaf et al., "Fractional laser-assisted drug uptake: impact of time-related topical application to achieve enhanced delivery," *Lasers Surg. Med.* **49**(4), 348–354 (2017).
87. M. Mogensen et al., "Nail thickness measurements using optical coherence tomography and 20-MHz ultrasonography," *Br. J. Dermatol.* **157**(5), 894–900 (2007).
88. E. Sattler et al., "Confocal laser scanning microscopy, optical coherence tomography and transonychia water loss for in vivo investigation of nails," *Br. J. Dermatol.* **166**(4), 740–746 (2012).
89. T. Gambichler et al., "Epidermal thickness assessed by optical coherence tomography and routine histology: preliminary results of method comparison," *J. Eur. Acad. Dermatol. Venereol.* **20**(7), 791–795 (2006).
90. T. Gambichler et al., "In vivo data of epidermal thickness evaluated by optical coherence tomography: effects of age, gender, skin type, and anatomic site," *J. Dermatol. Sci.* **44**(3), 145–152 (2006).

91. T. Gambichler et al., "Validation of optical coherence tomography in vivo using cryostat histology," *Phys. Med. Biol.* **52**(5), N75–N85 (2007).
92. M. Mogensen et al., "Morphology and epidermal thickness of normal skin imaged by optical coherence tomography," *Dermatology* **217**(1), 14–20 (2008).
93. J. Weissman, T. Hancewicz, and P. Kaplan, "Optical coherence tomography of skin for measurement of epidermal thickness by shapelet-based image analysis," *Opt. Express* **12**(23), 5760–5769 (2004).
94. T. Gambichler et al., "In vivo determination of epidermal thickness using high-definition optical coherence tomography," *Br. J. Dermatol.* **170**(3), 737–739 (2014).
95. T. Gambichler et al., "Comparison of histometric data obtained by optical coherence tomography and routine histology," *J. Biomed. Opt.* **10**(4), 044008 (2005).
96. M. Cossmann and J. Welzel, "Evaluation of the atrophogenic potential of different glucocorticoids using optical coherence tomography, 20-MHz ultrasound and profilometry; a double-blind, placebo-controlled trial," *Br. J. Dermatol.* **155**(4), 700–706 (2006).
97. N. G. Bartels et al., "Optical coherent tomography: promising in vivo measurement of hair shaft cross section," *J. Biomed. Opt.* **16**(9), 096003 (2011).
98. M. Kuck et al., "Analysis of the efficiency of hair removal by different optical methods: comparison of Trichoscan, reflectance confocal microscopy, and optical coherence tomography," *J. Biomed. Opt.* **17**(10), 101504 (2012).
99. C. Salvini et al., "Application of optical coherence tomography in non-invasive characterization of skin vascular lesions," *Skin Res. Technol.* **14**(1), 89–92 (2008).
100. H. C. Ring et al., "Optical coherence tomography imaging of telangiectasias during intense pulsed light treatment: a potential tool for rapid outcome assessment," *Arch. Dermatol. Res.* **305**(4), 299–303 (2013).
101. P. Gong et al., "Optical coherence tomography angiography for longitudinal monitoring of vascular changes in human cutaneous burns," *Exp. Dermatol.* **25**(9), 722–724 (2016).
102. J. S. Waibel et al., "The diagnostic role of optical coherence tomography (OCT) in measuring the depth of burn and traumatic scars for more accurate laser dosimetry: pilot study," *J. Drugs Dermatol.* **15**(11), 1375–1380 (2016).
103. Y. M. Liew et al., "In vivo assessment of human burn scars through automated quantification of vascularity using optical coherence tomography," *J. Biomed. Opt.* **18**(6), 061213 (2013).
104. A. A. Hussain et al., "A case report of differentiating staphylococcal scalded skin syndrome and toxic epidermal necrolysis by optical coherence tomography," *Skin Res. Technol.* **21**(3), 363–365 (2015).
105. M. Mogensen et al., "Optical coherence tomography imaging of bullous diseases," *J. Eur. Acad. Dermatol. Venereol.* **22**(12), 1458–1464 (2008).
106. C. A. Banzhaf et al., "In vivo imaging of sarcoptes scabiei infestation using optical coherence tomography," *Case Rep. Dermatol.* **5**(2), 156–162 (2013).
107. H. Morsy et al., "Imaging of cutaneous larva migrans by optical coherence tomography," *Travel Med. Infect. Dis.* **5**(4), 243–246 (2007).
108. T. Maier et al., "High-definition optical coherence tomography for the in vivo detection of demodex mites," *Dermatology* **225**(3), 271–276 (2012).
109. G. Rothmund et al., "Confocal laser scanning microscopy as a new valuable tool in the diagnosis of onychomycosis - comparison of six diagnostic methods," *Mycoses* **56**(1), 47–55 (2013).
110. F. Abuzahra et al., "Pilot study: optical coherence tomography as a non-invasive diagnostic perspective for real time visualisation of onychomycosis," *Mycoses* **53**(4), 334–339 (2010).
111. S. Z. Aydin et al., "Potential use of optical coherence tomography and high-frequency ultrasound for the assessment of nail disease in psoriasis and psoriatic arthritis," *Dermatology* **227**(1), 45–51 (2013).
112. S. J. Edwards et al., "Diagnostic accuracy of reflectance confocal microscopy using VivaScope for detecting and monitoring skin lesions: a systematic review," *Clin. Exp. Dermatol.* **42**(3), 266–275 (2017).

**Jonas Olsen** is an MD and PhD student at the Department of Dermatology, Zealand University Hospital, Denmark. He has authored several manuscripts in the clinical field of OCT in dermatology and is teaching applied medical statistics at the PhD-school at faculty of health sciences, University of Copenhagen. Currently, he is writing a PhD-thesis on the nonsurgical treatment effects on the microvasculature of nonmelanoma skin cancer assessed with OCT.

**Jon Holmes** has more than 30 years' experience in optical imaging, both in industrial manufacturing and in diagnostics for medicine, and in 2006 cofounded Michelson Diagnostics Ltd. and became the company's first CEO. Specializing in optical coherence tomography, he was elected a fellow of the Institute of Physics in November 2017. He is author of multiple patents and publications in peer-reviewed journals in the field of OCT.

**Gregor B. E. Jemec** is the founding chairman at the Department of Dermatology, Zealand University Hospital, and tenured professor at the University of Copenhagen, Denmark. He has broad academic interests in many fields of dermatology and publishes broadly with 450+ scientific publications, 10 books and 130+ invited lectures at international conferences. Currently, he heads a research group dedicated the clinical use of OCT.