

UNIVERSITY OF COPENHAGEN



Small Hard Macular Drusen and Associations in 11-to 12-Year-Old Children in the Copenhagen Child Cohort 2000 Eye Study

Munch, Inger Christine; Li, Xiao Qiang; Ahmad, Shaista Sumbal Mulk; Olsen, Else Marie; Skovgaard, Anne Mette; Larsen, Michael

Published in:
Investigative Ophthalmology & Visual Science

DOI:
[10.1167/iovs.18-25877](https://doi.org/10.1167/iovs.18-25877)

Publication date:
2019

Document version
Publisher's PDF, also known as Version of record

Document license:
[CC BY-NC-ND](https://creativecommons.org/licenses/by-nc-nd/4.0/)

Citation for published version (APA):
Munch, I. C., Li, X. Q., Ahmad, S. S. M., Olsen, E. M., Skovgaard, A. M., & Larsen, M. (2019). Small Hard Macular Drusen and Associations in 11-to 12-Year-Old Children in the Copenhagen Child Cohort 2000 Eye Study. *Investigative Ophthalmology & Visual Science*, 60(5), 1454-1460. <https://doi.org/10.1167/iovs.18-25877>

Small Hard Macular Drusen and Associations in 11- to 12-Year-Old Children in the Copenhagen Child Cohort 2000 Eye Study

Inger Christine Munch,^{1,2} Xiao Qiang Li,³ Shaista Sumbal Mulk Ahmad,² Else Marie Olsen,^{4,5} Anne Mette Skovgaard,^{4,6} and Michael Larsen^{2,3}

¹Department of Ophthalmology, Zealand University Hospital, Roskilde, Denmark

²Department of Clinical Medicine, Faculty of Health Sciences, University of Copenhagen, Copenhagen, Denmark

³Department of Ophthalmology, Rigshospitalet, Copenhagen, Denmark

⁴Institute of Public Health, University of Copenhagen, Copenhagen, Denmark

⁵Centre for Clinical Research and Disease Prevention, Capital Region, Denmark

⁶National Institute of Public Health, University of Southern Denmark, Copenhagen, Denmark

Correspondence: Inger Christine Munch, Department of Ophthalmology, Zealand University Hospital, Sygehusvej 10, Roskilde DK-4000, Denmark; icm@dadlnet.dk.

Submitted: October 19, 2018

Accepted: January 29, 2019

Citation: Munch IC, Li XQ, Ahmad SSM, Olsen EM, Skovgaard AM, Larsen M. Small hard macular drusen and associations in 11- to 12-year-old children in the Copenhagen Child Cohort 2000 Eye Study. *Invest Ophthalmol Vis Sci.* 2019;60:1454-1460. <https://doi.org/10.1167/iovs.18-25877>

PURPOSE. To assess the prevalence and associations of small hard drusen in a child cohort.

METHODS. Cross-sectional study of 11- to 12-year-old Danish children from the population-based Copenhagen Child Cohort 2000 Eye Study. Fovea-centered, 45° color images of both eyes were graded for macular drusen (within one optic-disc-rim-to-fovea distance of the foveal center) and for extramacular drusen. Analyses tested for associations between drusen and anthropometric measures including choroidal thickness.

RESULTS. Gradable fundus images from both eyes were available for 1333 children (640 boys, 693 girls) with a mean (SD) age of 11.7 (0.40) years. One or more small hard macular drusen (diameter <63 μm) were present in 82 (6.2%) right eyes and 82 (6.2%) left eyes and in 147 (11.0%) subjects. Four children (0.30%) had 20 or more small hard macular drusen in one or both eyes. Extramacular small hard drusen were present in 10.7% of children, and 19% of children had such drusen anywhere. The odds for having one or more small hard macular drusen increased with subfoveal choroidal thickness with an odds ratio of 1.15 (95% confidence interval, 1.03-1.28; $P = 0.013$) per 50-μm thicker choroid, adjusted for age and sex. The association with choroidal thickness was also present for extramacular drusen.

CONCLUSIONS. Having one or more small hard macular drusen was common in 11- to 12-year old children and it was associated with a thicker subfoveal choroid. Few children had many small hard drusen. There is no apparent clinical impact of small hard drusen in childhood.

Keywords: small hard drusen, children, choroid, optic coherence tomography, cohort study, population-based, CCC2000

Small hard drusen are a frequent ancillary finding of uncertain significance in people who undergo fundus examination. They are visible on fundus photographs in more than 90% of adults between 20 and 46 years of age.¹ Previous studies in adults²⁻⁴ have found that having many small hard drusen is associated with subsequent development of soft drusen typical of age-related macular degeneration (AMD). The heritability of having many small hard drusen is high,^{1,5} but it is not linked to the prominent AMD-associated polymorphisms in complement factor H, complement factor B, and *ARMS2*.⁶ The only systemic risk factors that have been identified for small hard drusen are age,^{3,6} higher levels of serum triglycerides, and lower levels of high-density lipoprotein cholesterol.⁷

Small hard drusen have a sharp outline, are uniformly bright white, and by convention of classification are smaller than 63 μm in diameter.⁸⁻¹⁰ Drusen with a diameter ≥125 μm usually have a somewhat unsharp border and a more yellowish color. They define, by current convention, the earliest stage of AMD.¹¹ Additional types of AMD drusen include cuticular drusen, which are numerous and small (25-μm to 75-μm diameter),¹²

and subretinal drusenoid deposits, which are located anteriorly to the retinal pigment epithelium.¹³

Small hard drusen in healthy children and young adults could be a matter of concern because of their unknown long-term impact on ocular health. Thus, there is potential clinical value in studying small hard drusen across the age spectrum. The present study examined the prevalence and associations of small hard drusen in children.

METHODS

Study Population

The Copenhagen Child Cohort 2000 (CCC2000) Eye Study is a population-based observational study, the baseline examination of which was an appendix to the 11-year follow-up of the prospective, longitudinal CCC2000 Study of child mental health, which covers a population cohort consisting, at the anonymized public registry level, of all 6090 children born in the 16 municipalities of the defunct Copenhagen County in the



year 2000.¹⁴ At the 11-year face-to-face survey of mental health, all 1632 children who presented for examination were invited to have their eyes examined, a procedure for which 1406 participants (86.2%) volunteered.¹⁵ The study was approved by the local medical ethics committee and performed in accordance with the Declaration of Helsinki. The protocol was not assigned a number as the study was purely observational and noninvasive. Written informed consent was obtained from the children's parents or legal guardians before examination.

Procedures

Previous reports on the CCC2000 eye study cohort cover choroidal and retinal nerve fiber layer thickness and optic disc drusen characteristics¹⁵⁻¹⁸ and the details of the protocol.¹⁵ In brief, all participants and their parents were asked about the participants' ophthalmic history, and anthropometric measures were obtained including weight and height. Puberty stage was assessed by the child choosing the most representative Tanner-stage drawing of their physical characteristics. Information about pregnancy, birth parameters, and sex of the child was obtained from the Danish Medical Birth Registry.¹⁴ The ethnicity of the children was indirectly assessed by the maternal citizenship code as registered in the Danish Civil Registration System as described in a previous report.¹⁶

All subjects underwent a general ophthalmic examination including nonmydriatic fundus photography with fovea- and disc-centered 45° digital color fundus photography (Topcon Mark II TRC-NW7SF; Topcon Corp., Tokyo, Japan). Fundus characteristics were assessed by an ophthalmologist (ICM) who was masked to all parameters. Digital images were examined on a 27-inch computer screen. Small hard drusen were defined as any bright element with a diameter equal to or smaller than 63 μm, whose shape, color, or proximity to adjacent structures did not suggest that it could be hard exudate, subretinal precipitate, focal loss of the retinal pigment epithelium, Gunn dots, or small posterior hyaloid reflexes as often seen along the larger vessels of the retina. The definition is comparable to the one used in our previous studies of small hard drusen.⁶ The definition excludes drusen associated with nevi. When lesions on digital images were deemed questionable or other retinal disease was present, a second ophthalmologist (ML) was consulted. The number of small hard drusen <63 μm was counted within a circle centered on the fovea with a radius stretching to the temporal rim of the optic disc, which results in the area having a radius of approximately 3000 μm (Fig. 1).⁶ Within this circle, drusen >63 μm, if present, were also registered. Drusen outside the central circle that were visible on fovea-centered 45° fundus photographs were counted and registered as extramacular drusen. Both eyes were assessed. Only subjects with gradable photographs from both eyes were included ($n = 1333$).

Best-corrected visual acuity (BCVA) was determined by using Early Treatment Diabetic Retinopathy Study (ETDRS) charts after the completion of an abbreviated refraction protocol where refractioning was pursued only until the participant read 80 ETDRS letters or better. Noncycloplegic objective refraction was measured by using an automated refractometer (Retinomax K-plus 2; Right MFG Co., Ltd., Tokyo, Japan) and used to guide refractioning. Ocular axial length was measured with an interferometric device (IOL-Master, version 3.01.0294; Carl Zeiss Meditec, La Jolla, CA, USA).

Spectral-domain optical coherence tomography (OCT, Spectralis HRA-OCT; Heidelberg Engineering, Heidelberg, Germany) was made with emphasis on enhanced-depth imaging mode scans. The protocol included a seven-line horizontal pattern and a four-line radial pattern, both centered

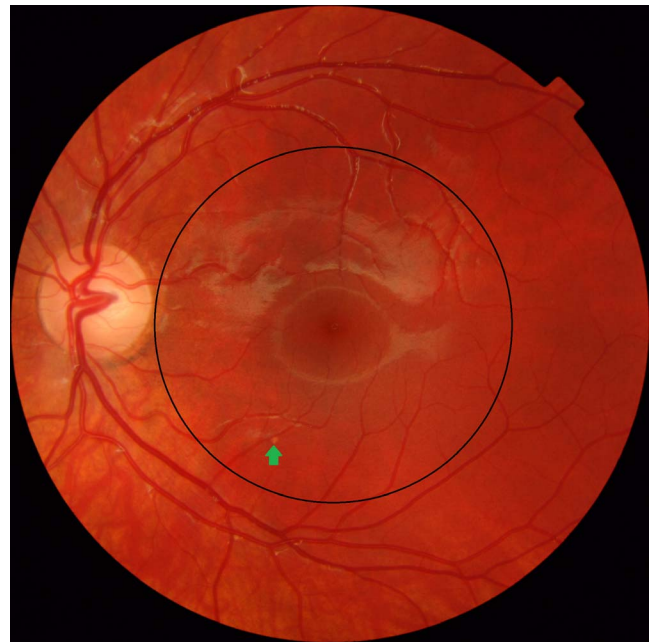

FIGURE 1. Forty-five-degree color fundus photograph of an 11-year-old participant from the CCC2000 Eye Study. A circle (black) centered on the fovea with a radius stretching to the temporal rim of the optic disc was used to define the macular area. In this case a bright fundus element of greatest linear dimension larger than 63 μm is seen (green arrow). It is the only example of a drusen-like element larger than 63 μm in the present study. Other bright areas seen in this photograph are fundus reflexes.

on the fovea. Subfoveal choroidal thickness was measured in right eyes by using the instrument manufacturer's software (Heidelberg Eye Explorer, version 1.6.1.0; Heidelberg Engineering). The segmentation line placed automatically at the inner limiting membrane was moved manually to the choroidoscleral border by an experienced operator (XQL) as previously described^{15,19} and illustrated in Figure 2.

Statistical Analysis

Statistical analyses were made by using the SAS software package (version 9.4; SAS Institute, Cary, NC, USA). Means and standard deviations (SDs) were calculated for continuous variables and medians and interquartile ranges (IQR) for skewed distributions (body weight). Comparisons between children with and without drusen were made by using the two-tailed Student's *t*-test or Wilcoxon's rank sum test (used for body weight) for continuous variables and χ^2 tests for categorical variables. Multiple logistic regression was used to estimate associations with drusen. Age was calculated in days but presented in years. Axial length, subfoveal choroidal thickness, spherical equivalent refractive error, BCVA, height, weight, and body mass index were included as continuous variables. Tanner stages were entered as ordinal data. Tests for interactions with sex were performed by adding the cross-product to the model. The level of statistical significance was set to $P < 0.05$, all tests were two-sided, and estimates are presented with 95% confidence intervals (CIs).

RESULTS

The age (mean [SD]) of the 1333 children (640 boys, 693 girls) with gradable fundus images from both eyes was 11.7 (0.40) years (Table 1). Small hard macular drusen were present in 82

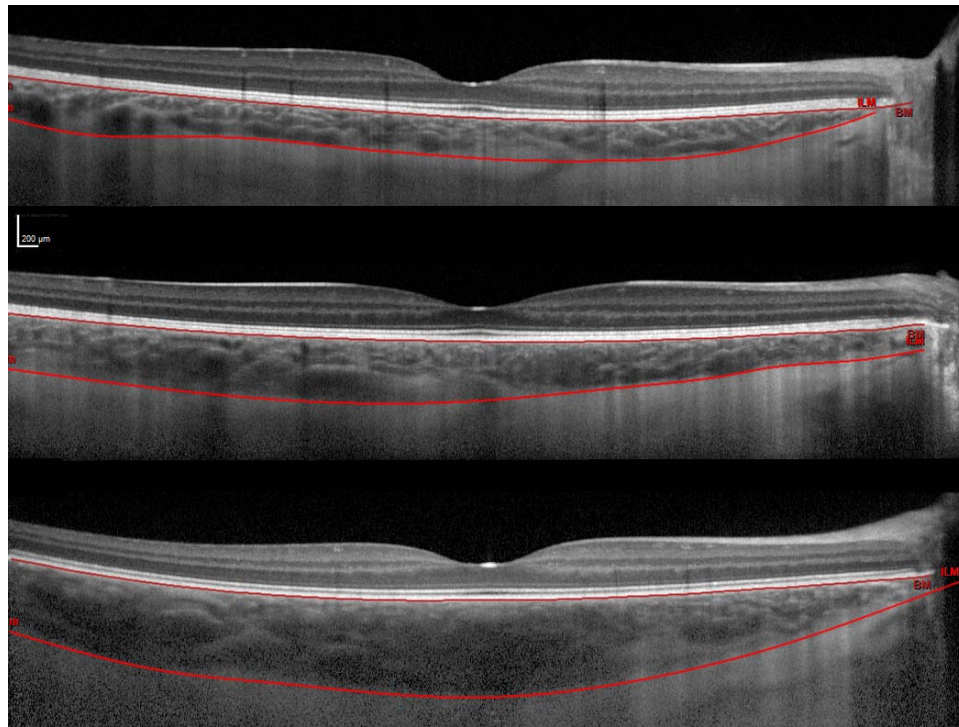


FIGURE 2. Horizontal transfoveal optical coherence tomography scans from three healthy subjects represent thin, medium, and thick choroids with subfoveal choroidal thicknesses of 238, 363, and 597 μm , respectively, from *top* to *bottom*. All three scans are from right eyes. Thickness was measured under the center of the foveal depression.

TABLE 1. Prevalence of Small Hard Drusen and Characteristics of the Study Population of 11- to 12-Year-Old Children

Parameter	All Participants, <i>n</i> = 1333	Boys, <i>n</i> = 640	Girls, <i>n</i> = 693	<i>P</i> Value
Presence of small hard macular drusen*, No. (%)	147 (11.0)	61 (9.5)	86 (12.4)	0.094
Presence of extramacular small hard drusen, No. (%)	143 (10.7)	53 (8.3)	90 (13.0)	0.0055
Presence of small hard drusen anywhere, No. (%)	249 (18.7)	100 (15.6)	149 (21.5)	0.0060
Visual acuity, right eyes, mean (SD), No. of ETDRS letters	88.7 (3.3)	88.9 (3.6)	86.6 (3.0)	0.15
Spherical equivalent refraction†, right eyes, mean (SD), D	0.11 (0.88)	0.09 (0.85)	0.13 (0.9)	0.51
Axial length, right eyes, mean (SD), mm	23.2 (0.79)	23.5 (0.74)	22.9 (0.74)	<0.0001
Subfoveal choroidal thickness, right eyes, mean (SD), μm	361 (78)	349 (73)	371 (82)	<0.0001
Peripapillary retinal nerve fiber layer, right eyes, mean (SD), μm	104 (9.7)	104 (9.7)	105 (9.6)	0.46
Age, mean (SD), y	11.7 (0.4)	11.7 (0.4)	11.7 (0.4)	0.82
Body weight, median (IQR), kg	41.3 (11)	40.4 (11)	42.2 (12)	0.032
Height, mean (SD), cm	152 (7.5)	151 (7.6)	153 (7.4)	0.018
Pubertal development, No. (%)				
Tanner stage 1	268 (22)	155 (27)	113 (18)	<0.0001
Tanner stage 2	637 (52)	319 (55)	318 (50)	
Tanner stage 3/4	313 (26)	106 (18)	207 (32)	
Birth weight, mean (SD), g	3535 (592)	3605 (615)	3469 (562)	<0.0001
Maternal smoking status during pregnancy, No. (%)				
None or ceased	1012 (82)	483 (82)	529 (82)	1.0
Continued	220 (18)	105 (18)	115 (18)	
Maternal country of citizenship, No. (%)				
European	1234 (93)	592 (93)	642 (93)	0.92
Non-European	99 (7.4)	48 (7.5)	51 (7.4)	

ETDRS, Early Treatment Diabetic Retinopathy Study; IQR, interquartile range.

* Defined as one or more small hard drusen within one optic-disc-rim-to-fovea distance of the fovea on fovea-centered, color, 45° fundus images in one or both eyes.

† Refraction measured without cycloplegia.

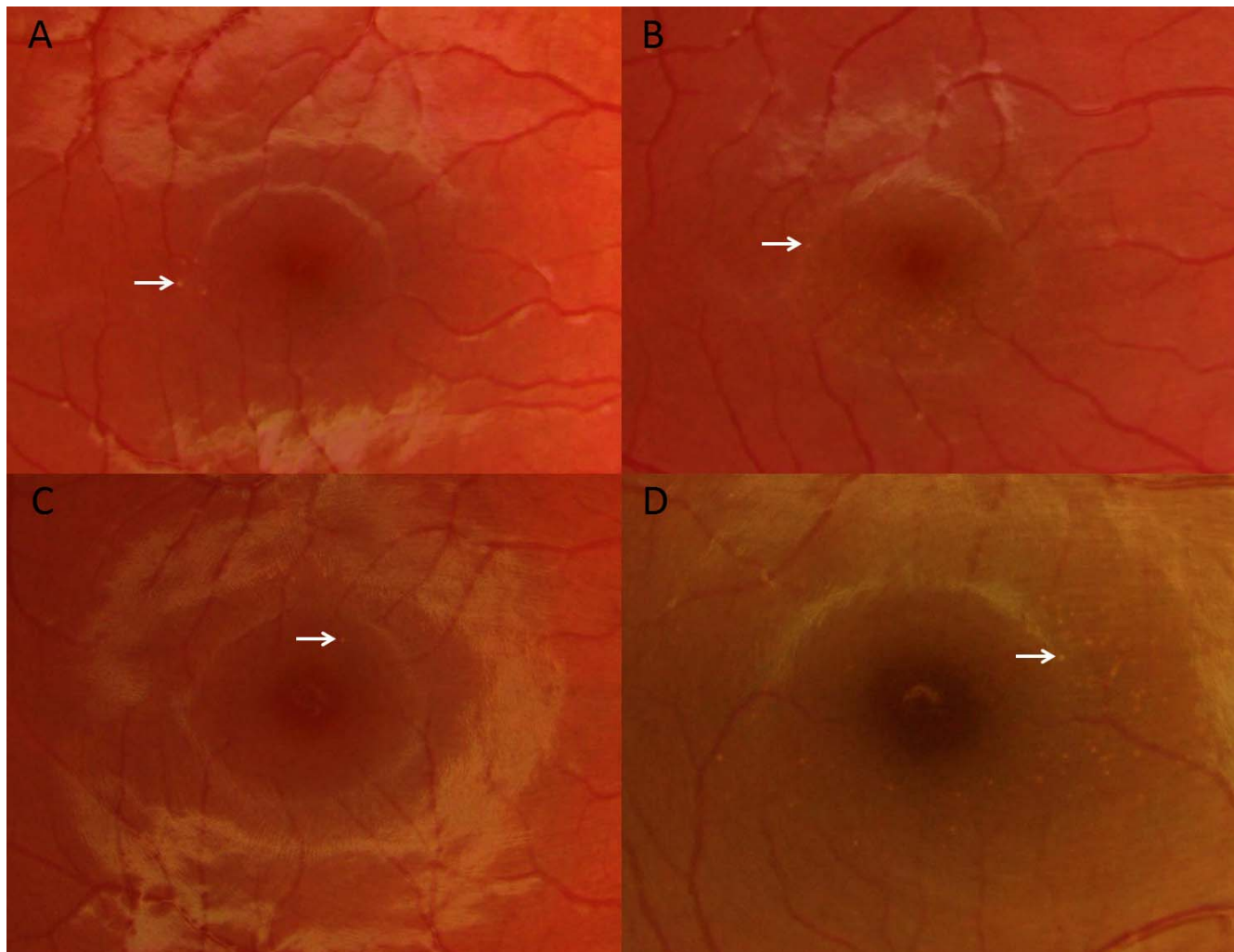


FIGURE 3. Color fundus photography details from the macula in 11-year-old children. (A) A girl with four small hard drusen in her right macula. (B) A boy with numerous small hard drusen in the macula in both eyes. (C) A boy with a single small hard drusen in the macula of his right eye. (D) A girl with several very distinct small hard drusen in the macula of both eyes.

(6.2% [95% CI, 4.9%–7.4%]) right eyes and in 82 (6.2% [95% CI, 4.9%–7.4%]) left eyes. A total of 147 (11.0% [95% CI, 9.3%–12.7%]) children had small hard macular drusen in at least one eye (Table 1). The prevalence of having one or more small hard macular drusen was 9.5% (61/640) in boys and 12.4% (86/693) in girls ($P = 0.094$; Table 1). Seventeen children (1.3%) had macular small hard drusen in both eyes. This frequency was higher than expected (0.38%) if one assumed no intereye dependence ($P < 0.0001$, Fisher's two-sided exact test). Thirty-two children (2.6%) had 2 or more drusen in at least one eye, nine children (0.68%) had 5 or more macular drusen in one (six children) or both eyes (three children), and four children (0.30%) had 20 or more small hard macular drusen in one (one child) or both eyes (three children) (Fig. 3, data not tabulated). We found a single druse-like element of diameter $63\ \mu\text{m}$ to $125\ \mu\text{m}$ in the right macula of a child with no other drusen (Fig. 1). We found no drusen larger than $125\ \mu\text{m}$.

Logistic regression analyses found that the odds for having small hard macular drusen increased by 15% per each $50\text{-}\mu\text{m}$ increase in choroidal thickness (odds ratio = 1.15 [95% CI, 1.03–1.28; $P = 0.013$; adjusted for age and sex; Table 2]). The association remained significant (odds ratio = 1.14 [95% CI, 1.01–1.28; $P = 0.038$; data not tabulated]) after adjustment also for the right eye's BCVA, subjective refraction, axial length,

retinal nerve fiber layer thickness, together with body weight, body height, pubertal development, birth weight, maternal smoking status during pregnancy, and maternal country of citizenship.

Small hard drusen farther from the center of the macula than one optic-disc-rim-to-fovea distance (extramacular drusen) were present in 98 (7.4%) right eyes and in 63 (4.7%) left eyes. In total, 143 (10.7% [95% CI, 9.1%–12.4%]; Table 1) children had extramacular drusen in any eye, whereas 18 (1.4%) children had extramacular drusen in both eyes. This was higher than expected if no intereye dependence was assumed ($P < 0.0001$, Fisher's exact test, two-sided). Nearly 19% of children (249/1333, 18.7% [95% CI, 16.6%–20.8%]; Table 2) had at least one visible small hard druse (macular or extramacular) on his or her fovea-centered, 45° fundus images.

Girls more often had extramacular small hard drusen than boys (90/693 [13.0%] vs. 53/640 [8.3%], $P = 0.0055$, Table 2; age-adjusted odds ratio = 1.66 [95% CI, 1.16–2.37; $P = 0.0058$], Table 2) although after multivariate adjustment the association was no longer significant. Having small hard drusen outside the macula was associated with having small hard drusen within the macula in that the former were present in 41 of the 147 (27.7%) children with macular drusen compared to only 102 of 1186 (8.6%) children without macular drusen ($P < 0.0001$).

TABLE 2. Associations of Small Hard Drusen in 11- to 12-Year-Old Children

Parameter	Small Hard Macular Drusen*, Age- and Sex-Adjusted Odds Ratios (95% CI)		Extramacular Small Hard Drusen, Age- and Sex-Adjusted Odds Ratios (95% CI)	
	Odds Ratios (95% CI)	P Value	Odds Ratios (95% CI)	P Value
Age, per 1-y increase	1.42 (0.93–2.15)	0.10	1.18 (0.77–1.82)	0.44
Sex, girls vs. boys	1.35 (0.95–1.91)	0.092	1.66 (1.16–2.37)	0.0058
Extramacular small hard drusen, present vs. none	4.00 (2.64–6.06)	<0.0001	–	–
Visual acuity, right eyes, per 5-letter increase in No. of ETDRS letters	0.85 (0.67–1.09)	0.20	1.17 (0.87–1.57)	0.30
Spherical equivalent refraction†, right eyes, per 1-diopter increase	0.89 (0.73–1.08)	0.24	0.96 (0.78–1.17)	0.67
Axial length, right eyes, per 1-mm increase	0.91 (0.72–1.14)	0.40	0.81 (0.64–1.03)	0.081
Subfoveal choroidal thickness, right eyes, per 50- μ m increase	1.15 (1.03–1.28)	0.013	1.14 (1.03–1.28)	0.016
Peripapillary retinal nerve fiber layer, right eyes, per μ m increase	0.92 (0.77–1.11)	0.40	0.94 (0.78–1.13)	0.51
Body weight, per 5-kg increase	0.99 (0.90–1.10)	0.85	0.97 (0.87–1.07)	0.53
Height, per 10-cm increase	0.93 (0.72–1.19)	0.54	0.97 (0.75–1.25)	0.81
Pubertal development				
Tanner stage 2 vs. stage 1	0.96 (0.60–1.52)	0.85	0.95 (0.60–1.52)	0.83
Tanner stage 3/4 vs. stage 1	0.93 (0.54–1.60)	0.79	0.84 (0.48–1.46)	0.53
Birth weight, per 100-g increase	0.99 (0.96–1.02)	0.56	1.00 (0.97–1.03)	0.94
Maternal smoking status during pregnancy, continued vs. none/ceased	1.22 (0.79–1.90)	0.38	0.78 (0.47–1.28)	0.32
Maternal country of citizenship, non-European vs. European	0.60 (0.27–1.31)	0.20	1.56 (0.87–2.78)	0.14

ETDRS, Early Treatment Diabetic Retinopathy Study.

* Defined as one or more small hard drusen within one optic-disc-rim-to-fovea distance of the fovea on fovea-centered, color, 45° fundus images in one or both eyes.

† Refraction measured without cycloplegia.

The age- and sex-adjusted odds ratio for having macular small hard drusen was 4.00 (95% CI, 2.64–6.06; $P < 0.0001$; Table 2) in children with extramacular small hard drusen compared with children without extramacular small hard drusen.

Extramacular small hard drusen were associated with a thicker subfoveal choroid with an odds ratio of 1.14 (95% CI, 1.03–1.28; $P = 0.016$; Table 2) per 50- μ m increase in the thickness of the choroid in the age- and sex-adjusted analysis but not after multivariate adjustment.

We found no associations between having one or more macular drusen or extramacular drusen and BCVA, subjective spherical refraction, ocular axial length, peripapillary retinal nerve fiber layer thickness, body weight at 11 to 12 years of age, body height, pubertal development, birth weight, maternal country of citizenship, or maternal smoking status during pregnancy in the age- and sex-adjusted analyses (Table 2).

DISCUSSION

In this population-based birth cohort study of 1333 healthy children aged 11 to 12 years, we found small hard macular drusen on fundus photographs in 11% of participants. The presence of small hard macular drusen was associated with increasing choroidal thickness and with the presence of extramacular drusen.

Few studies have investigated small hard drusen in children. Our observations are in agreement with a cross-sectional study from Finland based on 60° color transparency and black-and-white paper prints of fovea-centered fundus photographs from children and young adults where small defects in the retinal pigment epithelium, likely representing small hard drusen, were seen in as many as 47% of children with diabetes ($n = 206$; median age, 12.6 years) and in 54% of children ($n = 45$; median age, 11.8 years) without diabetes.²⁰ A large number of such elements were seen in 4.4% of the subjects. The higher

apparent prevalence of drusen-like elements found in this study compared with our study may to some extent be explained by the inclusion of all elements, regardless of location, into a single category, whereas we reported drusen separately for the macula. Hence, the prevalence of small hard drusen was 19% in our study when all drusen seen on the single 45°, fovea-centered nonmydriatic images were pooled. It might have been even higher, had we made photographs over a wider area such as the 60° mydriatic images used in the study from Finland. Part of the difference may also be related to the Finnish study's having included subjects up to the age of 19 years. Thus, studies from Denmark of healthy adults show an increasing prevalence and density by age, with small hard drusen anywhere in the fundus being found in 58% of 62 subjects with a median age of 21 years²¹ and in 96% of 220 twins of a mean age of 35 years.¹ Small hard drusen within the macula have been observed in 22% of 97 healthy young adults in Norway with a mean age of 23 years.²²

We found that the risk of having small hard drusen outside the macula increased nearly four times when drusen were present in the macula. This is an interesting corollary to studies of early⁶ and late^{23,24} AMD, which have shown a similar association between macular and extramacular lesions.

In the present study, girls more frequently had drusen outside the macula than boys, consistent with findings from our previous study of 1107 adults with a mean age of 48 years where the women-to-men odds ratio for the presence of peripheral drusen was 2.6.⁶ We found no significant association between small hard macular drusen and sex, neither in our earlier study nor in the present study, which is in agreement with other prior reports.^{3,25,26}

To the best of our knowledge, the association between small hard macular drusen and choroidal thickness is a new finding. Our working hypothesis was that a thinner choroid could be a risk factor for small hard drusen. First of all, the prevalence of small hard drusen increases with age⁶ and

choroidal thickness decreases with age.²⁷ Additionally, choroidal thickness decreases with increasing drusen load among AMD patients.²⁸ Finally, subretinal drusenoid deposits are associated with a thin choroid.^{29,30} Finding the opposite in the present study is consistent, however, with a previous study where the absence of AMD drusen was associated with a thinner choroid.³¹ Furthermore, the prevalence of AMD and the incidence of early AMD have been found to increase with increasing hyperopic refraction in several cohort studies.³²⁻³⁴ Because subfoveal choroidal thickness increases with increasingly hyperopic refraction and shorter axial length,^{15,19,35} these results also support the notion that a thicker choroid could be a risk factor for early AMD. A plausible alternative to small hard drusen being associated with future AMD is an association with the pachychoroid disease spectrum (e.g., pachychoroid pigment epitheliopathy, central serous chorioretinopathy, polypoidal choroidal vasculopathy) for which a thick choroid is a prominent risk factor.³⁶

Having many small hard macular drusen as an adult is associated with subsequent development of AMD⁵ but it is not known whether the presence of a few small hard drusen in a child predisposes to the continued accumulation of small hard drusen and to AMD. Given that small hard drusen are relatively common in children, they seem unlikely to be a marker of rare forms of drusen such as those seen in membranoproliferative glomerulonephritis³⁷ or malattia leventinese/Doyme's honeycomb disease.³⁸

The strengths of the present study included its population-based design, the high number of participants, and the inclusion of OCT, even if it was not invariably applied in a mode that is optimal for the imaging of small hard drusen. Specifically, the scan locations were not customized to the actual small hard drusen seen in a given participant and even if they had been, small hard drusen are not invariably visible on OCT.²² The examination of the relation between small hard drusen and choroidal thickness was a preplanned but secondary analysis. As such, there is a risk of mass significance resulting from multiple testing and therefore replication in one or more separate studies is desirable. No conclusion about causality can be made given the cross-sectional nature of the data analysis.

In conclusion, we found that small hard macular drusen are common in preadolescent children and that they are associated with a thick subfoveal choroid. The clinical significance of drusen in children is unknown. Further studies of early abnormalities of the outer retina in children should assess their potential impact on diseases of the adult eye.

Acknowledgments

Supported by the Jørgen Bagenkop-Nielsens Myopi-Fond, Øjenforeningen, Øjenfonden, University of Copenhagen, and Zealand University Hospital.

Disclosure: **I.C. Munch**, None; **X.Q. Li**, None; **S.S.M. Ahmad**, None; **E.M. Olsen**, None; **A.M. Skovgaard**, None; **M. Larsen**, None

References

- Munch IC, Sander B, Kessel L, et al. Heredity of small hard drusen in twins aged 20-46 years. *Invest Ophthalmol Vis Sci*. 2007;48:833-838.
- Klein R, Klein BE, Jensen SC, Meuer SM. The five-year incidence and progression of age-related maculopathy: the Beaver Dam Eye Study. *Ophthalmology*. 1997;104:7-21.
- Klein R, Myers CE, Lee KE, et al. Small drusen and age-related macular degeneration: The Beaver Dam Eye Study. *J Clin Med*. 2015;4:424-440.
- Klein R, Klein BE, Knudtson MD, Meuer SM, Swift M, Gangnon RE. Fifteen-year cumulative incidence of age-related macular degeneration: the Beaver Dam Eye Study. *Ophthalmology*. 2007;114:253-262.
- Hammond CJ, Webster AR, Snieder H, Bird AC, Gilbert CE, Spector TD. Genetic influence on early age-related maculopathy: a twin study. *Ophthalmology*. 2002;109:730-736.
- Munch IC, Ek J, Kessel L, et al. Small, hard macular drusen and peripheral drusen: associations with AMD genotypes in the Inter99 Eye Study. *Invest Ophthalmol Vis Sci*. 2010;51:2317-2321.
- Munch IC, Linneberg A, Larsen M. Precursors of age-related macular degeneration: associations with physical activity, obesity, and serum lipids in the Inter99 Eye Study. *Invest Ophthalmol Vis Sci*. 2013;54:3932-3940.
- Khan KN, Mahroo OA, Khan RS, et al. Differentiating drusen: drusen and drusen-like appearances associated with ageing, age-related macular degeneration, inherited eye disease and other pathological processes. *Prog Retin Eye Res*. 2016;53:70-106.
- Klein R, Davis MD, Magli YL, Segal P, Klein BE, Hubbard L. The Wisconsin age-related maculopathy grading system. *Ophthalmology*. 1991;98:1128-1134.
- Bird AC, Bressler NM, Bressler SB, et al. An international classification and grading system for age-related maculopathy and age-related macular degeneration: The International ARM Epidemiological Study Group. *Surv Ophthalmol*. 1995;39:367-374.
- Ferris FL, Davis MD, Clemons TE, et al. A simplified severity scale for age-related macular degeneration: AREDS Report No. 18. *Arch Ophthalmol*. 2005;123:1570-1574.
- Boon CJ, van de Ven JP, Hoyng CB, den Hollander AI, Klevering BJ. Cuticular drusen: stars in the sky. *Prog Retin Eye Res*. 2013;37:90-113.
- Zweifel SA, Spaide RF, Curcio CA, Malek G, Imamura Y. Reticular pseudodrusen are subretinal drusenoid deposits. *Ophthalmology*. 2010;117:303-312.
- Skovgaard AM, Olsen EM, Houmann T, et al. The Copenhagen County child cohort: design of a longitudinal study of child mental health. *Scand J Public Health*. 2005;33:197-202.
- Li XQ, Jeppesen P, Larsen M, Munch IC. Subfoveal choroidal thickness in 1323 children aged 11 to 12 years and association with puberty: the Copenhagen Child Cohort 2000 Eye Study. *Invest Ophthalmol Vis Sci*. 2014;55:550-555.
- Ashina H, Li XQ, Olsen EM, Skovgaard AM, Larsen M, Munch IC. Association of maternal smoking during pregnancy and birth weight with retinal nerve fiber layer thickness in children aged 11 or 12 years: The Copenhagen Child Cohort 2000 Eye Study. *JAMA Ophthalmol*. 2017;135:331-337.
- Li XQ, Munkholm A; for the Copenhagen Child Cohort Study Group, Larsen M, Munch IC. Choroidal thickness in relation to birth parameters in 11- to 12-year-old children: the Copenhagen Child Cohort 2000 Eye Study. *Invest Ophthalmol Vis Sci*. 2014;56:617-624.
- Malmqvist L, Li XQ, Eckmann CL, et al. Optic disc drusen in children: The Copenhagen Child Cohort 2000 Eye Study. *J Neuroophthalmol*. 2018;38:140-146.
- Li XQ, Larsen M, Munch IC. Subfoveal choroidal thickness in relation to sex and axial length in 93 Danish university students. *Invest Ophthalmol Vis Sci*. 2011;52:8438-8441.
- Falck A, Laatikainen L. White spots in the central fundus in diabetic children and adolescents. *Acta Ophthalmol (Copenh)*. 1992;70:243-247.
- Nielsen NV. The normal fundus, VI: the variation of fundus elements in relation to age and sex assessed by colour and filter fundus photography in clinically healthy subjects without ophthalmoscopic changes. *Acta Ophthalmol (Copenh)*. 1985;63:467-469.

22. Pedersen HR, Gilson SJ, Dubra A, Munch IC, Larsen M, Baraas RC. Multimodal imaging of small hard retinal drusen in young healthy adults. *Br J Ophthalmol*. 2018;102:146-152.
23. Seddon JM, Reynolds R, Rosner B. Peripheral retinal drusen and reticular pigment: association with CFHY402H and CFHrs1410996 genotypes in family and twin studies. *Invest Ophthalmol Vis Sci*. 2009;50:586-591.
24. Domalpally A, Clemons TE, Danis RP, et al.; Writing Committee for the Optos PERipheral RetinA (OPERA) Study. Peripheral retinal changes associated with age-related macular degeneration in the Age-Related Eye Disease Study 2: Age-Related Eye Disease Study 2 Report Number 12 by the Age-Related Eye Disease Study 2 Optos PERipheral RetinA (OPERA) Study Research Group. *Ophthalmology*. 2017;124:479-487.
25. Joachim NL, Mitchell P, Kifley A, Wang J. Incidence progression, and associated risk factors of medium drusen in age-related macular degeneration: findings from the 15-year follow-up of an Australian cohort. *JAMA Ophthalmol*. 2015;133:698-705.
26. Jonasson F, Arnarsson A, Sasaki H, Peto T, Sasaki K, Bird AC. The prevalence of age-related maculopathy in Iceland: Reykjavik Eye Study. *Arch Ophthalmol*. 2003;121:379-385.
27. Margolis R, Spaide RE. A pilot study of enhanced depth imaging optical coherence tomography of the choroid in normal eyes. *Am J Ophthalmol*. 2009;147:811-815.
28. Ko A, Cao S, Pakzad-Vaezi K, et al. Optical coherence tomography-based correlation between choroidal thickness and drusen load in dry age-related macular degeneration. *Retina*. 2013;33:1005-1010.
29. Mrejen S, Spaide RE. The relationship between pseudodrusen and choroidal thickness. *Retina*. 2014;34:1560-1566.
30. Camacho P, Dutra-Medeiros M, Cabral D, Silva R. Outer retina and choroidal thickness in intermediate age-related macular degeneration: reticular pseudodrusen findings. *Ophthalmic Res*. 2018;59:212-220.
31. Switzer DW Jr, Mendonca LS, Saito M, Zweifel SA, Spaide RE. Segregation of ophthalmoscopic characteristics according to choroidal thickness in patients with early age-related macular degeneration. *Retina*. 2012;32:1265-1271.
32. Wang JJ, Mitchell P, Smith W. Refractive error and age-related maculopathy: the Blue Mountains Eye Study. *Invest Ophthalmol Vis Sci*. 1998;39:2167-2171.
33. Lavanya R, Kawasaki R, Tay WT, et al. Hyperopic refractive error and shorter axial length are associated with age-related macular degeneration: the Singapore Malay Eye Study. *Invest Ophthalmol Vis Sci*. 2010;51:6247-6252.
34. Ikram MK, van Leeuwen R, Vingerling JR, Hofman A, de Jong PT. Relationship between refraction and prevalent as well as incident age-related maculopathy: the Rotterdam Study. *Invest Ophthalmol Vis Sci*. 2003;44:3778-3782.
35. Ikuno Y, Tano Y. Retinal and choroidal biometry in highly myopic eyes with spectral-domain optical coherence tomography. *Invest Ophthalmol Vis Sci*. 2009;50:3876-3880.
36. Cheung CMG, Lee WK, Koizumi H, Dansingani K, Lai TYY, Freund KB. Pachychoroid disease. *Eye (Lond)*. 2019;33:14-33.
37. Leys A, Proesmans W, Van Damme-Lombaerts R, Van Damme B. Specific eye fundus lesions in type II membranoproliferative glomerulonephritis. *Pediatr Nephrol*. 1991;5:189-192.
38. Stone EM, Lotery AJ, Munier FL, et al. A single EFEMP1 mutation associated with both Malattia Leventinese and Doyme honeycomb retinal dystrophy. *Nat Genet*. 1999;22:199-202.