



**Citalopram and the KCNE1 D85N variant
a case report on the implications of a genetic modifier**

Marstrand, Peter; Christensen, Alex Hørby; Bartels, Emil Daniel; Theilade, Juliane

Published in:
European heart journal. Case reports

DOI:
[10.1093/ehjcr/yty106](https://doi.org/10.1093/ehjcr/yty106)

Publication date:
2018

Document version
Publisher's PDF, also known as Version of record

Document license:
[CC BY-NC](https://creativecommons.org/licenses/by-nc/4.0/)

Citation for published version (APA):
Marstrand, P., Christensen, A. H., Bartels, E. D., & Theilade, J. (2018). Citalopram and the KCNE1 D85N variant: a case report on the implications of a genetic modifier. *European heart journal. Case reports*, 2(4), yty106. <https://doi.org/10.1093/ehjcr/yty106>

Citalopram and the KCNE1 D85N variant: a case report on the implications of a genetic modifier

Peter Marstrand^{1*}, Alex Hørby Christensen^{1,2}, Emil Daniel Bartels³, and Juliane Theilade¹

¹Department of Cardiology, Herlev-Gentofte Hospital, University Hospital Copenhagen, Herlev Ringvej 75, 2730 Copenhagen, Denmark; ²Department of Cardiology, Rigshospitalet, University Hospital Copenhagen, Denmark; and ³Department of Clinical Biochemistry, Rigshospitalet, University Hospital Copenhagen, Denmark

Received 4 April 2018; accepted 5 September 2018; online publish-ahead-of-print 26 September 2018

Background

Prolongation of the QT interval on the electrocardiogram is clinically important due to the association with an increased risk of sudden cardiac death. A long QT interval may be genetically determined (congenital long QT syndrome) or be drug-induced long QT syndrome e.g. caused by pharmaceutical drugs and electrolyte imbalances.

Case summary

In this report, we describe the case a 54-year-old woman, who presented with syncope. At presentation, the QTc interval was markedly prolonged, and she was admitted for observation under telemetry. The following day the patient had experienced a near syncope during an episode of 18 s of Torsade de Pointes (TdP). At the time of TdP, the potassium level (3.4 mmol/L) was mildly reduced, and the ECG showed a QTc interval of 640 ms. In spite of correction of hypokalaemia and discontinuation of the possibly LQTS-inducing drug citalopram the QTc duration remained intermittently prolonged. A transthoracic echocardiogram and a recent coronary angiogram were normal. The patient received an implantable cardioverter-defibrillator. Subsequent genetic testing identified a heterozygous KCNE1 p.D85N (c.253G>A) variant, a known QT modifier with a population prevalence of 1.3%.

Discussion

We conclude that the combination of a commonly prescribed antidepressant, discrete hypokalaemia, and a common KCNE1 QT modifier may cause severe QTc prolongation and life-threatening arrhythmia.

Keywords

Acquired long QT syndrome • Case report • Precision medicine • Genetics ventricular arrhythmias • Torsade de Pointes and KCNE1 p.Asp85Asn (c.253G>A)

Learning points

- Patients with a KCNE1 D85N variant should avoid reversible risk factors for drug-induced long QT syndrome (diLQTS).
- The finding of a KCNE1 D85N variant can be used to determine whether the relatives share the same increased risk of diLQTS.

Introduction

Prolongation of the QTc interval on electrocardiogram (ECG) is associated with an increased risk of ventricular arrhythmias and sudden cardiac death.¹ QTc prolongation results from dysfunction of cardiac ion channels; predominantly altered function of cardiac potassium (I_{kr} and I_{ks}) or cardiac sodium channels (I_{na}) may elicit the phenotype of the long QT syndrome.² In the congenital form of long

* Corresponding author. Tel: +45 3868 6674, Email: pmarstrand@hotmail.com. This case report was reviewed by Rami Riziq Yousef Abumualeq, Tor Biering-Sørensen, Mark Philip Cassar, Peysh A. Patel, and Christian Fielder Camm.

© The Author(s) 2018. Published by Oxford University Press on behalf of the European Society of Cardiology.

This is an Open Access article distributed under the terms of the Creative Commons Attribution Non-Commercial License (<http://creativecommons.org/licenses/by-nc/4.0/>), which permits non-commercial re-use, distribution, and reproduction in any medium, provided the original work is properly cited. For commercial re-use, please contact journals.permissions@oup.com

QT syndrome (cLQTS), the ion channels are dysfunctional due to inherited mutations² but the same ion channels can also be affected by numerous drugs and hypokalaemia.³ Drug-induced long QT syndrome (diLQTS) is mainly caused by drugs affecting the promiscuous hERG channel.⁴ However, recent studies have also identified an additional underlying genetic disposition or susceptibility to diLQTS; ~30% carry a mutation in the *KCNQ1*, *KCNH2*, *SCN5A*, *KCNE1*, or *KCNE2* genes.⁵ These patients can be perceived as having as a subclinical form of cLQTS, which will only be expressed when the I_{kr} current is exposed to a blocking agent. The identification of a disease-causing or a susceptibility inducing mutation may be useful in counselling the proband and relatives at possible risk.

Timeline

Timeline for hospitalization in 2016

Time	Event
10 months prior	Started citalopram 20 mg/day for depression
3 months prior (in hospital for 2 days)	Hospitalised due to dizziness and headache. An MRI identified an ischaemic lesion in the internal capsule. No sequelae
Hospitalization, Day 0	Malignant syncope, QTc interval at admission 490 ms
In hospital, +1 day	QTc interval = 640 ms. 18 s of Torsade de Pointes. Patient felt dizzy but remained conscious during the episode
In hospital, +3 days	Antidepressant was switched from citalopram to the non-QT-prolonging antidepressant sertraline
In hospital, +7 days	Normalization of QT-interval, QTc = 450 ms
In hospital, +9 days	Implantation of implantable cardioverter-defibrillator

Case presentation

A 54-year-old woman was brought to the emergency department after a syncope at home. The patient had been cleaning the barbecue in the garden when she felt 'hard heart beats' and passed out without further warning. The patient had no memory of the incident that had resulted in a mild head trauma.

Her past medical history was remarkable for deep vein thrombosis (~10 years earlier), ankylosing spondylitis, depression, and a recent transient ischaemic attack (TIA). Approximately 5 years earlier the patient had undergone a coronary angiogram following an episode of chest pains. The angiogram had identified no atheromatosis. Cardiovascular risk factors encompassed hypertension, well-controlled hypercholesterolaemia, and depression. The patient had

never smoked and did not have diabetes or a family history of heart disease or sudden premature death. The physical examination, including a cardiac and neurological examination, showed no abnormalities.

At admission, the patient was prescribed the following: citalopram 40 mg/day, adalimumab 40 mg subcutaneously/2 weeks (for ankylosing spondylitis), paracetamol p.n. 1 g max 4 times/day, enalapril 10 mg/day, atorvastatin 40 mg/day, and clopidogrel 75 mg/day.

A CT scan of the cerebrum showed no cerebral damage. The ECG showed sinus rhythm and QTc interval +600 ms (Figure 1A). Blood tests were largely normal [serum: potassium 3.4 mmol/L (ref 3.5–4.6 mmol/L) and magnesium, 1.01 mmol/L (ref 0.71–0.94 mmol/L)]. Haemoglobin, leucocytes, creatinine, sodium, alanine transaminase, basic phosphatase, and C reactive protein were within normal ranges. Also, troponin I and D-dimer were not elevated. A transthoracic echocardiography was performed, showing no abnormalities.

After 1 day of telemetry, an episode of self-terminating Torsade de Pointes (TdP) lasting 18 s was recorded (Figure 1B). The patient was conscious during the episode but reported feeling dizzy and that symptoms were similar to what she had felt before her syncope the previous day. Empirical treatment with 16 mmol intravenous magnesium and 3 g of potassium chloride was immediately given. Serum potassium increased to 3.8 mmol/L on the following day but the QTc interval remained prolonged (640 ms).

The case was conferred with a psychiatrist, and citalopram was tapered under simultaneous rapid titration of sertraline to 100 mg/day. Citalopram was completely discontinued from Day 5. At 1 week from admission, the QTc duration was within normal range (Figure 1C, QTc 450 ms), but the QTc duration fluctuated and was found outside normal range at Day 9 (600 ms), before normalization at Day 15 (460 ms). Earlier ECGs were available for evaluation; previous recordings showed QTc between 440 and 580 ms (Figure 1D).

At this point, it was considered possible that the patient was afflicted with the congenital long QT syndrome; even though two known triggers of induced QTc prolongation were present, correction of these did not clearly normalize QTc duration. In addition, previous ECG recordings clearly documented intermittent, significant QTc prolongation over an extended time period. On Day 8 treatment with atenolol 25 mg was initialized. On Day 9, an implantable cardioverter-defibrillator (VI-ICD) was implanted. Genetic testing was ordered and the proband was found to be heterozygote carrier of the *KCNE1* D85N (c.253G>A) variant.

The patient was closely followed the first 6 months after the TdP episode and seen monthly in the out-patient clinic. Currently, the patient is scheduled for follow-up with her cardiologist yearly, her ICD is interrogated in clinic every 6 months and by remote monitoring every 4 months. In 18 months of follow-up, the ICD has not registered any arrhythmias.

Discussion

We present a patient with syncope, severe QTc prolongation, and Torsades de Pointes ventricular tachycardia during treatment with citalopram. The patient was a heterozygous carrier of a *KCNE1*

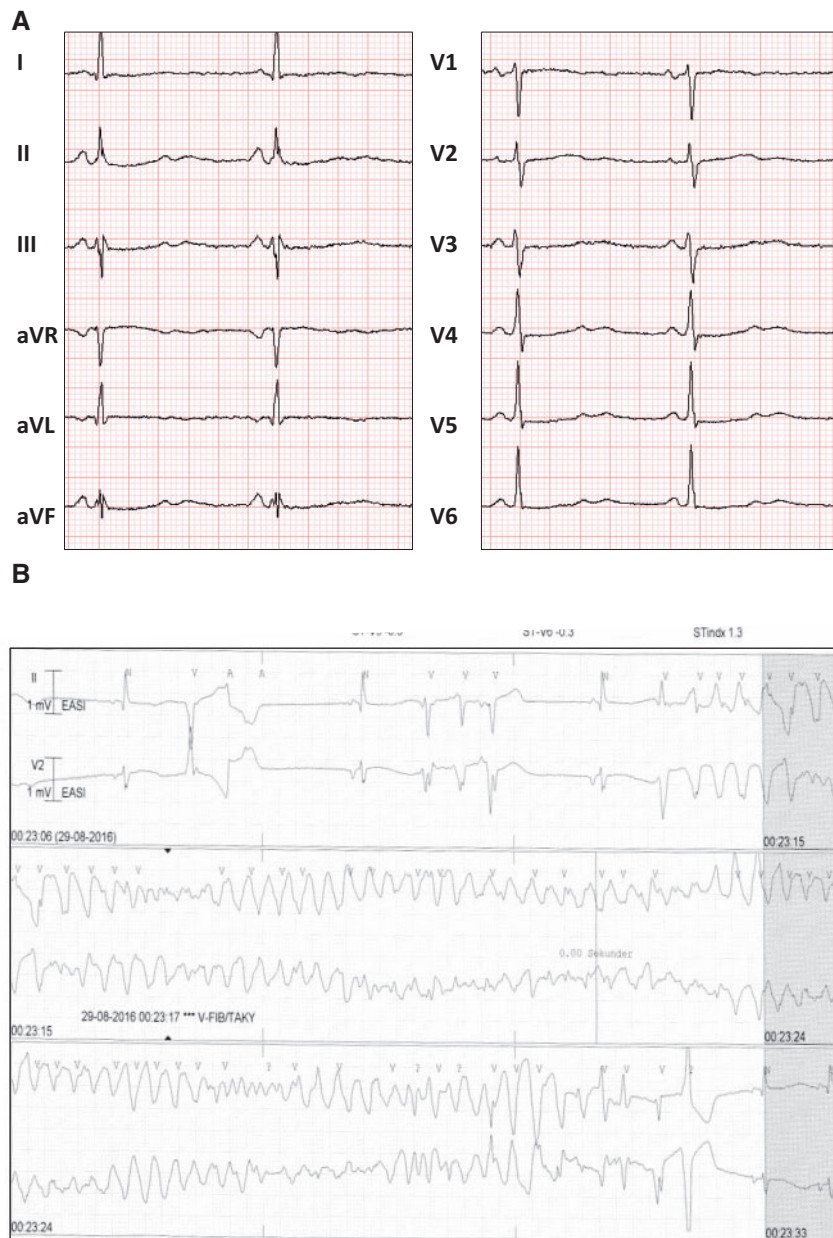


Figure 1 (A) Twelve-lead electrocardiogram on admission showing prolonged QTc interval (QTc = +600 ms). (B) Telemetry print on Day 2 of admission showing Torsade de Pointes. (C) Electrocardiogram examples during admission with severely prolonged QTc intervals. (D) Historical electrocardiograms used in the evaluation of the patient.

D85N (c.253G>A) variant. The gene encodes for the β -subunit of the voltage-gated potassium channels and the D85N (c.253G>A) variant has been associated with an increase in QTc interval of ~ 8 ms.⁶ Also, the variant is over-represented in patients with diLQTS⁷ and is a known modifier gene in cLQTS, type one.⁸ Distinguishing between diLQTS and cLQTS is challenging as there is a significant overlap in the phenotype including QTc duration on the ECG.⁵ One study reported that 40% of patients with diLQTS may have an underlying cLQTS diagnosis.⁹ When applying the

cLQTS score on our patient, she would receive three points in total (two points for TdP and one for syncope). Three points would categorize the patients as having 'intermediate probability of cLQTS'.¹ However, due to the reversible QT-prolongation, which normalized after discontinuing citalopram and correction of mild hypokalaemia, she was considered to have diLQTS. Citalopram has a half-life of 36 h, and the patient's QTc interval was within normal range 4 days (Day 7) after substitution of citalopram with sertraline. Also, we found that on Day 9, the QTc

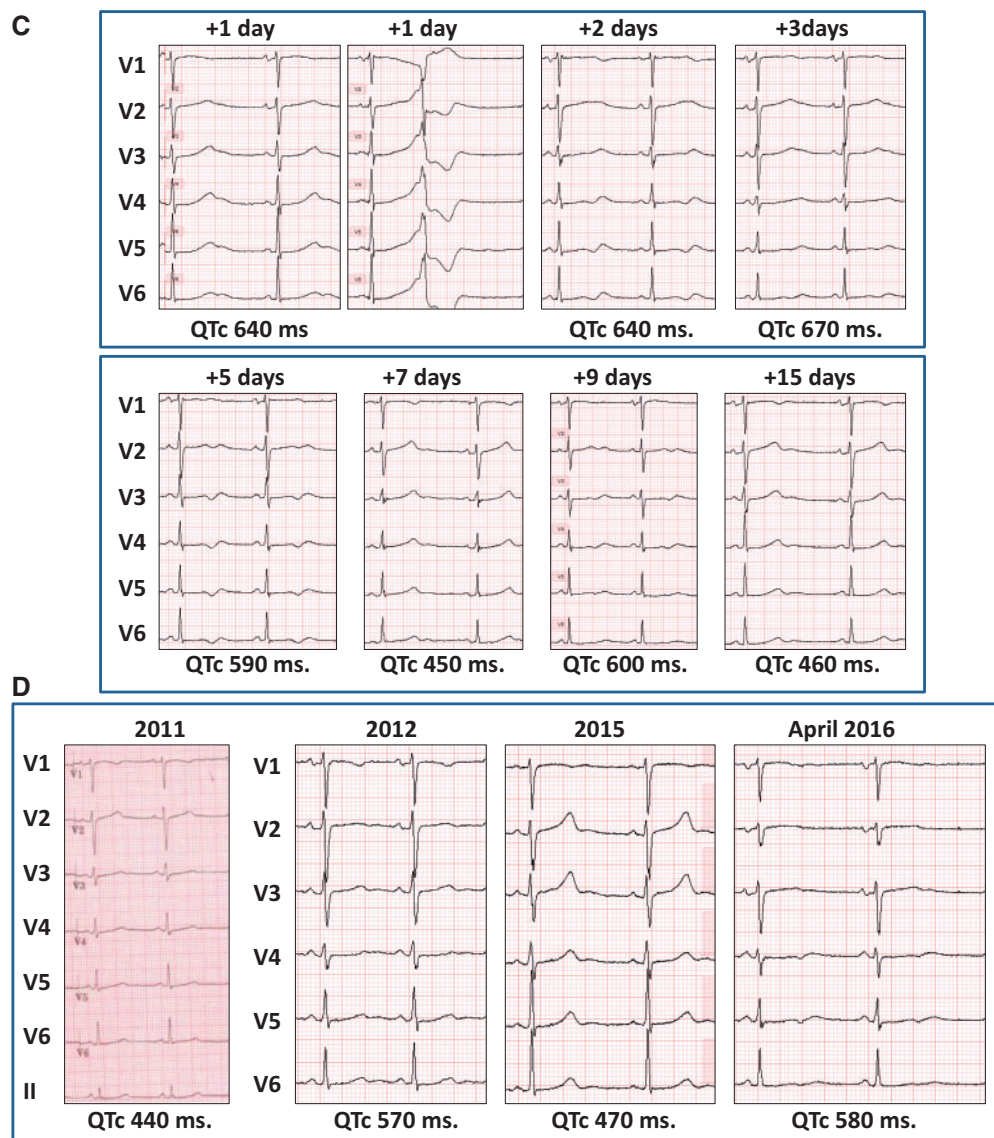
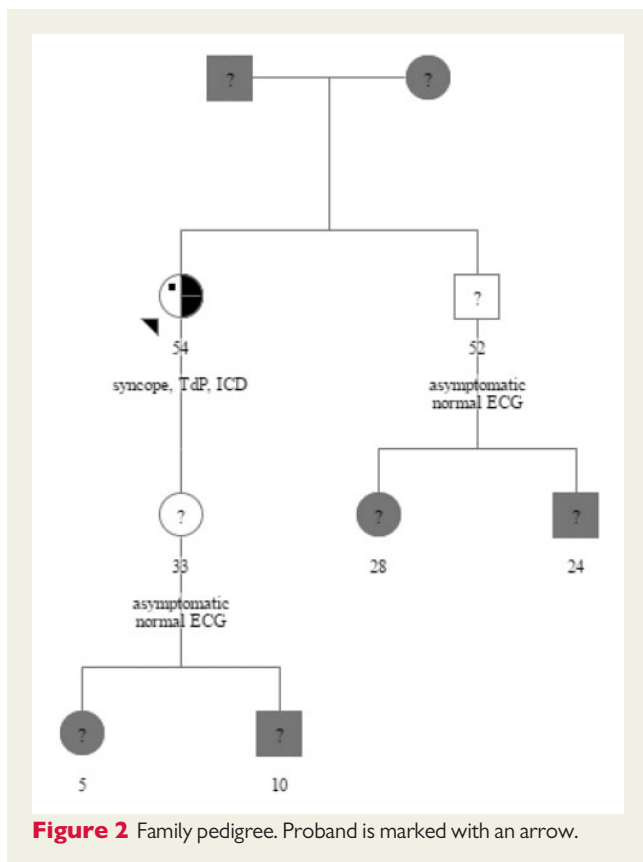


Figure I Continued.

interval was prolonged to 600 ms, which suggests that the QT-prolongation observed on the ECGs from this patient was not solely explained by treatment with citalopram. Consequently, we advised the patient to avoid all QTc prolonging drugs in the future. According to 2015 ESC guidelines, implantation of an ICD in cases with drug-related pro-arrhythmia, should rely on an individual evaluation (Class IIa, Level C).¹⁰ Based on the serial ECG findings in our patient, we remained unassured that her risk of future malignant arrhythmias would be sufficiently controlled solely by avoiding QTc prolonging drugs, therefore, an ICD was implanted. This is supported by the only recent study with long-term follow-up on diLQTS patients with ICDs, where they reported that 44% of patients with an ICD following aborted sudden cardiac death due to diLQTS received appropriate shocks during a mean follow-up of 84 ± 55 months.¹¹ In contrast, among patients with cLQTS, only

18–28% of patients with cLQTS experience appropriate shocks by their ICD.^{12,13} Though device programming may differ between studies and account for some of this observed difference, one may speculate that we at this point only identify the most malignant subgroup of diLQTS patients since their subsequent risk of ICD shocks is relatively high.

Different drug classes can cause diLQTS and TdP; a frequently updated online tool is available for risk assessment by drug type for physicians and patients.¹⁴ Citalopram is listed in the category of highest risk ('Known Risk of TdP'). Moreover, a Danish study associated citalopram with a 30% increase in risk for out-of-hospital cardiac arrest.¹⁵ This data supported our concern that citalopram may have elicited the arrhythmias observed in this patient. The genetic test result supported the notion that the patient was at increased risk of drug-induced ECG alterations and hereby at risk of malignant arrhythmias.



However, it should be noted that the minor allele frequency of *KCNE1* D85N (c.253G>A) occurs with an approximate 1.3% percent frequency in the Danish background population. Also, the patient had several other risk factors for dILQTS: female sex, age, pre-citalopram QTc interval in the high-normal range, and a slightly reduced potassium level. The individual contribution of these distinct risk factors is probably impossible to estimate in the clinical setting. At this point genetic testing and counselling should be tailored to the individual. In this family, one could interpret the findings as the proband as carrying a genetic susceptibility to drug-induced arrhythmias and screen family members accordingly (Figure 2).

Supplementary material

Supplementary material is available at *European Heart Journal - Case Reports* online.

Funding

FUKAP foundation and the Danish Heart Foundation (Grant 17-R115-A7532-22065).

Slide sets: A fully edited slide set detailing this case and suitable for local presentation is available online as [Supplementary data](#).

Consent: The author/s confirm that written consent for submission and publication of this case report including image(s) and associated text has been obtained from the patient in line with COPE guidance.

Conflict of interest: none declared.

References

- Schwartz PJ, Moss AJ, Vincent GM, Crampton RS. Diagnostic criteria for the long QT syndrome. An update. *Circulation* 1993;**88**:782–784.
- Tester DJ, Ackerman MJ. Genetics of long QT syndrome. *Methodist Debaquey Cardiovasc J* 2014;**10**:29–33.
- Roden DM. Drug-induced prolongation of the QT interval. *N Engl J Med* 2004;**350**:1013–1022.
- Sanguinetti MC, Jiang C, Curran ME, Keating MT. A mechanistic link between an inherited and an acquired cardiac arrhythmia: HERG encodes the IKr potassium channel. *Cell* 1995;**81**:299–307.
- Itoh H, Crotti L, Aiba T, Spazzolini C, Denjoy I, Fressart V, Hayashi K, Nakajima T, Ohno S, Makiyama T, Wu J, Hasegawa K, Mastantuono E, Dagradi F, Pedrazzini M, Yamagishi M, Berthet M, Murakami Y, Shimizu W, Guicheney P, Schwartz PJ, Horie M. The genetics underlying acquired long QT syndrome: impact for genetic screening. *Eur Heart J* 2016;**37**:1456–1464.
- Newton-Cheh C, Eijgelsheim M, Rice KM, de Bakker PIW, Yin X, Estrada K, Bis JC, Marcante K, Rivadeneira F, Noseworthy PA, Sotoodehnia N, Smith NL, Rotter JI, Kors JA, Witteman JCM, Hofman A, Heckbert SR, O'Donnell CJ, Uitterlinden AG, Psaty BM, Lumley T, Larson MG, Stricker BHC. Common variants at ten loci influence QT interval duration in the QTGEN Study. *Nat Genet* 2009;**41**:399–406.
- Kaab S, Crawford DC, Sinner MF, Behr ER, Kannankeril PJ, Wilde AAM, Bezzina CR, Schulze-Bahr E, Guicheney P, Bishopric NH, Myerburg RJ, Schott J-J, Pfeufer A, Beckmann B-M, Martens E, Zhang T, Stallmeyer B, Zumhagen S, Denjoy I, Bardai A, Van Gelder IC, Jamshidi Y, Dalageorgou C, Marshall V, Jeffery S, Shakir S, Camm AJ, Steinbeck G, Perz S, Lichtner P, Meitinger T, Peters A, Wichmann H-E, Ingram C, Bradford Y, Carter S, Norris K, Ritchie MD, George AL, Roden DM. A large candidate gene survey identifies the *KCNE1* D85N polymorphism as a possible modulator of drug-induced torsades de pointes. *Circ Cardiovasc Genet* 2012;**5**:91–99.
- Nishio Y, Makiyama T, Itoh H, Sakaguchi T, Ohno S, Gong Y-Z, Yamamoto S, Ozawa T, Ding W-G, Toyoda F, Kawamura M, Akao M, Matsuura H, Kimura T, Kita T, Horie M. D85N, a *KCNE1* polymorphism, is a disease-causing gene variant in long QT syndrome. *J Am Coll Cardiol* 2009;**54**:812–819.
- Itoh H, Sakaguchi T, Ding W-G, Watanabe E, Watanabe I, Nishio Y, Makiyama T, Ohno S, Akao M, Higashi Y, Zenda N, Kubota T, Mori C, Okajima K, Haruna T, Miyamoto A, Kawamura M, Ishida K, Nagaoka I, Oka Y, Nakazawa Y, Yao T, Jo H, Sugimoto Y, Ashihara T, Hayashi H, Ito M, Imoto K, Matsuura H, Horie M. Latent genetic backgrounds and molecular pathogenesis in drug-induced long-QT syndrome. *Circ Arrhythm Electrophysiol* 2009;**2**:511–523.
- Priori SG, Blomström-Lundqvist C, Mazzanti F, Blom N, Borggrefe M, Camm J, Elliott PM, Fitzsimons D, Hatala R, Hindricks G, Kirchhof P, Kjeldsen K, Kuck K-H, Hernandez-Madrid A, Nikolauou N, Norekvål TM, Spaulding C, Van Veldhuisen DJ. 2015 ESC guidelines for the management of patients with ventricular arrhythmias and the prevention of sudden cardiac death. *Rev Esp Cardiol (Engl Ed)* 2016;**69**:176.
- Mönnig G, Köbe J, Löher A, Wasmer K, Milberg P, Zellerhoff S, Pott C, Zumhagen S, Radu R, Scheld HH, Haverkamp W, Schulze-Bahr E, Eckardt L. Role of implantable cardioverter defibrillator therapy in patients with acquired long QT syndrome: a long-term follow-up. *Europace* 2012;**14**:396–401.
- Horner JM, Kinoshita M, Webster TL, Haglund CM, Friedman PA, Ackerman MJ. Implantable cardioverter defibrillator therapy for congenital long QT syndrome: a single-center experience. *Heart Rhythm* 2010;**7**:1616–1622.
- Schwartz PJ, Spazzolini C, Priori SG, Crotti L, Vicentini A, Landolina M, Gasparini M, Wilde AAM, Knops RE, Denjoy I, Toivonen L, Monnig G, Al-Fayyadh M, Jordaens L, Borggrefe M, Holmgren C, Brugada P, De Roy L, Hohnloser SH, Brink PA. Who are the long-QT syndrome patients who receive an implantable cardioverter-defibrillator and what happens to them? Data from the European Long-QT Syndrome Implantable Cardioverter-Defibrillator (LQTS ICD) Registry. *Circulation* 2010;**122**:1272–1282.
- Woosley RL, Heise CW, Romero KA. QTdrugs List, AZCERT, Inc. 1822 Innovation Park Dr., Oro Valley, AZ 85755. www.Crediblemeds.org (13 November 2017).
- Weeke P, Jensen A, Folke F, Gislason GH, Olesen JB, Andersson C, Fosbøl EL, Larsen JK, Lippert FK, Nielsen SL, Gerds T, Andersen PK, Kanters JK, Poulsen HE, Pehrson S, Køber L, Torp-Pedersen C. Antidepressant use and risk of out-of-hospital cardiac arrest: a nationwide case-time-control study. *Clin Pharmacol Ther* 2012;**92**:72–79.