



Traumatic bicycle handlebar hernia in children a systematic review

Schmidt, Magnus Strøh; Rosenberg, Jacob; Tolver, Mette Astrup

Published in:
Ugeskrift for Laeger

Publication date:
2018

Document version
Publisher's PDF, also known as Version of record

Document license:
[CC BY-NC](#)

Citation for published version (APA):
Schmidt, M. S., Rosenberg, J., & Tolver, M. A. (2018). Traumatic bicycle handlebar hernia in children: a systematic review. *Ugeskrift for Laeger*, 180(8), [A5433].

Traumatic bicycle handlebar hernia in children: a systematic review

Magnus Strøh Schmidt¹, Jacob Rosenberg² & Mette Astrup Tolver²

ABSTRACT

INTRODUCTION: This is a systematic review of existing literature on the diagnostic modalities and treatment of traumatic abdominal wall hernia caused by bicycle handlebar injury in children.

METHODS: A systematic literature search was conducted covering incidents involving children below 17 years of age. Data were extracted regarding gender, age, diagnostic modality, timing of surgery, location of hernia, associated injuries, management and recurrence of hernia.

RESULTS: A total of 62 cases of handlebar hernia were included in the systematic review. CT scan was the most frequently used final diagnostic modality (52%) followed by ultrasonography (13%), explorative laparotomy (5%) and diagnostic laparoscopy (5%). Coexisting intraabdominal injuries were present in 57% of all hernias located in the upper abdomen. Open surgical repair was the preferred treatment of choice (85%). Laparoscopic suturing was performed in one study. Six cases of handlebar hernia were treated conservatively. No cases of recurrence of hernia were reported in any of the cases.

CONCLUSIONS: Traumatic abdominal wall hernia can be visualized by ultrasonography, but CT scan is often used as the final diagnostic modality because of the risk of associated intra-abdominal injuries. Open surgical repair in layers or laparoscopic suturing during diagnostic laparoscopy may be appropriate in managing traumatic abdominal wall hernias in children. Non-surgical management has been described, but available data do not support a general recommendation for a non-surgical approach.

Abdominal trauma among children accounts for approximately 5% of all admissions to paediatric emergency departments [1]. These admissions include bicycle accidents where a fall can cause a collision between the abdomen and the bike stem, or, as in 70% of the cases, the end of the handlebar [2]. Besides the risk of lesions to internal abdominal organs, a traumatic abdominal wall hernia can be formed. Due to a higher elasticity of the skin compared with abdominal fascia and muscle, collision of a bicycle handlebar with the abdomen can cause rupture of the fascia without causing a skin lesion, thus producing a traumatic hernia. This is often referred to as "handlebar hernia". It is a rare injury that may result in prolonged pain and risk of bowel strangu-

lation if the condition is not diagnosed and treated timely.

The aim of this review was to evaluate the diagnostic modalities and treatment of bicycle handlebar hernia based on reported evidence. We provide a systematic review of the existing literature on bicycle handlebar injuries in children below 17 years of age.

METHODS

The reports were reviewed as recommended by the Preferred Reporting Items for Systematic Reviews and Meta-analyses (PRISMA) guideline [3]. A systematic literature search was conducted in PubMed, Embase, CINAHL and the Cochrane Library Database in September 2017. The search term "Handlebar Hernia" was used. In PubMed, no search filters were applied to ensure that no studies were overlooked. A similar search term and method was used in Embase, CINAHL and the Cochrane Library Database. All studies were screened by title and abstract. Duplicates, irrelevant topics and non-English articles were excluded. The remaining studies were read in full, including the references to identify additional relevant studies (Figure 1). All studies presenting cases of traumatic abdominal wall hernia caused by bicycle handlebar in children below 17 years of age were included, regardless of study design. Data on study information (authors and year of publication) and study results (gender, age, diagnostic modality, timing of surgery, location of hernia, associated injuries, management, and recurrence of hernia) were extracted from the available studies [1, 2, 4-46]. The results of the included studies were presented to provide an overview

SYSTEMATIC REVIEW

1) Health, University of Copenhagen
2) Department of Surgery, Herlev Hospital, Denmark

Dan Med J
2018;65(1):A5433



KEY POINTS

Traumatic abdominal wall hernia caused by handlebar injuries most often occurs in adolescent boys
CT is preferable for evaluation of the risk of intraabdominal injuries.
Ultrasonography can be used when no suspicion of intraabdominal damage exists
Associated intra-abdominal injuries are more frequent in upper abdominal hernias
Open surgical repair with sutured closure of all layers or laparoscopic suturing is recommended for managing these injuries
A non-surgical approach has been carried out with success in few cases, but available data do not support a general recommendation for non-surgical management.

FIGURE 1

Preferred Reporting Items for Systematic Reviews and Meta-analyses (PRISMA) flow diagram. A search through the included study references in order to find and include more cases (snowball search) [3].

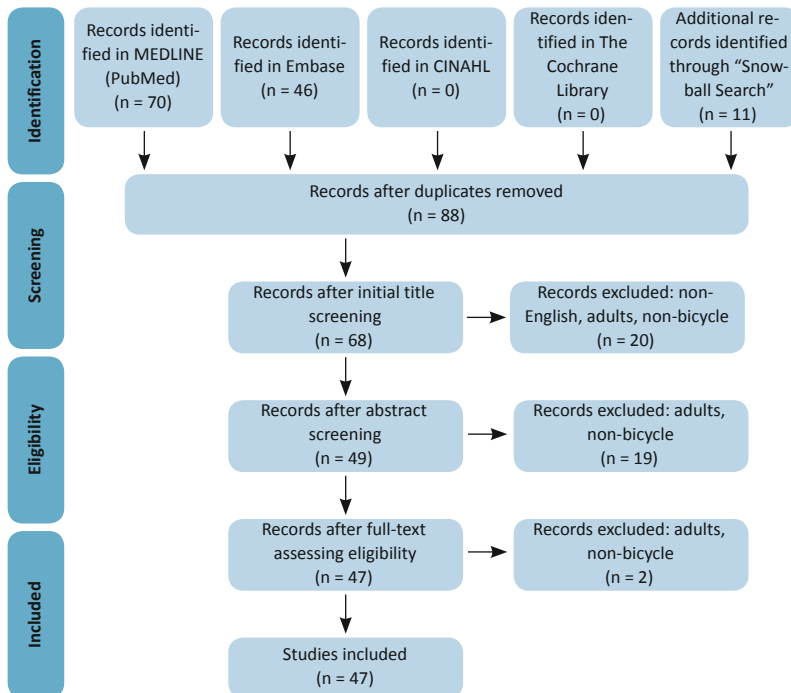
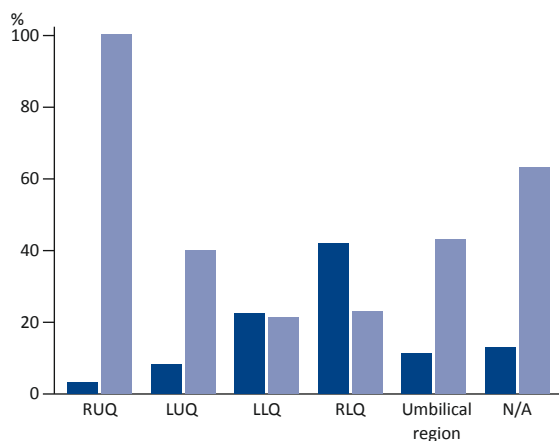


FIGURE 2

Anatomical distribution of hernias (■) and proportion of associated intra-abdominal injuries (■).



LLQ = left lower quadrant; LUQ = left upper quadrant; N/A = not available; RLQ = right lower quadrant; RUQ = right upper quadrant.

of the reported cases followed by a discussion of the reported diagnostic modalities and treatment options for bicycle handlebar hernia in children.

RESULTS

The systematic literature search identified 47 reports in-

cluding a total of 62 cases of handlebar hernia with the first reported case dating back to 1964 (Table 1). The median age was 11 years (range: 4-15 years) with a male-to-female ratio of approximately 9:1. The suspicion of traumatic abdominal wall hernia often arises during the clinical-anamnestic exam performed in patients having suffered a blunt abdominal trauma [34]. The typical clinical presentation of traumatic abdominal wall hernia may include a hyperaemic area, bruising and ecchymosis of the abdominal wall with a fluctuating bulge under the skin.

A characteristic ring-shaped “handlebar sign” is often present on the skin and may be used as a prognostic sign of internal injuries. One study found that 45% of the patients with life-threatening intra-abdominal injuries had the “handlebar sign” on the abdominal wall [23]. The present review found that 100% of the hernias in the right upper quadrant and 40% in the left upper quadrant had associated intra-abdominal injuries, whereas only 21% in the left lower quadrant and 23% in the right lower quadrant had intra-abdominal injuries (Figure 2). Overall, associated intra-abdominal injuries were reported in 26% of the cases. CT, being used as a final diagnostic modality in 52% of the cases, was the most common diagnostic modality. In 15% of the cases, a diagnosis was given based solely on the physical examination. Ultrasonography was used in the diagnostic process in 26% of the cases, but was used as the final diagnostic modality only in 13% of the cases.

Open surgical repair of the handlebar hernia was the treatment of choice in 85% of the cases. Laparoscopic suturing was used in one study [30]. In two cases, hernia was found during the initial explorative laparotomy for intestinal perforation and subsequently managed by internal repair without a separate skin incision [23]. Mesh was used only in one of the reported cases [14]. Almost two thirds (66%) of the patients who were treated with surgical repair had surgery immediately after presentation (Figure 3). There was no reported recurrence of hernia in any of the cases.

A total of six cases of traumatic abdominal wall hernia were treated conservatively (non-surgically) [20, 22, 23, 38, 46]. In all six cases, only local tenderness or pain was present on the site where the hernia protruded. The location of hernia was heterogeneously distributed in the left lower quadrant, the right lower quadrant and the left upper quadrant. In order to achieve the diagnosis, a CT was reported to have been used in five out of the six cases. Sizes of the fascia defects were described in three cases and measured 1-4 cm. In all six cases, no concurrent intra-abdominal injuries were present on investigation. An abdominal compression corset was used in two of the cases. In three cases, the defects in the abdominal wall were resolved completely within four



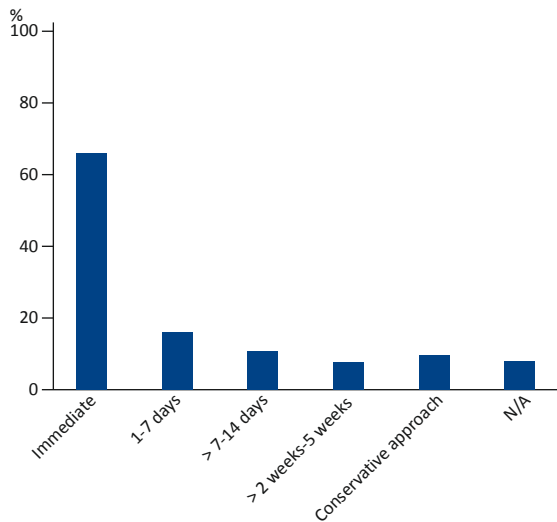
TABLE 1

Reference	Sex: n	Age, yrs	Final diagnostic modality	Timing of surgery	Location of hernia	Associated injuries	Management
Roberts, 1964 [47]	M: 1 F: 0	9	Physical exam	Immediate	LLQ	None	Open surgical repair
Maunola & Kekomaki, 1965 [48]	M: 0 F: 1	9	Physical exam	Immediate	LLQ	None	Open surgical repair
Herbert & Turner, 1973 [4]	M: 1 F: 0	7	X-ray	+ 3 wks	LLQ	None	Open surgical repair
Dreyfuss et al, 1986 [5]	M: 1 F: 0	11	X-ray	Immediate	Umbilical region/ rectus abdominus	None	Open surgical repair
Peters et al, 1988 [6]	M: 1 F: 0	9	CT scan	Immediate	Umbilical region/ rectus abdominus	Tear in proximal jejunum and mesentery	Open surgical repair
Mitchiner, 1990 [7]	M: 1 F: 0	7	CT scan	Immediate	LUQ	None	Open surgical repair
Damschen et al, 1994 [8]	M: 1 F: 0	5	Physical exam	Immediate	RLQ	None	Open surgical repair
Kubalak, 1994 [9]	M: 1 F: 0	8	Physical exam	+ 1 day	RLQ	Appendectomy	Open surgical repair
Iuchtman et al, 1997 [10]	M: 1 F: 0	7	US	+ 2 days	RLQ	None	Open surgical repair
Perez et al, 1998 [11]	M: 1 F: 0	11	Physical exam	Immediate	LLQ	None	Open surgical repair
Kubota et al, 1999 [12]	M: 1 F: 0	9	CT scan	Immediate	RLQ	None	Open surgical repair
Fraser et al, 2002 [13]	M: 1 F: 0	11	US	+ 1 day	RLQ	None	Open surgical repair
Mancel & Aslam, 2003 [14]	M: 1 F: 0	7	US	Immediate	LLQ	None	Open surgical repair + mesh
Goliath et al, 2004 [15]	M: 1 F: 0	11	CT scan	Immediate	RLQ	None	Open surgical repair
Prada Arias et al, 2004 [16]	M: 1 F: 1	10, 6	US	+ 1 day, + 10 days	RLQ	None (n = 2)	Open surgical repair (n = 2)
Chen et al, 2005 [17]	M: 1 F: 0	9	CT scan	Immediate	RLQ	None	Open surgical repair
Iinuma et al, 2005 [18]	M: 1 F: 0	8	X-ray + CT scan + diagnostic laparoscopy	+ 1 day	RLQ	Appendectomy	Open surgical repair
Matsuo et al, 2007 [20]	M: 1 F: 0	9	CT scan	-	LLQ	None	Conservative
Haimovici et al, 2007 [19]	M: 1 F: 0	15	CT scan	Immediate	Umbilical region/ rectus abdominus	Incarcerated small bowel	Open surgical repair
Mezhir et al, 2007 [21]	M: 1 F: 0	7	CT scan	Immediate	LUQ	Splenic injury, left renal in- jury, hemoperitoneum	Open surgical repair
Litton et al, 2008 [22]	M: 1 F: 0	13	CT scan	-	RLQ	None	Conservative
Narci et al, 2008 [1]	M: 1 F: 0	12	US + X-ray + CT scan	Immediate	RLQ	None	Open surgical repair
Karaman et al, 2009 [23]	M: 0 F: 0 N/A: 3	N/A	N/A, explorative laparotomy	N/A, immediate	Umbilical region/ rectus abdominus, LLQ	Ilium perforation, none (n = 2)	Conservative, Internal repair (n = 2)
Nguyen et al, 2009 [24]	M: 1 F: 0	6	Physical exam	Immediate	LLQ	None	Open surgical repair
Yegane et al, 2010 [26]	M: 1 F: 0	4	US + X-ray + explorative lapa- rotomy	Immediate	Umbilical region/ rectus abdominus	None	Open surgical repair
Tonsi et al, 2010 [25]	M: 1 F: 0	14	CT scan	Immediate	RLQ	Jejunum mesenteric tear, multiple enterotomies	Open surgical repair
van Bommel et al, 2011 [31]	M: 1 F: 0	7	Physical exam	+ 1 wk	RLQ	None	Open surgical repair
Mitchell et al, 2011 [29]	M: 1 F: 0	14	Physical exam	+ 1 day	RLQ	None	Open surgical repair
Rowell & Chin, 2011 [30]	M: 1 F: 0	14	CT scan + diagnostic lapa- roscopy	+ 1 day	RUQ	Colon serosal, mesenteric tear	Laparoscopic assisted Endo Close
Yan et al, 2011 [32]	M: 1 F: 0	8	CT scan	Immediate	RLQ	None	Open surgical repair
Hatti et al, 2011 [28]	M: 1 F: 0	5	US	+ 4 days	LLQ	None	Open surgical repair
Bosemani et al, 2011 [27]	M: 0 F: 2	11, 8	US + CT scan	Immediate, N/A	RLQ, RUQ	Jejunal perforation, lacera- tion of liver and pancreas	Open surgical repair, N/A
Decker et al, 2012 [33]	M: 1 F: 0	13	US + CT scan	Immediate	RLQ	None	Open surgical repair
Rathore et al, 2012 [34]	M: 5 F: 0	15, 15, 13, 9, 11	CT scan	Immediate, + 1 wk	N/A	Caecal wall haematoma, none, duodenal haematoma + pancreatic contusion	Open surgical repair (n = 5)
Thakur et al, 2013 [37]	M: 1 F: 0	9	US	+ 5 wks	RLQ	None	Open surgical repair
Klimek et al, 2013 [36]	M: 0 F: 1 N/A: 1	12, N/A	US + X-ray, N/A	Immediate, N/A	Umbilical region/ rectus abdominus, N/A	None, N/A	Open surgical repair (n = 2)
Upasani & Bouhadiba, 2013 [38]	M: 1 F: 0	12	CT scan	-	LUQ	None	Conservative
Griffin et al, 2013 [35]	M: 1 F: 0	11	CT scan	Immediate	RLQ	None	Open surgical repair
Yaylaci et al, 2014 [39]	M: 1 F: 0	11	US + CT scan	Immediate	LLQ	Jejunal perforation	Open surgical repair
Talutis et al, 2015 [42]	M: 2 F: 1	11, 9, 7	CT scan (n = 3)	Immediate	LLQ, RLQ	None, jejunal contusion, il- eal perforation	Open surgical repair (n = 3)
Angel Buitrago & Lugo-Vicente, 2015 [40]	M: 1 F: 0	14	US + CT scan	Immediate	Umbilical region/ rectus abdom inus	None	Open surgical repair
Hirose et al, 2015 [41]	M: 2 F: 0	14, 13	N/A	Immediate, N/A	LUQ, N/A	Duodenal injury, bladder rupture	Open surgical repair (n = 2)
Deepak et al, 2015 [2]	M: 2 F: 0	12, 12	CT scan	N/A (n = 2)	N/A, RLQ	Jejunal perforation, none	Open surgical repair (n = 2)
Pederiva et al, 2016 [43]	M: 1 F: 0	9	CT scan	+ 1 day	LLQ	Ileal perforation	Open surgical repair
Volpe et al, 2017 [46]	M: 2 F: 0	12, 8	Physical exam + US	-	RLQ	None	Conservative (n = 2)
Ramos-Irizarry et al, 2017 [44]	M: 1 F: 0	11	CT scan	Immediate	RLQ	None	Open surgical repair
Rinaldi et al, 2017 [45]	M: 2 F: 0	12, 13	CT scan + diagnostic lapa- roscopy	Immediate	LLQ, RLQ	None, sigmoid haematoma	Open surgical repair, N/A

F = female; M = male; LLQ = right lower quadrant; LUQ = left upper quadrant; N/A = not available; RLQ = right lower quadrant; RUQ = right upper quadrant; US = ultrasonography.

FIGURE 3

Timing of surgery in included cases.



N/A = not available.

months [20, 22, 23]. One case showed a decrease of the fascia defect from 2 cm to 5 mm within six months [38]. The last two cases diminished in size from 15 mm to 3 mm in 12 months and from 10 mm to 3 mm in two months [46].

DISCUSSION

A paediatric patient with a bicycle handlebar hernia is typically a school-aged boy. Occurrence of intra-abdominal injuries increased significantly with handlebar hernia located in the upper half of the abdomen. CT is often used as the final diagnostic modality, and open surgical repair of the handlebar hernia with layered closure without a mesh was the preferred approach, although successful laparoscopic sutured repair has also been described.

CT is the gold standard as a diagnostic imaging modality in evaluation of abdominal injuries after high-energy blunt trauma in haemodynamically stable children [49]. In the haemodynamically unstable child, an immediate explorative laparotomy is required [49]. Blunt trauma with a bicycle handlebar can be a high-energy or a low-energy trauma and is often an isolated trauma. Thus, in cases with an overall unaffected child and a low-energy trauma in the lower quadrants with a bicycle handlebar, ultrasonography can be used as an alternative. Attention is necessary during investigation as sensitivity and specificity obviously vary between the different modalities used for diagnosing a traumatic abdominal wall hernia. Ultrasonography is of great value but largely operator-dependent. In one study, traumatic abdominal wall hernia was initially misdiagnosed as an

abdominal wall haematoma, possibly due to the lack of ability of the ultrasonography to distinguish between haematoma and a bowel loop as they both may appear hyperechoic [50]. In one case, a hernia was missed during initial physical and ultrasonography examination during the first 48 hours [16]. Ultrasonography may be used to diagnose intra-abdominal injuries by the occurrence of free fluid in the peritoneal cavity. Minimal pelvic free fluid may be physiological in both boys and girls and is present in up to 12% of asymptomatic children without intra-abdominal injuries [51]. In one study, 3.5% of patients with small amounts of pelvic peritoneal fluid had intra-abdominal injuries, whereas 92.3% of patients with free fluid outside the pelvis had organ injury [52].

It is believed that abdominal wall defects can be overlooked during the initial radiographic investigation due to pain and muscle spasms [42]. A plausible reason for delayed initial diagnosing may be delayed herniation with rupture of the abdominal wall due to haematoma or wound infection [8, 28].

Early diagnosing and treatment may hypothetically be associated with less morbidity due to prevention of incarceration and strangulation [31]. Surgery with sutured closure with absorbable suture of all layers after evacuation of subcutaneous haematoma and removal of non-viable tissue was the preferred method in the management of these injuries. Laparoscopically sutured repair may also be an option, especially if diagnostic laparoscopy is performed anyway. Non-surgical treatment was used in four cases, apparently with success. However, in one case only clinical follow-up was performed.

A limitation of this review was that a majority of the included studies were case reports with a short follow-up period, making the risk of recurrence of hernia difficult to assess. Furthermore, there was no consistency in the variables presented.

CONCLUSIONS

Traumatic abdominal wall hernia caused by a bicycle handlebar in children is a rare type of injury. Traumatic abdominal wall hernia can be visualized by ultrasonography, but CT is often used as the final diagnostic modality because of the risk of associated intra-abdominal injuries. Surgical repair of the handlebar hernia with open or laparoscopic suturing can be used. Non-surgical management has been described in selected cases, but the available data do not support a general recommendation for non-surgical management.

CORRESPONDENCE: Magnus Strøgh Schmidt.
E-mail: magnusschmidt@gmail.com

ACCEPTED: 13 November 2017

CONFLICTS OF INTEREST: none. Disclosure forms provided by the authors are available with the full text of this article at www.danmedj.dk

LITERATURE

- Narci A, Sen TA, Koken R. Fascia, muscle and peritoneal rupture without any skin lesion as a result of blunt abdominal trauma – a case report. *Acta Chir Belg* 2008;108:774-6.
- Deepak J, Aravind KL, Shankar G et al. Bicycle handlebar injuries in children: Is "ring sign," an indicator of intra-abdominal organ injuries? *Indian J Child Health* 2015;2:204-9.
- Moher D, Liberati A, Tetzlaff J et al. Preferred reporting items for systematic reviews and meta-analyses: the PRISMA statement. *PLoS Med* 2009;6:e1000097.
- Herbert RJ, Turner FW. Traumatic abdominal wall hernia in a 7-year-old child. *J Pediatr Surg* 1973;8:975-6.
- Dreyfuss DC, Flancbaum L, Krasna IH et al. Acute trans-rectus traumatic hernia. *J Trauma* 1986;26:1134-6.
- Peters JC, Reinertson JS, Polansky SM et al. CT demonstration of traumatic ventral hernia. *J Comput Assist Tomogr* 1988;12:710-1.
- Mitchiner JC. Handlebar hernia: diagnosis by abdominal computed tomography. *Ann Emerg Med* 1990;19:812-3.
- Damschen DD, Landercaasper J, Cogbill TH et al. Acute traumatic abdominal hernia: case reports. *J Trauma* 1994;36:273-6.
- Kubalak G. Handlebar hernia: case report and review of the literature. *J Trauma* 1994;36:438-9.
- Iuchtman M, Kessel B, Kirshon M. Trauma-related acute spigelian hernia in a child. *Pediatr Emerg Care* 1997;13:404-5.
- Perez VM, McDonald AD, Ghani A et al. Handlebar hernia: a rare traumatic abdominal wall hernia. *J Trauma* 1998;44:568.
- Kubota A, Shono J, Yonekura T et al. Handlebar hernia: case report and review of pediatric cases. *Pediatr Surg Int* 1999;15:411-2.
- Fraser N, Milligan S, Arthur R et al. Handlebar hernia masquerading as an inguinal haematoma. *Hernia* 2002;6:39-41.
- Mancel B, Aslam A. Traumatic abdominal wall hernia: an unusual bicycle handlebar injury. *Pediatr Surg Int* 2003;19:746-7.
- Goliath J, Mittal V, McDonough J. Traumatic handlebar hernia: a rare abdominal wall hernia. *J Pediatr Surg* 2004;39:e20-e22.
- Prada Arias M, Dargallo Carbonell T, Estevez Martinez E et al. Handlebar hernia in children: two cases and review of the literature. *Eur J Pediatr Surg* 2004;14:133-6.
- Chen HY, Sheu MH, Tseng LM. Bicycle-handlebar hernia: a rare traumatic abdominal wall hernia. *J Chin Med Assoc* 2005;68:283-5.
- Iinuma Y, Yamazaki Y, Hirose Y et al. A case of a traumatic abdominal wall hernia that could not be identified until exploratory laparoscopy was performed. *Pediatr Surg Int* 2005;21:54-7.
- Haimovici L, Papafragkou S, Kessler E et al. Handlebar hernia: traumatic abdominal wall hernia with multiple enterotomies. A case report and review of the literature. *J Pediatr Surg* 2007;42:567-9.
- Matsuo S, Okada S, Matsumata T. Successful conservative treatment of a bicycle-handlebar hernia: report of a case. *Surg Today* 2007;37:349-51.
- Mezahir JJ, Glynn L, Liu DC et al. Handlebar injuries in children: should we raise the bar of suspicion? *Am Surg* 2007;73:807-10.
- Litton K, Izzidien AY, Hussien O et al. Conservative management of a traumatic abdominal wall hernia after a bicycle handlebar injury (case report and literature review). *J Pediatr Surg* 2008;43:e31-2.
- Karaman I, Karaman A, Aslan MK et al. A hidden danger of childhood trauma: bicycle handlebar injuries. *Surg Today* 2009;39:572-4.
- Nguyen MH, Watson A, Wong E. A 6-year-old boy presenting with traumatic evisceration following a bicycle handle bar injury: a case report. *Cases J* 2009;2:6315.
- Tonsi AF, Alkushheh M, Reddy K et al. Bicycle handlebar hernia with multiple enterotomies: a case report. *Acta Chir Belg* 2010;110:243-5.
- Yegane RA, Peyvandi H, Nowrouzi S et al. Handlebar hernia: a rare type of abdominal wall hernia. *Acta Med Iran* 2010;48:351-2.
- Bosemani T, Huisman T, Benson J et al. "Handlebar hernia" – CT findings and associated visceral injuries. *Pediatr Radiol* 2011;41: S342-S3.
- Hatti RB, Basarkod SI, Vishwanath G et al. Handlebar hernias: case reports of rare traumatic abdominal wall hernias. *J Clin Diagn Res* 2011;5:826-7.
- Mitchell PJ, Green M, Ramesh AN. Handlebar hernia in children. *Emerg Med J* 2011;28:439-40.
- Rowell EE, Chin AC. Laparoscopic repair of traumatic abdominal wall hernia from handlebar injury. *J Pediatr Surg* 2011;46:e9-e12.
- van Bommel AJ, van Marle AG, Schlejen PM et al. Handlebar hernia: a case report and literature review on traumatic abdominal wall hernia in children. *Hernia* 2011;15:439-42.
- Yan J, Wood J, Bevan C et al. Traumatic abdominal wall hernia – a case report and literature review. *J Pediatr Surg* 2011;46:1642-5.
- Decker S, Engelmann C, Krettek C et al. Traumatic abdominal wall hernia after blunt abdominal trauma caused by a handlebar in children: a well-visualized case report. *Surg* 2012;151:899-900.
- Rathore A, Simpson BJ, Diefenbach KA. Traumatic abdominal wall hernias: an emerging trend in handlebar injuries. *J Pediatr Surg* 2012;47:1410-3.
- Griffin LA, Scogletti VC, Nolan TC et al. Traumatic abdominal wall hernia from a handlebar injury. *Am Surg* 2013;79:E192-E193.
- Klimek PM, Lutz T, Stranzinger E et al. Handlebar injuries in children. *Pediatr Surg Int* 2013;29:269-73.
- Thakur SK, Gupta S, Goel S. Traumatic spigelian hernia due to handlebar injury in a child: a case report and review of literature. *Indian J Surg* 2013;75:404-6.
- Upasani A, Bouhadiba N. Paediatric abdominal wall hernia following handlebar injury: should we diagnose more and operate less? *BMJ Case Rep* 2013;2013.
- Yaylaci S, Ercelik H, Seyit M et al. Handlebar trauma causing small bowel hernia with jejunal perforation. *West J Emerg Med* 2014;15:367-8.
- Angel Buitrago L, Lugo-Vicente H. Handlebar hernia: case report and literature review. *Bol Asoc Med P R* 2015;107:58-61.
- Hirose T, Ogura H, Kiguchi T et al. The risk of pediatric bicycle handlebar injury compared with non-handlebar injury: a retrospective multicenter study in Osaka, Japan. *Scand J Trauma Resusc Emerg Med* 2015;23:66.
- Talutis SD, Muensterer OJ, Pandya S et al. Laparoscopic-assisted management of traumatic abdominal wall hernias in children: case series and a review of the literature. *J Pediatr Surg* 2015;50:456-61.
- Pederiva F, Guida E, Maschio M et al. Handlebar injury in children: The hidden danger. *Surgery* 2016;159:1477.
- Ramos-Irizarry CT, Swain S, Troncoso-Munoz S et al. Consequences of underestimating impalement bicycle handlebar injuries in children. *J Trauma Nurs* 2017;24:25-9.
- Rinaldi VE, Bertozzi M, Magrini E et al. Traumatic abdominal wall hernia in children by handlebar injury: When to suspect, scan, and call the surgeon. *Pediatr Emerg Care* 2017 24 Apr (e-pub ahead of print).
- Volpe A, Virgone C, Gamba P. Successful conservative management of handlebar hernia in children. *Pediatr Int* 2017;59:105-6.
- Roberts GR. Traumatic abdominal wall rupture. *Br J Surg* 1964;51:153-4.
- Maunola R, Kekomaki M. Traumatic hernia: two cases of traumatic subcutaneous rupture of the abdominal wall. *Acta Chir Scand* 1965;130:256-8.
- Miele V, Piccolo CL, Trinci M et al. Diagnostic imaging of blunt abdominal trauma in pediatric patients. *Radiol Med* 2016;121:409-30.
- Singal R, Gupta R, Mittal A et al. Delayed presentation of the traumatic abdominal wall hernia; dilemma in the management - review of literature. *Indian J Surg* 2012;74:149-56.
- Berona K, Kang T, Rose E. Pelvic free fluid in asymptomatic pediatric blunt abdominal trauma patients: A case series and review of the literature. *J Emerg Med* 2016;50:753-8.
- Rathaus V, Zissin R, Werner M et al. Minimal pelvic fluid in blunt abdominal trauma in children: the significance of this sonographic finding. *J Pediatr Surg* 2001;36:1387-9.