

UNIVERSITY OF COPENHAGEN



Ethnic differences in craniofacial and upper spine morphology in children with skeletal Class II malocclusion

Oh, Eunhye; Ahn, Sug-Joon; Sonnesen, Liselotte

Published in:
Angle Orthodontist

DOI:
[10.2319/083017-584.1](https://doi.org/10.2319/083017-584.1)

Publication date:
2018

Document version
Publisher's PDF, also known as Version of record

Citation for published version (APA):
Oh, E., Ahn, S-J., & Sonnesen, L. (2018). Ethnic differences in craniofacial and upper spine morphology in children with skeletal Class II malocclusion. *Angle Orthodontist*, 88(3), 283-291. <https://doi.org/10.2319/083017-584.1>

Ethnic differences in craniofacial and upper spine morphology in children with skeletal Class II malocclusion

Eunhye Oh^a; Sug-Joon Ahn^b; Liselotte Sonnesen^c

ABSTRACT

Objectives: To analyze differences in upper cervical spine and craniofacial morphology, including posterior cranial fossa and growth prediction signs, between Danish and South Korean pre-orthodontic skeletal Class II children and to analyze associations between upper cervical spine morphology and craniofacial characteristics.

Materials and Methods: One hundred forty-six skeletal Class II children—93 Danes (54 boys and 39 girls, mean age 12.2 years) and 53 Koreans (27 boys and 26 girls, mean age 10.8 years)—were included. Upper spine morphology, Atlas dimensions, and craniofacial morphology, including posterior cranial fossa and growth prediction signs, were assessed on lateral cephalograms. Differences and associations were analyzed by multiple linear and logistic regression analyses adjusted for age and gender.

Results: Significant differences between the ethnic groups were found in the sagittal and vertical craniofacial dimensions ($P < .001$), mandibular shape ($P < .01$), dental relationship ($P < .01$), posterior cranial fossa ($P < .05$), and growth prediction signs ($P < .001$). No significant differences were found in upper spine morphology and Atlas dimensions between the groups. Upper spine morphology/dimensions were significantly associated with the cranial base angle ($P < .01$), sagittal craniofacial dimensions ($P < .001$), posterior cranial fossa ($P < .001$), and growth prediction signs ($P < .05$).

Conclusions: Upper spine morphology/dimensions may be valuable as predictive factors in treatment planning for growing Class II children. (*Angle Orthod.* 2018;88:283–291.)

KEY WORDS: Craniofacial morphology; Upper spine morphology; Class II; Children

INTRODUCTION

Ethnic differences in craniofacial morphology have been documented previously^{1,2} and are generally accepted in the orthodontic specialty. Authors suggest that ethnic differences should be considered in

orthodontic practice and that modified standards for each ethnic group are recommended in orthodontic diagnosis.

Associations between craniofacial and upper cervical spine morphology have also been documented.^{3–5} Morphological upper cervical spine deviations occurred significantly more often in patients with severe malocclusions compared to patients with neutral occlusion, and the deviations of the upper cervical spine were associated with retrognathia, large inclination of the jaws, and a large cranial base angle.^{3,4} In addition, dimensions of the first cervical vertebra, Atlas, have been shown^{6,7} to be associated with craniofacial morphology and mandibular growth.

As the morphology and dimensions of the upper cervical spine are associated with craniofacial morphology, and because craniofacial morphological differences between Asians and Europeans have been found, upper spine morphology may be different in the two ethnic groups. As the upper spine belongs to the cerebellar and cervical spine field and the posterior

^a PhD student, Section of Orthodontics, Department of Odontology, Faculty of Health and Medical Sciences, University of Copenhagen, Copenhagen, Denmark.

^b Professor, Department of Orthodontics, School of Dentistry, Seoul National University, Seoul, Korea.

^c Associate Professor and Director of Postgraduate Program, Department of Odontology, Faculty of Health and Medical Sciences, University of Copenhagen, Copenhagen, Denmark.

Corresponding author: Dr Liselotte Sonnesen, Section of Orthodontics, Department of Odontology, Faculty of Health and Medical Sciences, University of Copenhagen, 20 Nørre Alle, DK-2200 Copenhagen N, Denmark (e-mail: alson@sund.ku.dk)

Accepted: November 2017. Submitted: September 2017.

Published Online: January 16, 2018

© 2018 by The EH Angle Education and Research Foundation, Inc.

cranial fossa represents the cerebellar part of the field visible on the lateral cephalogram, it also seems relevant to include this area in the analysis.⁸ Moreover, since previous studies⁹⁻⁷ have shown that upper spine morphology/dimensions were associated with craniofacial morphology and mandibular growth, and as classic longitudinal implant studies on lateral cephalograms by Björk⁹ have shown seven signs with which to predict mandibular growth, an association between upper spine morphology/dimensions and Björk's growth prediction signs⁹ is suggested.

The aims of this study were (1) to analyze differences in upper cervical spine and craniofacial morphology, including posterior cranial fossa and growth prediction signs, between European and Asian pre-orthodontic children with skeletal Class II malocclusion and (2) to analyze associations between morphological upper cervical spine deviations and craniofacial characteristics, including growth prediction signs. The null hypothesis was that there were no significant differences in upper cervical spine and craniofacial morphology between the two ethnic groups and no significant associations between upper cervical spine morphological deviations and craniofacial characteristics in the two groups.

MATERIALS AND METHODS

All pre-orthodontic children with skeletal Class II malocclusion registered in the Orthodontic section at the Department of Odontology, University of Copenhagen, Denmark, and the Orthodontic Department of Seoul National University Dental Hospital, South Korea, in the period from 2008 to 2015 were included. The inclusion criteria were (1) no previous orthodontic treatment, (2) lateral cephalogram available at pre-treatment and five first upper cervical vertebrae visible on the lateral cephalogram, (3) sagittal jaw relationship: Subspinale-Nasion-Supramentale (ss-n-sm) larger than 4.5° (1 standard deviation [SD] above the mean),^{2,10} (4) overjet larger than 5 mm (1 SD above the mean),^{2,11} and (5) before/on the pubertal growth peak (before/on capping of middle phalanx on the third finger [Mp3 cap]).¹² The exclusion criteria were patients with craniofacial syndromes or other general diseases.

The total group included 146 patients, 81 boys and 65 girls, aged 8–15 years. Ninety-three subjects were included from Copenhagen and 53 from Seoul (Table 1). The study was approved by the Danish Data Protection Agency (No. 2015-57-0121) and the ethical committee of Seoul National University Dental Hospital, South Korea (IRB 207/08-16).

When power analysis was performed using cephalometric variables representing the craniofacial morphology, such as ss-n-pg and NSL/ML,^{1,2} at least 20

Table 1. Craniofacial Characteristics and Atlas Dimensions in Skeletal Class II Danish and Korean Children—Continuous Data^a

Skeletal maturation	Danish (n = 93) (54 boys, 39 girls)		Korean (n = 53) (27 boys, 26 girls)		P-Value NS
	n	%	n	%	
PP2=	13	14	5	9.4	
MP3=	31	33.3	22	41.5	
S	34	36.6	9	17	
MP3 cap	15	16.1	17	32.1	
	Mean	SD	Mean	SD	P-value
Age, y	12.16	1.35	10.76	1.33	***
Posterior cranial fossa, mm					
s-d	65.87	7.05	66.68	4.43	NS
s-iop	92.51	4.99	90.49	4.40	NS
d-p	31.48	3.15	32.02	2.25	NS
p-iop	34.13	4.48	32.08	4.08	*
iop-s-d, °	28.39	3.15	28.84	2.73	NS
Cranial base angle, °					
n-s-ba	133.53	5.41	133.89	4.12	NS
Sagittal dimensions, °					
s-n-ss	80.65	3.04	80.41	3.00	NS
s-n-pg	75.34	3.17	74.14	2.94	NS
s-n-sm	74.14	3.08	73.85	2.84	NS
ss-n-pg	5.31	2.10	6.30	1.72	**
ss-n-sm	6.50	1.47	6.57	1.36	NS
Vertical dimensions, °					
NSL/NL	7.34	3.38	10.19	2.87	***
NSL/ML	32.10	5.78	37.90	4.78	***
NL/ML	24.76	5.18	27.70	4.62	*
Mandibular form, °					
ML/Rlar	119.21	5.76	121.97	6.40	NS
ML/MLar	20.58	2.62	18.54	2.59	**
Incisal relations, mm					
Overjet	9.26	2.10	8.08	2.24	***
Overbite	3.75	1.89	4.21	6.20	NS
Dental, °					
pr-n-ss	2.66	1.07	2.87	1.04	NS
ILs/NL	115.57	6.12	117.86	5.69	NS
ILi/ML	98.97	7.40	98.04	5.99	NS
CL/ML	75.69	5.95	78.56	5.56	**
Ols/NL	10.86	3.25	12.82	3.20	*
Oli/ML	18.78	3.74	18.99	3.78	NS
Atlas dimensions, mm					
Dorsal arch height	8.17	1.84	8.11	1.66	NS
Posterior neural arch height	3.85	0.84	3.97	0.70	NS
A-P dimension	44.25	2.95	44.10	3.15	NS

^a Linear regression analysis, adjusted for the effect of age and gender. Logistic regression analysis for skeletal maturation, adjusted for the effect of age and gender. NS indicates not significant.

* $P < .05$; ** $P < .01$; *** $P < .001$.

subjects in each group were required to have sufficient power (80%) to identify statistically significant differences at the 5% level of significance.

Skeletal maturation stage was assessed on hand-wrist radiographs.¹² Upper spine and craniofacial morphology, including growth prediction signs by Björk,⁹ were assessed on lateral cephalograms. All lateral cephalograms were taken in centric occlusion

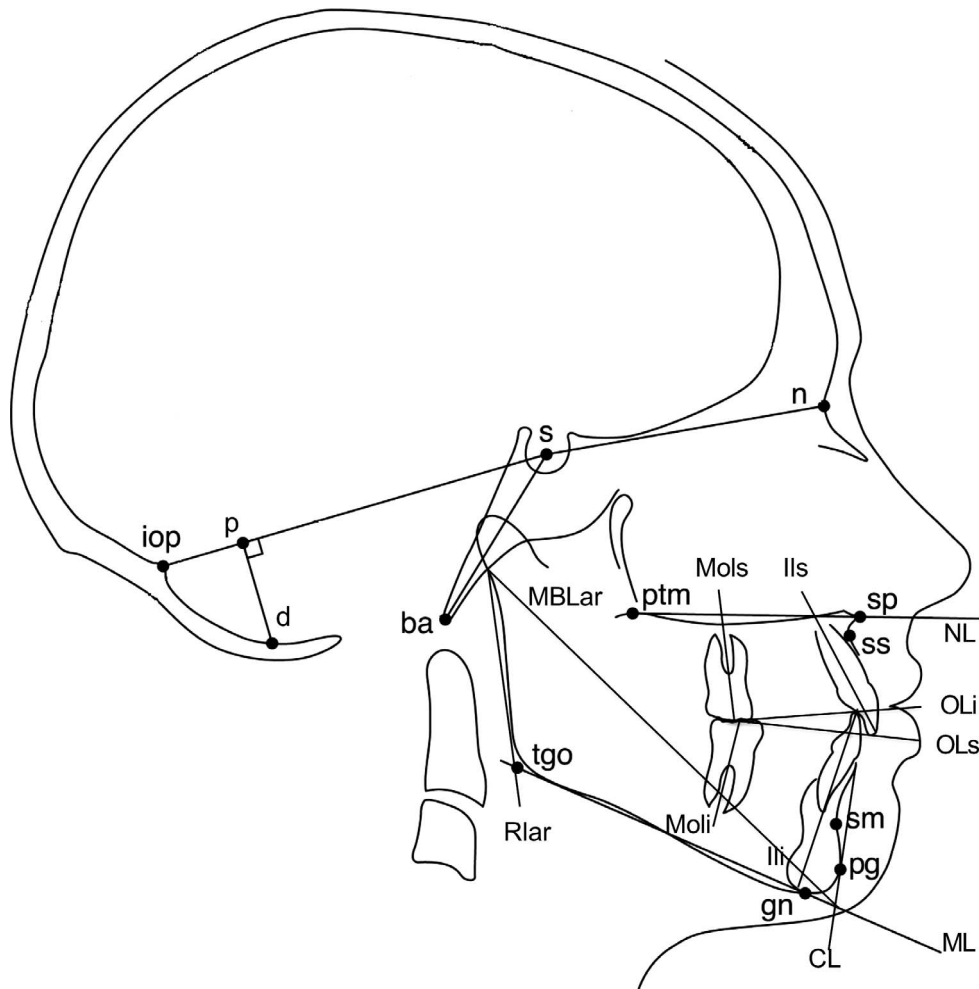


Figure 1. Reference points and lines according to Solow and Tallgren¹³ and Caspersen et al.¹⁴

and in the standard mirror position. For Danish children, the lateral cephalograms were taken at the Orthodontic section, Department of Odontology, University of Copenhagen, Denmark, with a Philips MEDIO 30 CP X-ray tube (Philips, Eindhoven, The Netherlands) with a film-to-focus distance of 180 cm and a film-to-median plane distance of 10 cm. For Korean children, the lateral cephalograms were taken at the Department of Oral and Maxillofacial Radiology, Seoul National University Dental Hospital, South Korea, with Asahi CX-90 SP (Toshiba, Tokyo, Japan) with a film-to-focus distance of 150 cm and a film-to-median plane distance of 15 cm. Correction for the constant linear enlargement was made for both groups digitally by TIOPS 2005 (version 2.12.4), including the resolution “X” and “Y” of the lateral cephalograms. The reference points were marked on the lateral cephalograms with the Tiops 2000 digitizer (version 2.7.0; TIOPS, Copenhagen, Denmark) and analyzed digitally by TIOPS 2005 (version 2.12.4).

Craniofacial and Upper Spine Morphology

Craniofacial morphology was analyzed according to the methods of Solow and Tallgren¹³ and Caspersen et al.¹⁴ (Figure 1; Table 1).

Morphological deviations of the upper cervical spine were visually assessed and classified into two categories: fusion and posterior arch deficiency, as described by Sandham.⁵ Fusions were divided into three categories: fusion, block fusion, and occipitalization. Posterior arch deficiency included partial cleft and dehiscence (Figure 2). Children with either fusions or posterior arch deficiency were categorized as upper spine morphological deviations, and children with more than one fusion deviation and/or more than one posterior arch deficiency were categorized as more than one deviation (Table 2).

Dimensions of Atlas were measured according to Huggare,⁶ and the height of the posterior neural arch at the slimmest part was measured as well (Figure 3; Table 1).

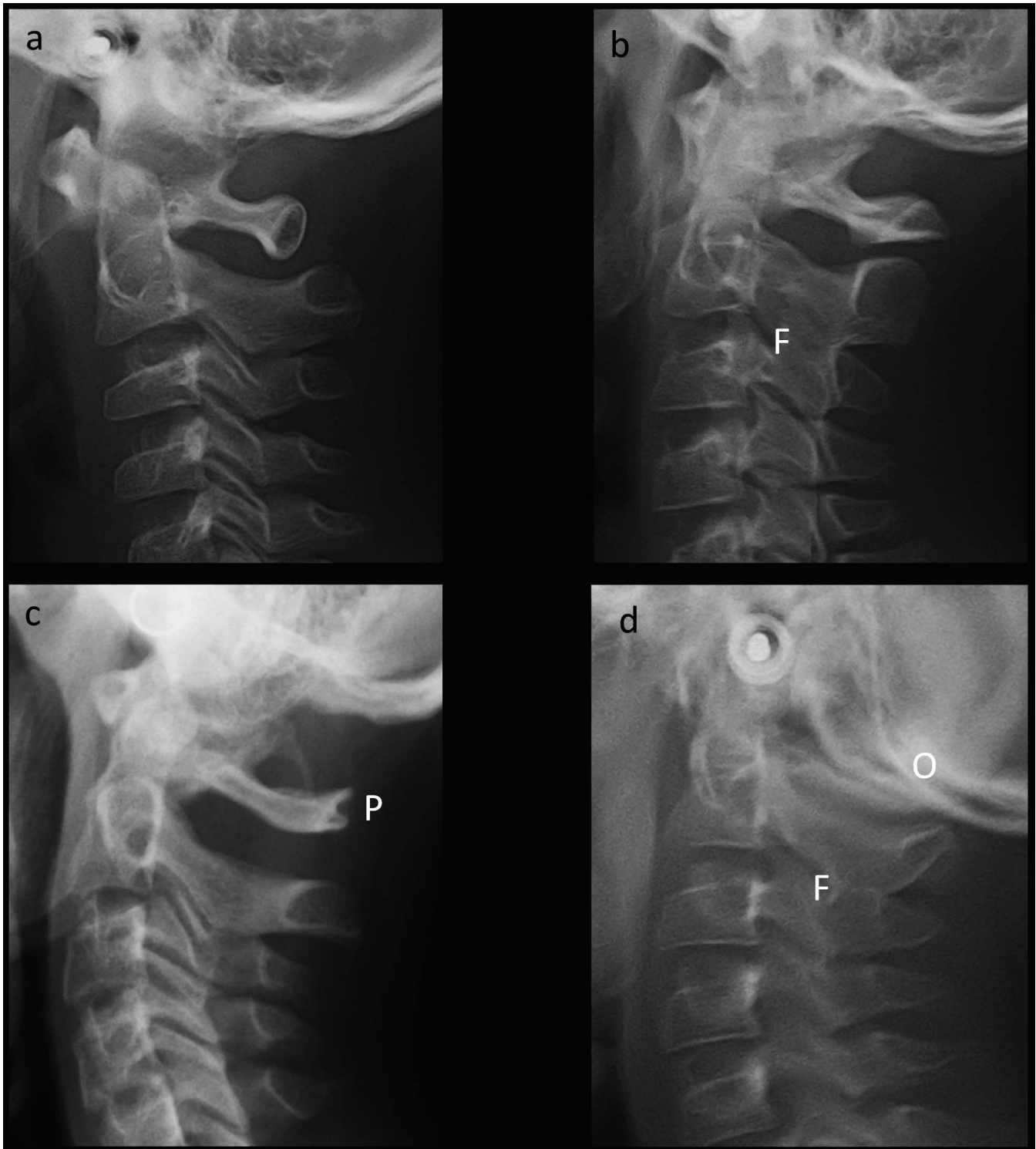


Figure 2. Morphological characteristics of the upper cervical vertebrae⁵: (a) normal upper spine and (b–d) morphological deviations of the upper spine. F indicates fusion; P, partial cleft; and O, occipitalization.

Growth Prediction Signs

The growth prediction signs according to Björk⁹ were evaluated, as follows: (1) Inclination of the condylar head, (2) curvature of the mandibular canal, (3) shape

of the lower border of the mandible, (4) inclination of the symphysis, (5) interincisal angle (IIs/IIIi), (6) intermolar angle (MOLs-MOLi), and (7) lower anterior face height (sp-gn). The four bony structures (1–4) were visually assessed and marked as forward,

Table 2. Prevalence and Pattern of Upper Cervical Spine Morphological Deviations in Skeletal Class II Danish and Korean Children^a

Variables	Danish (n = 93) (54 boys, 39 girls)		Korean (n = 53) (27 boys, 26 girls)		P-Value
	n	%	n	%	
Upper spine deviation	41	44.1	17	32.1	NS
Fusion	21	22.6	10	18.9	NS
Fusion of C2-C3	21	22.6	10	18.9	NS
Block fusion	2	2.2	0	0.0	NS
Occipitalization	1	1.1	1	1.9	NS
Posterior arch deficiency	25	26.9	12	22.6	NS
Partial cleft	25	26.9	12	22.6	NS
Dehiscence	0	0.0	0	0.0	NS
More than one deviation	5	5.4	5	9.4	NS

^a Logistic regression analysis, adjusted for the effect of age and gender. NS indicates not significant.

backward, and neutral growth prediction of the mandible according to Björk,⁹ and the three continuous variables (5–7) were analyzed digitally (Figure 4; Table 3).

Reliability and Method Error

The reliability was evaluated by remeasuring 25 lateral cephalograms at random. The differences between the two sets of remeasurements were calculated, and no systematic errors were found. The method

errors¹⁵ for craniofacial morphology, including the three continuous growth prediction signs, ranged from 0.14 to 2.12, and Atlas dimensions ranged from 0 to 1.0 mm. The reliability coefficients¹⁶ were 0.76–0.99 for the craniofacial morphology and 0.96–0.99 for the Atlas dimensions. The reliability was good ($\kappa = 0.70$) for the four categorical bony growth prediction signs and almost excellent ($\kappa = 0.78$) for the skeletal maturation stage between two sets assessed by kappa.¹⁷ The reliability of the morphological deviations in the upper cervical spine was previously reported ($\kappa = 0.82$).⁴

Statistical Analysis

Shapiro-Wilks W-test showed that all the variables were normally distributed. Differences in craniofacial variables, Atlas dimensions, and the three continuous variables of growth prediction signs between the two ethnic groups were assessed by multiple linear regression analysis with an adjustment for age and gender. Differences in upper spine morphology, the four categorical bony growth prediction signs, and skeletal maturation stage between the groups were assessed by logistic regression analysis with an adjustment for age and gender.

In the whole group, associations between the upper cervical spine morphological deviations and craniofacial morphology, including the growth prediction signs, were assessed by logistic regression analysis and

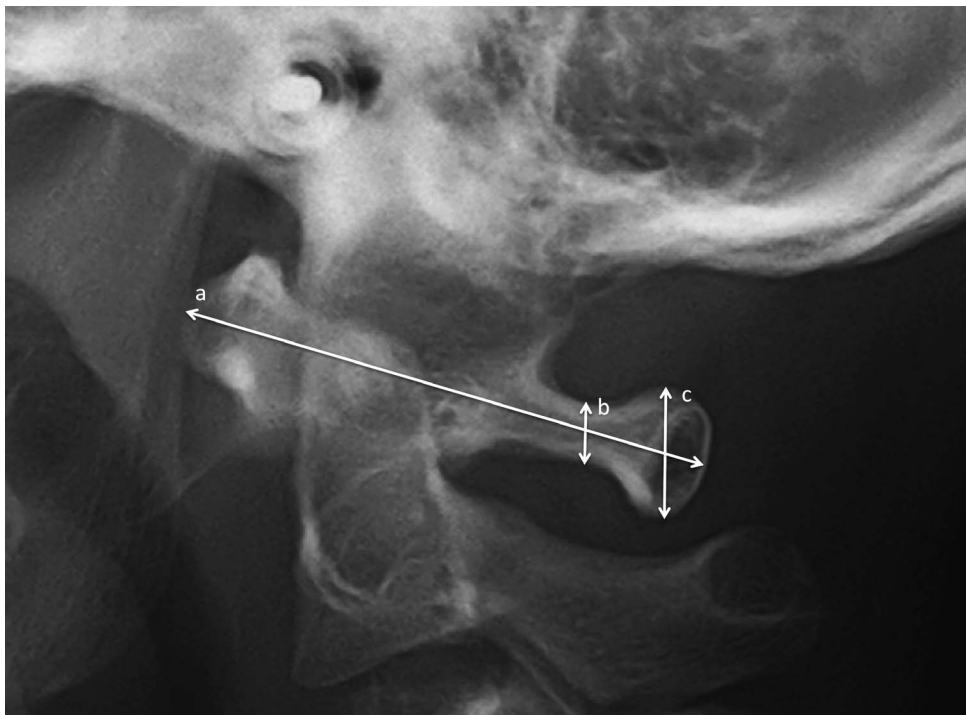


Figure 3. Reference lines for the Atlas dimensions according to Huggare⁶: anterior-posterior dimension (a), the height of the thinnest part of the posterior neural arch (b), and the height of the dorsal arch (c).

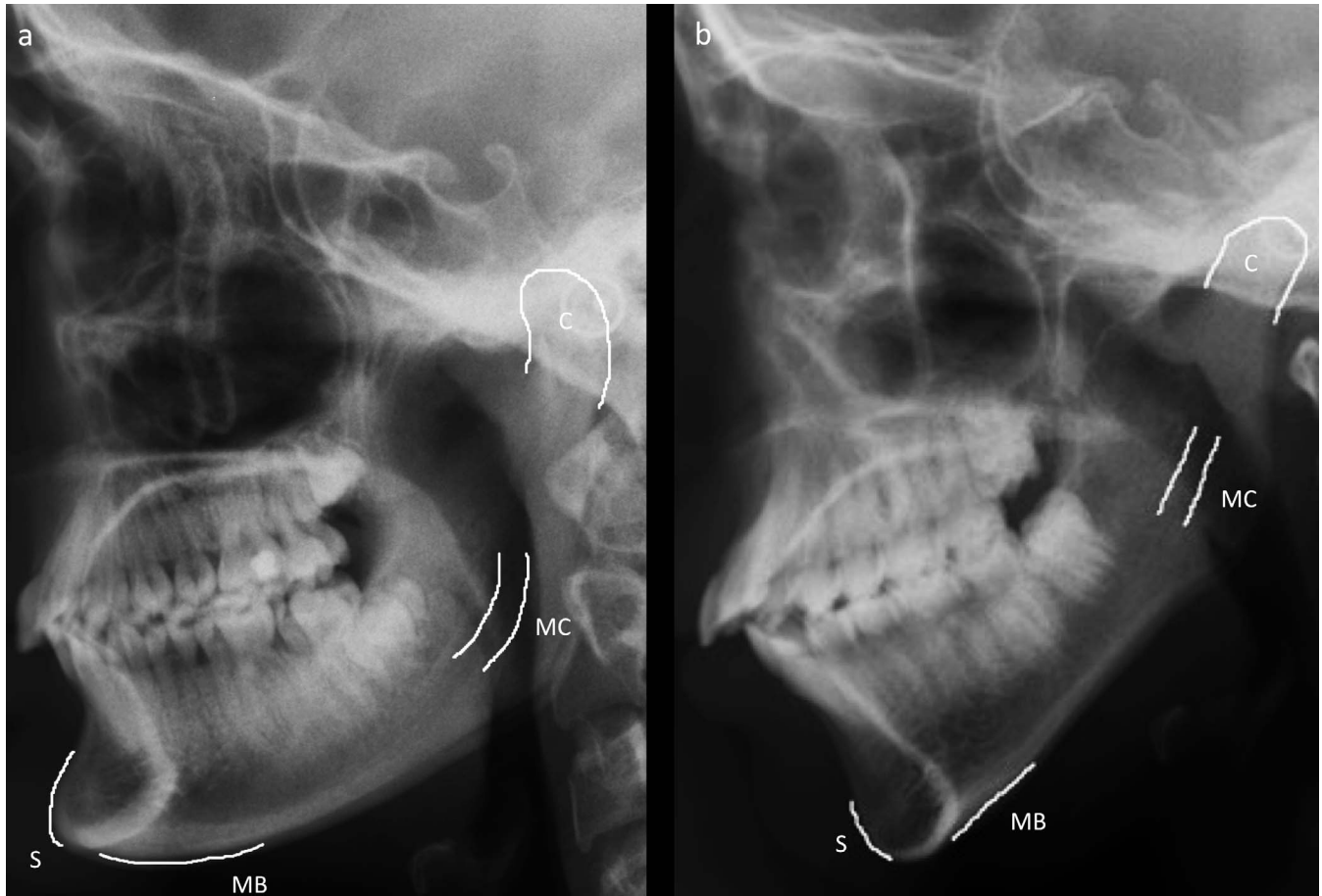


Figure 4. Lateral cephalograms illustrating Bjork's growth prediction signs⁹: (a) An example of all the forward growth prediction signs present and (b) an example of all the backward growth prediction signs present: Inclination of the condylar head (C), curvature of the mandibular canal (MC), shape of the lower border of the mandible (MB), and inclination of the symphysis (S).

adjusted for age and gender. Associations between Atlas dimensions and craniofacial morphology were assessed by linear regression analysis with an adjustment for age and gender. The data were analyzed using SPSS software (version 21.00; SPSS, Chicago, Ill).

RESULTS

The Danish children were significantly older than the Korean children ($P < .001$). No significant difference in skeletal maturation stage or gender between the groups was found (Table 1).

Craniofacial Morphology Between the Groups

The sagittal dimension of the posterior cranial fossa (p-iop; $P < .05$) was significantly larger in the Danish group compared to the Korean group. The Korean group presented a significantly retruded chin position (ss-n-pg; $P < .01$), steeper maxillary and mandibular plane angle (NSL/NL; $P < .001$, NSL/ML; $P < .001$, NL/ML; $P < .05$), more hyperdivergent mandibular

shape (ML/MBLar; $P < .01$) in the craniofacial dimensions, a significantly more proclined chin line (CL/ML; $P < .01$), and a significantly smaller overjet ($P < .001$) in the dental relationships compared to the Danish group (Table 1).

Growth Prediction Signs Between the Groups

In the Danish group, the border of the mandible ($P < .001$) and inclination of the symphysis ($P < .05$) presented significantly more forward rotation signs compared to those of the Korean group. In the Korean group, lower anterior face height was significantly larger (sp-gn; $P < .001$) and interincisal angle was smaller (IIs/IIi; $P < .05$) compared to the results for the Danish group (Table 3).

Upper Cervical Spine Morphology and Dimensions Between the Groups

There was no difference in the morphology and dimensions of the upper spine between the two ethnic groups (Tables 1 and 2).

Table 3. Seven Growth Prediction Signs in Skeletal Class II Danish and Korean Children—Three Continuous and Four Categorical Data^a

Continuous Variables	Danish (n = 93) (54 boys, 39 girls)		Korean (n = 53) (27 boys, 26 girls)		P-Value
	Mean	SD	Mean	SD	
LAFH (sp-gn), mm	62.00	4.65	63.83	4.51	...
Ils/lli, °	120.68	8.91	116.40	7.74	.
MoLs/MoLi, °	173.53	4.70	174.03	4.98	NS
Categorical Variables	n	%	n	%	P-Value
Condylar head					NS
Backward	21	22.6	24	45.3	
Forward	18	19.4	7	13.2	
Neutral	54	58.1	22	41.5	
Mandibular canal					NS
Backward	41	44.1	33	62.3	
Forward	14	15.1	4	7.5	
Neutral	38	40.9	16	30.2	
Border of mandible					...
Backward	16	17.2	28	52.8	
Forward	26	28.0	2	3.8	
Neutral	51	54.8	23	43.4	
Symphysis					.
Backward	10	10.8	15	28.3	
Forward	43	46.2	11	20.8	
Neutral	40	43.0	27	50.9	

^a Linear regression analysis for the continuous variables, adjusted for the effect of age and gender. Logistic regression analysis for the categorical variables, adjusted for the effect of age and gender. NS indicates not significant.

* $P < .05$; *** $P < .001$.

Associations Between Upper Spine vs Craniofacial Morphology and Growth Prediction Signs

In the total group, children with posterior arch deficiency or more than one deviation had significantly decreased overbite (overbite; $P < .05$). Children with any morphological deviations in the upper spine had decreased intermolar angle (MoLs/MoLi; $P < .05$) (Table 4).

The anterior-posterior dimension of Atlas was positively associated with posterior cranial fossa depth (s-d; $P < .01$, d-p; $P < .01$) and mandibular prognathia (s-n-pg; $P < .001$, s-n-sm; $P < .01$) and negatively associated with the cranial base angle (n-s-ba; $P < .01$) and sagittal jaw relationship (ss-n-pg, ss-n-sm; P

$< .001$) (Table 5). Regarding growth prediction signs, the posterior neural arch height of Atlas was positively associated with inclination of the condylar head ($P < .05$), and the anterior-posterior width of Atlas was positively associated with the lower border of the mandible ($P < .05$; Table 5).

DISCUSSION

The present study described the upper cervical spine and craniofacial morphology, including the posterior cranial fossa and growth prediction signs, in Korean and Danish children with skeletal Class II malocclusion and demonstrated associations between upper spine morphology and craniofacial characteristics. As Koreans and Danes are relatively homogeneous ethnic groups and represent the morphologic characteristics of Europeans and North-East Asians, the children were included as representatives of the two ethnic groups. Considering that craniofacial and upper spine morphology is closely associated with skeletal maturity, skeletal maturity was evaluated in the present study.^{12,18} There was no significant difference in skeletal maturity between the two ethnic groups in the present study despite the age difference. The age difference was statistically adjusted.

In the present study, the differences in craniofacial morphology coincided with the differences in the growth prediction signs between the groups. The Danish group had a higher prevalence of forward rotation signs, whereas the Korean group showed more backward rotation signs. The findings were in accordance with the notion that the Danes had more hypodivergent craniofacial morphology compared to the Koreans, which was in agreement with the findings of previous studies.^{1,2} In the posterior cranial fossa, Danish children presented a wider sagittal dimension (p-iop). The new finding may reflect general morphological differences between the two ethnic groups. The reliability of Björk’s growth prediction signs⁹ has been questioned previously,^{19,20} but the reliability was good, and the growth prediction signs reflected the divergence of the jaws in the present study.

Table 4. Significant Associations Between Upper Cervical Spine Morphology and Craniofacial Morphology, Including Growth Prediction Signs in the Total Group^a

	Posterior arch deficiency			Upper spine deviations			More than one deviation		
	P	OR	95% CI Lower-Upper	P	OR	95% CI Lower-Upper	P	OR	95% CI Lower-Upper
Overbite	*	0.781	0.629–0.970	NS			*	0.687	0.473–0.998
MoLs/MoLi	NS			*	0.927	0.861–0.998	NS		

^a OR indicates odds ratio; CI, confidence interval. Upper spine deviations: either fusions or posterior arch deficiency. Logistic regression analysis, adjusted for the effect of age and gender. NS indicates not significant.

* $P < .05$.

Table 5. Significant Associations Between Atlas Dimensions and Craniofacial Morphology, Including Growth Prediction Signs in the Total Group^a

Variables	Dorsal Arch Height				Posterior Neural Arch Height				Width (A-P)			
	P	Co	95% CI		P	Co	95% CI		P	Co	95% CI	
			Lower	Upper			Lower	Upper			Lower	Upper
Posterior cranial fossa												
s-d	*	0.057	0.012	0.101	*	0.026	0.005	0.047	**	0.108	0.037	0.180
d-p	NS				****	0.086	0.040	0.132	**	0.211	0.052	0.370
Cranial base												
n-s-ba	*	-0.064	-0.119	-0.008	*	-0.030	-0.056	-0.004	**	-0.131	-0.220	-0.043
Sagittal dimensions												
s-n-pg	NS				**	0.057	0.017	0.098	***	0.252	0.110	0.393
s-n-sm	NS				**	0.060	0.017	0.103	*	0.196	0.044	0.348
ss-n-pg	NS				NS				****	-0.451	-0.667	-0.236
ss-n-sm	NS				NS				****	-0.712	-1.010	-0.413
Dental												
pr-n-ss	NS				NS				*	0.469	0.047	0.892
Growth prediction signs												
sp-gn	*	0.076	0.014	0.137	NS				*	0.115	0.015	0.215
ConHead	NS				*	0.098	0.003	0.193	NS			
MnBorder	NS				NS				*	0.391	0.067	0.715

^a Co indicates regression coefficient; CI, confidence interval; ConHead, inclination of the condylar head; and MnBorder, lower border of the mandible. Multiple linear regression analysis, adjusted for the effect of age and gender. NS indicates not significant.

* $P < .05$; ** $P < .01$; *** $P < .001$; **** $P < .0001$.

Considering the significant craniofacial morphological differences between the two groups and their association with the upper spine morphology,^{3,4} morphological differences in the upper spine were anticipated between the two ethnic groups. However, there was no significant difference in the upper cervical spine morphology between the groups. Instead, the occurrence of morphological upper spine deviations and dimensions was consistent regardless of ethnicity in the Class II malocclusion. This finding may provide new knowledge for understanding upper spine morphology and dimensions in different ethnic groups.

Limitations with regard to detecting morphological deviations of the upper spine (ie, fusions) on two-dimensional images have been raised.^{21,22} In the present study, in order to avoid 'pseudofusion,' fusion was only registered if fusion was found consistently on all consecutive lateral cephalograms of the same patient and if fusion was confirmed independently by two of the authors. In a recent study²² it was found that the agreement between lateral cephalograms and cone-beam computed tomographic images in detecting upper spine deviations was good and that lateral cephalograms were sufficient for evaluating the upper spine morphology.

When associations between upper spine and craniofacial morphology were analyzed, only overbite was significantly associated with upper spine morphological deviations. Previously it was found^{3,4} that upper spine morphological deviations are associated with mandibular retrognathia, large inclination of the jaws, and a large cranial base angle. However, in the present study,

children with decreased Atlas dimension presented larger cranial base angle, retrognathia of the mandible, and constricted posterior cranial fossa in depth. The findings were in agreement with those of a previous study²³ in which it was reported that Atlas dimensions were associated with mandibular prognathia, cranial base angle, and posterior cranial fossa dimensions.

An explanation regarding the associations between the upper spine and the craniofacial morphology including the posterior cranial fossa could be found in the early embryogenesis. The upper spine and the posterior cranial fossa are derived from the same developmental origin of the notochord. In prenatal studies, Kjær⁸ illustrated that the notochord controls the development of the upper spine and the posterior cranial fossa, which are structures that belong to the cerebellar and the cervical spine field.^{8,23} Furthermore, because the notochord determines the development not only of the upper spine but also of the basilar part of the occipital bone that is the posterior part of the cranial base angle,⁸ the cranial base to which the jaws are attached could be the developing link between the cervical vertebral column and the jaws.^{3,4} Björk²⁴ found that the cranial base angle influences craniofacial morphology and that a large cranial base angle in adulthood is associated with retrognathia and an increased inclination of the jaws. The associations between the upper spine and the craniofacial morphology, including the cranial base, found in the present study may therefore be due to the developing link between the upper spine and the jaws through the cranial base.

Upper spine morphology and dimensions were also associated with growth prediction signs in the present study. Children with decreased Atlas dimensions presented more backward rotation signs in the condylar head and lower border of the mandible, which was in agreement with the findings of previous studies.^{6,7} Upper spine morphological deviations were also associated with a growth prediction sign, the intermolar angle. Previously, it has been documented that the intermolar angle had a high predictive value in mandibular rotation⁹ and that only the intermolar angle was unaffected by age.²⁰ Therefore, as the children were between 8 and 15 years of age before the pubertal growth peak in the present study, the intermolar angle presented stronger associations with the upper spine morphological deviations than with the other predictive signs when the results were adjusted for age and gender.

The new associations between upper spine morphology and growth prediction signs found in the present study indicate that Atlas dimensions and morphological upper spine deviations may be useful, in combination with Björk's predictive signs,⁹ in predicting mandibular growth and rotation in orthodontic treatment planning for growing children. For example, if a child shows an unfavorable growth pattern according to upper spine deviations and Björk's predictive signs,⁹ the prognosis of a growth adaptation treatment may be poor, and an alternative, compromised fixed appliance treatment may be suggested.

CONCLUSIONS

- New ethnic differences in posterior cranial fossa morphology and growth prediction signs between Danish and Korean children were found.
- Upper spine morphology/dimensions were significantly associated with the craniofacial morphology, including the posterior cranial fossa and growth prediction signs.
- The results may prove valuable in treatment planning for growing Class II children.

ACKNOWLEDGMENT

Professor Thomas A. Gerds, Biostatistics, University of Copenhagen, is thanked for statistical advice.

REFERENCES

1. Miyajima K, McNamara JA Jr, Kimura T, Murata S, Iizuka T. Craniofacial structure of Japanese and European-American adults with normal occlusions and well-balanced faces. *Am J Orthod Dentofacial Orthop.* 1996;110:431–438.
2. Park IC, Bowman D, Klapper L. A cephalometric study of Korean adults. *Am J Orthod Dentofacial Orthop.* 1989;96:54–59.
3. Sonnesen L, Pedersen C, Kjær I. Cervical column morphology related to head posture, cranial base angle and condylar malformation. *Eur J Orthod.* 2007;29:1–6.
4. Sonnesen L, Kjær I. Cervical vertebral body fusions in patients with skeletal deep bite. *Eur J Orthod.* 2007;29:464–470.
5. Sandham A. Cervical vertebral anomalies in cleft lip and palate. *Cleft Palate J.* 1986;23:206–214.
6. Huggare J. Association between morphology of the first cervical vertebra, head posture, and craniofacial structures. *Eur J Orthod.* 1991;13:435–440.
7. Huggare J. The first cervical vertebra as an indicator of mandibular growth. *Eur J Orthod.* 1989;11:10–16.
8. Kjær I. Orthodontics and foetal pathology: a personal view on craniofacial patterning. *Eur J Orthod.* 2010;32:140–147.
9. Björk A. Prediction of mandibular growth rotation. *Am J Orthod.* 1969;55:585–599.
10. Steiner CC. Cephalometrics for you and me. *Am J Orthod.* 1953;39:729–755.
11. Ricketts RM. A foundation for cephalometric communication. *Am J Orthod.* 1960;46:330–357.
12. Helm S, Siersbæk Nielsen S, Skieller V, Björk A. Skeletal maturation of the hand in relation to maximum pubertal growth in body height. *Danish Dent J.* 1971;75:1223–1234.
13. Solow B, Tallgren A. Head posture and craniofacial morphology. *Am J Phys Anthropol.* 1976;44:417–435.
14. Caspersen LM, Kjær I, Sonnesen L. How does occipitalization influence the dimensions of the cranium? *Orthod Craniofac Res.* 2010;13:162–168.
15. Dahlberg G. *Statistical Methods for Medical and Biological Students.* New York, NY: Interscience; 1940:122–132.
16. Houston WJB. The analysis of errors in orthodontic measurements. *Am J Orthod.* 1983;83:382–390.
17. Cohen J. A coefficient of agreement for nominal scales. *Educ Psych Meas.* 1960;23:37–46.
18. Perinette G, Sbardella V, Contardo L. Diagnostic reliability of the third finger middle phalanx maturation (MPM) method in the identification of the mandibular growth peak. *Eur J Orthod.* 2017;39:194–201.
19. Bremen JV, Panchez H. Association between Björk's structural signs of mandibular growth rotation and skeletal morphology. *Angle Orthod.* 2005;75:506–509.
20. Davidovitch M, Eleftheriadi I, Kostaki A, Shpack N. The use of Björk's indications of growth for evaluation of extremes of skeletal morphology. *Eur J Orthod.* 2016;38:555–562.
21. Bebnowski D, Hänggi MP, Markic G, Roos M, Peltomäki T. Cervical vertebrae anomalies in subjects with Class II malocclusion assessed by lateral cephalogram and cone beam computed tomography. *Eur J Orthod.* 2012;34:226–231.
22. Sonnesen L, Jensen KE, Petersson AR, Petri N, Berg S, Svanholt P. Cervical vertebral column morphology in patients with obstructive sleep apnoea assessed using lateral cephalograms and cone beam CT. A comparative study. *Dentomaxillofac Radiol.* 2013;42:20130060.
23. Gjörup H, Sonnesen L, Beck-Nielsen S, Haubek D. Upper spine morphology in hypophosphatemic rickets and healthy controls: a radiographic study. *Eur J Orthod.* 2014;36:217–225.
24. Björk A. The face in profile. *Sven Tandlak Tidsskr.* 1947;40:124–168.