



## **A Novel Technique for Constructing a Loop Ileostomy Side to Side Stapled Single Lumen Endileostomy**

Levic, Katarina; Bulut, Orhan

*Published in:*  
Clinics in Surgery

*Publication date:*  
2017

*Document version*  
Publisher's PDF, also known as Version of record

*Document license:*  
[CC BY](#)

*Citation for published version (APA):*  
Levic, K., & Bulut, O. (2017). A Novel Technique for Constructing a Loop Ileostomy: Side to Side Stapled Single Lumen Endileostomy. *Clinics in Surgery*, 2, [1336].



## A Novel Technique for Constructing a Loop Ileostomy: Side to Side Stapled Single Lumen Endileostomy

Katarina Levic<sup>1\*</sup> and Orhan Bulut<sup>2</sup>

<sup>1</sup>Department of Surgical Gastroenterology, Copenhagen University Hospital Hvidovre, Denmark

<sup>2</sup>Department of Clinical Medicine, University of Copenhagen, Copenhagen, Denmark

### Abstract

Construction of a diverting loop ileostomy is not uncommon, but not entirely risk free. The morbidity related to loop ileostomies and loop ileostomy closure is considerable. Some of the most frequent stoma complications are peristomal skin irritation, bandaging problems and leakage. In loop ileostomies the efferent limb is in closer contact with the skin, increasing the risk of irritation. End ileostomies however, are everted around the entire stomal circumference, allowing the stoma output to flow directly into the appliance. We present a novel simple technique for constructing a functional loop ileostomy, but with a single lumen and appearance of an end ileostomy that can be considered as a reasonable option for construction of a diverting ileostomy.

**Keywords:** Loop ileostomy; Enterostomy; Low anterior resection

### Introduction

Construction of a diverting loop ileostomy is not uncommon and some of the indications are to relieve bowel obstruction in advance malignant disease or in emergency situations, faecal diversion allowing the bowel to heal in Inflammatory Bowel Disease (IBD) and protection of a distal anastomosis. In gastrointestinal surgery, distal anastomoses are associated with higher risk of anastomotic leak [1]. Therefore, in order to facilitate healing of the anastomosis and decrease the risk of leakage, a diverting protective stoma is created, usually in form of a temporary loop ileostomy. Construction of a loop ileostomy is however not entirely risk free. The morbidity related to loop ileostomies and loop ileostomy closure is considerable [2]. Complications following construction of a loop ileostomy are high and stoma related morbidity occurs in 35%[3]. Some of the most frequent stoma complications are peristomal skin irritation, bandaging problems and leakage, with an incidence up to 42% [4] often due to skin contact with proteolytic enzymes from the ileostomy output [5]. In loop ileostomies the efferent limb is in closer contact with the skin, increasing the risk of irritation, while end ileostomies are everted around the entire stomal circumference, allowing the stoma output to flow directly into the appliance. Complications after closure of loop ileostomies are also considerable, and are reported in up to 43% [3]. In addition, up to 40% of the postoperative complications require surgical intervention [2]. Postoperative complications include wound infections, anastomotic leakage, incisional hernia, and small bowel obstruction, which is one of the most common complications after closure of loop ileostomy [6]. In an attempt for decreasing the rate of complications associated with a loop ileostomy, we present a simple technique for constructing a functional loop ileostomy, but with a single lumen and appearance of an end ileostomy.

### OPEN ACCESS

#### \*Correspondence:

Katarina Levic, Department of Surgical Gastroenterology, Copenhagen University Hospital Hvidovre, Denmark, Tel: +46 735036977; E-mail: katarina.levic@gmail.com

Received Date: 02 Sep 2016

Accepted Date: 27 Feb 2017

Published Date: 06 Mar 2017

#### Citation:

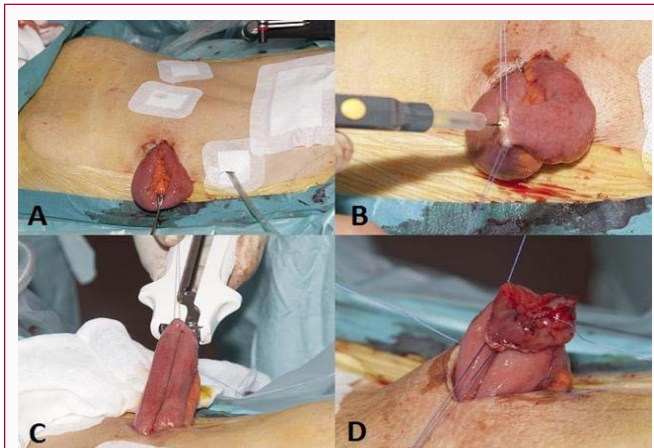
Levic K, Bulut O. A Novel Technique for Constructing a Loop Ileostomy: Side to Side Stapled Single Lumen Endileostomy. *Clin Surg*. 2017; 2: 1336.

**Copyright** © 2017 Katarina Levic. This is an open access article distributed under the Creative Commons Attribution License, which permits unrestricted use, distribution, and reproduction in any medium, provided the original work is properly cited.

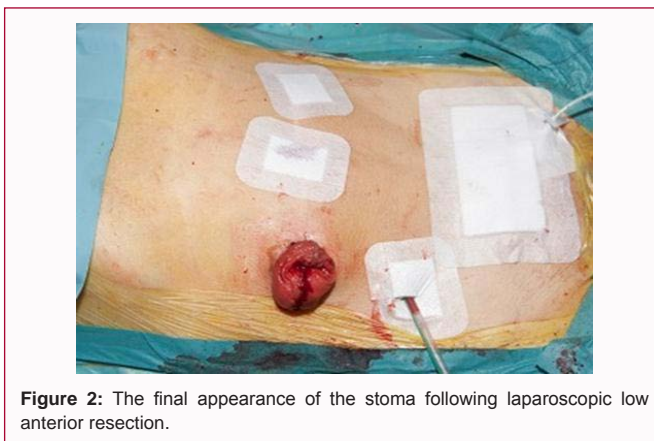### Methods

#### Surgical technique

A circular incision with electrocautery in the skin is done at the stoma site. The subcutaneous tissue is divided down to the anterior rectal fascia. The fascia and the underlying rectus muscle fibers are incised by a cross shaped incision down to the posterior fascial layer. The posterior fascial layer is divided along with the peritoneum, allowing entrance to the peritoneal cavity. A loop of terminal ileum is brought through the abdominal wall by gentle traction with a Babcock clamp (Figure 1A). Two sutures are placed, marking the afferent and efferent limb respectively. The loop is opened with a small incision from one mesenteric margin to the other on its anti-mesenteric wall (Figure 1B). A linear GIA 80 (Covidien IIC, Mansfield, MA, USA) stapling device is placed in the lumina and fired off (Figure 1C). creating a functional end-to-end anastomosis with a single lumen. Four stitches through the seromuscular layer including a full-thickness passage of the stoma edge are placed at 3,



**Figure 1:** Stepwise creation of a side to side single lumen end ileostomy; A) A loop of terminal ileum is brought through the abdominal wall by traction with a Babcock clamp. B) The loop is opened with a small incision from one mesenteric margin to the other on its anti-mesenteric wall. C) A linear GIA 80 stapling device is placed in the lumina and fired off, creating a functional end-to-end anastomosis with a single lumen. D) Four stitches through the seromuscular layer including a full-thickness passage of the stoma edge are placed at 3, 6, 9 and 12 o'clock allowing eversion of the stoma.

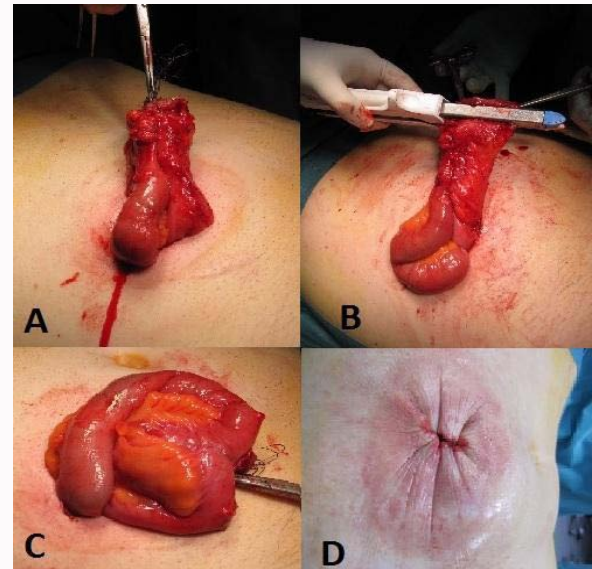


**Figure 2:** The final appearance of the stoma following laparoscopic low anterior resection.

6, 9 and 12 o'clock allowing eversion of the stoma (Figure 1D). The stoma should protrude 2-3 cm above the skin (Figure 2). The final step consists of placement of approximately eight absorbable sutures through the full thickness of the bowel wall but only through the skin dermis. The closure of the stoma is carried out in the following manner: A circumferential incision with electrocautery is made in the skin surrounding the stoma. The stoma is dissected free of the surrounding subcutaneous fat and fascia, down to the peritoneal cavity (Figure 3A). A functional end-to-end anastomosis is already present from the primary surgery. The ileostomy is closed with a linear stapling device (Figure 3B and 3C). After the closure of the fascia, the skin is close by purse-string sutures (3-0 PDS) (Figure 3D).

## Results

A total of 10 patients, of which 9 were male, underwent this procedure between January 2012 and February 2014. Initial surgery was performed as low anterior resection (LAR) for rectal cancer in 9 patients. One patient underwent the procedure after closure of colostomy after Hartmann's procedure for rectal cancer. The median age of the patients was 62 years (range 48 – 76). A GIA 80 stapler was used for stapling in all but one patient, in which a GIA 60 stapler was used at the beginning of the study period. There were no stoma-related



**Figure 3:** Closure of the loop ileostomy; A) The stoma is dissected free of the surrounding subcutaneous fat and fascia, down to the peritoneal cavity. B) The ileostomy is closed with a linear stapling device. C) The arrows are showing the line of previous end-to-end anastomosis. D) The skin is close by purse-string sutures (3-0 PDS).

complications. The median time to closure of the stoma was 4 months (range 3 – 27) depending on adjuvant chemotherapy. All patients had an uneventful postoperative course, and no late complications appeared during the follow-up period. In one patient, it was decided not to reverse the ileostomy due to development of distant metastasis and treatment with chemotherapy. The median follow-up time was 12 months (range 4 – 27).

## Discussion

Temporary diverting loop ileostomies are often used in colorectal surgery, when protection of distal anastomosis is needed. Other common situations where the creation of a loop ileostomy may be chosen, is in patients with IBD, either after creation of a ileal-pouch anal anastomosis in patients with ulcerative colitis, or as fecal diversion in patients with Crohn's disease allowing the affected bowel segment to heal, along with abdominal trauma, obstructing tumors, or severe fecal incontinence or anal stenosis [6]. However, ileostomy complications are not rare and range in a review by Kaidar-Person et al. [6] between 5% and 100%. Early complications often consist of infection of the surround skin, stomal retraction or ischemia or stoma necrosis, often due to interruption of segmental arterial supply [6,7]. Postoperative complications after loop ileostomy closure occur between 17% and 43% [2,3,8-13]. Mild complications include superficial wound infections and can often be treated conservatively. However, 40% of all postoperative complications after loop ileostomy closure require surgical intervention [2]. Although a loop ileostomy is technically easier to close, complications are reported to be higher than after an end ileostomy [14]. Anastomotic leakage is one of the most dreaded complications, and is reported to occur in up to 8% after closure of loop ileostomy [6]. Anastomotic leak can cause major problems such as enteric fistula, peritonitis, abscess and abdominal sepsis which can result in death. One of the most frequent complications, peristomal skin irritation, can cause great discomfort for the patient and be socially invalidating. The irritation is a result of chemical dermatitis, caused by the liquid output from the stoma which causes irritation

and desquamation when in contact with the skin, causing more leakage, and thereby also causing further skin irritation. In severe cases, development of parastomal pyoderma gangrenosum can occur and the management of pyoderma gangrenosum is often complicated and prolongs the hospital stay [15]. Therefore, eversion of the stoma with a 2-3 cm spout is of essence when constructing an ileostomy, as this allows the output to flow directly into the device, reducing the contact with the skin [16]. Full eversion is however difficult achieving in a loop ileostomy, as the efferent limb lies in a more direct contact with the peristomal skin. The present report describes an alternative technique for constructing a diverting ileostomy. The stoma contains both an afferent and efferent limb, meeting in a single lumen that protrudes through the abdominal wall. This results in a functioning loop-ileostomy, with an appearance of an end ileostomy. This allows for proper eversion of the stoma and creation of a spout of appropriate height, possibly reducing leakage rates and facilitating adherence of stomal appliance. Reversal of the stoma is easy and doesn't require major surgery. In our small series of ten patients, none had stoma related complication and none of the patient experienced peristomal skin problems or leakage. Although we currently use this technique for diverting ileostomies in low anterior resection (LAR), it may also be an option for other procedures in which a distal anastomosis is required, in patients with anal physiological disorders, and in patients with inflammatory bowel disease requiring surgical fecal diversion, among others.

## Conclusion

From our experience, it appears that this new approach should be considered as a reasonable option for construction of a diverting ileostomy. Although this series consist of a small sample size and long term data is lacking, this approach seems to be easy and safe to perform. A prospective randomized controlled trial comparing this technique with conventional loop ileostomy is needed in order to further evaluate the potential benefits of this novel technique.

## References

- Pommergaard H-C, Gessler B, Burcharth J, Angenete E, Haglind E, Rosenberg J. Preoperative risk factors for anastomotic leakage after resection for colorectal cancer: a systematic review and meta-analysis. *Colorectal Dis.* 2014; 16: 662-671.
- Gessler B, Haglind E, Angenete E. Loop ileostomies in colorectal cancer patients--morbidity and risk factors for nonreversal. *J Surg Res.* 2012; 178: 708-714.
- Abegg RM, Brokelman W, van Bebber IP, Bosscha K, Prins HA, Lips DJ. Results of construction of protective loop ileostomies and reversal surgery for colorectal surgery. *Eur Surg Res.* 2014; 52: 63-72.
- Bafford AC, Irani JL. Management and complications of stomas. *Surg Clin North Am.* 2013; 93:145-166.
- Shabbir J, Britton DC. Stoma complications: a literature overview. *Colorectal Dis.* 2010; 12: 958-964.
- Kaidar-Person O, Person B, Wexner SD. Complications of construction and closure of temporary loop ileostomy. *J Am Coll Surg.* 2005; 201: 759-773.
- Kann BR. Early stomal complications. *Clin Colon Rectal Surg.* 2008; 21: 23-30.
- Saha AK, Tapping CR, Foley GT, Baker RP, Sagar PM, Burke DA, et al. Morbidity and mortality after closure of loop ileostomy. *Colorectal Dis.* 2009; 11: 866-871.
- Phang PT, Hain JM, Perez-Ramirez JJ, Madoff RD, Gemlo BT. Techniques and complications of ileostomy takedown. *Am J Surg.* 1999; 177: 463-466.
- Pokorny H, Herkner H, Jakesz R, Herbst F. Predictors for complications after loop stoma closure in patients with rectal cancer. *World J Surg.* 2006; 30: 1488-1493.
- Mansfield SD, Jensen C, Phair AS, Kelly OT, Kelly SB. Complications of loop ileostomy closure: a retrospective cohort analysis of 123 patients. *World J Surg.* 2008; 32: 2101-2116.
- Akiyoshi T, Fujimoto Y, Konishi T, Kuroyanagi H, Ueno M, Oya M, et al. Complications of loop ileostomy closure in patients with rectal tumor. *World J Surg.* 2010;34: 1937-1942.
- El-Hussuna A, Lauritsen M, Bülow S. Relatively high incidence of complications after loop ileostomy reversal. *Dan Med J.* 2012; 59: 4517.
- Fonkalsrud EW, Thakur A, Roof L. Comparison of loop versus end ileostomy for fecal diversion after restorative proctocolectomy for ulcerative colitis. *J Am Coll Surg.* 2000; 190: 418-422.
- Wu X-R, Shen B. Diagnosis and management of parastomal pyoderma gangrenosum. *Gastroenterol Rep.* 2013; 1: 1-8.
- Shellito PC. Complications of abdominal stoma surgery. *Dis Colon Rectum.* 1998; 41: 1562-1572.