



Prenatal diagnosis of autosomal recessive Robinow syndrome using 3D ultrasound.

Jeppesen, Bolette F.; Buciek, Hanne Hove; Kreiborg, Sven; Hermann, Nuno Vibe; Darvann, Tron A.; Jørgensen, Finn Stener

Published in:
Clinical Case Reports

DOI:
[10.1002/ccr3.784](https://doi.org/10.1002/ccr3.784)

Publication date:
2017

Document version
Publisher's PDF, also known as Version of record

Document license:
[CC BY-NC-ND](https://creativecommons.org/licenses/by-nc-nd/4.0/)

Citation for published version (APA):
Jeppesen, B. F., Buciek, H. H., Kreiborg, S., Hermann, N. V., Darvann, T. A., & Jørgensen, F. S. (2017). Prenatal diagnosis of autosomal recessive Robinow syndrome using 3D ultrasound. *Clinical Case Reports*, 5(7), 1072-1076. <https://doi.org/10.1002/ccr3.784>

CASE REPORT

Prenatal diagnosis of autosomal recessive Robinow syndrome using 3D ultrasound

Bolette F. Jeppesen^{1,2}, Hanne B. Hove^{1,3}, Sven Kreiborg^{4,5}, Nuno V. Hermann^{4,5}, Tron A. Darvann^{5,6} & Finn Stener Jørgensen^{2,7}

¹Department of Clinical Genetics, Copenhagen University Hospital Rigshospitalet, Copenhagen, Denmark

²Faculty of Health and Medical Sciences, University of Copenhagen, Copenhagen, Denmark

³Department of Clinical Genetics, The RAREDIS Database, Section of Rare Diseases, Copenhagen University Hospital Rigshospitalet, Copenhagen, Denmark

⁴Department of Pediatric Dentistry and Clinical Genetics, School of Dentistry, Faculty of Health and Medical Sciences, University of Copenhagen, Copenhagen, Denmark

⁵3D Craniofacial Image Research Laboratory (School of Dentistry, University of Copenhagen; Centre of Head and Orthopaedics, Copenhagen University Hospital Rigshospitalet; and Department of Applied Mathematics and Computer Science, Technical University of Denmark), Copenhagen, Denmark

⁶Department of Oral and Maxillofacial Surgery, Copenhagen University Hospital Rigshospitalet, Copenhagen, Denmark

⁷Fetal Medicine Unit, Department of Obstetrics and Gynecology, Copenhagen University Hospital Hvidovre, Hvidovre, Denmark

Correspondence

Bolette F. Jeppesen, Department of Clinical Genetics 4062, Copenhagen University Hospital Rigshospitalet, Blegdamsvej 9, DK-2100 Copenhagen, Denmark.
Tel: +45 35455018; Fax: + 45 35454072;
E-mail: xwq151@alumni.ku.dk

Funding Information

No sources of funding were declared for this study.

Received: 1 April 2016; Revised: 11 August 2016; Accepted: 25 October 2016

Clinical Case Reports 2017; **5(7)**: 1072–1076

doi: 10.1002/ccr3.784

Bulleted statements: Robinow syndrome is a genetic disorder with symptoms such as facial abnormalities, dwarfism, genital hypoplasia, and vertebral malformations. This case report finds that the syndrome can be diagnosed prenatally using ultrasound by focusing on the characteristic phenotypical traits, especially the facial morphology along with mesomelia.

Introduction

Robinow syndrome is a rare, genetic disorder with symptoms such as short stature, characteristic facial features, and genital hypoplasia [1].

The syndrome was first described in 1969 by Robinow et al. [2]. Both autosomal dominant and recessive types

Key Clinical Message

This article hypothesizes that it is possible to detect and diagnose both the autosomal recessive and dominant forms prenatally using ultrasound. By focusing on the characteristic phenotypical presentation, the examiner is able to diagnose the syndrome prenatally, which is of clinical importance to the parents and counseling for the consideration of terminating the pregnancy.

Keywords

3D ultrasound, autosomal recessive Robinow syndrome, genital hypoplasia, hypertelorism, prenatal diagnosis, wide nose.

have been identified [1]. Robinow syndrome has a relatively higher incidence in families with Turkish background than in other nationalities [3].

The autosomal recessive form of Robinow syndrome (OMIM #268310) has dwarfism caused by a genetic mutation in the *ROR2* gene, a tyrosine kinase receptor that is linked to the development of the skeleton [4]. The

autosomal dominant form of the syndrome (OMIM #180700) with mutations in *WNT5A* is phenotypically milder with normal stature [5].

We present a case with prenatal diagnosis of autosomal recessive Robinow syndrome, detected at gestational age 21 weeks from 3D ultrasound. In the literature, only two recessive cases have been detected prenatally (Percin *et al.* 2001 [6] and Guven *et al.* 2006 [7]).

The aim of the present case report was to describe the prenatal characteristics of a fetus with Robinow syndrome using prenatal ultrasound, as we find that recessive Robinow syndrome belongs to the prenatally detectable skeletal dysplasias.

An early clinical recognition is important to parents, who can receive relevant information concerning the prognosis of this syndrome at an early stage of pregnancy including the possibility of terminating the pregnancy.

Case Report

This case concerns a 25-year-old primigravida. Approval to publish this article was provided by the parents of the proband.

The parents and the grandparents of the proband are consanguineous cousins from Iraq. Both parents are healthy, but the father has two siblings and one cousin affected by Robinow syndrome.

The combined first-trimester screening examination, which is offered at gestational age 11–14 weeks according to the Danish national screening program, was not performed. The mother of the proband had an ultrasound scan performed at a private clinic at gestational age 15 weeks and was told that the fetus was a female.

A routine ultrasound malformation scan performed by a sonographer at gestational age 21 weeks revealed a fetus with severe short limbs why the patient was referred for a fetal medicine expert examination a few days later. The prenatal examination was performed using a GE Voluson E8 Expert 3D ultrasound scanner, and later in the pregnancy, more examinations were made using a GE Voluson E10 Expert 3D ultrasound scanner. The scan revealed several dysmorphic facial features; for example, an abnormal short and wide nose, shortening of the long bones (Z -score -5 to -6), especially ulnae and radius bilaterally (Z -score -8 to -9),

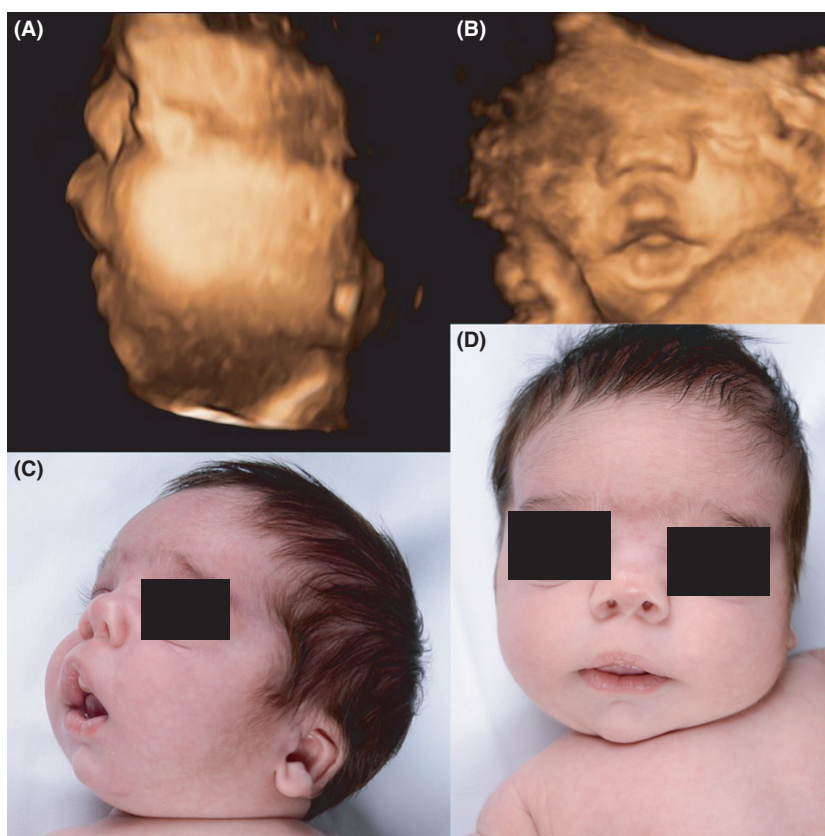


Figure 1. (A) The 3D reconstruction shows an abnormal flat profile and a triangular mouth with gingival hyperplasia. (B) The 3D reconstruction shows an upper lip with a characteristic eversion, hypertelorism, and a wide nasal root. (C, D) Photography of the male infant at the age of 7 weeks: an abnormal short and flat nose, a wide nasal root, hypertelorism, and prominent eyes.

and hemivertebrae. The shortening of the bones indicated mesomelia. The vertebral column was slightly crooked due to several hemivertebrae. A scrotum was seen but no penis. Combining the clinical and ultrasound findings, the case was found compatible with the recessive form of Robinow syndrome.

The parents were offered a cytogenetic analysis and karyotyping. However, they declined the offer on account of the small procedure-related risk of abortion. They were informed about the possibility of applying for permission for termination. However, the parents decided to proceed with the pregnancy to term.

Due to reduced growth of the fetus in the last trimester of the pregnancy, labor was induced at gestational age 37 + 5 weeks. The proband, a male infant, was delivered at gestational age 38 + 2 weeks; birthweight 2275 g; and birth length 42 cm. After 2 weeks at the neonatal unit, he was discharged with his parents to their home.

Postnatally, we elucidated the dysmorphic prenatal findings of the face even further, by transferring the ultrasound data to a computer running GE 4DView Software for 3D visualization and analysis of the specific facial features see Figure 1A and B. The 3D reconstruction in Figure 1A shows an abnormal profile, hypertelorism, a wide nasal root, and a triangular mouth with gingival hyperplasia. Figure 1B shows a characteristic eversion of the upper lip.

Postnatal examination and screening showed characteristic features similar to the prenatal ultrasound findings: a wide nasal root, an abnormal short and flat nose, hypertelorism, and prominent eyes see Figure 1C and D. There was a shortening of the upper and lower extremities including digits and toes, representative of dwarfism, malformations of the vertebrae, and a micropenis with normal scrotum see Figure 2. X-rays of the column demonstrated several malformations including dysplastic corpora with multiple hemivertebrae and spina bifida from L2 and distally.

MRI column showed several malformations including syrinx from Th8 to Th10, diastematomyelia from Th10 to ThL1, and a dermal sinus from L3 to L4. The child had no neurological signs or symptoms from the findings. All clinical findings indicated the diagnosis of autosomal recessive Robinow syndrome as proposed prenatally. The facial dysmorphism alone can be seen as a strong marker of the diagnosis when it comes to prenatal ultrasound scans, because it has a characteristic and explicit appearance.

The diagnosis was genetically confirmed at the age of 4 months with the finding of a novel homozygous frameshift mutation in the *ROR2* gene: c.139del p.Asp48 fs (OMIM 268310) corresponding to autosomal recessive Robinow syndrome [4].

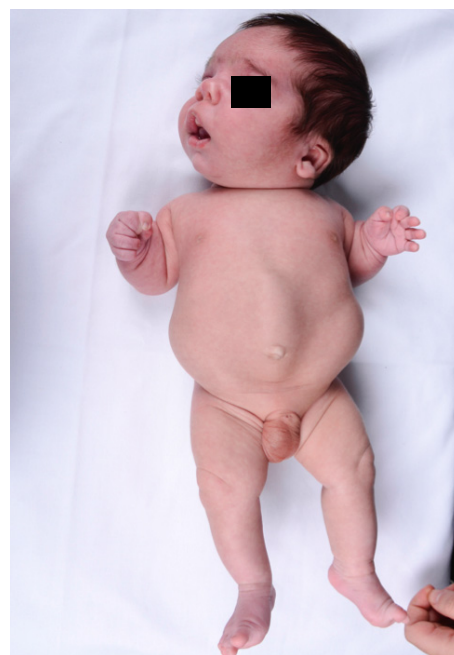

Figure 2. Photography of the male infant at the age of 7 weeks: Shortening of the upper and lower extremities including digits and toes and a micropenis with normal scrotum.

Discussion and Conclusion

By focusing on the characteristic phenotypical features in Robinow syndrome, among these especially the short disproportionate stature, the facial dysmorphism, and genital hypoplasia, we hypothesize that it is possible to detect and diagnose both the autosomal recessive and dominant forms prenatally. To the best of our knowledge, only two previous cases of prenatally diagnosed autosomal recessive Robinow syndrome (Percin et al. 2001 [6] and Guven et al. 2006 [7]) and two cases of prenatally diagnosed autosomal dominant Robinow syndrome (Loverro et al. 1990 [8] and Castro et al. 2013 [9]) have been reported in the literature.

In the dominant cases, Loverro et al. [8] found shortening of the forearms and an abnormal ulna/humerus length ratio. Castro et al. [9] found shortening of the forearms, an abnormal profile with flattening of the frontal bone, a broad nasal bridge, hypertelorism with prominent eyes, cleft palate, micrognathia, and low-set ears. Furthermore, the thorax was observed to be narrower in comparison with the abdomen. In the recessive cases, Percin et al. [6] found shortening of the humerus and femur, and Guven et al. [7] found decreased femur and humerus lengths and shortening of the long bones of the forearms. Only in the dominant case of Castro et al. [9], the facial dysmorphism was recognized prenatally.

Table 1. Ultrasound findings in prenatal diagnosis of Robinow syndrome.

Phenotypical traits	Dominant		Recessive		
	Loverro <i>et al.</i> (1990)	Castro <i>et al.</i> (2014)	Güven <i>et al.</i> (2006)	Percin <i>et al.</i> (2001)	Present study
Gender	Female	Female	Male	Male	Male
Age of diagnosis	GA 19 weeks	GA 23 + 1 weeks	GA 33 weeks	GA 12 + 4 weeks	GA 21 weeks
Shortening of the bones	Forearms, ulna/humerus length ratio	Radius, ulna	Humerus, femur, and forearm	Humerus and femur	All long bones, especially ulna and radius
Low-set ears	–	+	–	–	+
Hypertelorism	–	+	–	–	+
Prominent eyes	–	+	–	–	+
Nose	Short upturned	Wide nasal bridge	–	–	Short upturned Wide nasal bridge
Mouth		Cleft palate			Triangular mouth Gingival hyperplasia
Facial bones		Abnormal flat profile with flattening of the frontal bone Micrognathia			Abnormal flat profile
Hemivertebra	–	–	+	–	+
Genital abnormalities					Micropenis

This case report showed the prenatal findings of a fetus with autosomal recessive Robinow syndrome using 3D ultrasound. The findings included shortening of the long bones, especially radius and ulnae, bilaterally, several hemivertebrae, an abnormal facial profile, a wide nasal root, hypertelorism, and a triangular formed mouth with gingival hyperplasia. Furthermore, we found a normal scrotum, but no penis could be visualized. No previous studies have to our knowledge noted this genital malformation prenatally in Robinow syndrome, which also is an important diagnostic indicator of the syndrome.

Based on previous publications and the findings in the present case, we suggest that Robinow syndrome should be considered in the fetus with mesomelic growth retardation, facial characteristics, and micropenis in male fetuses. Prenatally, the examiner should be aware of differential diagnoses as discussed by Castro *et al.* [9]. With knowledge of the well-known characteristic features of Robinow syndrome outlined in this study, the examiner will be able to recognize and diagnose an affected fetus when performing prenatal ultrasound. According to Castro *et al.*, 80% of the affected individuals have a normal IQ, but among the rest some may have some degree of mental retardation, primarily in the autosomal recessive form of Robinow syndrome [9]. In relation to the prognosis and the psychological and mental challenges, it is of clinical importance to the parents, that they can receive counseling when considering the possibility of terminating the pregnancy (Table 1).

Authorship

BFJ: collected the clinical data and prepared the manuscript. HBH: presented the genetical confirmation of the diagnosis as well as the genetical counseling of the family. SK, NVH, and TAD: contributed with 3D data handling, reconstruction, and quantitative and qualitative comparison of the patient's prenatal morphology obtained by 3D ultrasound to postnatal obtained 3D facial surface scanning (in the 3D laboratory's 3dMD surface scanner, specially designed for infants and young children). FSJ: performed the prenatal diagnosis of the fetus. All authors contributed in both discussion and analysis of the patient data and commented on the manuscript at all stages.

Conflict of Interest

There are no conflict of interests for any of the co-authors of this manuscript.

References

- Hosalkar, H. S., and G. J. Shaw. 2002. Robinow syndrome. *J. Postgrad. Med.* 48:50–51.
- Robinow, M., F. N. Silverman, and H. D. Smith. 1969. A newly recognized dwarfing syndrome. *Am. J. Dis. Child.* 117:645–651.
- Aksit, S., H. Aydinlioglu, G. Dizdärer, S. Caglayan, D. Bektaslar, and A. Cin. 1997. Is the frequency of Robinow syndrome relatively high in Turkey? Four more case reports. *Clin. Genet.* 52:226–230.

4. Bokhoven, V. H., J. Celli, H. Kayserili, E. V. Beusekom, S. Balsi, W. Brussel, et al. 2000. Mutation of the gene encoding the ROR2 tyrosine kinase causes autosomal recessive Robinow syndrome. *Nat. Genet.* 25:423–426.
5. Masseur, J. F., E. Pardoro, A. M. Vianna-Morgante, A. Richieri-Costa, C. A. Kim, and D. Brunoni. 2007. Clinical Characterization of autosomal dominant and recessive Robinow syndrome. *Am. J. Med. Genet. A* 143:320–325.
6. Percin, E. F., T. Guvenal, A. Cetin, S. Percin, F. Goze, and S. Arici. 2000. First trimester diagnosis of Robinow syndrome. *Fetal Diagn. Ther.* 16:308–311.
7. Guven, M. A., C. Batukan, S. Ceylaner, M. Uzel, A. Ozbek, and G. Demirpolat. 2006. Prenatal and postnatal findings in a case with the autosomal recessive type of Robinow syndrome. *Fetal Diagn. Ther.* 21:386–389.
8. Loverro, G., G. Guanti, G. Caruso, and L. Selvaggi. 1990. Robinow's syndrome: prenatal diagnosis. *Prenat. Diagn.* 10:121–126.
9. Castro, S., E. Peraza, A. Barraza, and M. Zapata. 2014. Prenatal diagnosis of Robinow syndrome: a case report. *J. Clin. Ultrasound* 42:297–300.

Supporting Information

Additional Supporting Information may be found online in the supporting information tab for this article:

Video S1. GA 34+6: 3D ultrasound video shows the characteristic facial morphology of the fetus compatible with Robinow syndrome: an upper lip with a characteristic eversion, a wide nasal root and hypertelorism.