



## Post-Mortem Cardiac MRI in deceased with a history of mental illness

Jacobsen, Christina; Banner, Jytte; Vejlsttrup, Niels; Jensen, Karl Erik; Thomsen, Carsten; Baandrup, Ulrik; Banner, Jytte

*Publication date:*  
2014

*Document version*  
Peer reviewed version

*Citation for published version (APA):*  
Jacobsen, C., Banner, J., Vejlsttrup, N., Jensen, K. E., Thomsen, C., Baandrup, U., & Banner, J. (2014). *Post-Mortem Cardiac MRI in deceased with a history of mental illness*. Poster session presented at Biennial Meeting of Association for European Cardiovascular Pathology, Paris, France.



# Post-mortem cardiac MRI in deceased with a history of mental illness

C Jacobsen<sup>1</sup>, N Vejstrup<sup>2</sup>, KE Jensen<sup>3</sup>, C Thomsen<sup>3</sup>, U Baandrup<sup>4</sup>, J Banner<sup>1</sup>

<sup>1</sup>Section of Forensic Pathology, Department of Forensic Medicine, University of Copenhagen, <sup>2</sup> Department of Cardiology and <sup>3</sup>Department of Radiology, Rigshospitalet, University Hospital Copenhagen, <sup>4</sup>Center Clinical Research, Vendsyssel Hospital/Aalborg University

## Background

The Danish Departments of Forensic Medicine have established a nationwide, cross-disciplinary study: "SURVIVE" for research in forensic autopsy cases involving mentally ill deceased. A major focus is CVD. Opposed to clinical cardiology<sup>1</sup> the use of pmcMRI in forensic pathology is a fairly unknown area<sup>2-4</sup>.

## Aim

The aim of this ongoing study is to implement pmcMRI in a forensic pathology setting and to describe cardiovascular morphological changes focusing on hypertrophy and presence of edema as it can occur in myocarditis and ischemia.

## Material

So far 347 deceased with confirmed or suspected mental illness have been included in the SURVIVE study. 20 of these deceased, without signs of putrefaction on pmCT, were randomly included in this sub study (table 1).

Included deceased	n=20
Age (mean)	57
BMI (mean)	23,5
Interval (days) from death to autopsy (mean)	5,6 days
Cause of death	CVD (n=10) Other (n=8) Unexplained (n=2)
Presence of coronary atherosclerosis	Total n=13 LCA, incl. LAD and CX (n=12) Luminal reduction >50% (n=6) and <50% (n=6) RCA (n=9) Luminal reduction >75% (n=3)
Distribution of lividity	Front (n=2), Back (n=14), Combination (n=4)

Table 1. Baseline data for the deceased

## Methods

Prior to autopsy a pmcMRI is performed (1T Siemens Harmony MRI-scanner). The image analysis is done using the software OSIRIX®. The wall thickness of the left ventricle and presence of edema on the pmcMRI are registered, measured and correlated to autopsy findings and histopathology results. For correct correlation the 17-segment classification of the American Heart Association<sup>5</sup> is used (figure 1). The papillary muscles are excluded when measuring the width of the segments (figure 2).

### Left Ventricular Segmentation

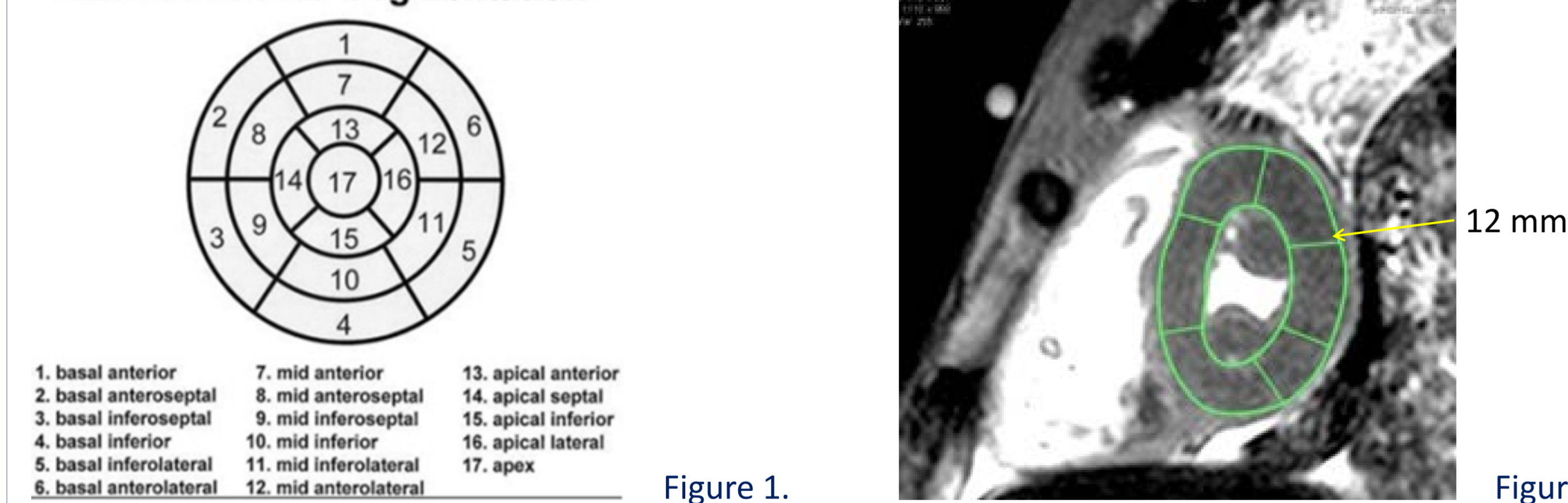

Figure 1.

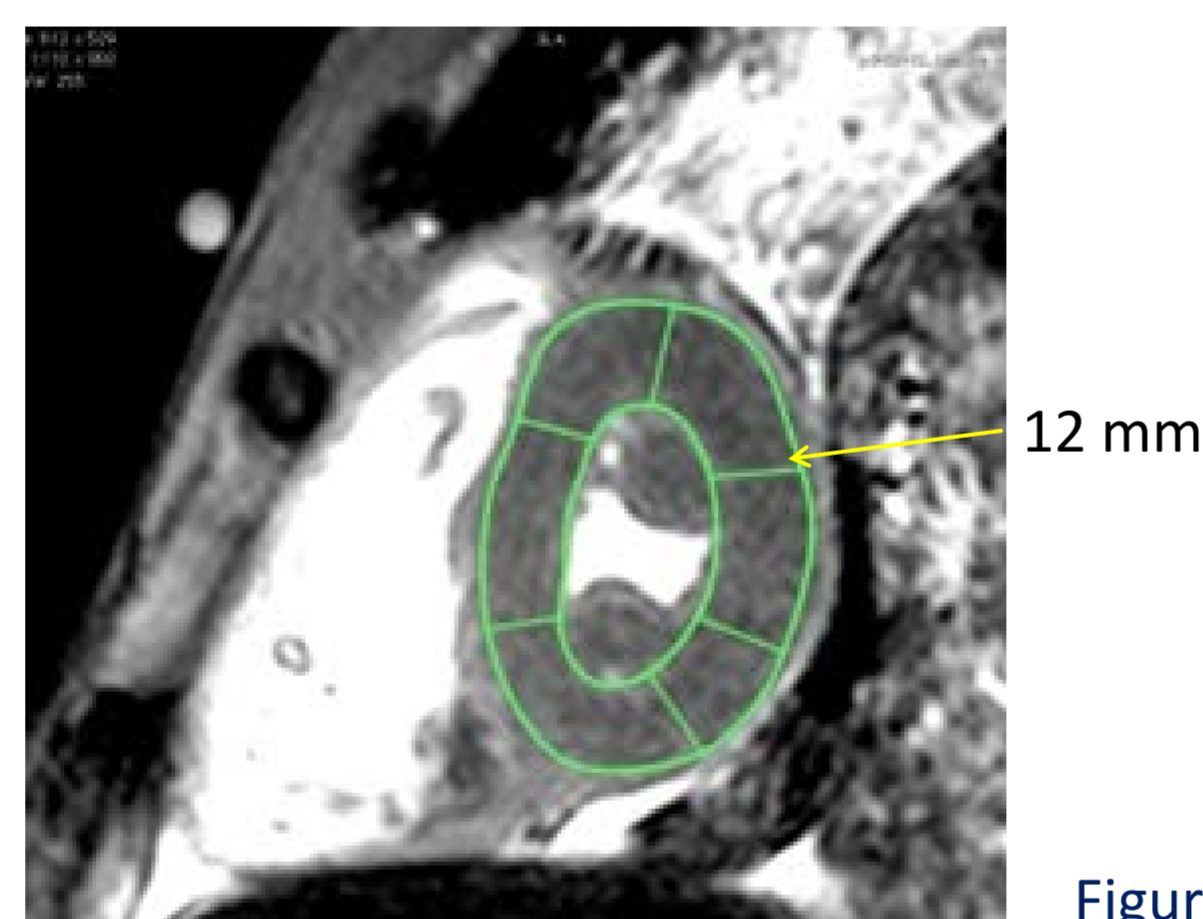


Figure 2.

Edema is diagnosed on pmcMRI by comparing the segmental signal intensities. A segment with a signal intensity higher than 2SD of the segment with the lowest signal is defined as representing edema (figure 3). Guided by the pmcMRI samples from the myocardium are taken and freeze dried to correlate the diagnosed edema with the myocardial water content (figure 4). Further samples are taken for histopathology (HE and van Gieson).

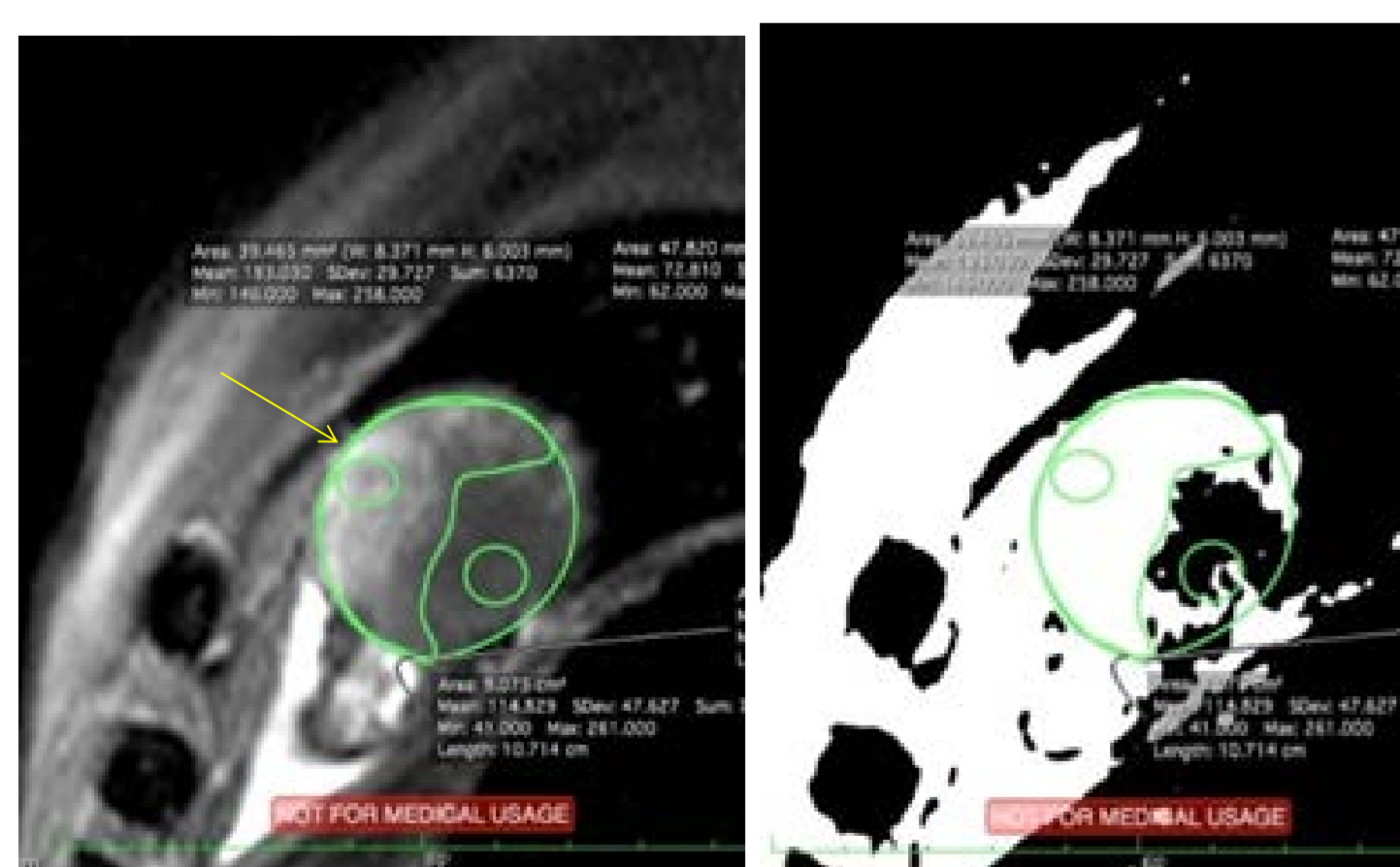


Figure 3. pmcMRI with edema (a. and b.)

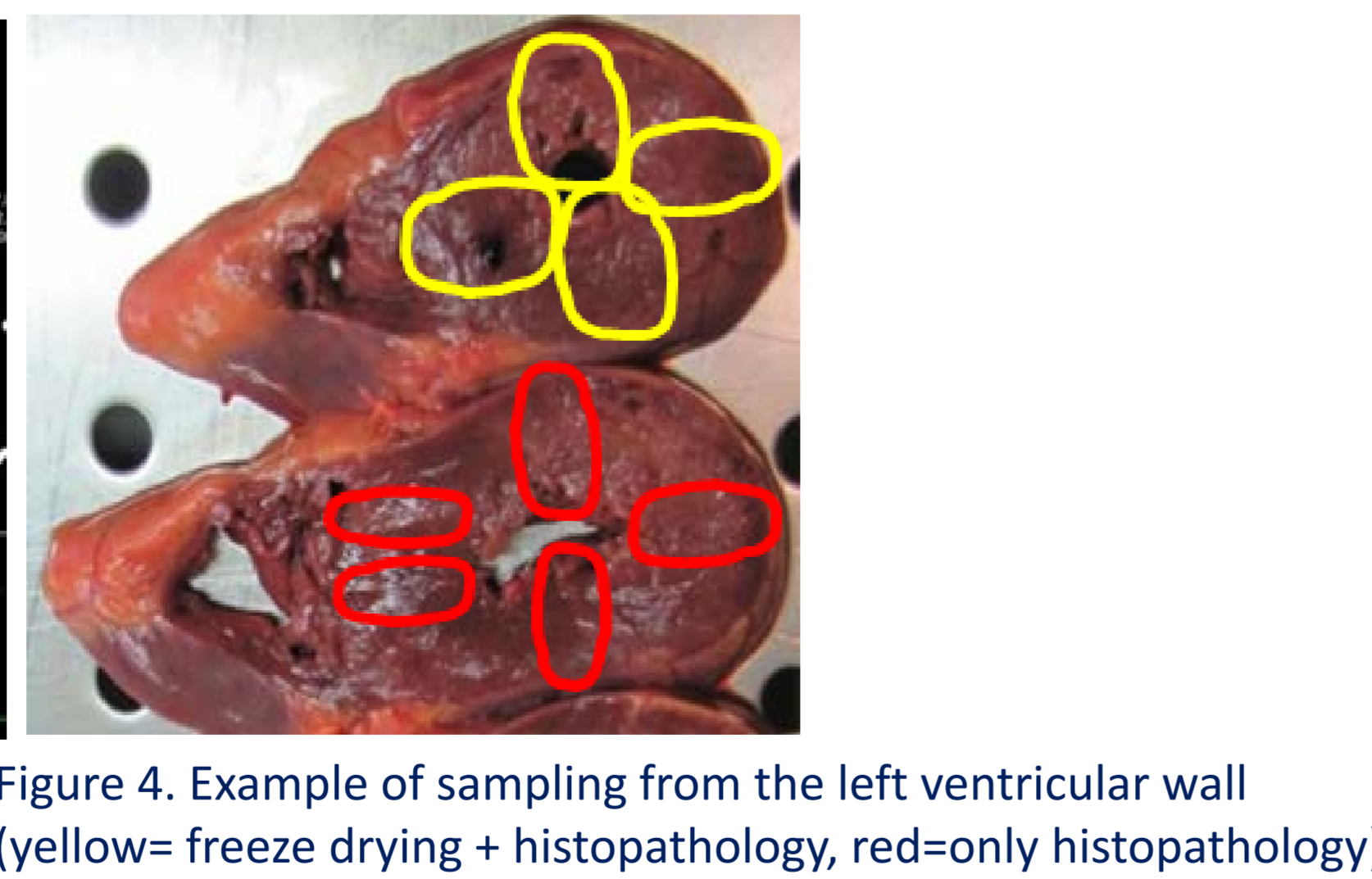
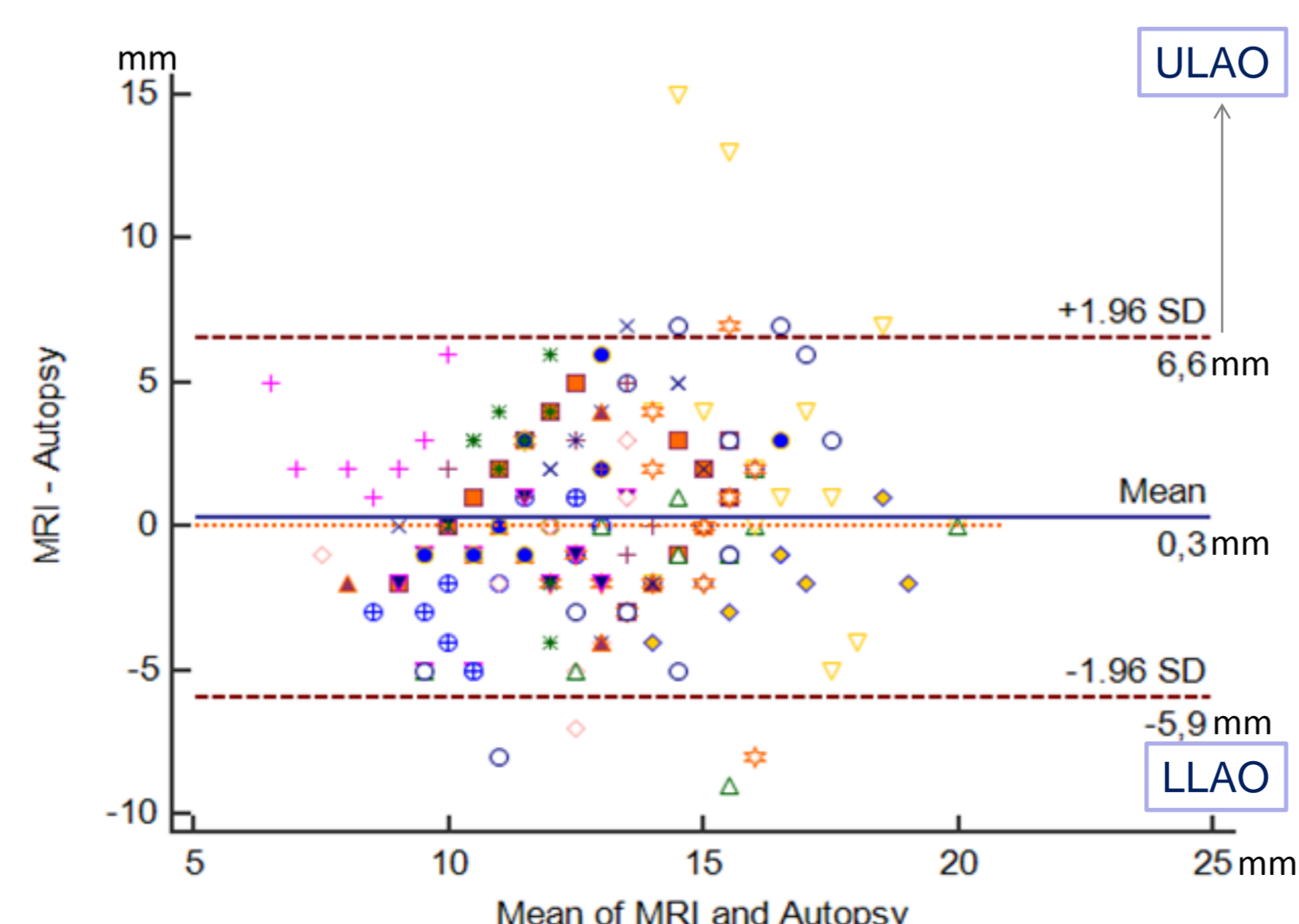


Figure 4. Example of sampling from the left ventricular wall (yellow= freeze drying + histopathology, red=only histopathology)

## Preliminary results

The measurement of the left ventricular wall thickness shows varying agreement between the two methods (Bland-Altman Plot) with a mean bias between the measurement methods of 0,3 mm (SD 3,185 mm). The outliers are caused by difficulty to differentiate papillary muscle from ventricular wall on the pmcMRI.



Method A/B: MRI/Autopsy  
Sample size 240

One symbol represents the 16 measurements in one case.  
5 cases were excluded due to skewness or suboptimal image quality.

**Hypertrophy** (ventricular wall thickness > 15 mm) is diagnosed more often on the pmcMRI than at autopsy (table 2). The correlation between the frontal, septal and posterior segments is good, but poor between the lateral segments (data not shown).

2x2 table	Disease Present		Disease Absent
	Test Positive:	39	49
Test Negative:	9	182	191
	19	221	

Table 2. Correlation of hypertrophy diagnosis on pmcMRI vs. autopsy

**Edema** was diagnosed in 14 cases on pmcMRI (table 3). In 9 cases the area with the highest water content corresponded to the highest signal intensity on pmcMRI. Within the same case the lowest difference in water content between the segments was 1% and the highest 14% (mean 7,8%). There were 6 cases without edema with a mean difference of water content between all 4 areas in the same case of 4,9% (SD 1,9). There was no correlation between the distribution of lividity and high signal intensity.

	Signal intensity	Difference in water content
Segments with lowest signal	69-158 (mean:115,5, SD:28,4)	0,1394 - 0,5309 (mean:0,3755)
Segments with highest signal	122 - 210 (mean:165, SD:28,7)	0,839 - 0,6292 (mean: 0,3464)

Table 3. The difference in signal intensities and water content after freeze drying

**Microscopy** showed a range of histopathologic changes involving different stages of infarction (table 4 and figure 5), which corresponded to the macroscopic findings in 14 cases. In 1 case there were atherosclerotic changes and histopathologically myocarditis sequelae.

Histopathologic changes	N findings
Wavy hyper contracted fibers	4
Edema	5
Hemorrhage	1
Beginning of neutrophil infiltration	1
Beginning of necrosis with paleness	1
Pycnosis of nuclei	1
Marginal contraction band necrosis	1
Eosinophilia	4
Loss of striation	1
Granulation tissue	2
Fibrosis	5
Hypertrophy of myocytes	6
Myocyt disarray	1
Basophil degeneration	1
Interstitial fibrosis	1
Leucocytes infiltration	1

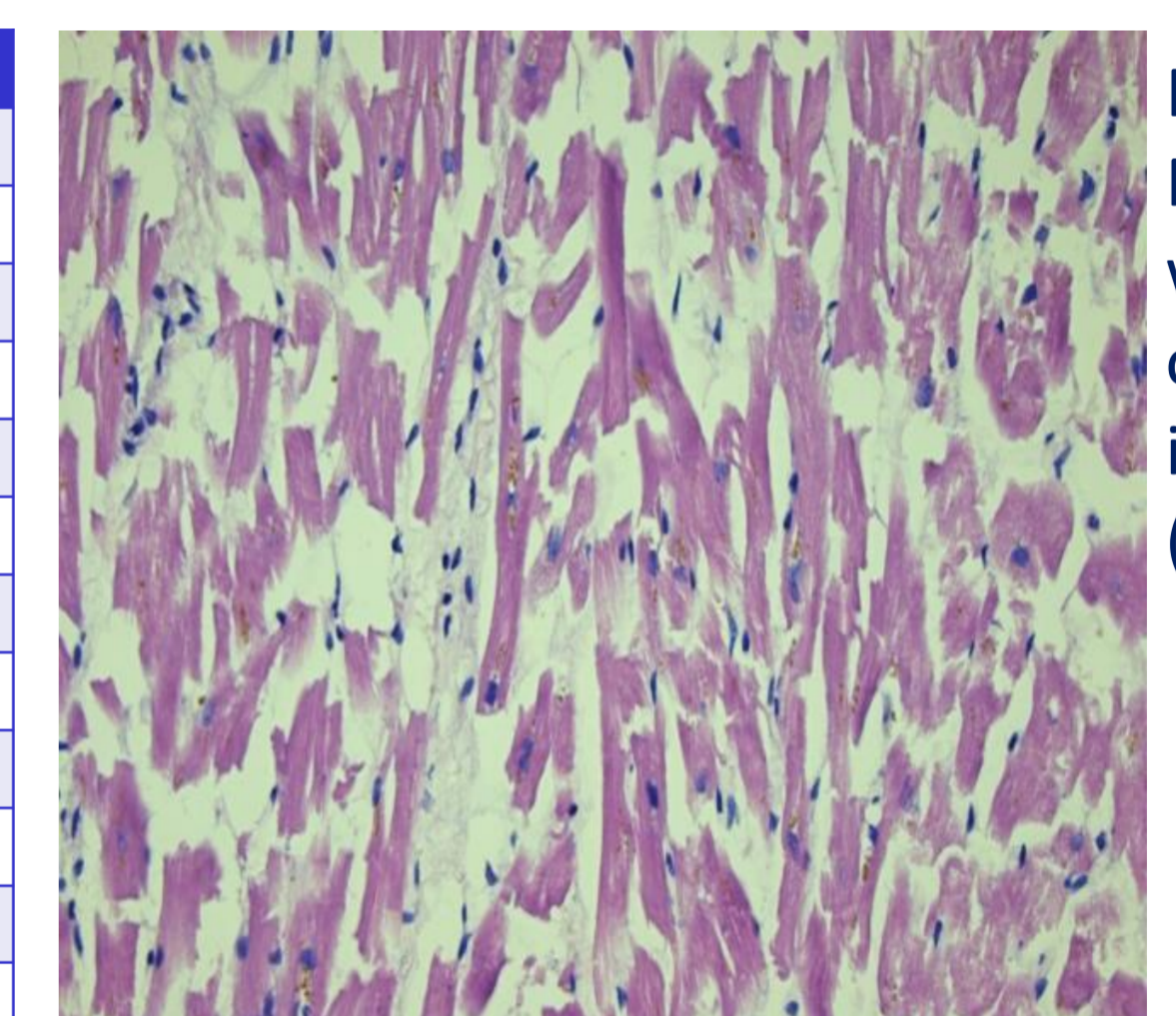


Figure 5. Myocytes with edema of the interstitium (HE)

Table 4. The registered histopathologic changes  
2 cases were excluded due to putrefaction

**Correlating edema with macroscopic atherosclerotic, myocardial and histopathologic changes** showed an overall good agreement (table 5).

Tabel 5.		Macroscopic atherosclerotic change		Macroscopic myocardial change		Histopathologic change	
		+	-	+	-	+	-
Edema (pmcMRI)	+	9	5	7	7	6	6
	-	1	5	2	4	5	1

## Discussion

The preliminary results show a good correlation between the measurements of ventricular wall thickness regarding the anterior, posterior and septal segments. The measurement of lateral segments was generally too wide on pmcMRI compared to the autopsy results resulting in a too frequent hypertrophy diagnosis.

The correlation between the diagnosis of edema and the results from the freeze drying were overall good. In a few cases the results did not match which needs to be elucidated further. The overall correlation between the macro- and microscopic findings with the pmcMRI was acceptable.

The results show good reason to continue the study and we believe that the use of pmcMRI in cardiovascular pathology is a useful adjunct to the forensic autopsy.

**Abbreviations:** cardiovascular disease (CVD), cardiac Magnetic Resonance Imaging (cMRI), post-mortem cardiac MRI (pmcMRI), post-mortem Computed Tomography (pmCT), proton density (PD), Upper limit of agreement (ULLAO), lower limit of agreement (ULLAO), left coronary artery (LCA), left anterior descending artery (LAD), circumflex artery (CX), right coronary artery (RCA)

**Literature:** <sup>1</sup>Pennell DJ et al. European Heart Journal (2004) 25, 1940-1965  
<sup>2</sup>Michaud K. Int J Legal Med (2014) 128:127-137  
<sup>3</sup>Jackowski C et al. Eur Radiol. 2011 Jan;21(1):70-8.  
<sup>4</sup>Jackowski C et al. J Am Coll Cardiol 2013 Aug 13;62(7):617-29  
<sup>5</sup>Cerqueira MD et al. Circulation 2002, 105:539-542.

Corresponding author: christina.jacobsen@sund.ku.dk  
For further information on the SURVIVE study use the QR-code or visit the website <http://retsmedicin.ku.dk/english/research/surviveprojects/>

