



## Embolic encephalitis in a porcine model of endocarditis

Christiansen, Johanna Kristina G; Oscarson, Malin; Jensen, Henrik Elvang; Johansen, Louise Kruse; Koch, Janne; Aalbæk, Bent; Nielsen, Ole Lerberg; Iburg, Tine Moesgaard; Leifsson, Páll S.

*Published in:*  
In Vivo

*Publication date:*  
2013

*Document version*  
Early version, also known as pre-print

*Citation for published version (APA):*

Christiansen, J. K. G., Oscarson, M., Jensen, H. E., Johansen, L. K., Koch, J., Aalbæk, B., ... Leifsson, P. S. (2013). Embolic encephalitis in a porcine model of endocarditis. *In Vivo*, 27(5), 591-597.

- 5 Berson EL, Rosner B, Sandberg MA, Weigel-DiFranco C, Brockhurst RJ, Hayes KC, Johnson EJ, Anderson EJ, Johnson CA, Gaudio AR, Willett WC and Schaefer EJ: Clinical trial of lutein in patients with retinitis pigmentosa receiving vitamin A. *Arch Ophthalmol* 128: 403-411, 2010.
- 6 Dalke C and Graw J: Mouse mutants as models for congenital retinal disorders. *Exp Eye Res* 81: 503-512, 2005.
- 7 Rivas MA and Vecino E: Animal models and different therapies for treatment of retinitis pigmentosa. *Histol Histopathol* 24: 1295-1322, 2009.
- 8 Tsubura A, Yoshizawa K and Kuro M: *N*-Methyl-*N*-nitrosourea animal models for retinitis pigmentosa. In: *Animal Models for the Study of Human Disease*. Conn M (ed.). Oxford, Elsevier, pp. 117-142, 2013.
- 9 Sanz MM, Johnson LE, Ahuja S, Ekstrom PA, Romero J and van Veen T: Significant photoreceptor rescue by treatment with a combination of antioxidants in an animal model for retinal degeneration. *Neuroscience* 145: 1120-1129, 2007.
- 10 Tsuruma K, Yamauchi M, Inokuchi Y, Sugitani S, Shimazawa M and Hara H: Role of oxidative stress in retinal photoreceptor cell death in *N*-methyl-*N*-nitrosourea-treated mice. *J Pharmacol Sci* 118: 351-362, 2012.
- 11 Ammon HP and Wahl MA: Pharmacology of *Curcuma longa*. *Planta Med* 57: 1-7, 1991.
- 12 Sharma RA, Gescher AJ and Steward WP: Curcumin: The story so far. *Eur J Cancer* 41: 1955-1968, 2005.
- 13 Zhou H, Beevers CS and Huang S: The targets of curcumin. *Curr Drug Targets* 12: 332-347, 2011.
- 14 Noorafshan A and Ashkani-Esfahani S: A Review of therapeutic effects of curcumin. *Curr Pharm Des* 19: 2032-2046, 2013.
- 15 Vasireddy V, Chavali VR, Joseph VT, Kadam R, Lin JH, Jamison JA, Kompella UB, Reddy GB and Ayyagari R: Rescue of photoreceptor degeneration by curcumin in transgenic rats with P23H rhodopsin mutation. *PLoS One* 6: e21193, 2011.
- 16 Woo JM, Shin DY, Lee SJ, Joe Y, Zheng M, Yim JH, Callaway Z and Chung HT: Curcumin protects retinal pigment epithelial cells against oxidative stress via induction of heme oxygenase-1 expression and reduction of reactive oxygen. *Mol Vis* 18: 901-908, 2012.
- 17 Zhao J, Yu S, Zheng W, Feng G, Luo G, Wang L and Zhao Y: Curcumin improves outcomes and attenuates focal cerebral ischemic injury via antiapoptotic mechanisms in rats. *Neurochem Res* 35: 374-379, 2010.
- 18 Yoshizawa K, Yang J, Senzaki H, Uemura Y, Kiyozuka Y, Shikata N, Oishi Y, Miki H and Tsubura A: Caspase-3 inhibitor rescues *N*-methyl-*N*-nitrosourea-induced retinal degeneration in Sprague-Dawley rats. *Exp Eye Res* 71: 629-635, 2000.
- 19 Doonan F, Donovan M and Cotter TG: Caspase-independent photoreceptor apoptosis in mouse models of retinal degeneration. *J Neurosci* 23: 5723-5731, 2003.
- 20 Wang L, Li C, Guo H, Kern TS, Huang K and Zheng L: Curcumin inhibits neuronal and vascular degeneration in retina after ischemia and reperfusion injury. *PLoS One* 6: e23194, 2011.
- 21 Goel A, Kunnumakkara AB and Aggarwal BB: Curcumin as "Curcumin": From kitchen to clinic. *Biochem Pharmacol* 75: 787-809, 2008.
- 22 EFSA Panel on Food Additives and Nutrient Sources added to Food (ANS): Scientific Opinion on the reevaluation of curcumin (E 100) as a food additive. *EFSA J* 8: 1679, 2010.
- 23 Sintara K, Thong-Ngam D, Patumraj S and Klaikeaw N: Curcumin attenuates gastric cancer induced by *N*-methyl-*N*-nitrosourea and saturated sodium chloride in rats. *J Biomed Biotechnol* 2012: 915380, 2012.
- 24 Matteucci A, Cammarota R, Paradisi S, Varano M, Balducci M, Leo L, Bellentani GC, De Nuccio C, Carnovale-Scalzo G, Sciorcia G, Frank C, Maltozzi C, Di Stasi AM, Visentin S and Mulchiodi-Albedi F: Curcumin protects against NMDA-induced toxicity: A possible role for NR2A subunit. *Invest Ophthalmol Vis Sci* 52: 1070-1077, 2011.
- 25 Mandal MN, Padolla JM, Zheng L, Agbaga MP, Tran JT, Wicker L, Kasus-Jacobi A, Elliott MH, Rao CV and Anderson RE: Curcumin protects retinal cells from light-and oxidant stress-induced cell death. *Free Radic Biol Med* 46: 672-679, 2009.
- 26 Dryja TP, McGee TL, Reichel E, Hahn LB, Cowley GS, Yandell DW, Sandberg MA and Berson EL: A point mutation of the rhodopsin gene in one form of retinitis pigmentosa. *Nature* 343: 364-366, 1990.
- 27 Burugula B, Ganesh BS and Chintala SK: Curcumin attenuates staurosporine-mediated death of retinal ganglion cells. *Invest Ophthalmol Vis Sci* 52: 4263-4273, 2011.
- 28 Kowluru RA and Kanwar M: Effects of curcumin on retinal oxidative stress and inflammation in diabetes. *Nutr Metab (Lond)* 4: 8, 2007.
- 29 Paik SS, Jeong E, Jung SW, Ho TJ, Kang S, Sim S, Jeon JH, Chun MH and Kim IB: Anthocyanins from the seed coat of black soybean reduce retinal degeneration induced by *N*-methyl-*N*-nitrosourea. *Exp Eye Res* 97: 55-62, 2012.

Received May 20, 2013

Revised June 19, 2013

Accepted June 20, 2013

## Embolc Encephalitis in a Porcine Model of Endocarditis

JOHANNA GYLLENSTEN CHRISTIANSEN<sup>1</sup>, MALIN OSCARSON<sup>1</sup>, HENRIK ELVANG JENSEN<sup>1</sup>, LOUISE KRUSE JENSEN<sup>1</sup>, JANNE KOCH<sup>1</sup>, BENT AALBÆK<sup>1</sup>, OLE LERBERG NIELSEN<sup>1</sup>, TINE MOESGAARD IBURG<sup>2</sup> and PÁLL SKÚLI LEIFSSON<sup>1</sup>

<sup>1</sup>Department of Veterinary Disease Biology, Faculty of Health and Medical Sciences, University of Copenhagen, Copenhagen, Denmark;

<sup>2</sup>Department of Pathology and Wildlife Disease, National Veterinary Institute, Uppsala, Sweden

**Abstract.** Background: Endocarditis is a severe disease in which neurological complications are frequent and associated with increased mortality and complex disease management. In the present study, the pig was evaluated as a model of embolic encephalitis as a complication of experimental infective endocarditis. Materials and Methods: Brains from pigs with experimental *Staphylococcus aureus*-associated infective endocarditis (IE; n=2), experimental non-bacterial thrombotic endocarditis (NBTE; n=5), experimental *S. aureus* sepsis without endocarditis (SNE; n=3) and saline controls (n=3), were used. The brains were examined for lesions macroscopically, histologically and immunohistochemically. Results: Lesions of focal encephalitis were found in the IE and SNE pigs, at considerably higher numbers in the IE pigs. Furthermore, microabscesses were common in the IE pigs, which fits the association between brain abscesses and *S. aureus*-associated endocarditis in humans. Conclusion: Experimental porcine *S. aureus*-associated endocarditis is advantageous for studying neurological complications, such as brain abscess formation, as a result of endocardial bacterial seeding.

Endocarditis is a severe disease which is associated with a significant risk of embolism to other tissues, particularly the brain (1, 2). In infective endocarditis (IE), neurological complications are frequent, strongly associated with mortality and can complicate management of the disease (3). Septic embolism to the brain can result in encephalitis with abscess formation, which in itself is a life-threatening condition (4). Hematogenous spread from a primary

infection outside of the central nervous system (CNS) is an important cause of brain abscesses in humans (5), where bacterial endocarditis and chronic pulmonary infection are the most common foci of primary infection (6, 7). The most frequent etiological agents of brain abscesses in humans are *Streptococcus* spp. and *Staphylococcus aureus* (5), which parallels *S. aureus* as the leading cause of IE (8, 3). Animal models can be valuable in increasing the knowledge of a disease, as well as for improving therapeutic and diagnostic methods. Experimental models of brain abscess have been described, however, the majority are produced by bacterial inoculation into a local artery supplying the brain (9, 10), or via direct inoculation into the brain parenchyma (10-14). Despite the high frequency of neurological complications in endocarditis, there is currently no description of a model of brain abscess formation as a complication of endocarditis, where hematogenous spread from a primary infectious focus causes the disease.

The size of the pig is advantageous in that it allows for utilization of human diagnostics and treatment methods, for example with regard to diagnostic imaging and surgical procedures. Furthermore, the finding of encephalic microabscesses in pigs with spontaneous endocarditis has been recently described (15), which leads to the theory that the pig may be a suitable model for this disease complex. However, there are no reports of examinations of brains from pigs with experimental endocarditis. Thus, the aim of this study was to evaluate the pig as a model of embolic encephalitis as a complication of endocarditis.

### Materials and Methods

**Experimental design.** Brain material from 13 pigs originating from two previous experiments in which the impact on the CNS was not examined, were used in the present study: one experimental porcine endocarditis study and one experiment of porcine *S. aureus* sepsis, respectively (Table 1). The experimental animals were clinically healthy, female Yorkshire-Landrace crossbreed pigs with a body weight (BW) of 13-25 kg (6-10 weeks of age). The pigs originated

Correspondence to: Johanna Gyllenstein Christiansen, Department of Veterinary Disease Biology, Faculty of Health and Medical Sciences, University of Copenhagen, Ridebanevej 3, DK-1870 Frederiksberg, Denmark. E-mail: jogy@sund.ku.dk

Key Words: Endocarditis, embolic encephalitis, porcine model, pig.

Table I. Experimental design and grouping of pigs.

Group	Pig number	Saline/ bacterial strain	First inoculation	Second inoculation	Time from first inoculation to euthanasia
Saline controls	1	Saline	T: 0	-	12 h
	2	Saline	T: 0	T: 12 h	24 h
	3	Saline	T: 0	T: 12 h	48 h
Septic non-endocarditic	4*	<i>S. aureus</i> S54F9 (porcine origin)	I: 10 <sup>8</sup> CFU/kg BW T: 0	I: 10 <sup>8</sup> CFU/kg BW T: 12 h	48 h
	5*	<i>S. aureus</i> S54F9 (porcine origin)	I: 10 <sup>8</sup> CFU/kg BW T: 0	I: 10 <sup>8</sup> CFU/kg BW T: 12 h	48 h
	6*	<i>S. aureus</i> S54F9 (porcine origin)	I: 10 <sup>8</sup> CFU/kg BW T: 0	I: 10 <sup>8</sup> CFU/kg BW T: 12 h	48 h
Non-bacterial thrombotic endocarditis	7	<i>S. aureus</i> S54F9 (porcine origin)	I: 10 <sup>5</sup> CFU/kg BW T: 0	I: 10 <sup>6</sup> CFU/kg BW T: 7 days	11 days
	8	<i>S. aureus</i> 8325-4 (human origin)	I: 10 <sup>5</sup> CFU/kg BW T: 0	I: 10 <sup>6</sup> CFU/kg BW T: 7 days	11 days
	9	<i>S. aureus</i> 8325-4 (human origin)	I: 10 <sup>7</sup> CFU/kg BW T: 0	-	4 days
	10	<i>S. aureus</i> 8325-4 (human origin)	I: 10 <sup>7</sup> CFU/kg BW T: 0	-	4 days
	11	<i>S. aureus</i> 8325-4 (human origin)	I: 10 <sup>7</sup> CFU/kg BW T: 0	-	4 days
Infective endocarditis	12*	<i>S. aureus</i> S54F9 (porcine origin)	I: 10 <sup>7</sup> CFU/kg BW T: 0	-	24 h
	13*	<i>S. aureus</i> S54F9 (porcine origin)	I: 10 <sup>7</sup> CFU/kg BW T: 0	-	48 h

T: Time from first inoculation, I: inoculum, CFU: colony-forming units, BW: body weight. \*Pigs which developed clinical sepsis during the experiment. Animals 7-13 received the first inoculation on day 4 after placement of a permanent cardiac catheter.

from the same specific pathogen-free (16) herd. In the experimental endocarditis study, seven pigs underwent surgery with placement of a permanent catheter in the left cardiac ventricle, and were intravenously inoculated through an ear vein with either the porcine *S. aureus* strain S54F9 (19) or the human *S. aureus* strain NCTC8325-4 in dosages and time frames shown in Table I. The animals were monitored clinically and echocardiographically, and euthanized on day 1, 2, 4 or 11 after the first inoculation. The six animals from the porcine *S. aureus* sepsis study did not receive a cardiac catheter, and three of the pigs were inoculated twice with the *S. aureus* strain S54F9 through an ear vein (Table I). The other three pigs without cardiac catheter served as controls and were sham-inoculated once or twice with sterile saline. The animals were euthanized at time points presented in Table I. For further detailed descriptions see Christiansen *et al.* (17) and Leifsson *et al.* (18). All procedures were performed in accordance with the Danish National Guidelines for Animal Care and were approved by the National Authority (The Animal Experiments Inspectorate, licence no. 2008/561-37) in Denmark.

**Histological preparation.** The preparation of serial sections of the brains was performed as described by Karstrup *et al.* (15). In brief, the right or left half of a formalin-fixed brain was placed in a casting mould filled with aqueous agar gel, left overnight at 5°, and subsequently cut into 4-mm transverse slices. The tissue slices were embedded in paraffin, cut and stained with hematoxylin and eosin (HE) (20). To further characterize the findings, selected slides were immunohistochemically stained. For the *in situ* detection of *S. aureus*, a monoclonal mouse antibody to *S. aureus* (21) was used at a dilution of 1:1000. For visualizing reactive astrocytes, a polyclonal rabbit antibody to glial fibrillary acidic protein (GFAP) (22) was used at a 1:2000 dilution. The presence of T-lymphocytes was confirmed by use of a monoclonal mouse antibody to CD3 (23) diluted to 1:1000,

and finally, an immunostaining for myeloperoxidase was used as a marker of neutrophils. The visualization of myeloperoxidase was initiated by antigen retrieval using a commercial antigen-retriever (DivaDecloaker 20x, Biocare Medical, LLC, Concord, CA, USA). The sections were then blocked with 4% normal goat serum (ABC kit, PK-6101; Vector Laboratories Inc., Burlingame, CA, USA) for 30 min. Endogenous biotin was blocked with an avidin solution for 15 min followed by a biotin solution for 15 min (Vector Laboratories Inc.). The primary antibody identifying myeloperoxidase was a polyclonal rabbit anti-human antibody (A 0398; DakoCytomation, Denmark A/S, Glostrup, Denmark) used at a dilution of 1:2000. Because of non-specific binding of the secondary antibody included in the ABC kit, a separate biotin-conjugated goat anti-rabbit antibody (Southern Biotech, Birmingham, AL, USA) was used at a 1:500 dilution. Thereafter, the ABC complex was incubated with the sections for 30 min, before treatment with the chromogen (DAB) for 6 min. All sections were counterstained with Mayer's hematoxylin. Positive, negative and nonsense controls were included in the myeloperoxidase staining, as well as in the other immunohistochemical protocols (21-23).

**Histology.** The animals were divided into four groups based on the presence or absence of clinical sepsis and endocardial pathology, respectively, as shown in Table I. All tissue sections were blinded and systematically examined in their entirety, and the results were recorded for each histological slide as lesion type, number, characteristics and localization. An exact count of lesions was performed up to 100; more numerous lesions were registered as >100. The localization of lesions within the different anatomical parts of the brain was registered, including the placement within white matter, grey matter, or grey-white junction. Additionally, for every finding, whether bacteria were identified in relation to the lesion was registered.

Table II. Definitions and categorization of brain lesions found in the pigs.

Lesion	Definition	Classification
A: Focal encephalitis	Focal or multifocal accumulation of inflammatory cells within the brain parenchyma	Loosely suppurative (Figure 1a) Microabscess (Figure 1d) Densely organized round cells (Figure 1b and c) Chronic focal encephalitis dominated by mononuclear cells
B: Perivascular accumulation of inflammatory cells	Perivascular accumulation of inflammatory cells	Including neutrophils (Figure 1e) Mononuclear cells exclusively
C: Leptomeningitis	Infiltration of inflammatory cells in the leptomeninges	Neutrophilic Mononuclear
D: Choroid plexitis	Infiltration of inflammatory cells in the choroid plexus	Neutrophilic

Table III. Type and number of lesions found in the brains from the experimental pigs.

Lesion	Saline controls		Septic non-endocarditic			Non-bacterial thrombotic endocarditis					Infective endocarditis		
	1	2	3	4	5	6	7	8	9	10	11	12	13
Pig no.													
Focal encephalitis													
Suppurative						6						13	11
Microabscess				1								21	20
Densely organized round cells												20	8
Chronic focal encephalitis													
Perivascular accumulation of inflammatory cells	12	2	2	2	3	7	10	8	19	7	7	>100	>100
Leptomeningitis <sup>†</sup>													
Neutrophilic				25	28	21						13	6
Mononuclear								25				1	3
Choroid plexitis <sup>†</sup>													
-neutrophilic				6		2						3	1

<sup>†</sup>Choroid plexitis and leptomeningitis were registered as present or not present per slide and the number reported is therefore the number of slides in which the lesion was present. All other lesions were registered as the number of lesions per histological slide, and then totalled-up to give the reported number.

## Results

**Pathology.** No macroscopic lesions were observed in the brains. The microscopic brain lesions could be categorized into four main types (A-D), as summarized in Table II, with the registered number of lesions presented in Table III.

A: Focal encephalitis was subdivided based on morphology into loosely suppurative (Figure 1a), more organized round cells (Figure 1b and c) and chronic focal encephalitis, and was present in all animals with IE and in two of the SNE pigs (no. 4 and 6). The SNE pigs had two and nine lesions, respectively, while there were 54 and 39 in the animals with IE. In both groups, there was a clear reaction in the vessels surrounding the encephalitic processes, consisting of reactive endothelial cells, vasculitis and perivascularitis. Many of the processes with

densely organized round cells had a distinct concentric arrangement (Figure 1b). Furthermore, edema and necrosis of the brain tissue were common findings within and around the lesions. There were some differences in the characteristics of the focal encephalitis in the two groups: i) Bacteria were only seen in encephalitic processes of animals with IE. ii) The lesions present in the IE animals were larger than in the SNE pigs. iii) Focal encephalitis consisting of densely organized round cells was only present in the IE animals.

B: Perivascular accumulations of inflammatory cells (Figure 1e) were present in all animals but in various numbers. The finding was most frequent in the animals with IE, both with regard to the number of perivascular accumulations that included neutrophils and overall.

C: Suppurative leptomeningitis was present in the IE and SNE pigs. In one pig with NBTE (no. 9), the presence of

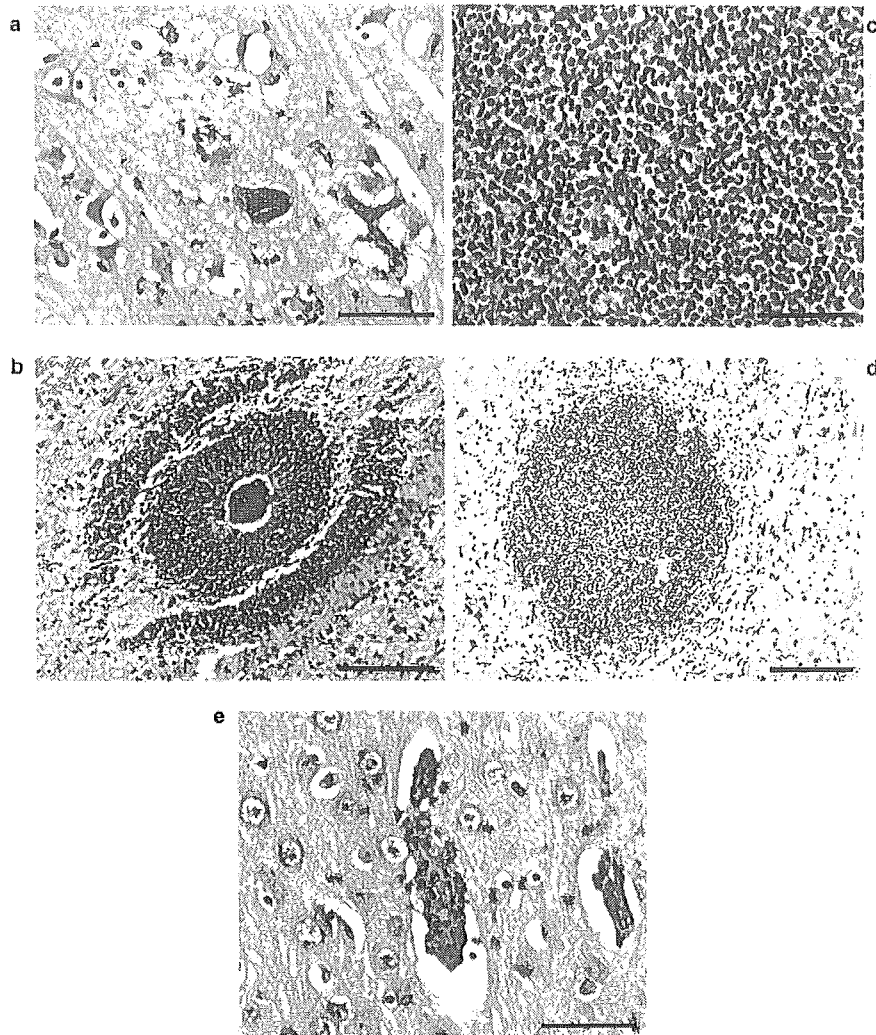


Figure 1. a: Focal encephalitis, suppurative. A bacterial colony is visible, grey matter. Pig no. 12, HE, Bar, 50 µm. b: Focal encephalitis, densely-organized round cells, grey matter. Pig no. 12, HE, Bar, 100 µm. c: Cellular details of a lesion from a pig of the focal encephalitis subgroup with densely-organized round cells. Pig no. 13, HE, Bar, 50 µm. d: Focal encephalitis, microabscess, grey matter, pig no. 12, HE, Bar, 150 µm. e: Perivascular infiltration of inflammatory cells, and an inflammatory reaction involving the vessel (vasculitis), dominated by neutrophils, grey matter. Pig no. 13, HE, Bar, 50 µm.

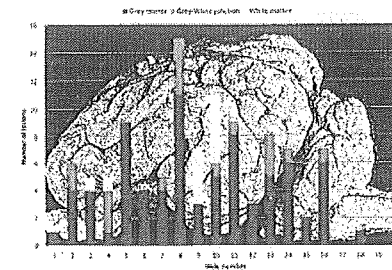


Figure 2. The localization of focal encephalitis in all pigs.

moderate mononuclear meningitis was noted. Mononuclear meningitic lesions were also present in low numbers in the animals with IE, in which the meningitis was otherwise dominated by neutrophils.

D: Suppurative choroid plexitis was registered in the animals with IE and in two SNE pigs.

Most of the type A and B lesions were present in the grey matter, followed by the grey-white junction. The localization of focal encephalitis in the brains is visualized in Figure 2.

**Immunohistochemistry.** Positive controls reacted in agreement with the various protocols, and negative and non-sense controls were without reactivity for all protocols. In the anti-CD3-stained slides, lesions of focal encephalitis with densely organized round cells were negative, with some positively stained cells in the tissue surrounding the lesions. Microabscesses were also negative, with very few positively stained cells in the surrounding tissue. Regarding perivascular accumulation of mononuclear cells, the anti-CD3 stain revealed variable results. In pigs no. 10 and 12, some positively stained cells were apparent in the perivascular accumulations. In pig no. 9, a large perivascular accumulation surrounding a large vessel contained many positively stained cells, although this pig had other, smaller perivascular accumulations where all cells were negative for CD3. In other perivascular accumulations, which included neutrophils (pig no. 13), no cells stained positively for CD3. This staining also confirmed the presence of CD3-positive cells in sections with mononuclear leptomeningitis. In tissue sections with focal encephalitis stained for GFAP, there was no staining inside the lesions, while there was a positive reaction consistent with hypertrophy and proliferation of astrocytes surrounding the lesions (Figure 3a). Furthermore, the *S. aureus* staining confirmed the findings in HE, in that all retrieved bacterial colonies stained positively (Figure 3b). With staining for

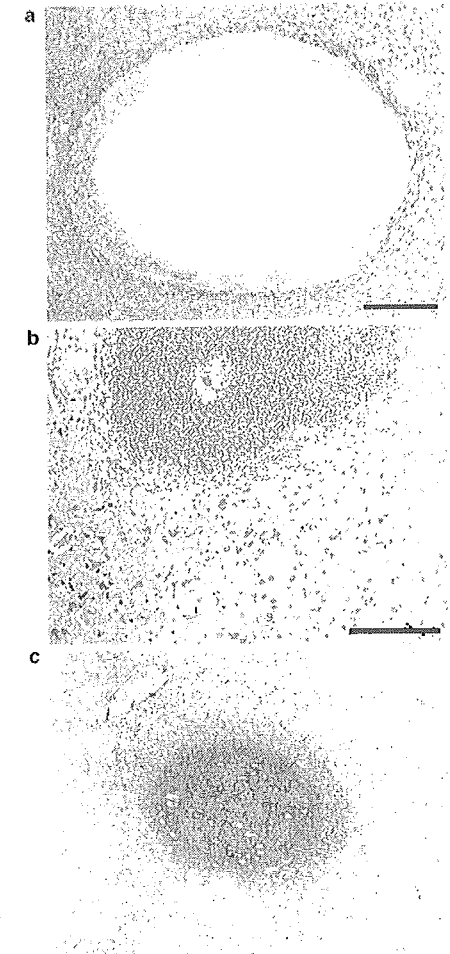


Figure 3. a: Staining of glial fibrillary acidic protein (GFAP). Focal encephalitis with densely-organized round cells. Cells located centrally in the lesion are negative and surrounded by positive cells (reactive astrocytes). White matter, pig no. 13, Bar, 200 µm. b: Immunostaining for *Staphylococcus aureus* shows positive colonies centrally located in a lesion of focal encephalitis with densely-organized round cells. Grey matter, pig no. 12, Bar, 200 µm. c: Immunostaining for myeloperoxidase, focal encephalitis. Grey matter, pig no. 12, Bar, 150 µm.

myeloperoxidase, the encephalitis subtype with densely organized round cells was further characterized. The stain showed positive cells inside the foci and in the tissue surrounding them (Figure 3c). Additionally, there was a diffuse positive reaction in and around the lesions, which gradually faded in the surrounding tissue.

## Discussion

Focal encephalitis was one of the main types of brain lesion in pigs of this study. It was only present in animals with IE and SNE, and the numbers of lesions of focal encephalitis were notably higher in the IE animals, despite the sepsis also present in the SNE pigs. This indicates that the numerous lesions of focal encephalitis in the IE pigs resulted from hematogenous spread of bacteria from the infectious focus in the heart, corresponding to the human condition (2). *S. aureus*-associated endocarditis in humans is associated with a high rate of embolic events and neurological complications are frequent, with an estimated occurrence in as many as 35-39% of the cases (8). Brain abscess is a potentially life-threatening complication of IE, and is described to be more prevalent in *S. aureus*-associated endocarditis than in IE due to other bacteria (2, 24). Brain microabscesses are more common than macroabscesses in patients with IE, and microabscesses are most commonly associated with *S. aureus* infections (25). In this study, microabscesses were common in the pigs with IE, and together with the finding of focal encephalitis with microabscesses in pigs with spontaneous bacterial endocarditis (15), this increases the potential for use of the pig as a model of this condition. The number of microabscesses in pigs with spontaneous endocarditis (15) was lower than in the IE pigs of this study, indicating that the experimental induction of *S. aureus*-associated IE is additionally favorable for hematogenous spread of bacteria to the brain.

Metastatic seeding from a primary infection outside of the CNS, such as endocarditis, is an important cause of brain abscesses in both humans (5) and animals (26). However, brain abscess formation following experimentally-induced bacteremia is described as being rare (5), as also observed in the present study, i.e. 11 foci recorded in the SNE group compared to 93 in the IE group. Therefore, experimental induction of brain abscesses has usually been performed either by inoculation through local injection into a vessel leading to the brain (9, 10), or via direct inoculation into the brain parenchyma (10-14). This, however, does not correspond to the clinical situation in the type of brain abscesses which are due to hematogenous spread of bacteria from a distant infectious focus.

Regarding the localization of lesions, brain abscesses caused by hematogenous spread of bacteria have been described to typically develop in the grey matter, since it receives a larger amount of blood than the white matter (26).

In addition, the grey-white junction is said to be predisposed for localization of brain abscesses, because of the poor microcirculatory flow in this area (26). This localization also matches the results from the current study where the lesions were predominantly found in the grey matter, followed by the grey-white junction. Differences in the volumes of the grey and white matter, respectively, might also have influenced these results.

The immunostaining for GFAP showed a positive reaction, revealing hypertrophy and proliferation of astrocytes surrounding microabscesses and in the subtype of focal encephalitis with densely organized round cells. This is in accordance with the inflammatory response in the brain, where encapsulation of lesions is normally dominated by astrocytes, as fibroblasts are sparse in the brain tissue (27). With regard to the focal encephalitis subtype with densely organized round cells, different immunostainings were utilized to identify the cell types in these lesions. The results were that the majority of cells reacted positively with the anti-myeloperoxidase stain and negatively for CD3. However, the morphology of the cells was not typical for granulocytes, and the reason for this is obscure. One theory is that the cells might have been toxically affected to achieve an unusual shape, similar to the 'oat cells' described in pneumonia (28).

Pig no. 9 differed from the other pigs with NBTE in that it had mononuclear leptomeningitis. This might be due to an individual reaction towards the inoculation. Suppurative leptomeningitis was found both in animals with IE and in the SNE pigs, and might be a consequence of the septicemic state. Furthermore, perivascular accumulations of inflammatory cells were present in all animals, although with massively elevated numbers in animals with IE compared to all other pigs. Focal lymphoid cell accumulations have been described as spontaneous lesions in the pig brain (29), although the extremely large numbers of perivascular inflammatory cell infiltrations in the IE pigs is most likely correlated to the finding of more severe inflammatory processes in the brains of these animals.

In conclusion, the brain lesions present in pigs with experimental endocarditis can be categorized into four main types. Focal encephalitis, characterized by presence of multiple microabscesses, choroid plexitis and neutrophilic leptomeningitis were found exclusively in pigs with *S. aureus*-associated endocarditis and in the SNE pigs. The highest numbers of lesions of focal encephalitis were present in animals with IE, even compared with non-endocarditic pigs with severe *S. aureus* sepsis. In general, the lesions were mainly localized in the grey matter. Brain abscesses are highly associated with *S. aureus*-associated endocarditis in humans, which parallels the observation of microabscesses as being common lesions in the IE pigs of this study. These pathological findings demonstrate that the experimental induction of *S. aureus*-associated endocarditis in pigs also is

advantageous for studying neurological complications such as brain abscess formation. Finally, it shows that the pig is a suitable animal model for hematogenously-induced brain abscesses resulting from secondary, e.g. endocardial, bacterial seeding.

## Conflicts of Interest

Authors declare no conflicts of interest.

## Acknowledgements

This work was financed by grant no. 271-07-0417 from the Danish Medical Research Council. Authors are grateful to Betina Andersen, Lisbet Kiorboe and Elizabeth Petersen for excellent laboratory support.

## References

- Lopez JA, Ross RS and Fishbein MC: Nonbacterial thrombotic endocarditis: A review. *Am Heart J* 113: 773-784, 1986.
- Prabhakaran S: Neurologic complications of endocarditis. CONTINUUM: Lifelong Learning in Neurology 14: 53-73, 2008.
- Tornos P, Gonzalez-Alujas T, Thuny F and Habib G: Infective endocarditis: The European viewpoint. *Curr Probl Cardiol* 36: 175-222, 2011.
- Muzumdar D, Jhavar S and Goel A: Brain abscess: An overview. *Int J Surg* 9: 136-144, 2011.
- Muthisen GE and Johnson JP: Brain abscess. *Clin Infect Dis* 25: 763-781, 1997.
- Sims L, Lim M and Harsh GR: Review of brain abscesses. *Oper. Tech. Neurosurg* 7: 176-181, 2005.
- Erdoğan E and Cansover T: Pyogenic brain abscess. *Neurosurg Focus* 24: E2, 1-10, 2008.
- Johnson MD and Johnson CD: Neurologic presentations of infective endocarditis. *Neurol Clin* 28: 311-321, 2010.
- Molinari GF, Smith L, Goldstein MN and Satran R: Brain abscess from septic cerebral embolism: an experimental model. *Neurology* 23: 1205-1210, 1973.
- Wood JH, Doppman JL, Lightfoote WE, Girton M and Ommaya AK: Role of vascular proliferation on angiographic appearance and encapsulation of experimental traumatic and metastatic brain abscesses. *J Neurosurg* 48: 264-273, 1978.
- Winn HR, Mendes M, Moore P, Wheeler C and Rodeheaver G: Production of experimental brain abscess in the rat. *J Neurosurg* 51: 685-690, 1979.
- Britt RH, Enzmann DR and Yeager AS: Neuropathological and computerized tomographic findings in experimental brain abscess. *J Neurosurg* 55: 590-603, 1981.
- Flaris NA and Hickey WF: Development and characterization of an experimental model of brain abscess in the rat. *Am J Pathol* 141: 1299-1307, 1992.
- Keilan T and Hickey WF: Proinflammatory cytokine, chemokine, and cellular adhesion molecule expression during the acute phase of experimental brain abscess development. *Am J Pathol* 157: 647-658, 2000.
- Karstrup CC, Jensen HE, Aalbak B, Leifsson PS, Boye M and Agerholm JS: Endocarditis-associated brain lesions in slaughter pigs. *J Comp Pathol* 144: 289-295, 2011.
- Harris DL and Alexander TJL: Methods of disease control. *In: Diseases of Swine*, 8th edn. Straw BE, Dallaire SY, Mengeling WL and Taylor DJ (eds.). Iowa: Iowa State University Press, pp. 1077-1110, 1999.
- Christiansen JG, Jensen HE, Johansen LK, Koch J, Koch J, Aalbak B, Nielsen OL and Leifsson PS: Porcine models of non-bacterial thrombotic endocarditis (NBTE) and infective endocarditis (IE) caused by *Staphylococcus aureus*: A preliminary study. *J Heart Valve Dis* 22: 368-376, 2013.
- Leifsson PS, Iburg T, Jensen HE, Agerholm JS, Kjelgaard-Hansen M, Winberg B, Heegaard PM, Astrup LB, Olsson AE, Skov MG, Aalbak B and Nielsen OL: Intravenous inoculation of *Staphylococcus aureus* in pigs induces severe sepsis as indicated by increased hypercoagulability and hepatic dysfunction. *FEMS Microbiol Lett* 309: 208-216, 2010.
- Hasman H, Moodley A, Guardabassi L, Stegger M, Skov RL and Aarestrup FM: Spa type distribution in *Staphylococcus aureus* originating from pigs, cattle and poultry. *Vet Microbiol* 141: 326-331, 2010.
- Stevens A and Wilson IG: The haematoxylin and eosin. *In: Theory and Practice of Histological Techniques*, 4th edn. Bancroft JD and Stevens A (eds.). New York: Churchill Livingstone, pp. 99-112, 1996.
- Jensen HE, Nielsen OL, Agerholm JS, Iburg T, Johansen LK, Johannesson E, Møller M, Jahn L, Munk L, Aalbak B and Leifsson PS: A non-traumatic *Staphylococcus aureus* osteomyelitis model in pigs. *In Vivo* 24: 257-264, 2010.
- Nielsen AB, Jansen ECL, Leifsson PS and Jensen HE: Immunoreactivity of bovine schwannomas. *J Comp Pathol* 137: 224-230, 2007.
- Isling LK, Aalbak B, Schröder M and Leifsson PS: Pyelonephritis in slaughter pigs and sows: Morphological characterization and aspects of pathogenesis and aetiology. *Acta Vet Scand* 52: 48, 2010.
- Røder BL, Wandahl DA, Espersen F, Fridmøller N, Skinhoj P and Rosdahl VT: Neurologic manifestations in *Staphylococcus aureus* endocarditis: A review of 260 bacteremic cases in nondrug addicts. *Am J Med* 102: 379-386, 1997.
- Williams SL and Allen BL: Neurologic manifestations of infective endocarditis. *In: Neurology and General Medicine*, 4th edn. Aminoff MJ (ed.). Philadelphia: Churchill Livingstone Elsevier, pp. 97-114, 2008.
- Zachary JF: Nervous system. *In: Pathologic Basis of Veterinary Disease*, 4th edn. McGavin MM, Zachary JF (eds.). China: Mosby Elsevier, pp. 875-877, 2007.
- Stevens A, Lowe JS and Young B: Nervous system. *In: Wheater's Basic Histopathology: A Colour Atlas and Text*, 4th edn. London: Churchill Livingstone, pp. 268-283, 2002.
- Reams RY, Glickman LT, Harrington DD, Thacker HL and Bowersock TL: *Streptococcus suis* infection in swine: A retrospective study of 256 cases. Part II. Clinical signs, gross and microscopic lesions, and coexisting microorganisms. *J Vet Diagn Invest* 6: 326-334, 1994.
- Svendson O, Skydsgaard M, Aarup V and Klastrup S: Spontaneously occurring microscopic lesions in selected organs of the Göttingen minipig. *Scand J Lab Anim Sci* 25(Suppl 1): 231-234, 1998.

Received May 14, 2013

Revised June 13, 2013

Accepted June 17, 2013