



Hepatic toxicity of artemisinin in turkeys

Thøfner, Ida; Larsen, Jytte Overgaard; Nielsen, Ole Lerberg; Liebhart, Dieter; Hess, Michael; Schou, Torben Wilde; Hess, Claudia; Ivarsen, Elise; Fretté, Xavier C.; Christensen, Lars P.; Mogensen, Jesper ; Nielsen, Kristian F.; Grevsen, Kai; Engberg, Ricarda M. ; Christensen, Jens Peter

Published in:
18th World Veterinary Poultry Association Congress

Publication date:
2013

Document version
Publisher's PDF, also known as Version of record

Citation for published version (APA):
Thøfner, I., Larsen, J. O., Nielsen, O. L., Liebhart, D., Hess, M., Schou, T. W., ... Christensen, J. P. (2013). Hepatic toxicity of artemisinin in turkeys. In *18th World Veterinary Poultry Association Congress: Proceedings* (pp. 723)

Hepatic toxicity of artemisinin in turkeys

Thøfner I¹, JO Larsen², OL Nielsen¹, D Liebhart³, M Hess³, TW Schou⁴, C Hess³, E Ivarsen⁵, XC Fretté⁵, LP Christensen⁵, J Mogensen⁶, KF Nielsen⁶, K Grevsen⁷, RM Engberg⁸ and JP Christensen¹

¹ Department of Veterinary Disease Biology, Faculty of Health and Medical Science, University of Copenhagen, ² Department of Neuroscience and Pharmacology, Faculty of Health and Medical Science, University of Copenhagen ³ Clinic for Avian, Reptile and Fish Medicine, Department for Farm Animals and Veterinary Public Health, University of Veterinary Medicine Vienna, ⁴ DHI Environment and Toxicology, DHI Group, ⁵ Institute of Chemical Engineering, Biotechnology and Environmental Technology, Faculty of Engineering, University of Southern Denmark, ⁶ Department of Systems Biology, Technical University of Denmark, ⁷ Department of Food Science, Aarhus University, and ⁸ Department of Animal Science, Aarhus University.

Conclusions

- The present findings suggest that artemisinin treatment modifies the post-natal development of the biliary duct system in turkeys.
- Artemisinin-treated birds displayed significantly higher relative length density of lumen-less bile ducts compared to control birds.
- Anisocytosis and anisokaryosis in cholangiocytes in artemisinin-treated birds.
- No differences in the volume fraction of cholangiocytes in relation to the volume of liver parenchyma between treatments.
- This is the first study that uses stereological microscopy for quantification of bile duct epithelium in turkey livers

Background

Development of resistance to anticoccidial drugs, removal of licensed antihistomonal formulations and a shift towards organic production has put the focus on natural occurring compounds for controlling protozoa infections in poultry.

Artemisinin originates from *Artemisia annua* and is widely used as an efficient antimalarial in humans.

Inhibitory activity against coccidia of chickens has been reported previously; however, toxic side effects, i.e. degeneration of the brain, liver and kidney, also were induced.

In a previous study investigating the effect of artemisinin against histomonosis in turkeys and chickens, artemisinin was administered in the feed to day-old turkeys (Thofner *et al.* 2012). As a result, sudden deaths occurred on day 5 and 6 in the group receiving 2600 mg artemisinin per kg feed, and the remaining birds in the group were subsequently euthanized.

Histology indicated bile duct proliferation of the treated turkeys.

Aim

The aim was to demonstrate the liver as the main target organ for acute toxicity of artemisinin both quantitatively and qualitatively in one-week old turkeys suspected of artemisinin intoxication by unbiased stereology.

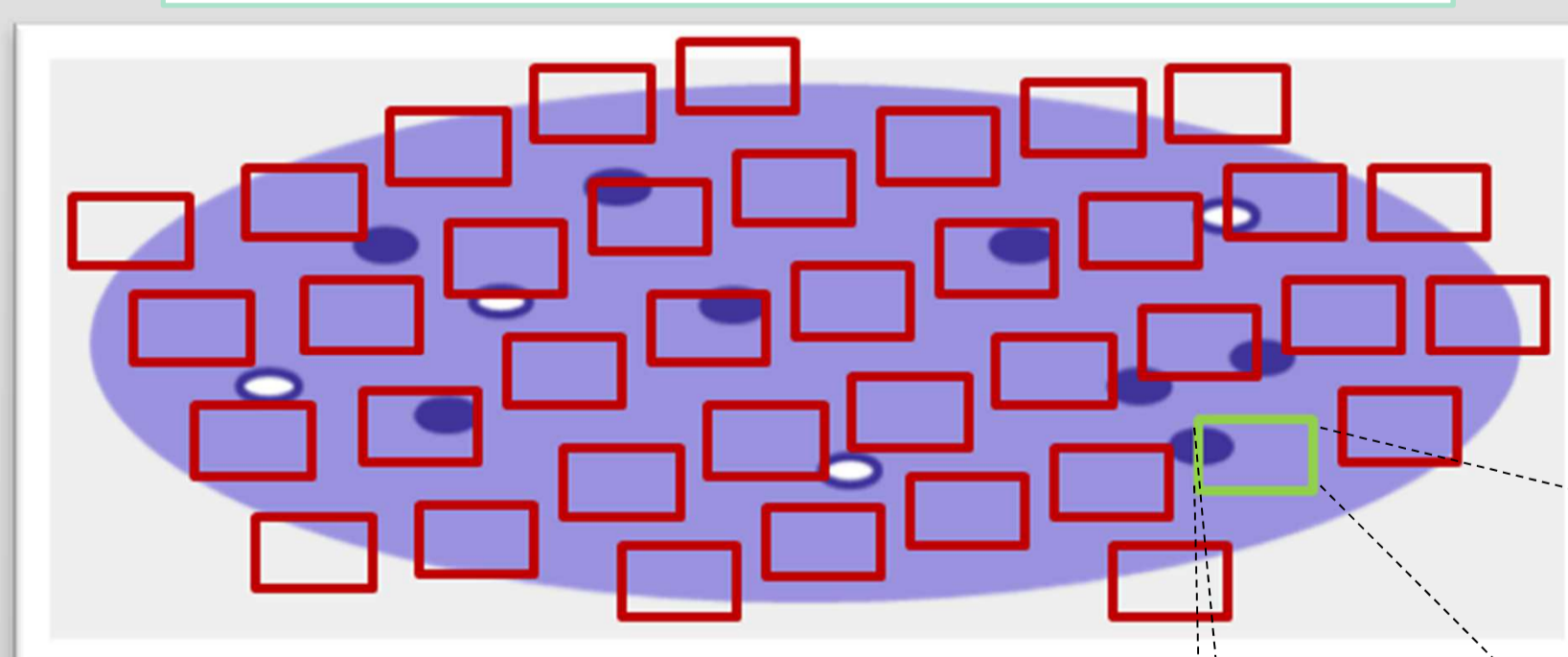
Histological preparation

– Formalin-fixed liver samples from artemisinin-treated turkey poults (5-7 days old, n=15) and untreated and normal untreated age-matched birds (n=10) in 4 µm thick sections.

– Immune staining of cytokeratin in biliary epithelium (Cytokeratin clone AE1/AE3, DAKO) to distinguish the cholangiocytes from liver parenchyma, connective tissue and blood vessels.

Stereology of bile ducts

Schematic overview of liver section



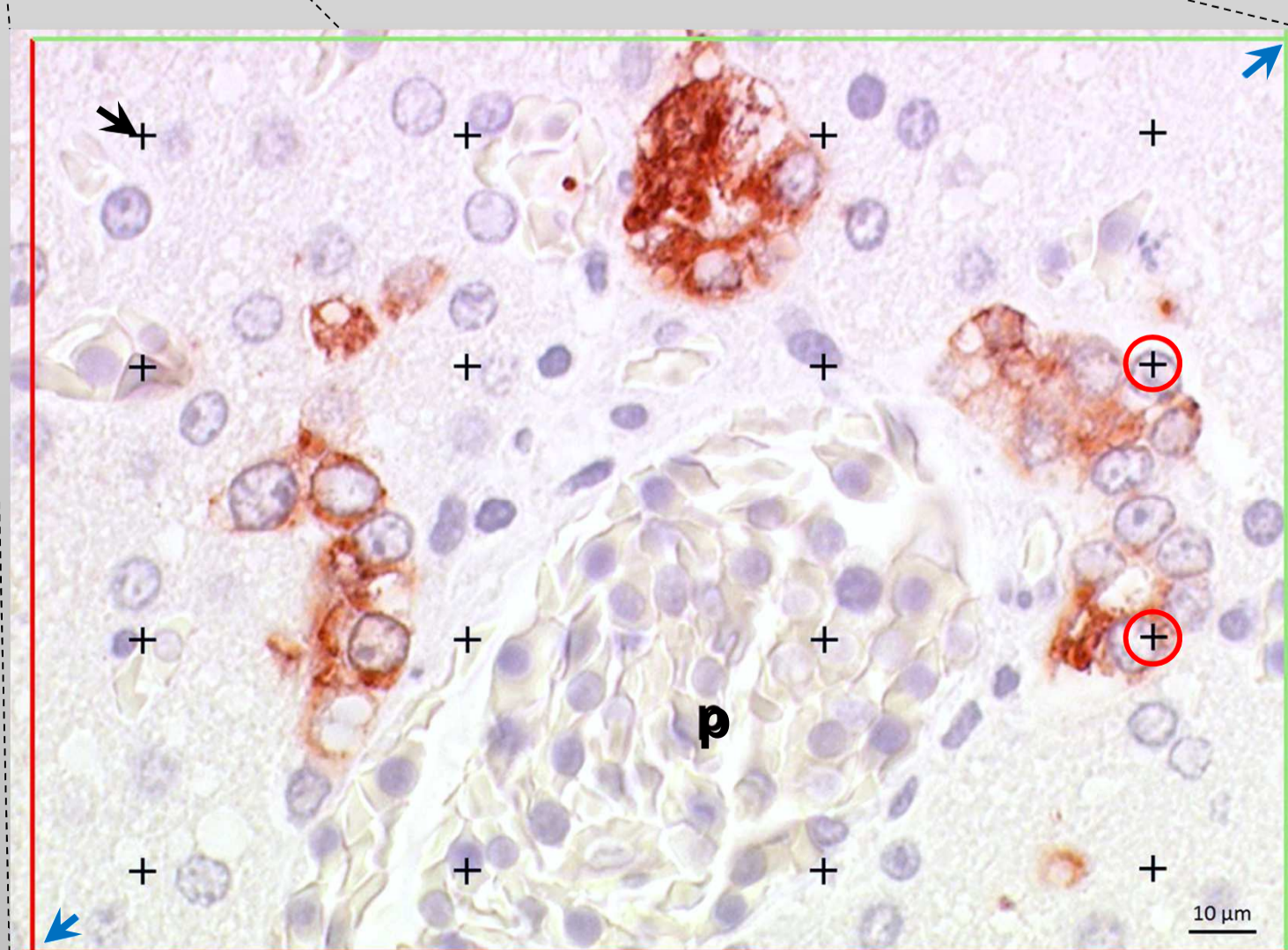
- Microscope with a motorized stage for accurate positioning at predefined steps of 400 µm (dx=dy)
- Random start
- ≥ 200 sampling areas

Volume fraction:

- Using point grid counting (**black arrow**)
- Cholangiocytes (**red circles**)/reference space (liver parenchyma including cholangiocytes)

Relative length density:

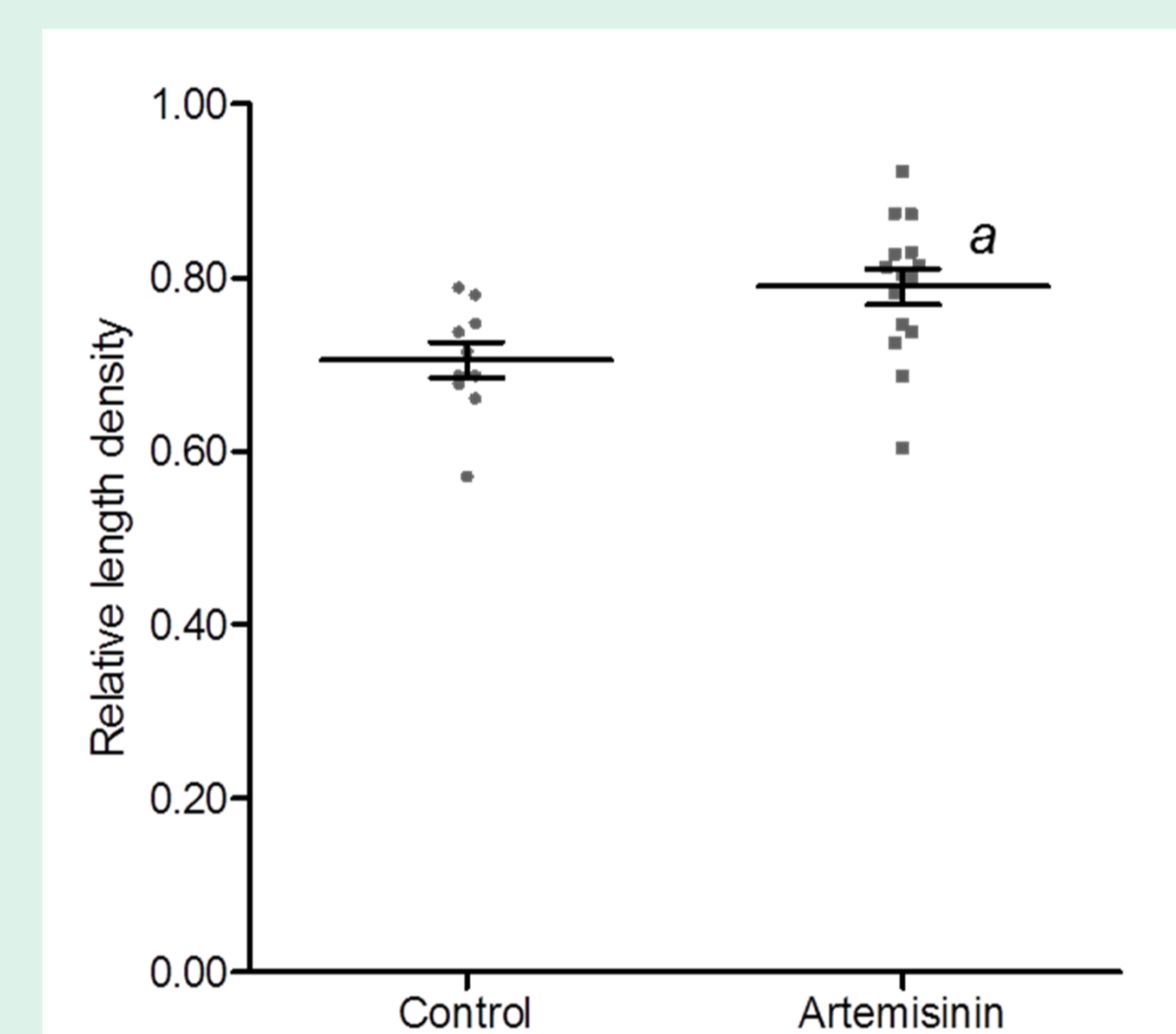
- Determination of bile duct with or without lumen per counting frame (**blue arrows**)
- Length density of lumen-less bile ducts/ total length density of all bile ducts.



Artemisinin-treated poult
p: portal vessel

Quantitative Results

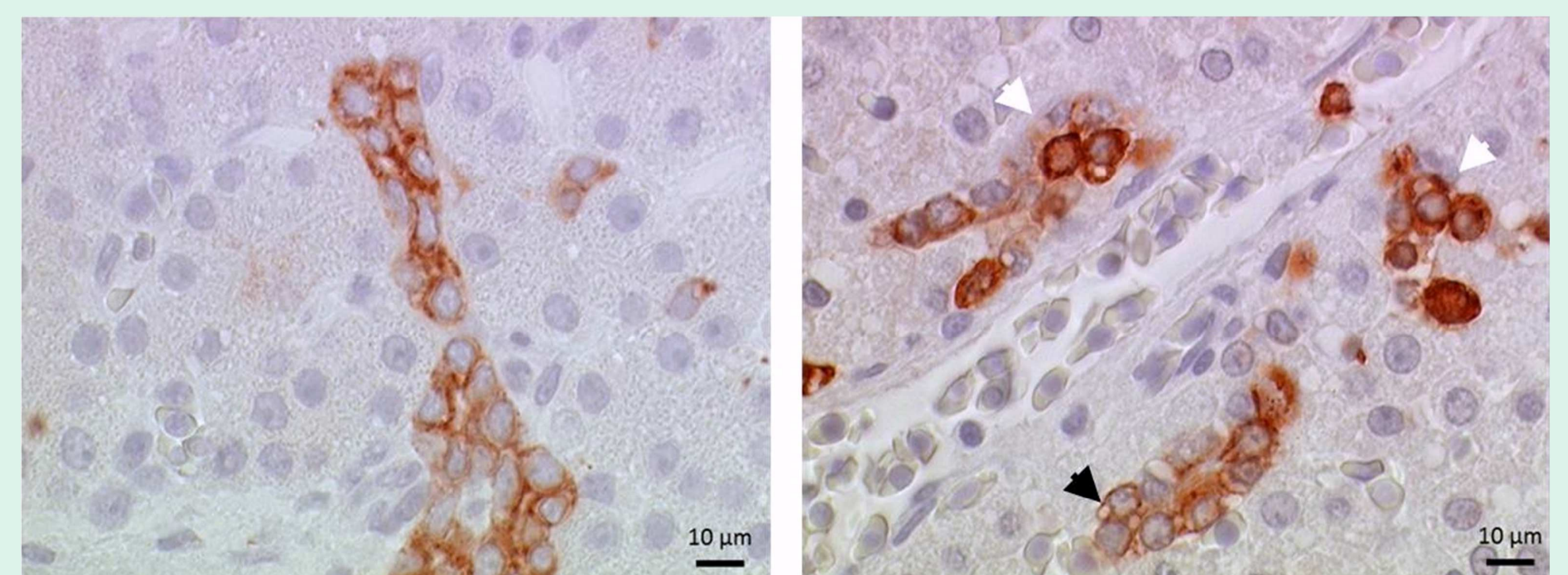
	Control (n=10)	Artemisinin (n=15)	p-value
Volume fraction (%)	1.15 ± 0.08	1.07 ± 0.08	0.4945
Relative length density (%)	70.56 ± 2.02	78.99 ± 2.07^a	0.0107



- No differences in the volume fraction of bile duct epithelium in relation to the volume of liver parenchyma between treatments
- Higher relative length density of lumen-less bile ducts in artemisinin-treated poults

Qualitative Results

- Pleomorphic appearance of biliary epithelial cells in artemisinin-treated poults.
 - Epithelial **anisocytosis** and **anisokaryosis** (**white arrowheads**).
 - Intracellular vacuoles (**black arrowhead**)
 - Irregular organization of cholangiocytes (**B**)



A – Control bird

B – Artemisinin treated bird

Cytokeratin stain of bile ducts.

Discussion

- The higher relative length density of lumen-less bile ducts indicates a proliferative response of the epithelium.
 - Artemisinin exposure or bile retention
- Bile retention in the mature bile ducts can explain the equal volume fractions.
- Epithelial pleomorphism suggests that high doses of artemisinin modifies the development and differentiation of the immature bile ducts in turkey poults.
- The present findings indicates that metabolism or excretion of artemisinin in birds may take place in the liver.

