



Quantitative assessment of bile ducts in turkeys treated with artemisinin: A model for liver toxicity?

Thøfner, Ida; Larsen, Jytte Overgaard; Nielsen, Ole Lerberg; Liebhart, Dieter ; Hess, Michael; Schou, Torben Wilde; Hess, Claudia; Ivarsen, Elise ; Fretté, Xavier C.; Christensen, Lars Porskjær; Grevsen, Kai; Engberg, Ricarda M.; Christensen, Jens Peter

Publication date:
2013

Document version
Publisher's PDF, also known as Version of record

Citation for published version (APA):
Thøfner, I., Larsen, J. O., Nielsen, O. L., Liebhart, D., Hess, M., Schou, T. W., ... Christensen, J. P. (2013). *Quantitative assessment of bile ducts in turkeys treated with artemisinin: A model for liver toxicity?*. Poster session presented at at annual Phd Day at Faculty of Health and Medical Sciences, Copenhagen, Denmark.

Quantitative assessment of bile ducts in turkeys treated with artemisinin

A model for liver toxicity?

Thøfner ICN¹, JO Larsen², OL Nielsen¹, D Liebhart³, M Hess³, TW Schou⁴, C Hess³, E Ivarsen⁵, XC Fretté⁵, LP Christensen⁵, K Grevsen⁶, RM Engberg⁷ and JP Christensen¹

¹ Department of Veterinary Disease Biology, Faculty of Health and Medical Science, University of Copenhagen, ² Department of Neuroscience and Pharmacology, Faculty of Health and Medical Science, University of Copenhagen ³ Clinic for Avian, Reptile and Fish Medicine, Department for Farm Animals and Veterinary Public Health, University of Veterinary Medicine Vienna, ⁴ DHI Environment and Toxicology, DHI Group, ⁵ Institute of Chemical Engineering, Biotechnology and Environmental Technology, Faculty of Engineering, University of Southern Denmark, ⁶ Department of Food Science, Aarhus University, and ⁷ Department of Animal Science, Aarhus University.

Conclusion

- The present findings suggest that artemisinin treatment changes the differentiation of the biliary duct system.
- The ratio of bile duct profiles with no lumen of the artemisinin treated birds is significantly higher than the same ratio in the control birds.
- No differences in the volume fraction of bile duct epithelium in relation to the volume of liver parenchyma between treatments.
- This is the first study that uses stereological microscopy for quantification of bile duct epithelium in turkey livers

Background

Development of resistance to anticoccidial drugs, removal of licensed antihistomonal formulations and a shift towards organic production has put the focus on natural occurring compounds for controlling protozoa infections in poultry.

Artemisinin originates from *Artemisia annua* and is widely used as an efficient antimalarial in humans. Inhibitory activity against coccidia of chickens was reported previously; however, toxic side effects, i.e. degeneration of the brain, liver and kidney, also were induced.

In a previous study investigating the effect of artemisinin against histomonosis in turkeys and chickens, artemisinin was administered in the feed to day-old turkeys (Thofner *et al.* 2012). As a result, sudden deaths occurred on day 5 and 6 in the group receiving 2600 mg artemisinin per kg feed, and the remaining birds in the group were then euthanized.

The histological examination of haematoxylin and eosin stained sections indicated bile duct proliferation of the treated turkeys.

In the present study we examined liver samples from the 15 dead/euthanized turkeys and 10 untreated and age-matched birds.

Aim

The aim was to quantify the volume fraction of bile duct epithelium and the number of bile duct profiles/area in turkeys suspected of artemisinin intoxication by unbiased stereology.

Methodology

Histological preparation

- Paraffin embedded formalin-fixed liver samples from Artemisinin treated turkey chickens (5-7 days old, n=15) and untreated and age-matched birds (n=10) were cut into 4 µm thick sections.
- Immunohistochemical detection of cytokeratin (Cytokeratin clone AE1/AE3, DAKO) was performed to distinguish the bile duct epithelium from liver parenchyma, connective tissue and blood vessels. Slides were counterstained with Mayers haematoxylin.

Stereology

- All fields of vision in all 25 sections were randomly selected within the delineated area of interest in steps of 400 µm (dx=dy).
- Determine the volume fraction of bile duct epithelium relative (Figure 1, red circles) to liver parenchyma using point grid counting (16 points per field of vision)
- Presence of lumen was noted for the transected bile duct profiles in each counting frame (7709,6 µm²). The relative number of lumen-less bile duct profiles per total number of bile duct transects were estimated as a function of the total observed area.

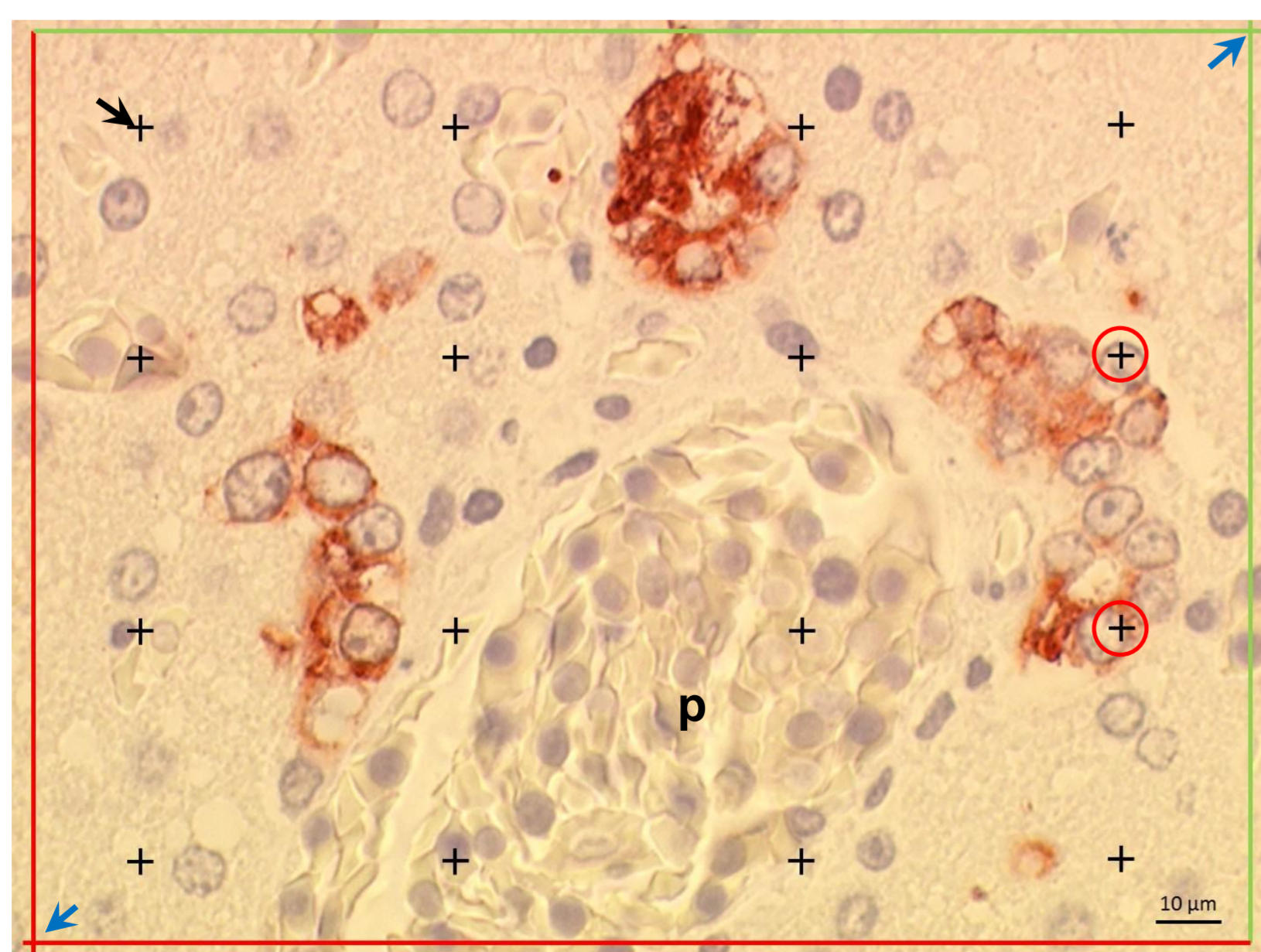


Figure 1: 16-point grid (black arrow) and counting frame (blue arrows) in a field of vision. p: portal vessel. Slide from Artemisinin treated bird (x60 objective, oil immersion. Total magnification: 3063x).

Table 1. Quantitation of bile duct proliferation in Artemisinin treated turkey chickens and untreated control birds. Mean ± SEM values and unpaired t-test, $p < 0,05$ (significance level).

	Control (n=10)	Artemisinin (n=15)	p-value
Volume fraction (bile epithelium/liver parenchyma)	0,01154 ± 0,0008389	0,01069 ± 0,0008334	0,4945
Examined area (mm ²)	2,655 ± 0,2039	2,201 ± 0,1146	0,0478
Ratio: bile duct profiles no lumen/total no. of bile duct profiles	0,7056 ± 0,02025	0,7899 ± 0,02071	0,0107
Total no bile duct profiles/mm ²	44,83 ± 3,114	39,59 ± 3,260	0,2808
No. of bile duct profiles no lumen/ mm ²	31,93 ± 2,744	31,79 ± 3,203	0,9768
No. of bile duct profiles with lumen/ mm ²	12,90 ± 0,9060	7,795 ± 0,6172	< 0,0001

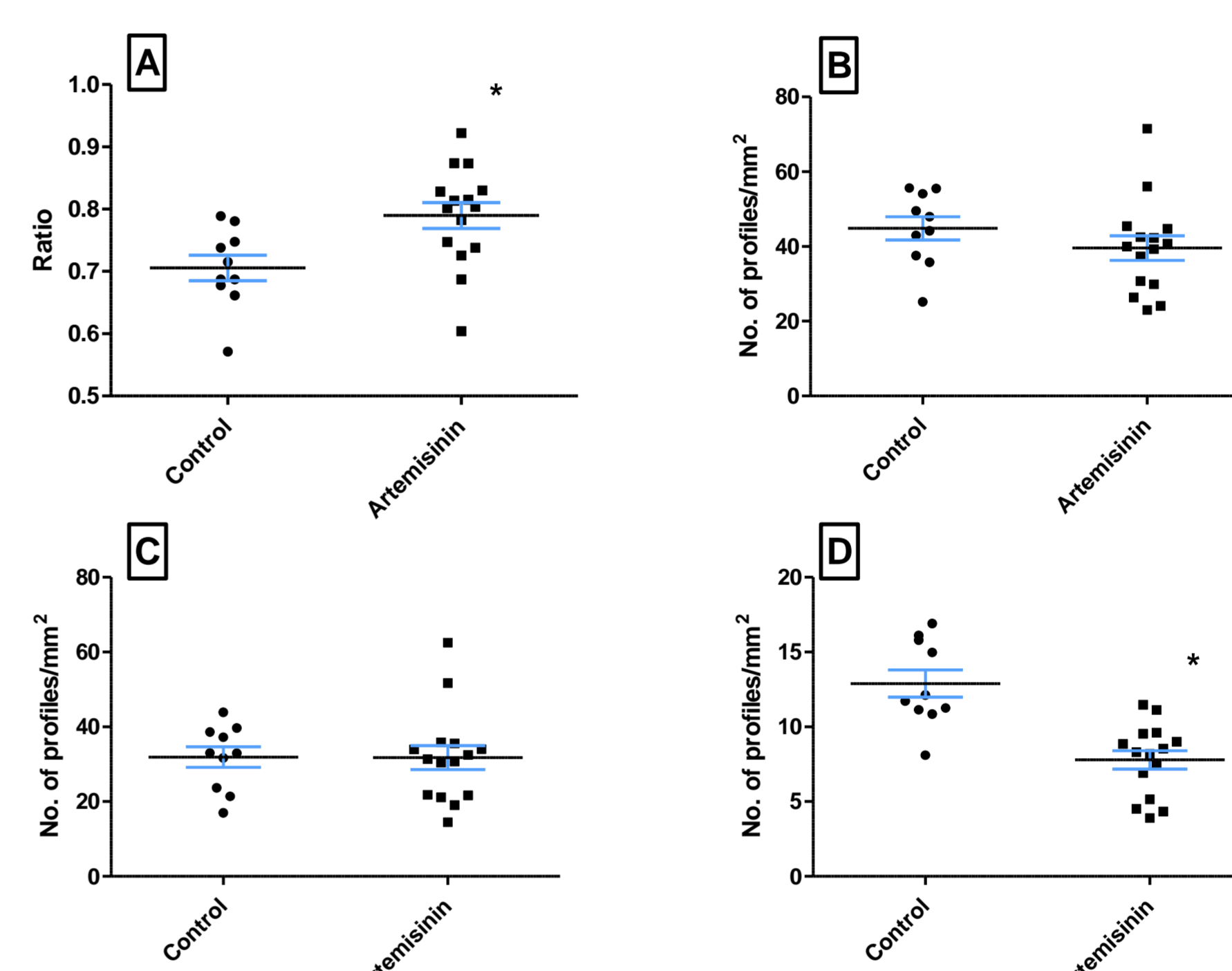


Figure 2 A) Ratio of bile duct profiles no lumen/total number of bile duct profiles. B) Total number of bile duct profiles. C) Number of bile duct profiles without lumen. D) Bile duct profiles with lumen. *: significant difference between control group and artemisinin treated group.

Discoveries

- No differences in the volume fraction of bile duct epithelium in relation to the volume of liver parenchyma between treatments (Table 1).
- The ratio of bile duct profiles with no lumen of the artemisinin treated birds is significantly higher than the same ratio in the control birds (Table 1 and Figure 2).
 - The total number of counted profiles with or without lumen did not differ significantly between the two groups. Neither did the absolute number of bile duct profiles without lumen.
 - In the control bird the absolute number of bile duct profiles with lumen is significantly higher than in the artemisinin treated birds ($P < 0,0001$).
- Epithelial anisocytosis and anisokaryosis of bile epithelium was observed in the artemisinin treated group (Figure 3).

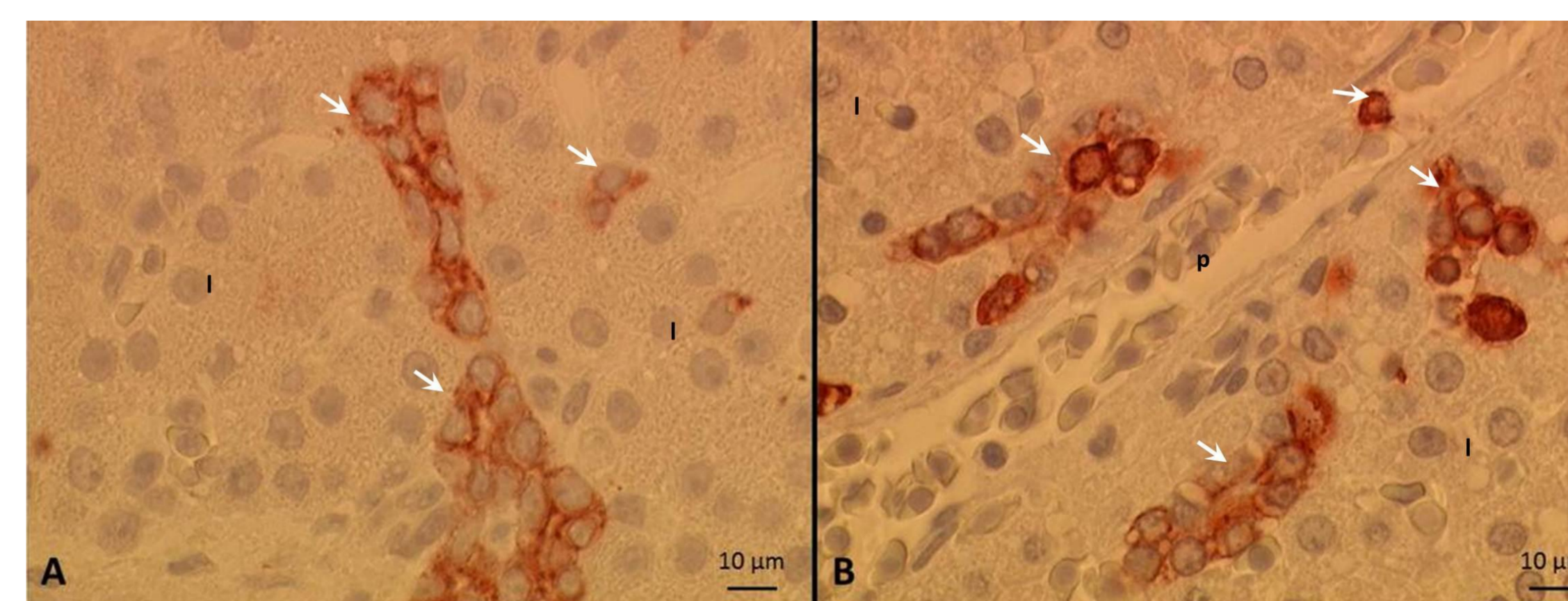


Figure 3 Bile duct profiles without lumen (white arrows). A) Control bird. B) Artemisinin treated bird. Note the pleomorphic appearance (anisocytosis and anisokaryosis; intracellular vacuoles) and irregular organisation of the bile epithelium in artemisinin treated birds (B) compared to untreated birds. (A) (l: liver parenchyma; p: portal vessel). (x60 objective, oil immersion. Total magnification: 3063x)

Discussion

The present findings suggest that metabolism or excretion of artemisinin in birds may take place in the liver. However, no analysis on bile or faecal matter was performed.

The difference in the relative ratio of bile duct profiles without lumen may be explained by a significant difference in the absolute number of bile duct profiles with lumen between treatments. Combined with the observed pleomorphic appearance of bile duct epithelium in artemisinin treated birds the present observation suggest that bile differentiation is abnormal as a response to toxic injury caused by artemisinin.

Turkey fetuses has been evaluated as suitable for assessing *in ovo* carcinogenicity showing hepatic changes similar to adult rodents (Williams, *et al.*, 2011), however the histological evaluation is purely descriptive. This is the first study that uses stereological microscopy for quantification of bile duct epithelium in turkey livers.

Key words

Toxicity, artemisinin, turkeys

References

Thofner *et al.* (2012). Anthistomonal effects of artemisinin and Artemisia annua extracts in vitro could not be confirmed by in vivo experiments in turkeys and chickens. *Avian Pathology* 41, 487-496. doi: 10.1080/03079457.2012.714459

Williams *et al.* (2011). Production of liver preneoplasia and gallbladder agenesis in turkey fetuses administered diethylnitrosamine. *Arch. Toxicol.* 85:681-687

Contact

Ida Thøfner
DVM, Ph.D. fellow
icnt@sund.ku.dk

