
CASE SERIES**SNODGRASS Procedure – A Versatile Technique for Various Types of Hypospadias Repair***Hombalkar N. N.¹, Gurav P. D.^{1*}, Dhandore P. D.¹, Parmar R. R.¹**¹Department of Surgery, Govt. Medical College, Miraj and Padmabhusan Vasantdada Patil Government Hospital, Sangli - 416416 (Maharashtra), India***Abstract:**

There are about 156 operations described for hypospadias. The sheer number of procedures indicates that no single procedure is standard for hypospadias. We report our series of 20 patients operated for hypospadias by Snodgrass procedure. The technical details of the procedure and post-operative management protocol is discussed.

Key words: Urethroplasty, Tubularised, Snodgrass.

Introduction:

The term Hypospadias is derived from Greek and refers to a Rent (Spadon) on the ventrum of the penis. It is defined as hypoplasia of tissues forming the ventral aspect (ventral radius) of the penis beyond the division of the corpus spongiosum. Hypospadias is characterized by a ventral triangular defect whose summit is formed by division of the corpus spongiosum, sides are formed by two pillars of atretic spongiosum and base is formed by the glans itself [1]. Snodgrass described the tubularised incised plate (TIP) for repair of hypospadias in 1994 as a mean to widen and improve mobilization of the urethral plate when performing a Thiersch-Duplay urethroplasty [2]. Since that time many reports have been published describing the success of this modified procedure to repair distal hypospadias lesions [3, 4]. As a

result of the popularity of this procedure, many other currently used techniques such as Mathieu or Transverse Island only, for distal hypospadias will probably be used less and less. Results are poorer and complications are greater in extensive procedures such as tube urethroplasty, compared to flaps and TIP [5].

Modern approach in hypospadias repair is to preserve the urethral plate if possible [6]. Given the relative simplicity of the operative concept, low complication rate and good cosmetic result in distal hypospadias, the tubularised incised plate procedure has been progressively applied to more proximal defects [7, 8].

Material and Methods:

We consecutively performed Snodgrass procedure on 19 boys for primary hypospadias and one boy with post operative urethocutaneous fistula at Government Medical College and Hospital, Miraj from July 2011 to June 2012. The boys' age at surgery ranged from 18 months to 14 years. The types of hypospadias were confirmed on table pre-operatively by doing artificial erection of penis. None of our patients had chordee even after artificial erection of penis. The position of the hypospadiac meatus in patients is shown in Table 1.

Surgical Procedure:

We performed the Snodgrass TIP Urethroplasty with mobilization of a dorsal dartos flap for

Table 1: Showing Types of Hypospadias

Type of Hypospadias	No. of Patients
Coronal	04
Distal	10
Mid penile	04
Penoscrotal without chordee and adequate urethral plate	01
Operated hypospadias with fistula	01
Total	20

neourethral covering (Fig. 1 to 5). Briefly, a stay suture was placed at the dorsal skin of the glans for easy handling and then the urethral plate was outlined. A U-shaped incision was made, extending along the edges of the urethral plate from the tips of the glans to 2–3 mm or healthy skin proximal to the hypospadiac meatus. A circumferential incision 5–7 mm proximal to the coronal margin was extended from each edge of the urethral plate and the penile shaft was degloved. Artificial erection was performed to rule out chordee. A longitudinal relaxing incision was made at the midline from the distal extent of the urethral plate to the hypospadiac meatus, which widened the plate to approximately 13–16 mm. The urethral plate was then tubularised over a 7-Fr infant feeding tube with a continuous 6–0 Dexon absorbable suture to create the neourethra that was extended upto around 5 mm proximal to the tip of the glans. Vascularised pedicled flap was elevated from inner surface of dorsal prepuce up to the base of penis and mobilised eventually over neourethra. It is an intermediate barrier layer between neourethra and surface skin layer. The redundant dorsal skin was transferred for

resurfacing closure. Infant feeding tube secured to the glans penis and kept in situ for approximately 10–12 days, which served for drainage of urethral discharge. Infant feeding tube was irrigated with 2 cc of distilled water every day. Flag dressing was used postoperatively for every patient. Dressing was changed under general anaesthesia on post-operative day 5.

Post-Operative Protocol

- Tab. Oxybutinin 2.5 mg twice a day
- Daily enemas
- Daily flushing of Infant Feeding Tube with 2 ml of Distilled Water
- Tab Bromelain
- IV Cefotaxime / amikacin for 1 week
- Infant Feeding Tube drainage of urine for 10-12 days
- Change of dressing under general anaesthesia on post-operative day 5

Results:

All patients obtained a functional neourethra with a vertically oriented, slit-like meatus, almost at the tip of the glans penis. A small urethocutaneous fistula occurred in two patients with distal penile hypospadias. The location of these fistula was subcoronal in one patient and distal penile in other patient. Both the patients were managed conservatively with regular urethral dilatation by infant feeding tubes of appropriate sizes and healed spontaneously. One patient with distal hypospadias developed complete skin dehiscence. One patient with midpenile hypospadias developed post operative penile torsion. At the follow up, the size of the neourethra was routinely calibrated with infant feeding tube on outpatient basis for all patients. Meatal stenosis or Urethral stricture

Table 2: Showing Complications in 20 Patients of Hyospadias Operated by Snodgrass Procedure

Type of hyospadias	Urethocutaneous Fistula	Penile Torsion	Skin Dehiscence
Coronal	-	-	-
Distal	2	-	1
Mid penile	-	1	-
Penoscrotal without chordee and adequate urethral plate	-	-	-
Hyospadias with fistula	-	-	-
Total	4		

was not encountered in any patient at the time of this report. Table 2 shows complications in 20 patients of hyospadias operated by snodgrass procedure

Discussion:

The surgical objectives of modern hyospadiology have been complete straightening of the penis, creating a hairless, smooth urethra of uniform calibre with the position of the meatus almost at the tip of the glans penis, normalization of voiding and erection, and normal appearance of the penis with a minimum of complications. Regardless of the severity of the malformation, urologists strive to meet such demands. As a result, over 200 described operative procedures or modifications have emerged to manage boys with hyospadias but no single procedure has been considered as panacea for all types of hyospadias and it has remained one of the most challenging problems in urological surgery. Nonetheless, significant progress has been made in the field as staged repairs have given way to single-stage operations such as those described by Asopa et al [9] and Duckett [10,11]. At the end of the 20th cen-

tury, Snodgrass advocated a versatile TIP procedure for most cases of hyospadias repair, which showed favourable cosmetic and functional results [7, 12, 13]. The most common complications were fistulae and meatal stenosis but these occurred at a relatively low incidence. Most encouragingly, few urethral strictures have, to our knowledge, been reported with the Snodgrass operation. The longitudinal incision on urethral groove described by Snodgrass is considered an innovation to urethral plate preservation surgery. It allows tension-free tubularization of the narrow urethral plate to form a neourethra of an adequate size. Recent histological studies have demonstrated that the urethral plate consists of epithelium overlying well-vascularised connective tissue with rich nerve supply [14, 15]. In an experimental study, Bluestein and co-authors confirmed that healing of the midline incision of the urethral plate during urethroplasty occurred by re-epithelialisation with normal tissue ingrowth and without scarring or contracture [15]. These features may explain why few urethral strictures are encountered using this technique. Histologically there has been no evidence of

fibrous or dysplastic cords in the urethral plate traditionally believed to be responsible for chordee, which supports dorsal plication to achieve penile straightening without transaction of the urethral plate [15, 16].

Another key step in Snodgrass repair is the interposition of a barrier layer of subcutaneous dartos tissue between the neourethra and the overlying skin closure. However, the wide dissection of a layer of dartos pedicle from the dorsal prepuce and shaft skin may, at least theoretically, jeopardize blood supply to the skin that is used for resurfacing closure, and predispose to skin loss and dehiscence. Mobilization and ventral transposition of the dartos flap around one side of the penile shaft may also predispose to penile torsion. We believe that urethral fistula is unlikely to occur in the scrotal area, and instead there may be two spots vulnerable to fistula formation which deserve special attention during hypospadias repair with the Snodgrass procedure: One, in the

subcoronal region and the other at the penoscrotal junction. Although routine urethral dilatation may not be necessary after Snodgrass repair, we carried out regular urethral calibration with infant feeding tube of appropriate size at outpatient clinics every 2–3 weeks for approximately 3 months after the operation, and then optionally at later follow ups. At the time of this report, no urethral stricture had been recognized clinically.

Conclusion:

In spite of our short case-series, we believe that the Snodgrass operation can be applied to a wide range of defects from distal to most severe perineal hypospadias. It creates a functional urethra of uniform calibre with a vertical slit-like meatus almost at the tip of the glans penis. The most common complication of urethral fistula occurs at an acceptably low rate and is much easier to handle than urethral stricture.

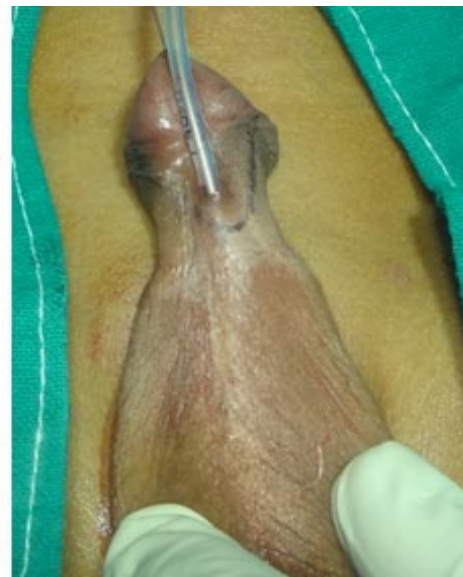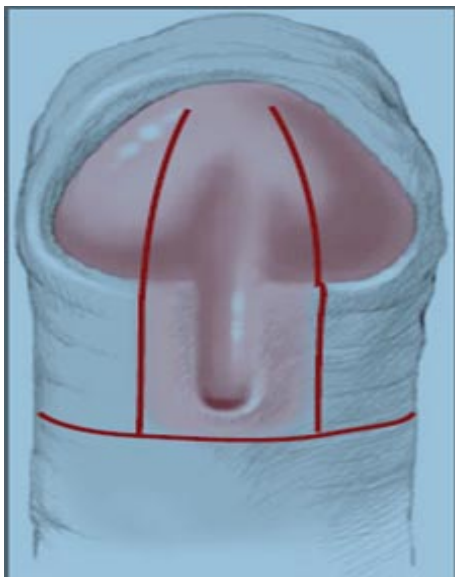


Fig. 1: U Shaped Incision along Urethral Plate with Circumcoronal Extension

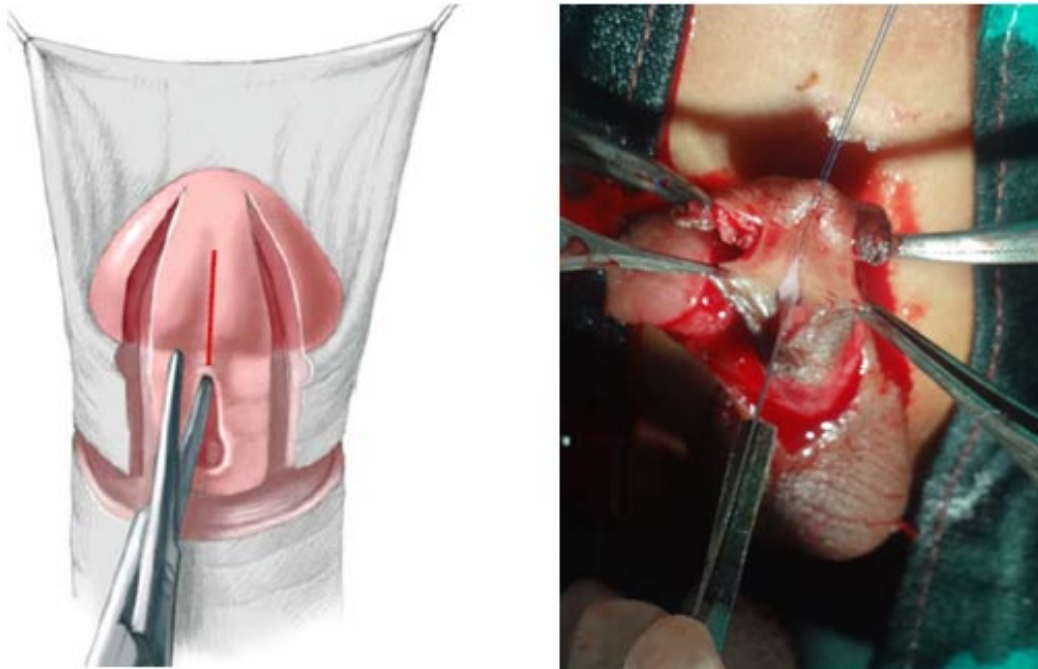


Fig. 2: Vertical Deep Midline Incision over Urethral Plate

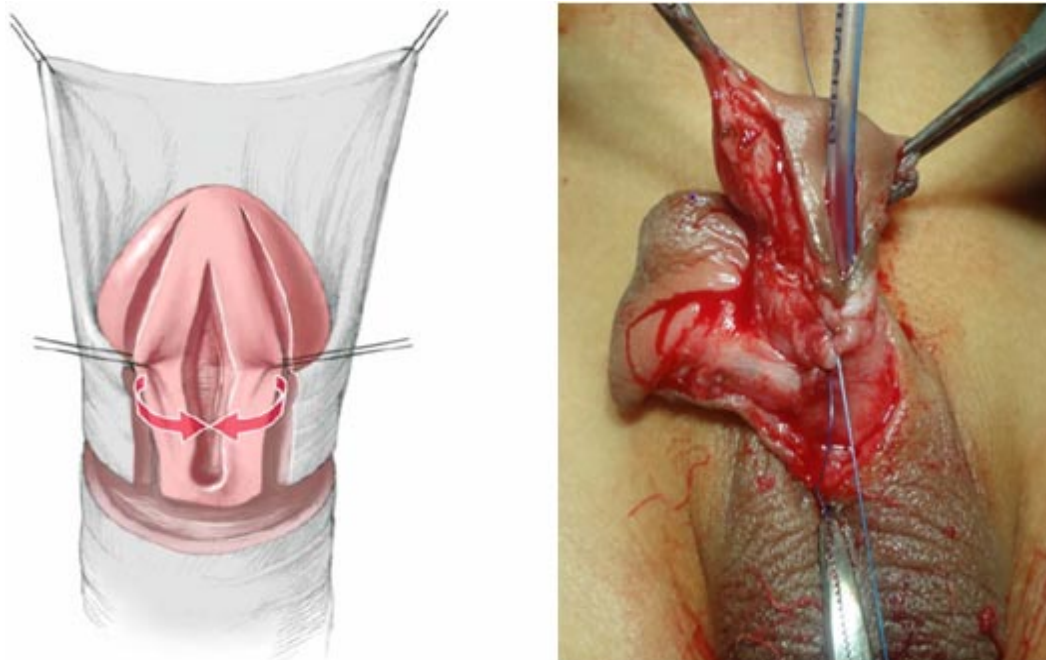


Fig. 3: Tubularization of Urethral Plate

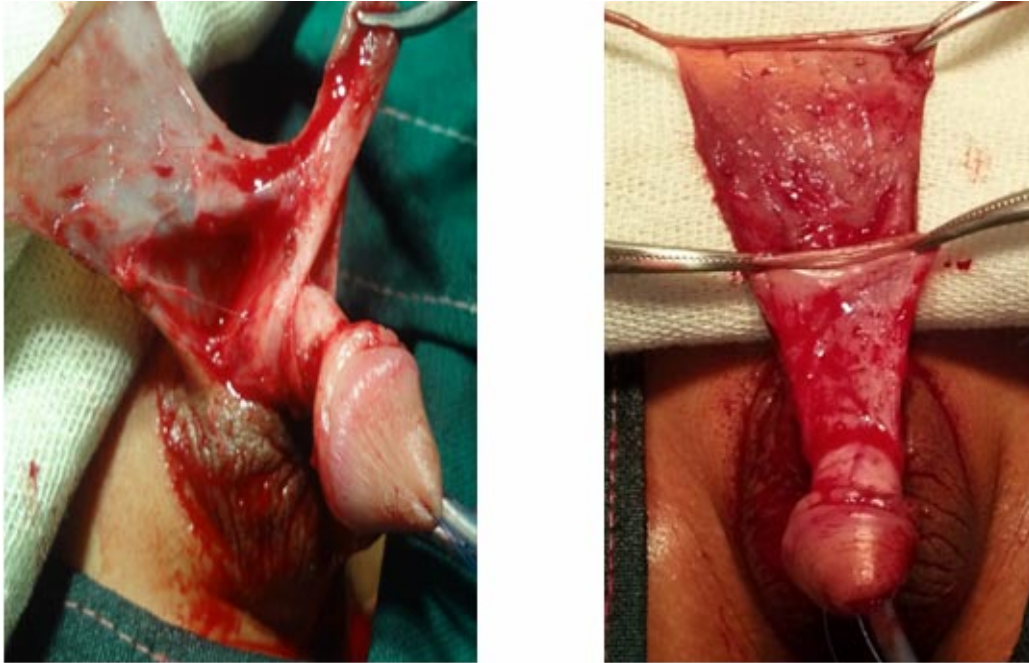


Fig. 4: Vascularised Pedicled Flap from Dorsal Inner Prepuce

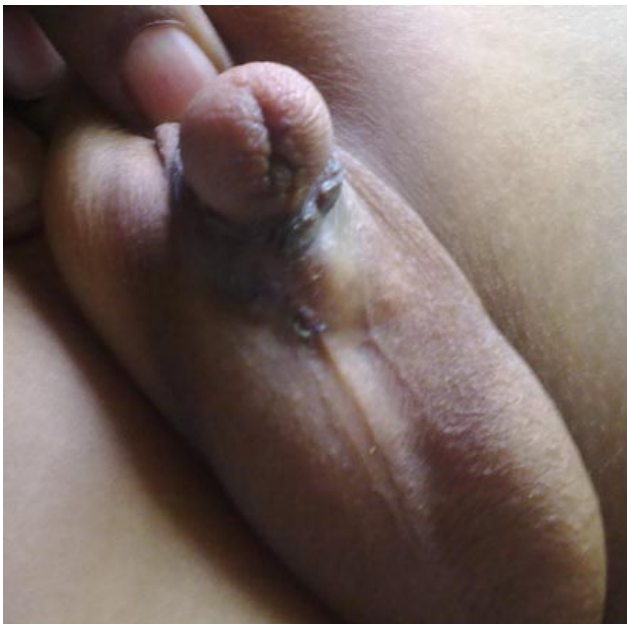

Fig. 5: S—, 4 years, Penoscrotal, 1 Month Post-Operatively



Fig. 6: Shan—, 10 years, Distal Penile, 6 Months Post-Operatively

References:

1. Prem Puri, Michael Hollwarth. In Paediatric surgery: Chapter 51; Hypospadias. Springer 2005: 529.
2. Snodgrass, W. Tubularized, incised plate urethroplasty for distal hypospadias repair. *J Urol* 1994; 151:464-465.
3. Snodgrass W, Koyle M, Manzoni G, Horowitz R, Caldamone A, Ehrlich R. Tubularized incised plate hypospadias repair: results of a multicenter experience. *J Urol* 1996; 156:839-841.
4. Steckler, R. E. Zaontz, M. R. Stent-free Thiersch-Duplay hypospadias repair with the Snodgrass modification. *J Urol* 1997; 158(3 Pt 2):1178-1180.
5. Retik AB, Atala A. Complications of hypospadias repair. *Urol Clin North Am* 2002; 29(2):329-339.
6. Upadhyay J, Shekarriz B, Khoury AE. Midshaft hypospadias. *Urol Clin North Am* 2002; 29(2):299-310.
7. Snodgrass W, Koyle M, Manzoni G, Hurwitz R, Caldamone A, Ehrlich R. Tubularized incised plate hypospadias repair for proximal hypospadias. *J Urol* 1998; 159(6): 2129-2131.
8. Braga LH, Pippi Salle JL, Lorenzo AJ, Skeldon S, Dave S, Farhat WA, Khoury AE, Bagli DJ. Comparative analysis of tubularized incised plate versus onlay island flap urethroplasty for penoscrotal hypospadias. *J Urol* 2007; 178(4 Pt 1):1451-1456; discussion 1456-1457.
9. Asopa HS, Elhence EP, Atri SP, Bansal NK. One-stage correction of penile hypospadias using a foreskin tube, a preliminary report. *Int Surg* 1971; 55(6): 435-440.
10. Duckett JW. The island flap technique for hypospadias repair. *Urol Clin North Am* 1981; 8(3): 503-511.
11. Duckett JW. MAGPI (meatoplasty and glanuloplasty): a procedure for subcoronal hypospadias. *Urol Clin North Am* 1981; 8(3):513-519.
12. Snodgrass WT. Tubularized incised plate hypospadias repair: indications, technique, and complications. *Urology* 1999; 54(1): 6-11.
13. Snodgrass W, Patterson K, Plaire JC, Grady R, Mitchell ME. Histology of the urethral plate: Implications for hypospadias repair. *J Urol* 2000; 164(3 Pt 2):988-9; discussion 989-990.
14. Erol A, Baskin LS, Li YW, Liu WH. Anatomical studies of the urethral plate: Why preservation of the urethral plate is important in hypospadias repair. *BJU Int* 2000; 85(6): 728-734.
15. Bleustein CB, Esposito MP, Soslow RA, Felsen D, Poppas DP. Mechanism of healing following the Snodgrass repair. *J Urol* 2001; 165(1): 277-279.
16. Snodgrass W. Changing concepts in hypospadias repair. *Curr Opin Urol* 1999; 9(6): 513-516.

***Author for Correspondence:** Dr. P. D. Gurav, Professor and Head, Department of Surgery, Govt. Medical College, Miraj and Padmabhusan Vasantdada Patil Government Hospital, Sangli - 416416 (Maharashtra), India Cell:9422040331 Email:prakashgurav37@yahoo.com