



Thomas Jefferson University  
Jefferson Digital Commons

Department of Orthopaedic Surgery Faculty  
Papers

Department of Orthopaedic Surgery

11-17-2019

## Volume Changes After Traumatic Spinal Cord Injury in Animal Studies - A Systematic Review

Mahdi Sharif-Alhoseini  
*Tehran University of Medical Sciences*

Fariba Vahedi  
*Tehran University of Medical Sciences*

Mahmoud Omidbeigi  
*Shahid Beheshti University of Medical Sciences*

Marzieh Sharifi  
*Tehran University of Medical Sciences*

Follow this and additional works at: <https://jdc.jefferson.edu/orthofp>

Zahra Hassannejad  
*Tehran University of Medical Sciences*

[Let us know how access to this document benefits you](https://jdc.jefferson.edu/orthofp)

See next page for additional authors

### Recommended Citation

Sharif-Alhoseini, Mahdi; Vahedi, Fariba; Omidbeigi, Mahmoud; Sharifi, Marzieh; Hassannejad, Zahra; Zadegan, Shayan Abdollah; Rezvan, Motahareh; Mokhatab, Mona; Sajadi, Kiavash; Shakouri-Motlagh, Aida; Shokraneh, Farhad; Vaccaro, Alexander R.; and Movaghar, Vafa Rahimi, "Volume Changes After Traumatic Spinal Cord Injury in Animal Studies - A Systematic Review" (2019). *Department of Orthopaedic Surgery Faculty Papers*. Paper 131.  
<https://jdc.jefferson.edu/orthofp/131>

This Article is brought to you for free and open access by the Jefferson Digital Commons. The Jefferson Digital Commons is a service of Thomas Jefferson University's [Center for Teaching and Learning \(CTL\)](#). The Commons is a showcase for Jefferson books and journals, peer-reviewed scholarly publications, unique historical collections from the University archives, and teaching tools. The Jefferson Digital Commons allows researchers and interested readers anywhere in the world to learn about and keep up to date with Jefferson scholarship. This article has been accepted for inclusion in Department of Orthopaedic Surgery Faculty Papers by an authorized administrator of the Jefferson Digital Commons. For more information, please contact: [JeffersonDigitalCommons@jefferson.edu](mailto:JeffersonDigitalCommons@jefferson.edu).

---

**Authors**

Mahdi Sharif-Alhoseini, Fariba Vahedi, Mahmoud Omidbeigi, Marzieh Sharifi, Zahra Hassannejad, Shayan Abdollah Zadegan, Motahareh Rezvan, Mona Mokhatab, Kiavash Sajadi, Aida Shakouri-Motlagh, Farhad Shokraneh, Alexander R. Vaccaro, and Vafa Rahimi Movaghar

# Volume Changes After Traumatic Spinal Cord Injury in Animal Studies-A Systematic Review

Mahdi Sharif-Alhoseini<sup>1</sup>, Fariba Vahedi<sup>1</sup>, Mahmoud Omidbeigi<sup>2</sup>, Marzieh Sharifi<sup>1</sup>, Zahra Hassannejad<sup>1</sup>, Shayan Abdollah Zadegan<sup>1</sup>, Motahareh Rezvan<sup>1</sup>, Mona Mokhatab<sup>1</sup>, Kiavash Sajadi<sup>1</sup>, Aida Shakouri-Motlagh<sup>3</sup>, Farhad Shokraneh<sup>4</sup>, Alexander R. Vaccaro<sup>5</sup>, Vafa Rahimi-Movaghar<sup>1,6,7</sup>

<sup>1</sup> Sina Trauma and Surgery Research Center, Tehran University of Medical Sciences, Tehran, Iran

<sup>2</sup> Skull Base Research Center, Loghman Hakim Hospital, Shahid Beheshti University of Medical Sciences, Tehran, Iran

<sup>3</sup> Department of Chemical and Biomolecular Engineering, University of Melbourne, Melbourne, Australia

<sup>4</sup> Cochrane Schizophrenia Group, Institute of Mental Health, University of Nottingham, Nottingham, UK

<sup>5</sup> Department of Orthopaedic Surgery, The Rothman Institute, Thomas Jefferson University, Philadelphia, USA

<sup>6</sup> Brain and Spinal Cord Injury Research Center, Tehran University of Medical Sciences, Tehran, Iran

<sup>7</sup> Neuroscience Institute, Tehran University of Medical Sciences, Tehran, Iran

Received: 13 Jan. 2019; Accepted: 19 May 2019

**Abstract-** There are limited data on the lesion volume changes following spinal cord injury (SCI). In this study, a meta-analysis was performed to evaluate the volume size changes of the injured spinal cord over time among animal studies in traumatic SCI. Following the Preferred Reporting Items for Systematic Reviews and Meta-Analyses (PRISMA) guidelines, we conducted a comprehensive electronic search of English literature of PubMed and EMBASE databases from 1946 to 2015 concerning the time-dependent changes in the volume of the spinal cord following mechanical traumatic SCI. A hand-search was also performed for non-interventional, non-molecular, and non-review studies. Quality appraisal, data extraction, qualitative and quantitative analyses were performed afterward. Of 11,561 articles yielded from electronic search, 49 articles were assessed for eligibility after reviewing of titles, abstracts, and references. Ultimately, 11 articles were eligible for quantitative synthesis. The ratio of lesion volume to spinal cord total volume increased over time. Avascularity appeared in spinal cord 4 hours after injury. During the first week, the spinal subarachnoid space decreased. The hemorrhagic lesion size peaked in 1 week and decreased thereafter. Significant loss of gray and white matter occurred from day 3 with a slower progression of white matter damage. Changes of lesion extent over time is critical in pathophysiologic processes after SCI. Early avascularity, rapid loss of gray matter, slow progression of white matter damage, and late cavitation are the pathophysiologic key points of SCI, which could be helpful in choosing the proper intervention on a timely basis.

© 2019 Tehran University of Medical Sciences. All rights reserved.

*Acta Med Iran* 2019;57(6):385-394.

**Keywords:** Spinal cord injuries; Animal models; Pathophysiology

## Introduction

Understanding the pathophysiology of spinal cord injury (SCI) is the key element for developing interventions to eliminate, or even reverse the pathological processes after SCI that lead to permanent damage of the spinal cord. The pathophysiology of SCI is biphasic, including a primary injury followed by a second wave of damage that can be the target for the interventions to prevent further spinal cord destruction. The initial pathogenic factor is a mechanical injury due to

the disruption of spinal cord structures. The secondary injury consists of a cascade of biochemical and molecular events that lasts several days to weeks and leads to the progression of the primary injury (1). These events lead to intramedullary hemorrhage, cellular inflammation, necrosis, apoptosis, gliosis, demyelination, and cyst and microcyst formation around the lesion (2). Enlargement of lesion size due to secondary damage could cause massive additional cell death (3). The changes in spinal cord lesion volume over time following SCI remains poorly understood. It is important to understand the

**Corresponding Author:** V. Rahimi-Movaghar

Sina Trauma and Surgery Research Center, Tehran University of Medical Sciences, Tehran, Iran

Tel: +98 915 342 2682, Fax: +98 21 66757009, E-mail addresses: v\_rahimi@sina.tums.ac.ir, v\_rahimi@yahoo.com

changes related to the extent of tissue damage as an inevitable pathophysiologic process following SCI. Therefore, through a systematic review of time-dependent pathophysiology of traumatic SCI in experimental animal studies, we aimed to focus on the injury volume changes after SCI and provide best evidence of the timing and factors contributing to this change.

## Materials and Methods

### Search and selection of studies

This systematic review was conducted following PRISMA (Preferred Reporting Items for Systematic Review and Meta-analyses) guidelines (4) (see the Appendix). An electronic database searches on MEDLINE via PubMed and EMBASE via Ovid SP were performed on 24 October 2015 to retrieve the relevant English literature published using the following keywords: SCI, pathophysiology, time, and animal. We also reviewed the references of relevant studies.

### Study eligibility

We included all animal studies on SCI published in English, regardless of study design, sample size, date of publication, or follow-up time. Following the removal of duplicates, the abstracts of the remaining articles were independently screened by 2 of the authors. An article was eligible if it was an experimental study on time-dependent pathophysiology of traumatic SCI. We also selected eligible studies considering the extent of tissue damage and changes in injury volume. Injury volume was defined as regions containing intramedullary hemorrhage, edema, cellular inflammation, gliosis, necrotic tissue, apoptosis, cyst, cavitation, or demyelination, which were compared to the surrounding normal spinal cord tissue (5-7). Exclusion criteria were non-English studies, reviews, molecular studies, and interventional studies. No studies were excluded based on

the quality of methods. Inter-observer agreement for study eligibility after abstract screening was tested using the kappa statistic. When studies had insufficient data on the volume change of the injured spinal cord, the authors were contacted via e-mail, up to 3 times when necessary, and the studies were excluded if data were still not supplied.

### Data extraction and quality assessment

To survey the level of evidence, we used a checklist of potential variables affecting the quality of animal studies regarding the pathophysiology of traumatic SCIs (8). Two independent reviewers (FV and MS) extracted data focusing on the extent of tissue damage and injury volume. In case of disagreement or uncertainty, the consensus was achieved through focused discussion meetings.

### Data analysis

Descriptive analyses were conducted using PASW (SPSS Inc., Illinois, USA). The injury volume changes were investigated, given the homogeneous animal and injury models. Because of the heterogeneity of studies for animal models we considered 11 studies with maximum similarity in animal and injury models to perform a quantitative synthesis.

To specifically compare the results of homogeneous studies with different scorings, the coefficient of variation (standard deviation divided by the mean) was used.

## Results

Of 11,557 papers identified through Medline and EMBASE searching, 49 were eligible. The study selection procedure is summarized in figure 1.

Characteristics of the included studies are presented in table 1. The last column of Table 1 depicts quality scores of studies achieved by using the checklist of Hassannejad *et al.*, (8) and were expanded in table 2.

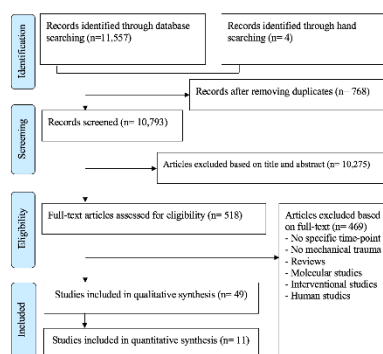


Figure 1. Flow diagram of the summarized search procedure

**Table 1. 49 studies related to injury volume after traumatic spinal cord injury based on publication date, animals, injury model, number of animals, grouping, and quality scores**

Author; Date	Animals	Injury Model: Method (feature); Level	Number of animals	Grouping (Number per group)	Number of controls	Quality scores <sup>*</sup> (from 15)
Andrade; 2008 (9)	Rat	NYU impactor (10 g from 25 or 50 mm)); T9-10	28	Injury severity: 25 mm (11), 50 mm (10)	8	10
Anthes; 1995 (42)	Rat	Clip (53 g for 1 min); C8-T1	24	Post-SCI time: 15 min, 2 h, 24 h (each group: 6)	6	11
Blight; 1985 (43)	Cat	Weight drop (13 g from 20 cm); T9	30	Post-SCI time: 2 d (5), 7 d (4), 3 m (5), 8 m (5)	11	8
Blight; 1991 (36)	Guinea pig	Forceps (for 15 sec); T13	16	Post-SCI time: 57-94 d (12)	4	10
Blomster; 2013 (34)	Mouse	IH impactor (0.5 N); T9	16	Post-SCI time: 7 d (4), 28-35 d (7)	5	12
Bose; 2005 (10)	Rat	NYU impactor (10 g from 2.5 cm); T7&9	10	Post-SCI time: 4 m (10)	6	10
Brennan; 2013 (33)	Mouse	IH impactor (71 kilodynes); T9	4	Post-SCI time: Live imaging in 2 h, 1, 3, 7 & 30 d (4)	0	11
Bresnahan; 1978 (40)	Monkey	Weight drop (20 g from 25 cm); Thoracic	13	Post-SCI time: 4 h, 6 h, 12 h, 18 h, 48 h, 1 w, 3 w, 9.5 w, 10 w (each group: 1)	4	8
Byrnes; 2010 (11)	Rat Mouse	Weight drop (Rat: 10 g from 25 mm; Mouse: 1.9 g from 20 mm); T9	Rat: 9 Mouse: 9	Post-SCI time: Live imaging in 1, 7, 14, 21 & 28d	N/A	12
Camand; 2004 (44)	Mouse	Transection; T7-9	82	Post-SCI time: 8 d (19), 1 m (14), 3 m (10), 6 m (11), 12 m (8)	10	10
Carlson; 2003 (41)	Dog	Dynamic compression (for 30 or 180 min); T13	16	Compression time: 30 min (8), 180 min (8)	0	10
Ditor; 2008 (45)	Rat	Clip (50 g for 60 sec); T4	9	Post-SCI time: 6 w (9)	0	9
Dusart; 1994 (3)	Rat	Transection; Middle to lower thoracic	47	Post-SCI time: 1 h, 3 h, 6 h, 12 h, 1 d, 2 d, 4, 8 d, 15 d, 21 d, 1 m, 2 m, 3 m (each group: 2-7)	2	9
Ek; 2012 (24)	Rat	Impactor (28.5 N); T10	N/A	Post-SCI time: 1 d, 1w, 4 w, 10 w (each group: 3-4)	N/A	9
Ellingson; 2010 (12)	Rat	NYU impactor (10 g from 25 mm), T8	66	Post-SCI time: 2 w (10), 5 w (8), 10 w (7), 15 w (7), 20 w (11), 25 w (7)	16	10
Fairholm; 1971 (32)	Rabbit Dog	Weight drop (Rabbit:50 gcf; Dog: 300 gcf); L3-4	Rabbit:34 Dog: 5	Post-SCI time: Rabbits: 10 min, 30 min, 1 h, 2 h, 4 h, 6 h, 12 h, 1 d, 2 d, 7 d, 14 d (29) Dogs: 2 d (5)	Rabbit: 5 Dog: 0	7
Finkelstein; 1990 (13)	Rat	Weight drop (10 g from 2.5, 5, or 17.5 cm); T8	24	Injury severity: 2.5 cm (9), 5 cm (7), 17.5 cm (8)	0	11
Gledhill; 1973 (39)	Cat	Brass screw compression (N/A); L1	13	Unique Severity: (8)	5	7
Griffiths; 1975 (46)	Dog	Fogarty catheter (0.35 cc for 30 sec to 5.5 h); T13	20	Compression time: Acute maintained (4), Acute maintained (4), Chronic maintained (3), Chronic released (5)	4	5
Grossman; 2001 (14)	Rat	Weight drop (10 g from 205 cm); T7	56	Post-SCI time: 15 min (10), 4 h (15), 8 h (10), 24 h (15)	6	9
Guizar-Sahagun; 1994 (31)	Rat	Weight drop (15 g from 8 cm); T9	54	Post-SCI time: 1 d, 3 d, 5d, 8d, 11 d, 2 w, 3w, 4w, 5w, 6w, 7w, 8w, 15w, 20 w, 30 w, 52 w (each group: 3)	0	10

Volume changes after spinal cord injury

Continuance of Table 1

<b>Hill; 2001(15)</b>	Rat	Weight drop (10 g from 6.25, 12.5, or 25 mm); T9-10	33	Injury severity: 6.25-mm (4), 12.5-mm (26), 25-mm (3)	N/A	9
<b>Hu; 2010 (16)</b>	Rat Dog	Weight drop (Rat: 10 g from 25 mm; Dog: 30 g from 50mm); T9	Rat: 58 Dog: 16	Rat: 1 d, 1 w, 2 w, 4 w, 8 w, 16 w (each group: 9) Dog: 1 d, 1 w, 2 w, 4 w, 8 w, 16 w (each group: 2)	Rat: 4 Dog: 4	11
<b>Kostyk; 2008 (47)</b>	Mouse	Contusion by an electromagnetic device (1.35 mm tip diameter over 23 msec); T9	64	Genetic Background: C57BL/6J (35), MRL/MpJ (39)	N/A	13
<b>Kouyoumdjian; 2009 (48)</b>	Mouse	Compression by an ogival-shaped device (for 1, 5, or 10 min); T9-10	106	Injury severity: 1-mm, 0.9 mm, 0.8 mm (each group: 10)	18	15
<b>Koyanagi; 1993 (22)</b>	Rat	Clip (51 g for 1 min); C8-T1	19	Post-SCI time: 15 min (9), 4 h (5), 24 h (5)	0	7
<b>Kuhn; 1998 (35)</b>	Mouse	Weight drop (1 or 2 or 3 g for 2.5 or 5 cm); T8	57	Injury severity: 1 g (4), 2 g (21), 3 g (17)	15	13
<b>Lane; 2007 (37)</b>	Opossum	Transection; T4-6	57	Post-SCI time: 0 h, 3 h, 24 h (each group: 15-20)	6	12
<b>Leskovar; 2000 (49)</b>	Rat	Watchmaker's forceps (for 3 sec); T9-12	44	Post-SCI time: 3 d, 5 d, 10 d, 21d (each group: 11)	N/A	8
<b>Li; 2004 (50)</b>	Rat Mouse	Weight drop; T8-9 Rat: 35 or 50 g Mouse: 5 or 10 g/mm <sup>2</sup>	Rat: 40 Mouse: 16	Injury severity: Rat: 35 g (16), 50 g (16) Mouse: 5 g /mm <sup>2</sup> (4), 10 g/mm <sup>2</sup> (4)	Rat: 8 Mouse: 8	10
<b>Liu; 1997 (20)</b>	Rat	Weight drop (10 g from 6.25 or 12.5 mm); T8-9	100	Injury severity: 6.25 mm (64), 12.5 mm (24)	12	11
<b>Lonjon; 2010 (28)</b>	Rat	Fogarty catheter (10 or 15 µl for 10 min); T8-9	46	Injury severity: 10 µl of water (10), 15 µl of water (26)	10	11
<b>Moriarty; 1998 (30)</b>	Rat	Watchmaker's forceps (N/A); T11	22	Unique Severity: (20)	2	9
<b>Namiki; 1999 (51)</b>	Rat	Clip (20 or 112 g for 1 min); T1	53	Injury severity: 20 g (38), 112 g (15)	N/A	10
<b>Narayana; 2004 (26)</b>	Rat	Impactor (speed of bit 1.5 m/sec, compression 1.7 mm), T7	25	Unique Severity: speed of the bit 1.5 m/sec, cord compression 1.7 mm, duration of compression: 80 msec (19)	6	9
<b>Noble; 1985 (7)</b>	Rat	Weight drop (10 g from 2.5, 5, 7.5, 10, or 17.5 cm); T8	51	Injury severity: 2.5 cm (11), 5 cm (9), 7.5 cm (8), 10 cm (11), 17.5 cm (9)	3	9
<b>Nout; 2009 (52)</b>	Rat	NYU impactor (10 g from 12.5 mm); C5	12	Unique Severity: (6)	6	12
<b>Pearse; 2005 (25)</b>	Rat	OSU impactor (3 Kilodynes); C5	70	Injury severity: 0.8 mm, 0.95mm, 1.1 mm (each group: 20)	10	11
<b>Poon; 2007 (53)</b>	Rat	Clip (20, 26, or 35 g for 1 min); T2	24	Injury severity: 20 g, 26 g, 35 g (each group: 8)	N/A	10
<b>Reyes-Alva; 2013 (27)</b>	Rat	NYU impactor (10 g from 12.5mm); T9	20	Post-SCI time: 1 h, 1 d, 3 d 7 d, 30 d, 90 d (each group: 2)	8	12
<b>Shibuya; 2003 (23)</b>	Rat	Metal rod impactor (30 g for 10 min); T11-12	25	Post-SCI time: 24 h, 1 w, 4 w, 12 w (each group: 5)	5	11
<b>Steencken; 2010 (17)</b>	Rat	NYU impactor (10 g from 25 mm); T9	32	Post-SCI time: 2 w (7), 6 w (17), 16 w (4)	4	11
<b>Swartz; 2009 (54)</b>	Rat	IH impactor (100 kilodynes); T10	35	Compression time: 10 sec (9), 30 sec (8), 5 min (10)	8	11
<b>Vaughn; 2013 (29)</b>	Rat	Forceps (for 15 sec); T8	40	Post-SCI time: 1 d, 3 d, 1w, 2w, 4w, 6w (each group: 6)	4	11
<b>Vessal; 2007 (55)</b>	Rat Monkey	Rhizotomy; C8-T1 Rhizotomy; C5-T1	Rat: 18 Monkey: 7	Injury location: Rat: Dorsal column (6), Dorsal root (6)	Rat: 6 Monkey: 2	10

Continuance of Table 1

Vink; 1989 (38)	Rabbit	Weight drop (20 g from 7.5 cm); L3	22	Unique Severity: (14)	8	9
Whetstone; 2003 (56)	Mouse	Weight drop (3 g from 5 cm); T8	72	Post-SCI time: 25 min (4), 35 min (5), 1.5 h (5), 4.5 h (5), 1 d (12), 3 d (9), 1 w (10), 2 w (12), 3 w (9)	13	12
Zai; 2005 (18)	Rat	Weight drop (10 g from 2.5 cm); T8	40	Post-SCI time: 1 d (10), 2 d (8), 3 d (12), 4 d (2), 7 d (4)	6	9
Zhang; 1997 (21)	Rat	Forceps (for 2 sec); T8	54	Post-SCI time: 2 min (2), 3 h (2), 6 h (4), 12 h (4), 2 d (4), 3 d (6), 1 w (7), 2 w (6), 3 w(9), 6 w (5), 8 w (5)	0	11

Table 2. Quality assessment of the included studies (8)\*

Author; Date (Ref. No)	Species	Appropriate tests	Severity of injury	Level of injury	Age/weight	Number of animals per group	Designation of strain	Definition of control	Statistical analysis	Regulation and ethics	Bladder expression	Blindness of assessor	Genetic background	Allocation concealment	Reasons for excluding animals
Andrade; 2008 (9)	+	+	+	+	+	+	+	+	+	?	+	?	?	?	?
Anthes; 1995 (42)	+	+	+	+	+	+	+	+	+	+	+	?	?	?	?
Blight; 1985 (43)	+	+	+	+	+	+	+	+	?	?	?	?	?	?	?
Blight; 1991 (36)	+	+	+	+	+	+	+	+	+	?	+	?	?	?	?
Blomster; 2013 (34)	+	+	+	+	+	+	+	+	+	+	+	+	+	?	?
Bose; 2005 (10)	+	+	+	+	+	+	+	+	+	+	?	?	?	?	?
Brennan; 2013 (33)	+	+	+	+	+	+	+	?	+	+	+	?	?	?	?
Bresnahan; 1978 (40)	+	+	+	+	+	+	+	?	?	?	?	?	?	?	?
Byrnes; 2010 (11)	+	+	+	+	+	+	+	+	+	?	+	+	?	?	?
Camand; 2004 (44)	+	+	+	+	+	+	+	+	+	?	?	?	?	?	?
Carlson; 2003 (41)	+	+	+	+	+	+	+	?	+	+	+	?	?	?	?
Ditor; 2008 (45)	+	+	+	+	+	+	+	?	+	?	?	?	?	?	?
Dusart; 1994 (3)	+	+	+	+	+	+	+	+	+	?	?	?	?	?	?
Ek; 2012 (24)	+	+	+	+	+	+	?	+	+	?	?	?	?	?	?
Ellingson; 2010 (12)	+	+	+	+	+	+	+	+	+	?	?	?	?	?	?
Fairholm; 1971 (32)	+	+	+	+	+	+	?	+	?	?	?	?	?	?	?
Finkelstein; 1990 (13)	+	+	+	+	+	+	+	+	?	?	+	?	?	?	?
Gledhill; 1973 (39)	+	+	+	+	+	+	?	+	?	?	?	?	?	?	?
Griffiths; 1975 (46)	+	+	+	+	?	+	?	?	?	?	?	?	?	?	?
Grossman; 2001 (14)	+	+	+	+	+	+	+	+	?	?	?	?	?	?	?
Guizar-Sahagun; 1994 (31)	+	+	+	+	+	+	?	?	+	+	?	?	+	?	?
Hill; 2001(15)	+	+	+	+	+	+	?	?	+	+	?	?	?	?	?
Hu; 2010 (16)	+	+	+	+	+	+	+	+	+	+	?	?	?	?	?
Kostyk; 2008 (47)	+	+	+	+	+	+	+	+	+	+	+	+	?	?	?
Kouyoumdjian; 2009 (48)	+	+	+	+	+	+	+	+	+	+	+	+	+	+	+
Koyanagi; 1993 (22)	+	+	+	+	+	+	?	?	?	?	?	?	?	?	?
Kuhn; 1998 (35)	+	+	+	+	+	+	+	+	+	+	?	+	+	?	?
Lane; 2007 (37)	+	+	+	+	+	+	+	+	+	?	+	?	+	?	?
Leskovar; 2000 (49)	+	+	+	+	+	+	?	+	?	?	?	?	?	?	?
Li; 2004 (50)	+	+	+	+	+	+	+	?	?	?	?	?	+	?	?
Liu; 1997 (20)	+	+	+	+	+	+	?	+	+	+	?	?	?	?	?
Lonjon; 2010 (28)	+	+	+	+	+	+	+	+	+	+	?	?	?	?	?
Moriarty; 1998 (30)	+	+	+	+	+	+	+	+	?	?	?	?	?	?	?
Namiki; 1999 (51)	+	+	+	+	+	+	+	+	+	?	?	?	?	?	?
Narayana; 2004 (26)	+	+	+	+	+	+	+	+	?	?	?	?	?	?	?
Noble; 1985 (7)	+	+	+	+	+	+	+	+	?	?	?	?	?	?	?
Nout; 2009 (52)	+	+	+	+	+	+	+	+	+	?	+	?	+	?	?
Pearse; 2005 (25)	+	+	+	+	+	+	+	+	+	+	?	?	?	?	?

Continuance of Table 2															
Poon; 2007 (53)	+	+	+	+	+	+	+	?	+	+	+	?	?	?	?
Reyes-Alva; 2013 (27)	+	+	+	+	+	+	+	+	+	+	+	+	?	?	?
Shibuya; 2003 (23)	+	+	+	+	+	+	+	+	+	+	+	+	?	?	?
Steencken; 2010 (17)	+	+	+	+	+	+	+	+	+	+	+	+	?	?	?
Swartz; 2009 (54)	+	+	+	+	+	+	+	+	+	+	+	?	?	?	?
Vaughn; 2013 (29)	+	+	+	+	+	+	+	+	+	+	+	+	?	?	?
Vessal; 2007 (55)	+	+	+	+	+	+	+	+	+	+	+	+	?	?	?
Vink; 1989 (38)	+	+	+	+	+	+	+	+	+	?	?	?	?	?	?
Whetstone; 2003 (56)	+	+	+	+	+	+	+	+	+	+	+	+	?	?	?
Zai; 2005 (18)	+	+	+	+	+	+	+	+	+	?	?	?	?	?	?
Zhang; 1997 (21)	+	+	+	+	+	+	+	?	+	?	+	+	?	+	?

\* + : Low risk; ? : Unclear; - : High risk

Contusion was the most common pattern of injury (44, 90%) followed by transection (5, 10%). The most common level of injury in the included studies was thoracic (43, 88%) followed by cervical (5, 10%), lumbar (2, 4%), and unknown (3, 6%). The rat was the most common animal in the experimental models of SCI. More than one animal was used in 5 studies (10%). All animals are shown in figure 2.

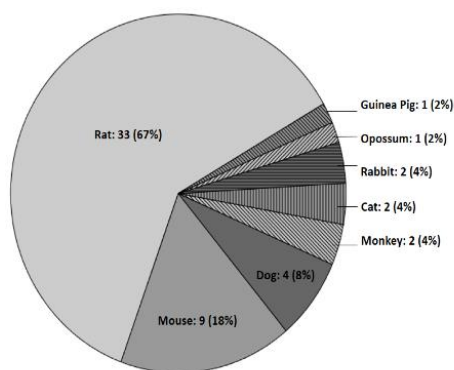


Figure 2. Animals used in 49 included studies

Due to the heterogeneity of studies in view of a variation of animal models, a meta-analysis was impossible. We considered studies with maximum similarity in animal and injury models to undertake a quantitative synthesis. We selected 11 homogeneous studies (7,9-18) which all used the rat model of SCI in the lower thoracic level induced by a 10 grams weight dropped from a height of 25 mm, (Figure 3) and showed functional, electrophysiological, and morphological outcomes similar to humans following SCI (19).

Using the coefficient of variation, the results of homogeneous studies with different scorings were compared. The ratio of injury volume to the total volume of spinal cord over the time period after traumatic SCI was shown in Figure 3.

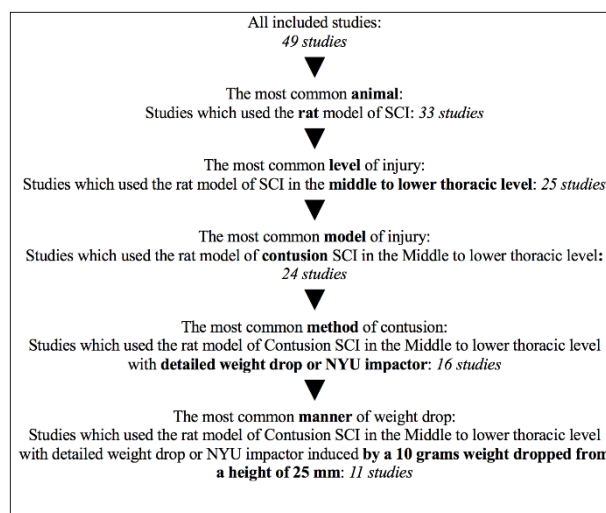


Figure 3. The process of selecting homogeneous studies

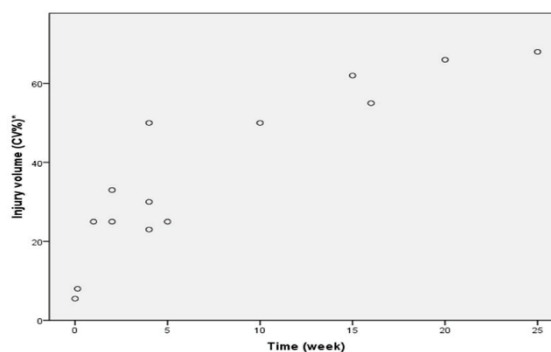


Figure 4. The percentage of injury volume compared to the total volume of the spinal cord through time after traumatic injury

\* Coefficient of variation: the ratio of the standard deviation to the mean, displayed in percentage.

## Discussion

The rat was the most common animal used in the included studies. In rat SCI models, immediately after contusive SCI, the lesion of the spinal cord was narrow



and elliptical in shape. The progressive expansion of the lesion was initially identified at 5 minutes post-injury through the disappearance of Nissl substance in neurons (20). The continuity of the cord was disrupted, and the gap appeared approximately 0.3 mm long (equivalent to the width of the forceps) in the white matter and slightly longer in the central gray matter (21). After 15 minutes, tissue damage and hemorrhages were largely confined to the central gray matter with little visible damage in the surrounding white matter. However, the rapid loss of gray matter neurons occurred at the same time (1). One hour later, the injury volume was still small, corresponding to the initial mechanical trauma. Adhesion of inflammatory cells onto the endothelium within the vascular wall was seen at 3 hours (3). After 4 hours, avascularity could be seen inside the injured spinal cord, and displacement of the sulcal arteries occurred at the injury level, extending rostrally and caudally (22). Constriction of the sulcal arteries at the injury site was more likely to be detected after 24 hours (22). The microscopic examination at 24 hours after injury showed a marked hemorrhagic and necrotic lesion at the epicenter, extending to both sides approximately equivalent to the spinal cord diameter (23). At this time point, the boundary between white and gray matter was difficult to distinguish (24).

Three days post-injury, a significant loss of gray matter volume was observed (25). On day 4, the core of the impact site, with blood cells intermixed with damaged axons and the damaged regions appeared to be merging (15). The dorsal column lesion continued to enlarge in size and took the configuration of a long narrow tunnel rostrocaudally extending to the epicenter (26). Five days post-injury, accumulations of macrophages within the hemorrhagic lesion of the spinal cord in degenerating parenchyma could be found, and cystic cavitation of the extended until compromising the white matter (21). Zhang and Guth reported that during the first week, a secondary vascular injury occurred leading to hemorrhage around the dorsal column which increased the SCI injury volume (21). During the first week, the spinal subarachnoid space was decreased regardless of the grades of spinal cord injury severities (27).

After one week, the hemorrhagic lesion almost disappeared, and flattening of the spinal cord in the epicenter became more prominent (23). Shibuya *et al.* showed that the hemorrhagic lesion reached the maximum size in the 5-mm rostral and caudal regions up to 1 week after the injury, and thereafter gradually decreased. No large hemorrhagic or necrotic lesion was observed in the 10-mm rostral or caudal regions in the first week (23). However, in a balloon inflation SCI

model, the injury was extended toward rostral and caudal spinal cord. Seven days after inflating the balloon with 10 microliters of water, the lesion size was 74% of the tissue at the epicenter with a 12 mm rostrocaudal extension. At the same time, inflating the balloon with 15 microliters of water caused 96% of the epicenter tissue damaged and the rostrocaudal extension was 18 mm (28). During the first 2 weeks, the total cord volume significantly decreased in mild, moderate, and severe injuries. The decrease in the area of spared white matter started on day 1 and reached its maximum size on 14 days post-injury (29). By the 2<sup>nd</sup> and the 3<sup>rd</sup> weeks, the primary lesion remained large, whereas the dorsal column lesion significantly decreased in size, probably due to regeneration (21). The progression of white matter damage was slower than grey matter and was related to the severity of injury. The area of the spared white matter was significantly greater in 2 weeks compared to that in 16 weeks post-injury (17). The significant loss of white matter volume was reported only in moderate and severe injuries, while reduction in gray matter volume continued significantly for 3 weeks in all grades of injuries (25). Three weeks after mild, moderate, or severe injury, the average measured rostral/caudal extent of the lesion reached 4 mm (25,30). In addition, a large amount of fluid filling the cystic cavity was found in the center of the spinal cord, with only a thin rim of white matter remaining underneath the pial surface. At 4 weeks after SCI, only an outer rim remained at the injury center, and a similar appearance was seen as late as 10 weeks (24). Histopathologic assessment at 1 month showed restitution of the spinal subarachnoid space, atrophy of the cord, intramedullary cysts in various sizes, and also post-traumatic arachnoiditis characterized by cord tethering, subarachnoid cysts, and nerve roots traps (27). Two months after injury (crushing with jewelers forceps), the dorsal column lesion was almost completely repaired, and the lesion volume significantly reduced (21). The maximal extensions of the cavity occurred rostrocaudal during this time (15). At 9 weeks, significant reductions in the volume of normal-appearing white matter were seen (25). Although the spinal subarachnoid space reduced after both mild and severe injuries in the first week, this space increased in chronic stages post-injury (27). Ellingson *et al.*, showed a significant extension of the traumatic lesion up to 15 weeks at a speed of 57  $\mu\text{m}/\text{day}$  (12).

After 16 weeks, the lesions, in the longitudinal plane, reached 1 to 1.5 segments, both rostrally and caudally. In the medial to lateral plane, these lesions varied in severity from moderate intensity with loss of gray and white matter to severe intensity with loss of gray matter and

## Volume changes after spinal cord injury

extensive loss of white matter with only a thin rim of white matter remaining (10). Fifty-two weeks after contusion, the lesion area appeared to be collapsed. Small flattened cavities were seen in the preserved spinal cord parenchyma (31).

In the other animal models, results were slightly different from what was observed in the rat model. In mice, tissue softening was detectable at the injury site after 6 hours (32). The dorsal columns showed the most dramatic and rapid decline in the myelin amount by 1-day post-injury (33). This reduction was observed in ventral and lateral funiculi, too. During the first week, the Wallerian degeneration occurred obviously through the dorsal funiculi proximal and distal to the site of impact (34). Myelin reduction and shrinkage of cord continued to 30 days (33). Four weeks after contusive SCI, tissue volume loss was approximately 50%, and presence of tissue atrophy was observed (35). In guinea pigs, the spinal cord reduced in the cross-sectional area, particularly in the dorso-ventral axis, over a length of 5-10 mm of the injury level after 10 weeks (36). In opossums, the gap between the cut ends of transected cords increased considerably after 3 days. However, this gap started to be filled up with tissue, some of which appeared to invade the surrounding meninges (37). In rabbits, the epicenter was characterized by a central cavity surrounded by partial rim of the residual white matter after 2 weeks (38). In cats, after 3 weeks, the longitudinal extent of lesion was equivalent to the spinal cord diameter (39). In monkeys, complete disruption in the center of the lesion was reported at 48 hours post-contusion (40). In dogs, the quantitative analysis of spared tissue revealed a dramatically smaller lesion volume and a greater percentage of residual white matter at the 30 minutes compared to 3 hours (41).

Changes related to the extent of tissue damage over time is an important part of the pathophysiologic process after SCI. Early avascularity, the rapid loss of gray matter, slow progression of white matter damage, and late cavitation are the pathophysiologic key points of SCI, which could help researchers to develop proper interventions on a timely basis.

## Acknowledgments

This study was supported by Sina Trauma and Surgery Research Center, Tehran University of Medical Sciences, Tehran, Iran (No. 93-02-38-25620).

## References

1. Ek CJ, Habgood MD, Callaway JK, Dennis R, Dziegielewska KM, Johansson PA, et al. Spatio-temporal progression of grey and white matter damage following contusion injury in rat spinal cord. *PLoS one* 2010;5:e12021.
2. Gensel JC, Tovar CA, Hamers FP, Deibert RJ, Beattie MS, Bresnahan JC. Behavioral and histological characterization of unilateral cervical spinal cord contusion injury in rats. *J Neurotrauma* 2006;23:36-54.
3. Dusart I, Schwab ME. Secondary cell death and the inflammatory reaction after dorsal hemisection of the rat spinal cord. *Eur J Neurosci* 1994;6:712-24.
4. Moher D, Liberati A, Tetzlaff J, Altman DG. Preferred reporting items for systematic reviews and meta-analyses: the PRISMA statement. *Int J Surg* 2010;8:336-41.
5. Fujiki M, Furukawa Y, Kobayashi H, Abe T, Ishii K, Uchida S, Kamida T. Geranylgeranylacetone limits secondary injury, neuronal death, and progressive necrosis and cavitation after spinal cord injury. *Brain Res* 2005;1053:175-84.
6. Kuluz J, Samdani A, Benglis D, Gonzalez-Brito M, Solano JP, Ramirez MA, Luqman A, Santos RD, Hutchinson D, Nares M, Padgett K. Pediatric spinal cord injury in infant piglets: description of a new large animal model and review of the literature. *J Spinal Cord Med* 2010;33:43-57.
7. Noble LJ, Wrathall JR. Spinal cord contusion in the rat: morphometric analyses of alterations in the spinal cord. *Exp Neurol* 1985;88:135-49.
8. Hassannejad Z, Sharif-Alhoseini M, Shakouri-Motlagh A, Vahedi F, Zadegan SA, Mokhtab M, Rezvan M, Saadat S, Shokraneh F, Rahimi-Movaghar V. Potential variables affecting the quality of animal studies regarding pathophysiology of traumatic spinal cord injuries. *Spinal Cord* 2016;54:579-83.
9. Andrade MS, Hanania FR, Daci K, Leme RJ, Chadi G. Contuse lesion of the rat spinal cord of moderate intensity leads to a higher time-dependent secondary neurodegeneration than severe one: An open-window for experimental neuroprotective interventions. *Tissue Cell* 2008;40:143-56.
10. Bose P, Parmer R, Reier PJ, Thompson FJ. Morphological changes of the soleus motoneuron pool in chronic midthoracic contused rats. *Exp Neurol* 2005;191:13-23.
11. Byrnes KR, Fricke ST, Faden AI. Neuropathological differences between rats and mice after spinal cord injury. *J Magn Reson Imaging* 2010;32:836-46.
12. Ellingson BM, Schmit BD, Kurpad SN. Lesion growth and degeneration patterns measured using diffusion tensor 9.4-T magnetic resonance imaging in rat spinal cord injury. *J Neurosurg Spine* 2010;13:181-92.
13. Finkelstein SD, Gillespie JA, Markowitz RS, Johnson DD,

- Black P. Experimental spinal cord injury: qualitative and quantitative histopathologic evaluation. *J Neurotrauma* 1990;7:29-40.
14. Grossman SD, Rosenberg LJ, Wrathall JR. Temporal-spatial pattern of acute neuronal and glial loss after spinal cord contusion. *Exp Neurol* 2001;168:273-82.
  15. Hill CE, Beattie MS, Bresnahan JC. Degeneration and sprouting of identified descending supraspinal axons after contusive spinal cord injury in the rat. *Exp Neurol* 2001;171:153-69.
  16. Hu R, Zhou J, Luo C, Lin J, Wang X, Li X, Bian X, Li Y, Wan Q, Yu Y, Feng H. Glial scar and neuroregeneration: histological, functional, and magnetic resonance imaging analysis in chronic spinal cord injury. *J Neurosurg Spine* 2010;13:169-80.
  17. Steencken AC, Stelzner DJ. Loss of propriospinal neurons after spinal contusion injury as assessed by retrograde labeling. *Neuroscience* 2010;170:971-80.
  18. Zai LJ, Wrathall JR. Cell proliferation and replacement following contusive spinal cord injury. *Glia* 2005;50:247-57.
  19. Metz GA, Curt A, Van De Meent H, Klusman I, Schwab ME, Dietz V. Validation of the weight-drop contusion model in rats: a comparative study of human spinal cord injury. *J Neurotrauma* 2000;17:1-7.
  20. Liu XZ, Xu XM, Hu R, Du C, Zhang SX, McDonald JW, Dong HX, Wu YJ, Fan GS, Jacquin MF, Hsu CY. Neuronal and glial apoptosis after traumatic spinal cord injury. *J Neurosci* 1997;17:5395-406.
  21. Zhang Z, Guth L. Experimental spinal cord injury: Wallerian degeneration in the dorsal column is followed by revascularization, glial proliferation, and nerve regeneration. *Exp Neurol* 1997;147:159-71.
  22. Koyanagi I, Tator CH, Lea PJ. Three-dimensional analysis of the vascular system in the rat spinal cord with scanning electron microscopy of vascular corrosion casts. Part 2: Acute spinal cord injury. *Neurosurgery* 1993;33:285-92.
  23. Shibuya S, Miyamoto O, Itano T, Mori S, Norimatsu H. Temporal progressive antigen expression in radial glia after contusive spinal cord injury in adult rats. *Glia* 2003;42:172-83.
  24. Ek CJ, Habgood MD, Dennis R, Dziegielewska KM, Mallard C, Wheaton B, Saunders NR. Pathological changes in the white matter after spinal contusion injury in the rat. *PloS one* 2012;7:e43484.
  25. Pearse DD, Lo Jr TP, Cho KS, Lynch MP, Garg MS, Marcillo AE, Sanchez AR, Cruz Y, Dietrich WD. Histopathological and behavioral characterization of a novel cervical spinal cord displacement contusion injury in the rat. *J Neurotrauma* 2005;22:680-702.
  26. Narayana PA, Grill RJ, Chacko T, Vang R. Endogenous recovery of injured spinal cord: longitudinal in vivo magnetic resonance imaging. *J Neurosci Res* 2004;78:749-59.
  27. Reyes-Alva HJ, Franco-Bourland RE, Martinez-Cruz A, Grijalva I, Madrazo I, Guizar-Sahagun G. Spatial and temporal morphological changes in the subarachnoid space after graded spinal cord contusion in the rat. *J Neurotrauma* 2013;30:1084-91.
  28. Lonjon N, Kouyoumdjian P, Prieto M, Bauchet L, Haton H, Gaviria M, Privat A, Perrin FE. Early functional outcomes and histological analysis after spinal cord compression injury in rats. *J Neurosurg Spine* 2010;12:106-13.
  29. Vaughn CN, Iafate JL, Henley JB, Stevenson EK, Shlifer IG, Jones TB. Cellular neuroinflammation in a lateral forceps compression model of spinal cord injury. *Anat Rec* 2013;296:1229-46.
  30. Moriarty LJ, Duerstock BS, Bajaj CL, Lin K, Borgens RB. Two-and three-dimensional computer graphic evaluation of the subacute spinal cord injury. *J Neurol Sci* 1998;155:121-37.
  31. Guizar-Sahagun G, Grijalva I, Madrazo I, Franco-Bourland R, Salgado H, Ibarra A, et al. Development of post-traumatic cysts in the spinal cord of rats subjected to severe spinal cord contusion. *Surg Neurol* 1994;41:241-9.
  32. Fairholm DJ, Turnbull IM. Microangiographic study of experimental spinal cord injuries. *J Neurosurg* 1971;35:277-86.
  33. Brennan FH, Cowin GJ, Kurniawan ND, Ruitenberg MJ. Longitudinal assessment of white matter pathology in the injured mouse spinal cord through ultra-high field (16.4 T) in vivo diffusion tensor imaging. *Neuroimage* 2013;82:574-85.
  34. Blomster LV, Cowin GJ, Kurniawan ND, Ruitenberg MJ. Detection of endogenous iron deposits in the injured mouse spinal cord through high-resolution ex vivo and in vivo MRI. *NMR Biomed* 2013;26:141-50.
  35. Kuhn PL, Wrathall JR. A mouse model of graded contusive spinal cord injury. *J Neurotrauma* 1998;15:125-40.
  36. Blight AR. Morphometric analysis of a model of spinal cord injury in guinea pigs, with behavioral evidence of delayed secondary pathology. *J Neurol Sci* 1991;103:156-71.
  37. Lane MA, Truettner JS, Brunschwig JP, Gomez A, Bunge MB, Dietrich WD, et al. Age-related differences in the local cellular and molecular responses to injury in developing spinal cord of the opossum, *Monodelphis domestica*. *Eur J Neurosci* 2007;25:1725-42.
  38. Vink R, Noble LJ, Knoblach SM, Bendall MR, Faden AI. Metabolic changes in rabbit spinal cord after trauma: magnetic resonance spectroscopy studies. *Ann Neurol*

## Volume changes after spinal cord injury

- 1989;25:26-31.
39. Gledhill RF, Harrison BM, McDonald WI. Demyelination and remyelination after acute spinal cord compression. *Exp Neurol* 1973;38:472-87.
  40. Bresnahan JC. An electron-microscopic analysis of axonal alterations following blunt contusion of the spinal cord of the rhesus monkey (*Macaca mulatta*). *J Neurological Sci* 1978;37:59-82.
  41. Carlson GD, Gorden CD, Oliff HS, Pillai JJ, Lamanna JC. Sustained spinal cord compression: part I: time-dependent effect on long-term pathophysiology. *JBSJ* 2003;85:86-94.
  42. Anthes DL, Theriault E, Tator CH. Characterization of axonal ultrastructural pathology following experimental spinal cord compression injury. *Brain Res* 1995;702:1-6.
  43. Blight AR. Delayed demyelination and macrophage invasion: a candidate for secondary cell damage in spinal cord injury. *Cent Nerv Syst Trauma* 1985;2:299-315.
  44. Camand E, Morel MP, Faissner A, Sotelo C, Dusart I. Long-term changes in the molecular composition of the glial scar and progressive increase of serotonergic fibre sprouting after hemisection of the mouse spinal cord. *Eur J Neurosci* 2004;20:1161-76.
  45. Ditor DS, John S, Cakiroglu J, Kittmer C, Foster PJ, Weaver LC. Magnetic resonance imaging versus histological assessment for estimation of lesion volume after experimental spinal cord injury. *J Neurosurg* 2008;9:301-6.
  46. Griffiths IR. Vasogenic edema following acute and chronic spinal cord compression in the dog. *J Neurosurg* 1975;42:155-65.
  47. Kostyk SK, Popovich PG, Stokes BT, Wei P, Jakeman LB. Robust axonal growth and a blunted macrophage response are associated with impaired functional recovery after spinal cord injury in the MRL/MpJ mouse. *Neuroscience* 2008;156:498-514.
  48. Kouyoumdjian P, Lonjon N, Prieto M, Haton H, Privat A, Asencio G, et al. A remotely controlled model of spinal cord compression injury in mice: toward real-time analysis. *J Neurosurg Spine* 2009;11:461-70.
  49. Leskovar AL, Moriarty LJ, Turek JJ, Schoenlein IA, Borgens RB. The macrophage in acute neural injury: changes in cell numbers over time and levels of cytokine production in mammalian central and peripheral nervous systems. *J Exp Biol* 2000;203:1783-95.
  50. Li GL, Farooque M, Isaksson J, Olsson YN. Changes in synapses and axons demonstrated by synaptophysin immunohistochemistry following spinal cord compression trauma in the rat and mouse. *Biomed Environ Sci* 2004;17:281-90.
  51. Namiki J, Tator CH. Cell proliferation and nestin expression in the ependyma of the adult rat spinal cord after injury. *J Neuropathol Exp Neurol* 1999;58:489-98.
  52. Nout YS, Mihai G, Tovar CA, Schmalbrock P, Bresnahan JC, Beattie MS. Hypertonic saline attenuates cord swelling and edema in experimental spinal cord injury: a study utilizing magnetic resonance imaging. *Crit Care Med* 2009;37:2160-6.
  53. Poon PC, Gupta D, Shoichet MS, Tator CH. Clip compression model is useful for thoracic spinal cord injuries: histologic and functional correlates. *Spine* 2007;32:2853-9.
  54. Swartz KR, Scheff NN, Roberts KN, Fee DB. Exacerbation of spinal cord injury due to static compression occurring early after onset. *J Neurosurg Spine* 2009;11:570-4.
  55. Vessal M, Aycock A, Garton MT, Ciferri M, Darian-Smith C. Adult neurogenesis in primate and rodent spinal cord: comparing a cervical dorsal rhizotomy with a dorsal column transection. *Eur J Neurosci* 2007;26:2777-94.
  56. Whetstone WD, Hsu JY, Eisenberg M, Werb Z, Noble-Haesslein LJ. Blood-spinal cord barrier after spinal cord injury: Relation to revascularization and wound healing. *J Neurosci Res* 2003;74:227-39.